



# Frontal lobe position after single-layer cadaveric dermal matrix repair of large anterior skull base defects

Corinna G. Levine<sup>1</sup> | Abdullah N. Al-Rasheedi<sup>2</sup> | Alejandro Mantero<sup>3</sup> |  
Mohammad Al-Bar<sup>4</sup> | Roy R. Casiano<sup>1</sup>

<sup>1</sup>Rhinology & Skull Base Surgery, Department of Otolaryngology, University of Miami Miller School of Medicine, Miami, Florida, USA

<sup>2</sup>Otolaryngology Head & Neck Surgery, Jouf University—Medical College, Skaka, Saudi Arabia

<sup>3</sup>Department of Public Health Sciences, Biostatistics Collaboration and Consulting Core, Miami, Florida, USA

<sup>4</sup>Otolaryngology, King Fahad Hospital of the University, Imam Abdulrahman Bin Faisal University, Khobar, Saudi Arabia

## Correspondence

Corinna G. Levine, Rhinology & Skull Base Surgery, Department of Otolaryngology, University of Miami Miller School of Medicine, 1120 NW 14th St, 5th Floor, Miami, FL 33136, USA.

Email: [cxl861@miami.edu](mailto:cxl861@miami.edu)

## Funding information

None

## Abstract

**Objective:** Endoscopic repair of large anterior skull base (ASB) defects has excellent results when using multilayered repairs with a nasoseptal flap. However, in extensive intranasal tumors, a nasoseptal flap may not always be available. One alternative option is a flexible single-layer ASB repair. Initial studies indicate low cerebrospinal fluid leak rates with a single-layer repair. However, the level of frontal lobe support, particularly the propensity for a significant inferior displacement of the frontal lobe, is not known. The goal of this study is to determine the frontal lobe position after single-layer acellular dermal allograft repair in large ASB defects.

**Study Design:** Retrospective cohort study.

**Setting:** Tertiary care medical center.

**Subjects and Methods:** This cohort study compares the frontal lobe position in adults who underwent endoscopic endonasal ASB tumor resection and single-layer cadaveric dermal matrix repair (ASB cohort) with control subjects without intracranial abnormalities (control cohort). The ASB cohort includes subjects with an ASB defect of  $\geq 5$  cm anterior/posterior and  $\geq 1.5$  cm wide and who had imaging at least 2 months after surgery. The frontal lobe position is measured on sagittal CT/MRI using a reference line from the base of the sella to the nasion. A value of zero indicates that the inferior-most aspect of the frontal lobe is at the level of the nasion–sellar line. A positive value indicates that the frontal lobe is inferior to the nasion–sellar line. The ASB cohort frontal lobe position is compared with the control cohort using the Mann–Whitney *U* test. A priori we set an absolute difference of 5 mm as a clinically significant difference.

**Results:** The ASB cohort includes 47 subjects who are 57% male with an average age of 60 years (range: 31–89 years). The most common ASB pathology is esthesioneuroblastoma ( $n = 21$ ) and 81% of the ASB cohort had postoperative radiation. The control cohort includes 20 subjects who are 60% male, with a mean age of 45 years (range: 19–74 years). The majority of controls underwent imaging

This is an open access article under the terms of the [Creative Commons Attribution-NonCommercial-NoDerivs License](https://creativecommons.org/licenses/by-nc-nd/4.0/), which permits use and distribution in any medium, provided the original work is properly cited, the use is non-commercial and no modifications or adaptations are made.

© 2022 The Authors. *World Journal of Otorhinolaryngology - Head and Neck Surgery* published by John Wiley & Sons Ltd on behalf of Chinese Medical Association.

for head trauma ( $n = 13$ ). The ASB mean frontal lobe position is  $-0.2$  mm superior to the nasion–sellar line (range:  $-9.2$  to  $10.4$  mm), while the control's mean frontal lobe position is  $1.1$  mm inferior to the nasion–sellar line. This difference is not statistically significant ( $P = 0.13$ ) and does not reach our a priori definition of clinical significance. The frontal lobe position of ASB subjects who had radiation is closer to the nasion–sellar line as compared with those who did not undergo radiation.

**Conclusions:** Single-layer acellular dermal graft repair maintains frontal lobe support and position in large ASB defects.

#### KEYWORDS

anterior skull base, cohort study, frontal lobe, skull base repair, skull base tumor

#### Key points

- Single-layer dermal graft anterior skull base repair did not demonstrate inferior displacement of the frontal lobes as compared to controls.
- Radiation had a negligible impact on the position of the frontal lobes after single-layer dermal graft repair of large anterior skull base defects.

## INTRODUCTION

Recently, we have seen noticeable progress in the ability to endonasally access and resect large skull base tumors. In turn, there is an increased need for robust skull base reconstruction options to close large and more complex defects. Successful endoscopic reconstruction depends on more than one factor, including size, location of the defect, tumor type, exposure to radiation therapy, and the rate of cerebrospinal fluid (CSF) flow. These factors are important considerations when selecting the most appropriate reconstructive approach.<sup>1-3</sup> Multiple studies demonstrate excellent results with the endoscopic repair of large anterior skull base (ASB) defects or malignant neoplasms.<sup>1-6</sup> Most studies describe using multilayered repairs with a septal flap. However, in the setting of an extensive intranasal tumor, a nasoseptal flap may not always be available. In these instances, alternative vascularized flaps or single-layer reconstruction can be used to reconstruct large ASB defects. Due to the increased surgical time and morbidity of raising another vascularized flap outside of the nasal cavity, such as a pericranial flap, many surgeons choose a single-layer repair. Several centers have published results indicating an excellent overall success rate of  $>90\%$ , as defined by the absence of postoperative CSF leak.<sup>7,8</sup> However, it is not clear how much support a flexible single-layer ASB graft reconstruction provides and if significant inferior displacement of the frontal lobe occurs over time. The goal of this study is to determine the frontal lobe position after single-layer dermal matrix allograft repair in large ASB defects.

## MATERIALS AND METHODS

### Study design

This is a retrospective cohort study comparing the frontal lobe position in subjects who underwent ASB tumor resection and single-layer cadaveric dermal matrix repair (ASB cohort) with control subjects who did not have prior skull base trauma (control cohort). This study was approved by the Institutional Review Board at the University of Miami.

### Population

The ASB cohort included all subjects who underwent endoscopic ASB tumor resection and reconstruction with a single-layer cadaveric dermal allograft at the University of Miami Hospital between June 2008 and June 2019. We included adult subjects with a skull base defect of at least  $5$  cm anterior to posterior and at least  $1.5$  cm wide. Subjects must have a postoperative CT or MRI imaging 2 months or more after ASB surgery. We excluded all patients who underwent a combined open and endoscopic surgical approach for tumor resection.

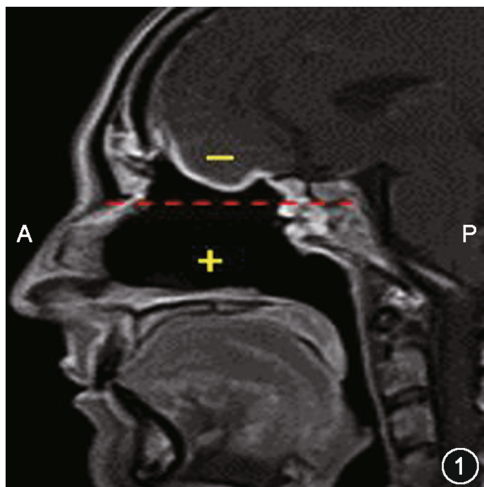
The control cohort included a random sample of 20 consecutive nonsurgical patients who underwent routine head imaging for reasons unrelated to ASB tumors or intracranial lesions in April 2014. Subjects were included if they had normal intracranial findings and anatomy, as assessed by the neuroradiologist in the final report. Subjects with any abnormal intracranial findings were excluded.

## Frontal lobe position measurement

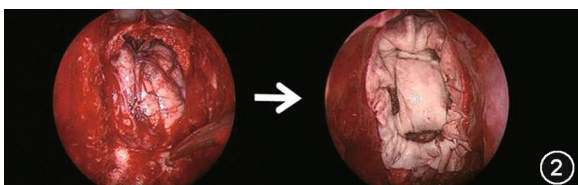
The frontal lobe's position is measured on a sagittal view of CT/MRI (Figure 1) using a reference line from the base of the sella to the nasion (nasion–sellar line). A value of 0 mm indicates that the inferior aspect of the frontal lobe is at the level of the nasion–sellar line. A positive value indicates the frontal lobe dropped inferiorly below the nasion–sellar line. A negative value indicates that the frontal lobe is positioned superior to the nasion–sellar line (Figure 1). When multiple postoperative imaging studies were available, we used the study at the time furthest from surgery. A priori we set an absolute difference of 5 mm as a clinically significant difference.

## Surgical technique

Transnasal endoscopic surgical resection of the tumor was performed as described in detail in the text by Casiano et al.<sup>7</sup> Briefly, each defect was repaired using the Miami “inlay onlay” technique or “hammock” technique with a single-layer acellular dermal graft (medium thickness



**FIGURE 1** Frontal lobe position is measured using a sagittal view of CT/MRI using a reference line from the base of the sella to the nasion. Frontal lobe position at the nasion–sellar line is represented by zero. Frontal lobe position is measured from the nasion–sellar line in millimeters. Position superior to the line is a negative number, while position below the line is positive



**FIGURE 2** Anterior skull base repair using single-layer acellular dermal matrix allograft

AlloDerm: 0.53–1.02 mm, LifeCell Corporation). The graft is positioned into the defect in its central portion and absorbable packing is placed at the edges of the defect and tucked under the frontal lobe, creating the inlay portions. The intracranial (and supraorbital) part of the graft is held in position by the brain's weight. The extracranial portion of the graft extends over the bony margins of the defect, creating the onlay portion of the repair (Figure 2). Nasal packing (Merocel: 4.5 cm Medtronic Xomed Incorporated) is placed in the nasal cavity to support the repair. This packing is removed within 2 weeks after surgery. Lumbar drains are not placed as part of the standard repair and tissue adhesive is not used.

## Statistical analysis

Descriptive statistics were determined for each cohort and compared between groups. Subgroup descriptive statistics are compared within the ASB cohort. Mean and median frontal lobe position is statistically compared between cohorts using the Mann–Whitney *U* and Wilcoxon rank-sum tests. Cohort subgroups were compared using the  $\chi^2$  and Kruskal–Wallis tests. All biostatistical analysis was performed in R version 4.0.0. A *P* value less than 0.5 is considered statistically significant.

## RESULTS

### Cohort descriptive statistics

The ASB cohort included 47 subjects who met initial inclusion and exclusion criteria. The ASB cohort was 57% male with a mean age of 60 years (range: 31–89 years). The average time from surgery to follow-up imaging was 2.6 years (mean: 956 days; range: 60–4112) and average body mass index of 25.8 (range: 16.6–34.8). The tumor pathologies were esthesioneuroblastoma ( $n = 21$ ), squamous cell carcinoma (SCC) and adenocarcinoma (Adeno) ( $n = 14$ ) and olfactory groove meningiomas ( $n = 2$ ). The other 10 subjects (Other) had a mix of other benign and malignant tumor types such as hemangiopericytoma, adenoid cystic carcinoma, inverting papilloma, synovial sarcoma, and others. In the ASB cohort, 81% (38/47) of subjects had radiation after tumor resection (Table 1).

The control cohort consisted of 20 subjects who were 60% male, with a mean age of 45 years (range: 19–74 years, Table 1). The majority of subjects in the control cohort underwent CT scan for head trauma ( $n = 13$ ). The other indications for head imaging included acute sinusitis ( $n = 3$ ), diplopia ( $n = 2$ ), facial abscess ( $n = 1$ ), and retroantral mass ( $n = 1$ ). The cohort was significantly younger than the ASB cohort ( $P < 0.001$ ) and did not have radiation.

### Frontal lobe position

The frontal lobe position after tumor resection and reconstruction is just superior to the reference line (mean:  $-0.2$  mm; range:  $-9.2$  to

**TABLE 1** Cohort demographic and clinical characteristics of ASB and control cohort

Patient characteristics	ASB cohort (n = 47)	Control cohort (n = 20)	P value
Age, median (range)	60 (31–89)	45 (19–74)	<0.001 <sup>a</sup>
Gender, male, n (%)	27 (57)	12 (60)	1 <sup>b</sup>
Radiation, n (%)	38 (81)	0 (0)	—
Imaging indication	Skull base tumor Esthesio (21) Meningiomas (2) SCC and Adeno (14) Benign and other tumors (10)	Head pathology Trauma (13) Sinusitis (3) Diplopia (2) Facial abscess (1) Retroantral mass (1)	—

Abbreviations: Adeno, adenocarcinoma; ASB, anterior skull base; ethesio, esthesioneuroblastoma; SCC, squamous cell carcinoma; —, no data.

<sup>a</sup>Wilcoxon rank sum test.

<sup>b</sup> $\chi^2$ -squared test.

**TABLE 2** Frontal lobe position relative to nasion–sellar line of ASB and control cohort

	Mean (mm)	Median (mm)	Range (mm)	P value
ASB cohort	-0.2	0.0	-9.2 to 10.4	0.13 <sup>a</sup>
Radiation				0.67 <sup>a</sup>
Yes	-0.5	0.0	-9.2 to 8.1	
No	1.0	-2.4	-4.4 to 10.4	
Imaging indication				0.48 <sup>b</sup>
Ethesio	-1.4	-1.0	-9.2 to 7.3	
Meningioma	2.8	2.8	-3.0 to 8.5	
SCC and Adeno	1.3	0.9	-5.2 to 5.3	
Other	-0.3	-0.8	-5.2 to 5.3	
Control cohort	1.1	0.7	-1.7 to 3.6	

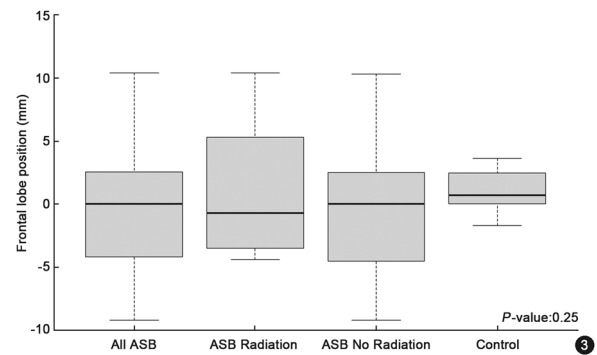
Note: Frontal lobe position is measured relative to the nasion–sellar line in millimeters (mm). A positive displacement is below the reference line.

Abbreviations: Adeno, adenocarcinoma; ASB, anterior skull base; ethesio, esthesioneuroblastoma; SCC, squamous cell carcinoma.

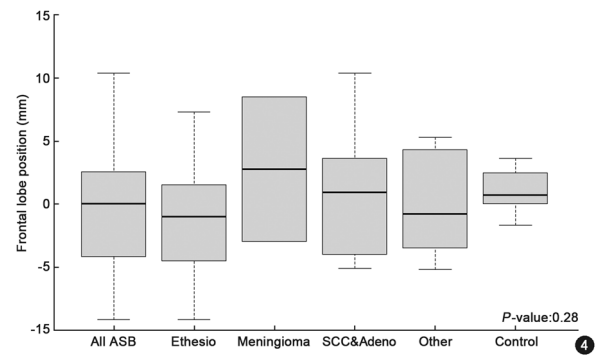
<sup>a</sup>Wilcoxon rank sum test.

<sup>b</sup>Kruskal–Wallis test.

10.4). In contrast, the control cohort's frontal lobe position is inferior to the nasion–sellar line (mean: 1.1 mm; range: -1.7 to 3.6, Table 2). This difference was not statistically different ( $P = 0.13$ ). Subjects who underwent radiation after tumor resection and repair have a frontal lobe position that is closer to the nasion–sellar line



**FIGURE 3** Impact of radiation on frontal lobe displacement after treatment compared with the control cohort. Frontal lobe position is measured relative to the reference line in millimeters. A positive displacement is below the nasion–sellar line. Box plot represents the interquartile date and the line indicates the median frontal lobe position measured from the nasion–sellar line. ASB, anterior skull base



**FIGURE 4** Frontal lobe displacement after treatment among different skull base tumor types as compared with the control cohort. Box plot represents interquartile range and the line indicates the median frontal lobe position measured from the nasion–sellar line. Adeno, adenocarcinoma; ASB, anterior skull base; ethesio, esthesioneuroblastoma; SCC, squamous cell carcinoma

than the subjects who did not receive postoperative radiotherapy (radiation mean -0.5 mm vs. no radiation mean 1.0 mm;  $P = 0.67$ ). This difference was not statistically or clinically significant (Table 2, Figure 3).

We also compared frontal lobe position after reconstruction by diagnosis (Table 2, Figure 4). Esthesioneuroblastomas on average had frontal lobe position above the nasion–sellar line (mean: -1.4 mm; range: -9.2 to 7.3 mm). In contrast, meningiomas, SCC, and Adeno on average had frontal lobe displacement below the nasion–sellar line (meningioma: mean 2.8 mm; range: -3.0 to 8.6 mm; SCC and Adeno: mean 1.3 mm; range: -5.2 to 5.3 mm). The category of Other mixed tumor types on average had displacement superior to the nasion–sellar line (mean: -0.3 mm, range: -5.2 to 5.3 mm). The difference between categories was not statistically significant ( $P = 0.48$ ) and did not reach clinical significance.

## DISCUSSION

### Frontal lobe position after reconstruction

Frontal lobe position after ASB repair has been evaluated in multilayer repairs. Eloy et al.<sup>5</sup> examined nine subjects who had endoscopic endonasal resection and repair for large ASB tumors. They used a triple-layer repair that included fascia lata, acellular dermal allograft, and a nasoseptal flap. The position of the frontal lobe was measured pre- and postoperatively relative to the nasion-sellar line. No comparison group was used. It is notable that this study used preoperative imaging where the tumor was present and could be displacing the frontal lobe superiorly, to make the preoperative measurements. The study found that on average subjects had a slightly superior displacement of the frontal lobe and that all changes in frontal lobe position were less than 5 mm. The authors concluded that this study demonstrated that rigid support was not necessary in ASB repair.

Fiacchini et al.<sup>9</sup> compared the degree of frontal lobe displacement among subjects undergoing endoscopic multilayer reconstruction with pericranial flap reconstruction using the nasion-sellar line as a reference. This study found that there was more inferior displacement of the frontal lobe (mean: 2.3 mm) in the subjects who underwent naso-septal flap repair as compared with the pericranial flap (mean: 0.5 mm superior displacement). In both repair techniques, the amount of average displacement was also less than 5 mm.

To our knowledge, this is the first study to examine frontal lobe position after single-layer endonasal endoscopic repair of the ASB. Rather than use the subjects as their own controls, which has inherent bias related to the potential superior displacement of the frontal lobe by the tumor, we compared our postoperative frontal lobe position with that of normal control subjects who did not have an intracranial abnormality. Thus, our results compare the final frontal lobe position after resection and repair with an estimate of where the subject's frontal lobe might have been if they did not have an ASB tumor. On average our ASB cohort had a 1.3 mm superior displacement of the frontal lobe relative to the nasion-sellar line as compared with the controls. Our finding is similar to the study by Eloy et al.<sup>5</sup> and indicates that inferior frontal lobe displacement or "frontal sagging" is generally not present after single-layer dermal graft reconstruction.

### ASB subgroups

#### Radiation

Previous research examining single-layer nonrigid repairs did not specifically examine durability beyond CSF in the absence of a CSF leak.<sup>8,10,11</sup> In this study, 81% of subjects in the ASB cohort underwent radiation after tumor resection and repair. Compared with controls, the ASB subjects have a frontal lobe position that is

superior to the nasion-sellar line. Comparing ASB repair subjects who had radiation to the ASB subgroup that did not receive radiation, those who had radiation have a frontal lobe position that is superior to the nasion-sellar line. ASB subject without radiation had a frontal lobe position below the nasion-sellar line and that is very similar to the control cohort. The difference between mean frontal lobe position between the two cohorts is 1.5 mm and does not reach clinical significance. Our findings indicate that postoperative radiation has a minimal impact on frontal lobe position after single-layer acellular dermal graft repair.

#### ASB tumor type

This study has small subgroups of different tumor types. In general, SCCs and adenocarcinomas have frontal lobe position that is most similar to the controls. Meningiomas have a frontal lobe position that is inferior to the controls and other tumor types. In contrast, the mixed other tumors and esthesioneuroblastomas had a frontal lobe position furthest superior from the nasion-sellar line and the control mean position. These are subtle differences, all average measurements are significantly less than the clinically significant difference of 5 mm; however, due to the small subgroup samples sizes, no definitive conclusions can be drawn for the subtle differences. A larger sample is needed to study this further.

#### Limitations

This is a retrospective cohort study that includes the limitations of utilizing follow-up imaging that occurs at different times after surgery. When multiple options for postoperative imaging were present, we choose to use the imaging study further from surgery to maximize our ability to capture displacement of the frontal lobe position over time.

The sample size of 47 ASB subjects is small heterogeneous sample. While this is a large series for the ASB literature, this cohort does include patients who did and did not have radiation and those who had malignant or nonmalignant tumors. Our subgroup analysis does indicate that frontal lobe position after resection and repair differs between individual tumor pathologies. This is an inherent challenge as some tumors are more likely to involve a nasoseptal flap than others. For example, it is rare to have an olfactory meningioma with a single-layer repair because a nasoseptal flap is often uninvolved and readily available. In these cases, the senior authors choose to utilize this second layer to provide the patient with the best possible potential repair outcomes.

There are inherent differences between the cohorts. In addition to the previously mentioned differences in tumor resection and radiation, the ASB cohort is older. Since the brain naturally loses some volume over time, it is possible that we might see a more superior "natural" frontal lobe position in age-matched controls. This is a conservative bias where we may be overestimating the difference

between our ASB cohort frontal lobe position and that of the controls. The healthy controls were also thought to be a more appropriate control than those with ASB tumors treated with radiation ( $\pm$ chemotherapy) by the authors given the propensity for residual or scarred tissue that could create a bias that underestimates the difference in frontal lobe position.

Lastly, it is important to acknowledge the limits of human and imaging accuracy during tumor measurement. This measurement specifically depends on how finely the sagittal imaging cuts were performed and how precise the measurement ruler lines were drawn. While every effort was made to accurately measure the position of the reference line and the frontal lobe position to a tenth of a millimeter, it is likely that the error in these measurements is 1–3 tenths of a millimeter.

## CONCLUSIONS

This retrospective study indicates that the use of single-layer acellular dermal graft repair can support the frontal lobe in large ASB defects that result after the resection of benign and malignant tumors. The average frontal lobe position is within 5 mm from the position of healthy controls who did not have ASB instrumentation or intracranial abnormalities. Furthermore, frontal lobe support and position are maintained after adjuvant radiation.

## AUTHOR CONTRIBUTIONS

*Conceptualization, methodology, data curation, formal analysis, roles/writing—original draft, writing—review and editing, supervision:* Corinna G. Levine. *Data curation, methodology, roles/writing—original draft, writing—review and editing:* Abdullah N. Al-Rasheedi. *Methodology, formal analysis, writing—review and editing:* Alejandro Mantero. *Data curation, methodology, writing—review and editing:* Mohammad Al-Bar. *Conceptualization, methodology, writing—review and editing; project administration; supervision:* Roy R. Casiano.

## ACKNOWLEDGMENT

None declared.

## CONFLICT OF INTERESTS

Roy Casiano is a consultant for Medtronic, Neil Med Inc., Olympus ENT. His role does not conflict with the research in this manuscript.

## DATA AVAILABILITY STATEMENT

The data supporting the findings of this study is available on request from corresponding author provided that there is data sharing agreement approval. The data is not publicly available due to privacy and ethical restrictions.

## ETHICS STATEMENT

The Institutional review board at the University of Miami approved this retrospective review.

## REFERENCES

- Zuniga MG, Turner JH, Chandra RK. Updates in anterior skull base reconstruction. *Curr Opin Otolaryngol Head Neck Surg*. 2016;24(1):75-82. doi:10.1097/MOO.0000000000000223
- Harvey RJ, Parmar P, Sacks R, Zanation AM. Endoscopic skull base reconstruction of large dural defects: a systematic review of published evidence. *Laryngoscope*. 2012;122(2):452-459. doi:10.1002/lary.22475
- Soudry E, Turner JH, Nayak JV, Hwang PH. Endoscopic reconstruction of surgically created skull base defects: a systematic review. *Otolaryngol Head Neck Surg*. 2014;150(5):730-738. doi:10.1177/0194599814520685
- Anstead A, Lu JJ. Cerebral spinal fluid leak repair. *Opera Tech Otolaryngol Head Neck Surg*. 2014;25(2):187-193.
- Eloy JA, Shukla PA, Choudhry OJ, Singh R, Liu JK. Assessment of frontal lobe sagging after endoscopic endonasal transcribriform resection of anterior skull base tumors: is rigid structural reconstruction of the cranial base defect necessary. *Laryngoscope*. 2012;122(12):2652-2657. doi:10.1002/lary.23539
- Komotar RJ, Starke RM, Raper DM, Anand VK, Schwartz TH. Endoscopic endonasal versus open repair of anterior skull base CSF leak, meningocele, and encephalocele: a systematic review of outcomes. *J Neurol Surg A Cent Eur Neurosurg*. 2013;74(4):239-250. doi:10.1055/s-0032-1325636
- Casiano RR, Herzallah IR, Eloy JA, Margulies R. *Endoscopic Sinonasal Dissection Guide: Including Orbit and Skull Base*. 2nd ed. Thieme Medical Publishers; 2017.
- Yoo F, Wang MB, Bergsneider M, Suh JD. Single layer repair of large anterior skull base defects without vascularized mucosal flap. *J Neurol Surg B Skull Base*. 2017;78(2):139-144. doi:10.1055/s-0036-1593438
- Germani RM, Vivero R, Herzallah IR, Casiano RR. Comparison of a purely endoscopic three-layer technique versus pericranial flap for reconstruction of anterior skull base defects after sino-nasal tumor resection: assessment of postoperative frontal lobe sagging and frontal lobe falling. *Rhinology*. 2020;58(5):482-488. doi:10.4193/Rhin19.431
- Germani RM, Vivero R, Herzallah IR, Casiano RR. Endoscopic reconstruction of large anterior skull base defects using acellular dermal allograft. *Am J Rhinol*. 2007;21(5):615-618. doi:10.2500/ajr.2007.21.3080
- Lorenz RR, Dean RL, Hurley DB, Chuang J, Citardi MJ. Endoscopic reconstruction of anterior and middle cranial fossa defects using acellular dermal allograft. *Laryngoscope*. 2003;113(3):496-501. doi:10.1097/00005537-200303000-00019

**How to cite this article:** Levine CG, Al-Rasheedi AN, Mantero A, Al-Bar M, Casiano RR. Frontal lobe position after single-layer cadaveric dermal matrix repair of large anterior skull base defects. *World J Otorhinolaryngol Head Neck Surg*. 2022; 8:36-41. doi:10.1002/wjo2.23