



## Case report

# Hypersensitivity pneumonitis caused by the broom grass (*Calluna vulgaris*)



Yusuf Aydemir\*, Adil Can Güngen, Hikmet Çoban

Sakarya University, Department of Pulmonology, Sakarya, Turkey

## ARTICLE INFO

## Article history:

Received 1 February 2015

Received in revised form

2 June 2015

Accepted 3 June 2015

## Keywords:

Hypersensitivity pneumonitis

Broom grass

*Calluna vulgaris*

## ABSTRACT

Hypersensitivity pneumonitis (HP), is an inflammatory disease that represents one possible response of the interstitial and parenchymal tissue to the intensive and repeated inhalation of organic dusts or reactive chemicals substances. In this case report, for the first time in the literature as we know, acute hypersensitivity pneumonitis in a patient who working in broom grass manufacturing were presented. Broom manufacturer employee 35 years old female patient was admitted with dyspnea, fever and cough, beginning the three months before. Physical examination, there were bilateral basal crackles. On Thorax CT bilateral diffuse ground-glass opacity and mosaic perfusion were observed. Patient was hospitalized, IV prednisolone therapy was started. Almost complete clinical improvement was achieved. We would like to emphasize that detailed occupational history should be questioned; because; diagnosis of acute HP, due to the mixing with the viral infection or atypical pneumonia, easily skipped.

© 2015 The Authors. Published by Elsevier Ltd. This is an open access article under the CC BY-NC-ND license (<http://creativecommons.org/licenses/by-nc-nd/4.0/>).

## 1. Introduction

Hypersensitivity pneumonitis (HP), is an inflammatory disease that represents one possible response of the interstitial and parenchymal tissue to the intensive and repeated inhalation of organic dusts or reactive chemicals substances. Multiple causative agents have been identified but the two most common are: Thermophilic actinomycetes, responsible for farmers lung, and avian proteins, which induce bird fancier's lung. Except farmers, HP; also working in the food industry, mushroom cultivation, tobacco farming, gypsum-plaster and wooden workers, are frequently seen. In this case report, for the first time in the literature as we know, acute hypersensitivity pneumonitis in a patient who working in broom grass manufacturing were presented.

## 2. Case report

Broom manufacturer employee 35 years old female patient was admitted with dyspnea, fever, cough, fatigue, loss of appetite and weight loss beginning the three months before. She had 5 packs/year smoking history. Previously been treated with antibiotics

(macrolid and gemifloksasin) and combination of inhaled beta adrenergic agonist and steroid, but complaints not improved. Physical examination, fever 37.6 C, there were bilateral basal crackles. Other systemic examination and spirometry were normal. The PA chest X-ray showed bilateral reticulonodular infiltration (Fig. 1). On Thorax CT bilateral diffuse ground-glass opacity and mosaic perfusion were observed (Fig. 2). Laboratory investigations Saturation 94, WBC:7.1 K/uL, CRP:14.3 mg/l (normal range: 0–5 mg/l); sedimentation was 27 mm/h (normal range: 0–20 mg/l). Routine biochemical tests, except to LDH (313 U/L; normal range: 125–220 U/L) were normal. Total IgE levels and RF were normal. Patient was hospitalized, 80 mg/day IV prednisolone therapy was started. Clinical improvement was achieved, steroid treatment was discontinued within 10 days. Control CT was found to be almost complete disappearance of the lesions.

## 3. Discussion

HP is a inflammatory respiratory disease caused by a delayed immune response to a variety of antigens. It was first described in farmers about eighty years ago [1]. The true prevalence of HP is unknown due to its failure to diagnose, as well as geographical variation related to the regional distribution of triggering environmental exposures [2].

Causative agents of HP include microorganisms (Thermophilic actinomycetes. *Saccharopolyspora rectivirgula*, *Bacillus subtilis*,

\* Corresponding author. Sakarya University, Training and Research Hospital, 54100 Sakarya, Turkey.

E-mail address: [dryaydemir@yahoo.com](mailto:dryaydemir@yahoo.com) (Y. Aydemir).

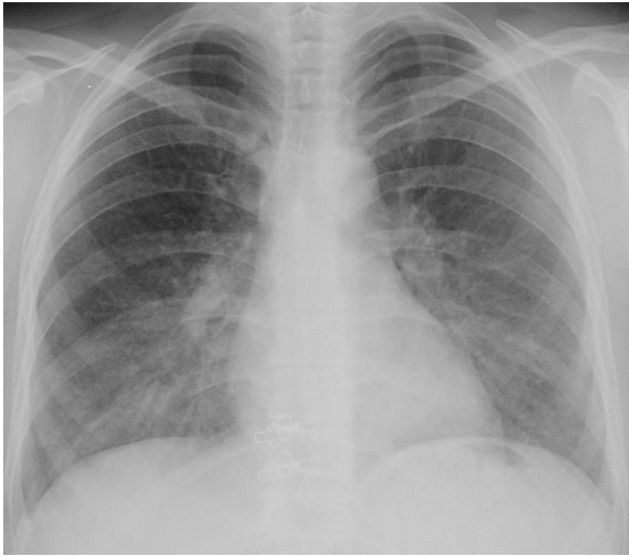


Fig. 1. Chest x-ray in patient.

Penicillium species, Mycobacterium avium-intracellulare, Trichosporon cutaneum, Aspergillus), plant (soybean, coffee) and animal (avian, rat) proteins, and organic and inorganic chemicals (isocyanates, anhydrides) [3]. Exposure to these airborne antigens, occurs in various environments, hobbies and occupations, with contaminated air. These occupations include: Farmers, bird fanciers, wood, cheese, malt, plastic workers, painters, hot tub users, animal handlers and laboratory workers, wheat workers and silo fillers [4]. Others have been reported only in isolated cases. These isolated cases shows the importance of the careful taking of an environmental history. Furthermore, recognition of etiologic agents in at the rare occupations exposures is important. Our patient is the first case described in this very rare occupational group, as far as we know.

The clinical presentation is divided into acute, subacute, and chronic forms, depending on the amount of inhaled antigen and repeated exposure [4]. The acute form develops on exposure to a massive amount of antigens on a single occasion and symptoms appear 4–6 h afterwards. Symptoms include shortness of breath, cough and fever. The subacute form would be added to them progressively as dyspnea, fatigue, anorexia and weight loss. Chronic hypersensitivity pneumonitis is an interstitial lung disease that occurs after continued or repeated exposure to an inhaled antigenic stimulus. It can progress to end-stage fibrosis and shares many clinical and radiological features with idiopathic pulmonary fibrosis and idiopathic nonspecific interstitial pneumonia [3,4]. Our patients, 4 years, had worked in the production of grass broom, at intervals. The fact, her husband was working this job and she's been helping her husband on some days. We believe that, as a result of, with small amounts but intervals of continuing exposure, occurred subacute HP.

Previously described the following significant predictors of HP: exposure to a known offending antigen, positive precipitating antibodies, recent episode of symptoms, inspiratory crackles, symptoms 4–8 h after exposure, and weight loss [5]. However, if HP is highly suspected through a detailed history, usually variable diagnostic tests, imaging methods, even lung biopsy are performed. Histopathological examination of lung tissue are usually not required for HP diagnosis. Transbronchial lung biopsy diagnostic efficiency of the HP is low. The chest radiography/tomography in HP, demonstrate ground-glass opacities and centrilobular nodularity indicate active inflammation. Chronic HP is characterized by reticulation, traction bronchiectasis and, occasionally, honeycombing that can mimic usual interstitial pneumonia [2]. In our case, bilateral and widely ground-glass opacities and nodularity appearance was compatible with HP.

It is important that HP can be distinguished from sarcoidosis and other interstitial lung disease. Bronchoalveolar lavage fluid can be useful in supporting a diagnosis of HP as well as excluding other etiologies such as infection or hemorrhage. Bronchoalveolar lavage

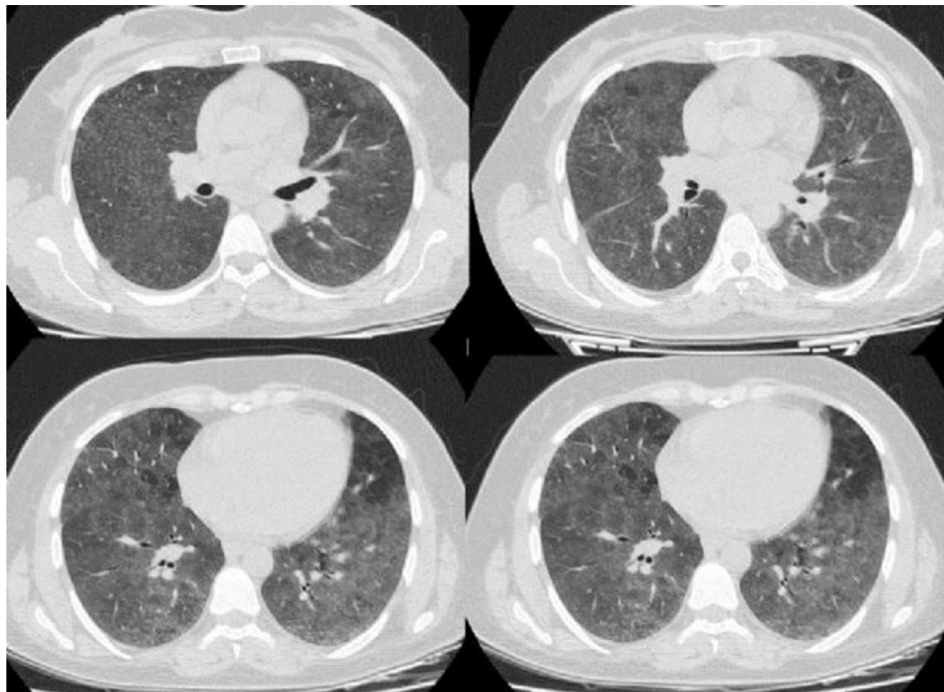


Fig. 2. Thorax BT in patient.

fluid typically shows a threefold to fivefold increase in cell count with an elevated percentage of CD8 lymphocytes, so that the CD4/CD8 ratio is usually less than 1 [2,4]. Unfortunately, bronchoscopy could not be performed in our case because the patient does not accept.

After a correct, early diagnosis and effective avoidance of the causative substances, HP is treated by oral or systemic corticosteroids [3,4]. Also in our case, with steroid therapy was dramatically improvement.

The prognosis in HP depends on a number of factors: duration of exposure, clinic presentation (acute, subacute, or chronic), age, intensity of exposure, histopathologic changes, and lung function abnormality [3]. The recommended and most effective treatment for HP is immediate removal of the causative antigens in the environment [6].

Early diagnosis and effective treatment and removal of the cause is very important because chronic HP, or a diagnosis in its advanced stages, can lead to disability and is associated with increased mortality [3,6]. We would like to emphasize that detailed occupational history should be questioned; because; diagnosis of acute HP,

due to the mixing with the viral infection or atypical pneumonia, easily skipped.

#### Conflict of interest

The authors declare that they have no competing interests.

#### References

- [1] J.M. Campbell, Acute symptoms following work hay, *BMJ* 2 (1932) 1143–1144.
- [2] K. Johannson, C.J. Ryerson, Making an accurate diagnosis of chronic hypersensitivity pneumonitis, *Can. Respir. J.* 21 (6) (2014) 370–372.
- [3] A.M. Patel, J.H. Ryu, C.E. Reed, Hypersensitivity pneumonitis: current concepts and future questions, *J. Allergy Clin. Immunol.* 108 (5) (2001) 661–670.
- [4] L.C. Mohr, Hypersensitivity pneumonitis, *Curr. Opin. Pulm. Med.* 10 (2004) 401–411.
- [5] Y. Lacasse, M. Selman, U. Costabel, J.C. Dalphin, M. Ando, F. Morell, et al., Clinical diagnosis of hypersensitivity pneumonitis, *Am. J. Respir. Crit. Care Med.* 168 (2003) 952–958.
- [6] E.R. Fernandez Perez, J.J. Swigris, A.V. Forssen, et al., Identifying an inciting antigen is associated with improved survival in patients with chronic hypersensitivity pneumonitis, *Chest* 144 (2013) 1644–1651.