

## CASE REPORT

# Potential effects of transdermal nitric oxide donor on fetal growth restriction and oligohydramnios: A case report

Tsuyoshi Murata<sup>1</sup>  | Toma Fukuda<sup>1</sup> | Tetsu Sato<sup>2</sup> | Aya Kanno<sup>1</sup> | Hyo Kyojuka<sup>1</sup> | Shun Yasuda<sup>1</sup> | Akiko Yamaguchi<sup>1</sup> | Shogo Kin<sup>2</sup> | Keiya Fujimori<sup>1</sup>

<sup>1</sup>Department of Obstetrics and Gynecology, Fukushima Medical University School of Medicine, Fukushima, Japan

<sup>2</sup>Department of Obstetrics and Gynecology, Takeda General Hospital, Fukushima, Japan

## Correspondence

Tsuyoshi Murata, Department of Obstetrics and Gynecology, School of Medicine, Fukushima Medical University, 1 Hikarigaoka, Fukushima 960-1295, Japan.  
Email: tuyoshim@fmu.ac.jp

## Abstract

Transdermal nitric oxide donor may be a relatively safe treatment strategy for fetal growth restriction and oligohydramnios due to placental insufficiency.

## KEYWORDS

fetal growth restriction, nitric oxide donor, oligohydramnios

## 1 | INTRODUCTION

There are no recommendations for the specific treatment of placental insufficiency. Here, we report a case of a patient with fetal growth restriction and oligohydramnios that dramatically improved with transdermal nitric oxide donor. Transdermal nitric oxide donor may be a relatively safe strategy for placental insufficiency.

There are various causes of fetal growth restriction (FGR) and oligohydramnios, among which placental insufficiency, a placental disorder, is the major cause.<sup>1,2</sup> However, no specific treatment has been recommended for FGR and oligohydramnios caused by placental insufficiency so far.<sup>3</sup> Here, we present a case of FGR and oligohydramnios that improved dramatically with transdermal isosorbide dinitrate (ISDN) as nitric oxide donor (NOD) in a woman, which lead to the birth of a term appropriate-for-gestational-age infant.

## 2 | CASE HISTORY

A 31-year-old healthy and multiparous woman with a prepregnancy body weight of 38 kg and body mass index (BMI) 16.4 kg/m<sup>2</sup> was referred to the obstetric unit at 20 weeks' gestation due to FGR. She was also diagnosed with oligohydramnios at 19 weeks' gestation. At 20 weeks' gestation, the estimated fetal weight (EFW) was 193 g (−2.2 SD).

During a previous uneventful pregnancy, she gave birth to a term infant weighing 3100 g. She did not smoke or drink alcohol and was not under the influence of any drugs during the current pregnancy. An estimated date of delivery was determined based on crown-rump length during the first trimester. She was normotensive throughout the pregnancy and had no vaginal bleeding or symptoms indicating premature rupture of membranes (PROM). Despite being diagnosed with oligohydramnios before the viable period, she desired to continue the pregnancy.

### 3 | DIFFERENTIAL DIAGNOSIS AND INVESTIGATIONS

Ultrasonography (US) performed at 20 weeks and 5 days of gestation showed an EFW of 256 g ( $-1.8$  SD) and amniotic fluid index (AFI) of 3.7 (Figure 1). The fetus demonstrated active movement and no structural anomalies. Absence of end-diastolic flow in the umbilical artery (UmA) was not detected on color Doppler imaging, and the pulsatility index (PI) and resistance index (RI) of the UmA (1.09 and 0.70, respectively) were within the normal range at that gestational age (Figure 2). The PI of the fetal middle cerebral artery (MCA) and fetal ductus venosus (DV) was also within the normal range.

Speculum vaginal examination of the cervix and vaginal cavity demonstrated no evidence of PROM, as there was no pooling of amniotic fluid, no change in color of bromothymol blue paper, and no signs of ferning. Fetal fibronectin was not detected in the patient's vaginal secretions. Blood tests showed no evidence of maternal infections caused by toxoplasma, rubella, cytomegalovirus, or herpes simplex virus. Finally, the patient did not have anemia or thrombocytopenia and urinary protein was not detected.

Based on these results, we diagnosed the patient with FGR and oligohydramnios possibly caused by placental insufficiency without hypertensive disorders of pregnancy.

### 4 | TREATMENT

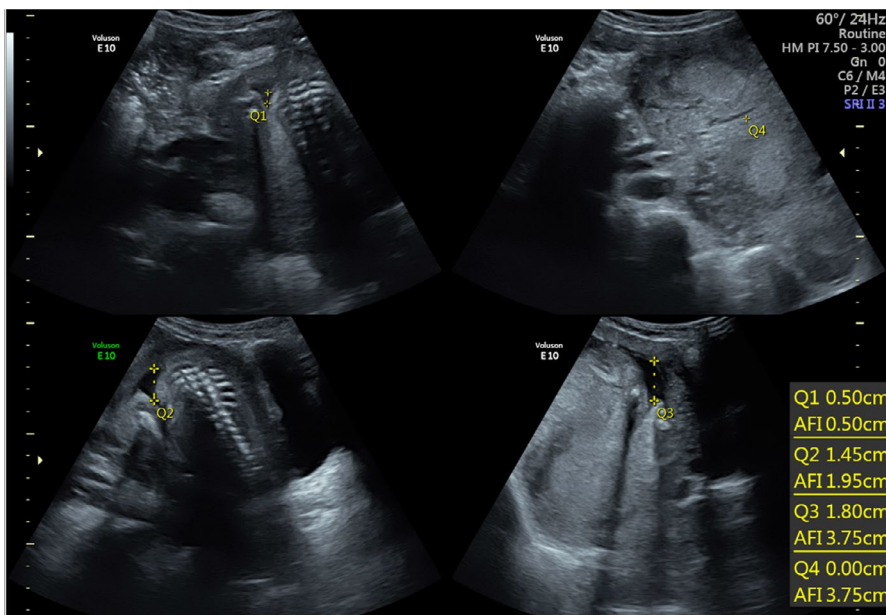
Initially, the patient was prescribed bed rest and hydration for 2 weeks to improve fetal growth and amniotic fluid volume (AFV); however, no significant changes in fetal growth and AFV were detected on US at 22 weeks' gestation.

Next, to improve FGR and oligohydramnios by improving placental perfusion, she was prescribed a daily dose of 40 mg transdermal ISDN (FrandoL tape, Astellas Pharma Inc, Tokyo, Japan). Written informed consent for ISDN was obtained due to the off-label use of the drug. Five days after the start of transdermal ISDN treatment, US demonstrated improvement in EFW (489 g,  $-1.6$  SD) and AFI (9.1; Figure 3). Color Doppler imaging showed slight reduction in PI and RI of the UmA (0.89 and 0.62, respectively) compared to pretreatment measurements (Figure 4). There were no significant changes in PI of the MCA and DV with treatment. Cardiotocography revealed fetal heart rate (FHR) accelerations, moderate FHR variability, and no FHR decelerations (Figure 5).

Transdermal ISDN was used until 36 weeks' gestation. Throughout the pregnancy, her lifestyle included a healthy diet, exercise routine, appropriate quantity of sleep and time spent working, and a gestational weight gain of 9 kg was noted, which was appropriate as per her prepregnancy BMI.

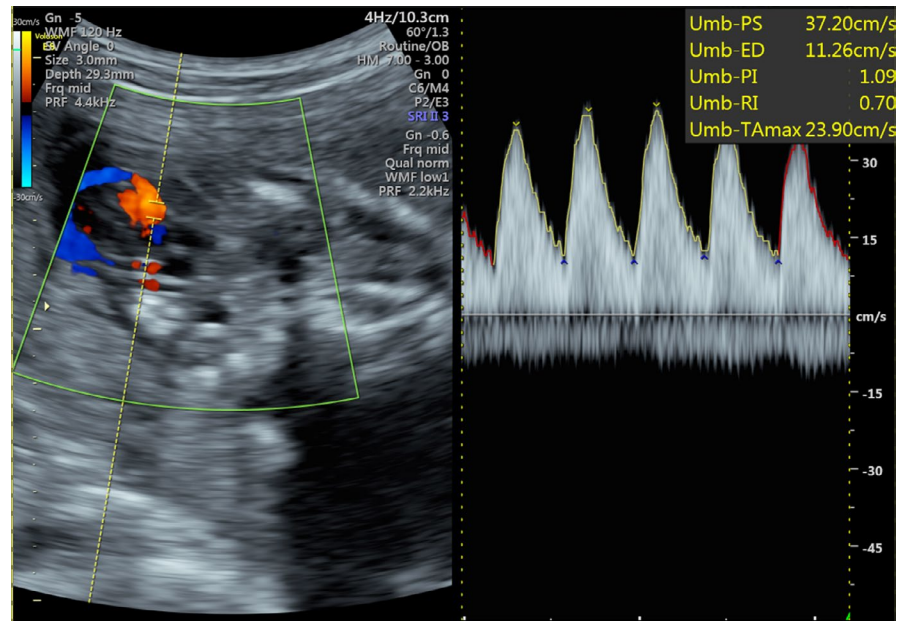
### 5 | OUTCOME AND FOLLOW-UP

The pregnancy developed uneventfully without signs of cervical ripening. During a follow-up, US demonstrated appropriate fetal growth (EFW: approximately  $-1$  SD) and adequate AFV (AFI: ranging from 8 to 12). At 37 weeks' gestation, she showed an AFI of 5, indicating oligohydramnios without PROM. She underwent labor induction using oxytocin at 38 weeks' gestation due to oligohydramnios and delivered a female newborn vaginally. The newborn weighed 2462 g ( $-1.1$  SD) at birth, which was appropriate-for-gestational-age, with a height of 45 cm ( $-1.5$  SD), head circumference of 32.5 cm ( $-0.4$  SD), and Apgar scores of 8 and 9 at 1 and

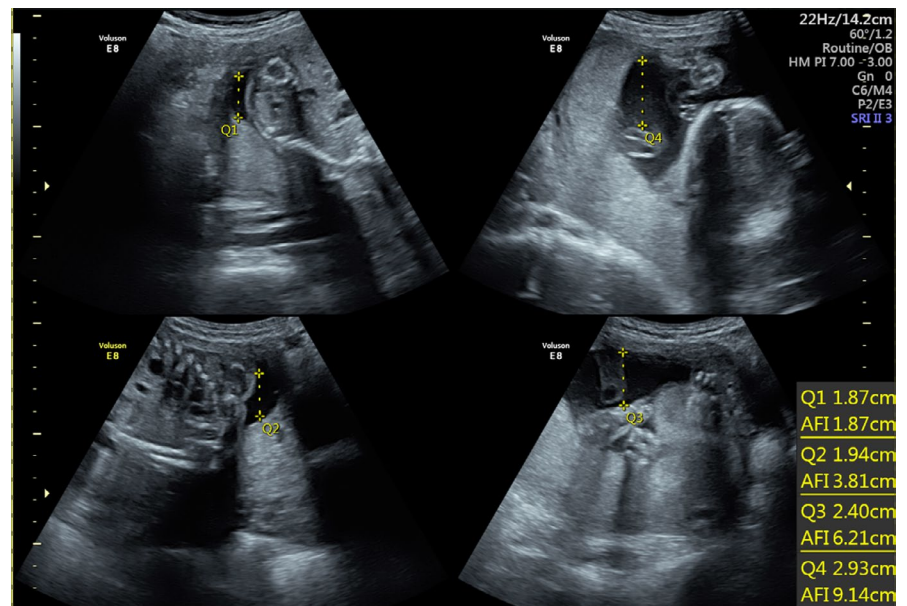


**FIGURE 1** Ultrasonographic assessment of the amniotic fluid index at 20 wk and 5 d of gestation

**FIGURE 2** Color Doppler imaging of the umbilical artery assessing the pulsatility index and resistance index at 20 wk and 5 d of gestation



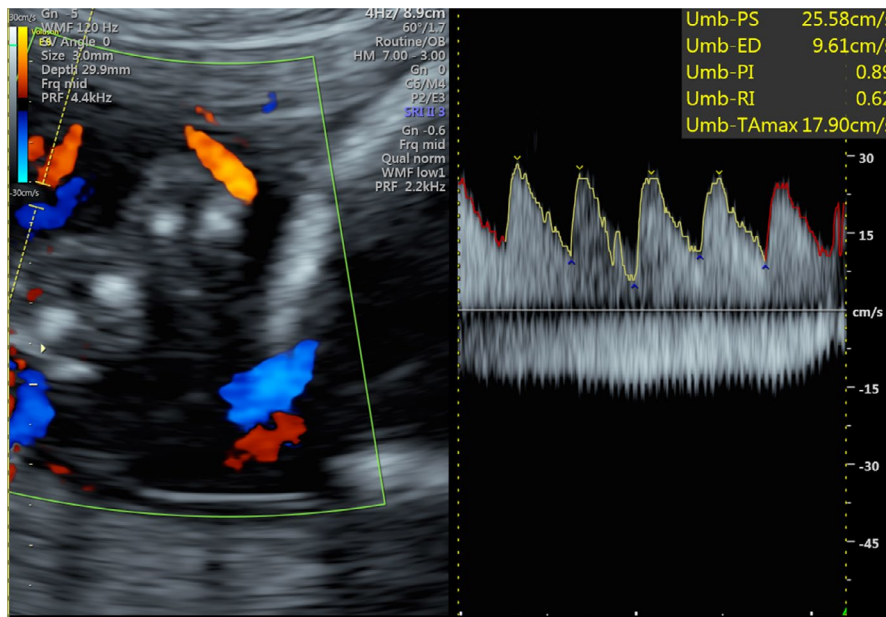
**FIGURE 3** Ultrasonographic assessment of the amniotic fluid index 5 d after the start of transdermal treatment with nitric oxide donor



5 minutes, respectively. The pH, pCO<sub>2</sub>, pO<sub>2</sub>, and base excess of the UmA were 7.332, 47.9 mm Hg, 18.9 mm Hg, and -1.6 mmol, respectively. The newborn exhibited no anomalies. The placenta weighed 377 g. The umbilical cord was 45 cm long with central cord insertion. Examination of the placenta did not reveal a single umbilical artery. Histological findings of the placenta indicated no causes of fetal hypoxia: no cholangiosis, hyperplastic extracellular matrix of chorion, or hyperplastic syncytiums. Therefore, no mechanical abnormality in the placenta was detected as the potential cause of FGR. The maternal and neonatal courses were uneventful, and the mother and her child were discharged 5 days after the delivery.

## 6 | DISCUSSION

In the present case, fetal growth and AFV improved dramatically by transdermal NOD despite lack of improvements after bedrest and hydration for 2 weeks. Approximately 5% of pregnancies are affected by FGR,<sup>4</sup> a condition related to 28%-45% of nonanomalous stillbirths,<sup>5</sup> and increases the risk of neonatal mortality and morbidity.<sup>6</sup> Furthermore, due to development of pulmonary hypoplasia, severe oligohydramnios, defined as the maximum vertical depth of amniotic fluid pocket of <1 cm, is a risk factor for intrauterine fetal death and neonatal mortality.<sup>7</sup> Therefore, transdermal NOD may be a treatment option for placental insufficiency as it improves



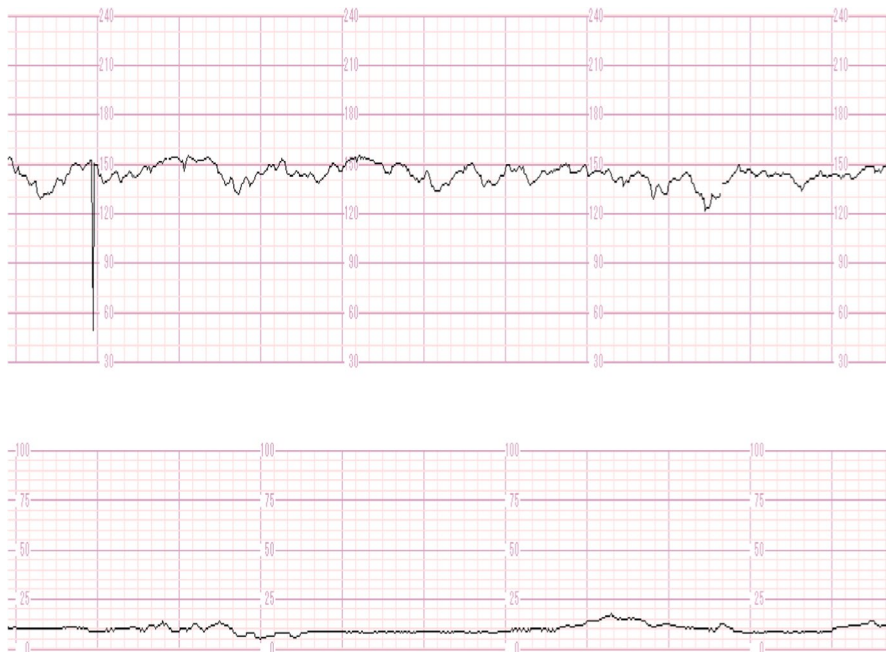
**FIGURE 4** Color Doppler imaging of the umbilical artery assessing the pulsatility index and resistance index 5 d after the start of transdermal treatment with nitric oxide donor

fetoplacental perfusion required for better fetal growth and increases AFV.

Currently, there are no reported randomized control trials (RCT) clarifying the efficacy of long-term usage of transdermal NOD in cases of FGR and oligohydramnios caused by placental insufficiency.<sup>8-10</sup> Nevertheless, in a cohort study of 108 patients with FGR, an oral dose of 3 g/day of L-arginine—an NOD—for 20 days significantly improved fetal growth compared to that in patients without treatment.<sup>11</sup> Furthermore, in a case series including 12 pregnant women with preeclampsia, the AF pocket increased approximately 4-fold with transdermal NOD treatment.<sup>12</sup> The mechanism underlying improvements in uteroplacental perfusion with transdermal NOD is most likely its vasodilating effect via acetylcholine-induced

relaxation.<sup>13</sup> In vascular smooth muscle cells, endothelial nitric oxide and prostaglandin I<sub>2</sub> stimulate cyclic guanosine and cyclic adenosine monophosphate production, resulting in the relaxation of these cells.<sup>14</sup> In the present case, there were no structural or histological abnormalities of the placenta or umbilical cord, which may indicate the functional effects of transdermal NOD on fetoplacental perfusion.

Sildenafil citrate, a phosphodiesterase type 5 inhibitor and a potentiating factor of nitric oxide, may also cause vasodilatation of the uterine vessels and may be a candidate for the treatment of FGR.<sup>15</sup> However, a recent meta-analysis demonstrated that sildenafil was related to increased neonatal birth weight but not to improvement of oligohydramnios.<sup>16</sup> Furthermore, a multicenter, randomized controlled study by the STRIDER



**FIGURE 5** Cardiocotography revealing fetal heart rate accelerations, moderate fetal heart rate variability, and no fetal heart rate decelerations 5 d after the start of transdermal treatment with nitric oxide donor

(Sildenafil therapy in dismal prognosis early-onset intrauterine growth restriction) group revealed that sildenafil did not improve survival or short-term neonatal morbidity in patients with severe early-onset FGR.<sup>17</sup> Thus, the utility of sildenafil in treating FGR and oligohydramnios caused by placental insufficiency remains controversial. A study of each pharmacology may be required to understand the effects of both transdermal NOD and sildenafil on fetoplacental perfusion.

According to numerous cross-sectional studies, fetal Doppler findings are closely related to perinatal risks.<sup>18</sup> However, several studies have demonstrated that transdermal NOD affects uterine vascular impedance without changing UmA and MCA perfusion in women susceptible to preterm labor<sup>19</sup> and preeclampsia.<sup>20,21</sup> Similarly, the present case showed improved fetal growth and AFV with normal PI and RI of UmA.<sup>22</sup> Therefore, the effects of transdermal NOD on fetoplacental perfusion may not be able to be evaluated using US of the UmA and MCA. Furthermore, transdermal NOD may be useful for improving fetoplacental perfusion even in women without abnormal US findings of perfusion. Future studies should clarify the utility of additional measurements to evaluate fetoplacental perfusion and clarify the effects of NOD.

Several points should be clarified before recommending transdermal NOD. First, the effect of NOD on its own to improve fetal growth and AFV has not been demonstrated using the biochemical or biophysical methods evaluated in this case. As previously reported, the combination of NOD and maternal hydration can improve maternal hemodynamic indices.<sup>23</sup> Further studies are required to elucidate the effect of NOD on ameliorating FGR and oligohydramnios. Second, although transdermal NOD is relatively safe for pregnant women,<sup>24</sup> it may cause cervical ripening and maternal hypotension,<sup>9</sup> which may be critical side effects during pregnancy. Therefore, a large-scale RCT is required to clarify the efficacy and safety of transdermal NOD to improve FGR and oligohydramnios caused by placental insufficiency.

In conclusion, transdermal NOD may improve fetal growth and AFV in cases of placental insufficiency in women without abnormal US findings of perfusion.

## ACKNOWLEDGMENTS

Published with written consent of the patient.

## CONFLICT OF INTEREST

None declared.

## AUTHOR CONTRIBUTIONS

TM: acquired and analyzed the data, wrote and critically revised the manuscript, approved the final version of the manuscript, and agreed to be accountable for all aspects of the work and ensure that questions related to the accuracy or integrity of any part of the work are appropriately investigated and resolved. TF: acquired the data, approved the final

version of the manuscript and agreed to be accountable for all aspects of the work and ensure that questions related to the accuracy or integrity of any part of the work are appropriately investigated and resolved. TS: acquired the data, approved the final version of the manuscript and agreed to be accountable for all aspects of the work and ensure that questions related to the accuracy or integrity of any part of the work are appropriately investigated and resolved. AK: acquired the data, approved the final version of the manuscript and agreed to be accountable for all aspects of the work and ensure that questions related to the accuracy or integrity of any part of the work are appropriately investigated and resolved. HK: acquired the data, approved the final version of the manuscript and agreed to be accountable for all aspects of the work and ensure that questions related to the accuracy or integrity of any part of the work are appropriately investigated and resolved. SY: acquired the data, approved the final version of the manuscript and agreed to be accountable for all aspects of the work and ensure that questions related to the accuracy or integrity of any part of the work are appropriately investigated and resolved. AY: acquired the data, approved the final version of the manuscript and agreed to be accountable for all aspects of the work and ensure that questions related to the accuracy or integrity of any part of the work are appropriately investigated and resolved. SK: acquired the data, approved the final version of the manuscript and agreed to be accountable for all aspects of the work and ensure that questions related to the accuracy or integrity of any part of the work are appropriately investigated and resolved. KF: contributed to the interpretation of the results, critically revised the manuscript critically, approved the final version of the manuscript, and agreed to be accountable for all aspects of the work and ensure that questions related to the accuracy or integrity of any part of the work are appropriately investigated and resolved.

## INFORMED CONSENT

Written informed consent for this publication was obtained.

## ORCID

Tsuyoshi Murata  <https://orcid.org/0000-0001-9506-117X>

## REFERENCES

1. Zur RL, Kingdom JC, Parks WT, Hobson SR. The placental basis of fetal growth restriction. *Obstet Gynecol Clin North Am.* 2020;47:81-98.
2. Silver RM. Examining the link between placental pathology, growth restriction, and stillbirth. *Best Pract Res Clin Obstet Gynaecol.* 2018;49:89-102.
3. American College of Obstetricians and Gynecologists. ACOG Practice bulletin no. 134: Fetal Growth Restriction. *Obstet Gynecol.* 2013;121:1122-1133.
4. Bamfo JE, Odibo AO. Diagnosis and management of fetal growth restriction. *J Pregnancy.* 2011;2011:640715.

5. Bettiol A, Lombardi N, Crescioli G, et al. Pharmacological interventions for the prevention of fetal growth restriction: protocol for a systematic review and network meta-analysis. *BMJ Open*. 2019;9:e029467.
6. McIntire DD, Bloom SL, Casey BM, Leveno KJ. Birth weight in relation to morbidity and mortality among newborn infants. *N Engl J Med*. 1999;340:1234-1238.
7. Goto T, Sugiura T, Awaya R, et al. Survival of fetuses with severe oligohydramnios. *Clin Exp Obstet Gynecol*. 2016;43:341-344.
8. Figueroa R, Maulik D. Prenatal therapy for fetal growth restriction. *Clin Obstet Gynecol*. 2006;49:308-319.
9. de Pace V, Chiossi G, Facchinetti F. Clinical use of nitric oxide donors and L-arginine in obstetrics. *J Matern Fetal Neonatal Med*. 2007;20:569-579.
10. Groom KM, David AL. The role of aspirin, heparin, and other interventions in the prevention and treatment of fetal growth restriction. *Am J Obstet Gynecol*. 2018;218:S829-S840.
11. Sieroszewski P, Suzin J, Karowicz-Bilińska A. Ultrasound evaluation of intrauterine growth restriction therapy by a nitric oxide donor (L-arginine). *J Matern Fetal Neonatal Med*. 2004;15:363-366.
12. Nakatsuka M, Takata M, Tada K, et al. A long-term transdermal nitric oxide donor improves uteroplacental circulation in women with preeclampsia. *J Ultrasound Med*. 2002;21:831-836.
13. Dalle Lucca JJ, Adeagbo AS, Alsip NL. Oestrous cycle and pregnancy alter the reactivity of the rat uterine vasculature. *Hum Reprod*. 2000;15:2496-2503.
14. Mombouli JV, Vanhoutte PM. Endothelial dysfunction: from physiology to therapy. *J Mol Cell Cardiol*. 1999;31:61-74.
15. Lin CS, Lin G, Xin ZC, Lue TF. Expression, distribution and regulation of phosphodiesterase 5. *Curr Pharm Des*. 2006;12:3439-3457.
16. Ferreira RDD, Negrini R, Bernardo WM, Simões R, Piato S. The effects of sildenafil in maternal and fetal outcomes in pregnancy: A systematic review and meta-analysis. *PLoS One*. 2019;14:e0219732.
17. Sharp A, Cornforth C, Jackson R, et al. Maternal sildenafil for severe fetal growth restriction (STRIDER): a multicentre, randomised, placebo-controlled, double-blind trial. *Lancet Child Adolesc Health*. 2018;2:93-102.
18. Baschat AA. Doppler application in the delivery timing of the preterm growth-restricted fetus: another step in the right direction. *Ultrasound Obstet Gynecol*. 2004;23:111-118.
19. Kähler C, Schleussner E, Möller A, Seewald HJ. Nitric oxide donors: effects on fetoplacental blood flow. *Eur J Obstet Gynecol Reprod Biol*. 2004;115:10-14.
20. Cacciatore B, Halmesmäki E, Kaaja R, Teramo K, Ylikorkala O. Effects of transdermal nitroglycerin on impedance to flow in the uterine, umbilical, and fetal middle cerebral arteries in pregnancies complicated by preeclampsia and intrauterine growth retardation. *Am J Obstet Gynecol*. 1998;179:140-145.
21. Trapani A Jr, Gonçalves LF, Pires MM. Transdermal nitroglycerin in patients with severe pre-eclampsia with placental insufficiency: effect on uterine, umbilical and fetal middle cerebral artery resistance indices. *Ultrasound Obstet Gynecol*. 2011;38:389-394.
22. Drukker L, Staines-Urias E, Villar J, et al. International gestational age-specific centiles for umbilical artery Doppler indices: a longitudinal prospective cohort study of the INTERGROWTH-21st Project. *Am J Obstet Gynecol*. 2020;222:602.e1-602.e15.
23. Tiralongo GM, Pisani I, Vasapollo B, Khalil A, Thilaganathan B, Valensise H. Effect of a nitric oxide donor on maternal hemodynamics in fetal growth restriction. *Ultrasound Obstet Gynecol*. 2018;51:514-518.
24. Lees C, Campbell S, Jauniaux E, et al. Arrest of preterm labour and prolongation of gestation with glyceryl trinitrate, a nitric oxide donor. *Lancet*. 1994;343:1325-1326.

**How to cite this article:** Murata T, Fukuda T, Sato T, et al. Potential effects of transdermal nitric oxide donor on fetal growth restriction and oligohydramnios: A case report. *Clin Case Rep*. 2020;8:3287–3292. <https://doi.org/10.1002/ccr3.3410>