

Natasha Klimas, Josephine Quintanilla-Dieck, and Travis Vandergriff

Abstract

Erythema multiforme in its most extreme form has traditionally been divided between toxic epidermal necrolysis and Stevens-Johnson Syndrome. These two life-threatening skin diseases are now considered part of the same spectrum of disease. They can be differentiated by clinical and histological criteria. We can also now predict which patients are apt to have the most guarded prognosis. Treatment by multiple agents is imperfect, but offers a better chance of a good outcome than ever before.

Keywords

Immune memory • Histocompatibility complex • Apoptosis • “Target” lesions • “Wet paper” appearance • Asboe-Hanson sign • IVIG • Plasmapheresis

N. Klimas, BS
Department of Dermatology, University of Texas
Southwestern Medical Center, Dallas, TX, USA
e-mail: nkklimas@gmail.com

J. Quintanilla-Dieck, MD
Department of Dermatology, University of Texas
Southwestern Medical Center, Dallas, TX, USA
e-mail: mariaqd@gmail.com

T. Vandergriff, MD (✉)
Dermatology and Pathology, UT Southwestern
Medical Center, 5323 Harry Hines Blvd,
Dallas, TX 75390, USA
e-mail: travis.vandergriff@utsouthwestern.edu

Introduction

Stevens–Johnson syndrome (SJS) and toxic epidermal necrolysis (TEN) are acute, life-threatening mucocutaneous reactions characterized by epidermal necrosis and detachment of differing severity, which are drug-induced in most cases. SJS is defined by <10 % body surface area (BSA) of involvement, SJS–TEN overlap by 10–30 %, and TEN by >30 %.

Epidemiology

TEN and SJS are rare disorders, with an incidence of 0.4–1.2 per million person-years for TEN and 1.2–6.0 per million person-years for SJS. Both

reactions are more common with increasing age. TEN and SJS occur more frequently in females, with a female-to-male ratio of 1.5–1.

Immunocompromise predisposes individuals to SJS and TEN. Patients with AIDS are at a 1,000-fold increased risk for TEN compared to the general population. Those with connective tissue diseases and malignancies are also more susceptible to SJS and TEN. Ninety-five percent of SJS/TEN cases are associated with medication use. Risk is highest during the initial 1–3 week(s) of therapy, but extends into the 8 week following drug exposure. In rare cases, SJS/TEN may also be induced by measles-mumps-rubella vaccination and microbial pathogens such as *Mycoplasma pneumonia*, dengue virus, and cytomegalovirus (CMV).

More than 100 drugs have been linked with SJS/TEN in the adult population. However, the following “high risk” medications trigger most cases: antimicrobial sulfonamides, sulfasalazine, allopurinol, nevirapine, lamotrigine, carbamazepine, phenytoin, phenobarbital, non-steroidal anti-inflammatory agents (NSAIDs), aminopenicillins, cephalosporins, and quinolones. Recently, Sassolas et al. published an algorithm for assessment of drug causality in SJS/TEN (ALDEN), which provides a structured scoring system to help identify the causative drug (please refer to Suggested Readings list for details).

Mortality rates in SJS/TEN vary widely and are contingent on multiple factors, particularly BSA of detachment and patient age. Average mortality rates in SJS are estimated at 1–5 %, and in TEN they are 25–35 %. Survival analysis conducted among SJS/TEN patients has shown that mortality risk extends far beyond the acute phase of illness, with a mortality rate of 23 % at 6 weeks and 34 % at 1 year. Factors that increase mortality risk include severe liver or kidney disorders, recent infection, and malignancy.

Pathophysiology

The mechanisms responsible for SJS/TEN development are incompletely understood. However, drug hypersensitivity is widely accepted as the *sine qua non* of SJS/TEN pathogenesis. T-cell

mediated hypersensitivity triggering SJS/TEN is thought to result from an impaired capacity to detoxify reactive intermediate drug metabolites; altered drug metabolism may be attributable to both genetic and acquired causes. Antigens yielded by the reaction of metabolites with host tissues then initiate the pathogenic immune response.

Further corroborating evidence favoring an immune-mediated diathesis in SJS/TEN is provided by the timeline of development: a 1- to 3-week interval of sensitization between the onset of drug therapy and disease manifestation is typical. Immune memory is also implicated by the rapid recrudescence of SJS/TEN following drug re-challenge.

In the early phases of cutaneous lesions, cytotoxic CD8+ T cells expressing cutaneous lymphocyte-associated antigen (CLA) involved with skin-homing predominate, implicating major histocompatibility complex (MHC) class-I restricted antigen presentation and subsequent clonal expansion. Natural killer T-cells (NKT) and monocytes/macrophages are also recruited. T-cells isolated from SJS/TEN blisters have drug-specific cytotoxicity targeted to keratinocytes and B-lymphocytes.

Cytotoxicity in SJS/TEN is thought to be multifactorial, with contributions by both the Fas-Fas ligand (FasL) pathway and granulysin. Granzyme B, as well as Interleukin (IL)-6, TNF- α , interferon- γ , and IL-18 are also found within blister fluid and/or lesional epidermis. The effects of these cytokines likely gives rise to the constitutional symptoms of epidermal necrolysis. In addition, the actions of these cytokines provide a molecular basis for discrepancy between the fulminant epidermal denudation and the incongruously scant inflammatory infiltrates of SJS/TEN lesions.

Cell-mediated cytotoxicity precipitates widespread apoptosis, a characteristic feature of the initial phase of SJS/TEN, the consequence of which is the classical “necrolysis” observed histologically. As SJS/TEN progresses, the burden of apoptotic cells overcomes the capacity of phagocytes for elimination and within hours, the apoptotic cells release their intracellular contents,

triggering inflammation. Dissolution of intracellular and basement membrane adhesions occurs and epidermal viability is lost, generating the histologic picture of epidermal necrolysis.

Apoptosis in SJS/TEN is thought to be initiated by the binding of specific ligands to cell surface death receptors. In this process, the Fas (CD95, Apo-1)/ FasL (CD95L) receptor-ligand pair plays a prominent role. Following ligation, intracellular signaling machinery, namely FADD and pro-caspase-8, is activated. In turn, this generates apoptosis through autoactivation of the protease caspase-8 and activation of additional caspases responsible for cellular dissolution (caspases-3, -6, -7). Blood levels of soluble FasL are increased in patients with TEN, and blood levels correlate with BSA of involvement.

Compelling evidence also supports a prominent role in SJS/TEN induction by granulysin, a cytolytic product of NK cells and cytotoxic T-lymphocytes. In the murine model, intradermal injection of granulysin results in features mimicking SJS/TEN. Further, gene expression profiling of blister fluid demonstrates granulysin expression is two to four times greater than other cytotoxic proteins including perforin, granzyme B or soluble FasL. Depleting granulysin diminishes cytotoxicity.

Strong associations exist between certain MHC allotypes and epidermal necrolysis; thus, genetic susceptibility is also thought to play a pivotal role. This feature is demonstrated by the increased incidence of TEN development among human leukocyte antigen (HLA)-B12 in individuals. In addition, the HLA-B12 haplotype is linked with heightened risk of ocular complications. Among the Han Chinese, Thai, Malaysian, and South Indian populations, HLA-B*1502 correlates with increased risk for SJS/TEN induced by aromatic antiepileptic agents such as carbamazepine, oxcarbazepine, lamotrigine, and phenytoin. In the above populations, as well as Europeans, HLA-B*5801 incurs increased risk for allopurinol-induced epidermal necrolysis. Among Europeans, HLA-B*5701 correlates with abacavir-induced hypersensitivity reactions and HLA-A*3101 with carbamazepine-induced hypersensitivity.

Clinical Presentation

It is important to note that although they share many clinical features and were previously thought to lie on a nosographic continuum of severity, erythema multiforme (EM) is currently considered a distinct clinical entity from SJS and TEN. EM is a self-limited disorder. With only minor epidermal denudation, often 1–2 % BSA involvement (<10 %), EM preferentially involves the distal extremities in a symmetric distribution. EM exhibits characteristic “target” lesions with three zones: (1) an outer erythematous zone; (2) an edematous paler zone; and (3) a dark, dusky center. “Atypical” target lesions feature ill-defined margins and/or two zones in contrast to the three of classical targets. Mucosal involvement is minimal in the EM minor and occurs in 5–60 % of EM major patients. In contrast, mucosal involvement is seen in 92–100 % of SJS and nearly 100 % of TEN patients. Moreover, EM confers minimal to no systemic symptoms. Differentiation of EM from SJS and TEN is based predominately on clinical features, particularly lesion distribution and the presence of classical target lesions. Classical target lesions must be present for a diagnosis of EM, whereas the diagnoses of SJS/TEN are to be considered for atypical targets. Histological features of EM resemble those of SJS/TEN and are therefore of limited discriminative utility.

Clinical Manifestations

Prodromal symptoms of SJS and TEN precede cutaneous manifestations by 1–3 days and include eye stinging, odynophagia, and fever. The trunk, often the pre-sternal region, is frequently the initial site of cutaneous involvement (Fig. 24.1). Lesions then spread to the face, neck, hands, feet, and proximal upper extremities. Relative sparing of the distal upper and lower extremities is typical.

Early cutaneous findings generally include irregularly shaped, erythematous, dusky red or purpuric macules that are typically tender. These lesions have the tendency to rapidly coalesce with

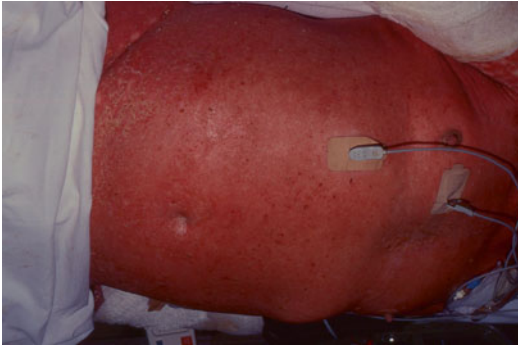


Fig. 24.1 Dusky red discoloration with trunkal involvement that is often seen early in TEN. Early desquamation is starting over lower abdominal panniculus. Reaction was to Bactrim

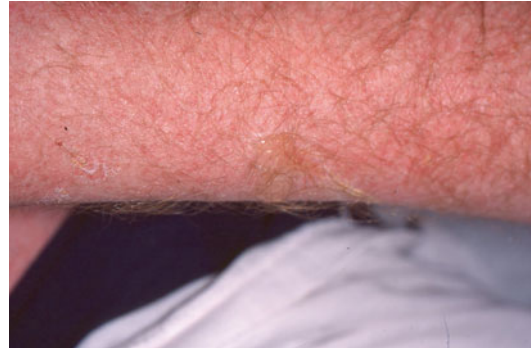

Fig. 24.2 Diffuse erythema over forearm with fragile blisters. The blisters on the left are already broken and the “wet cigarette paper” is on the lower border of arm just to the left of center

disease progression. In some cases, early lesions may be slightly infiltrated. Atypical targets with dark centers are also often seen. At this point in the evolution of SJS or TEN, lesions may mimic more benign drug-related disorders including exanthematous drug eruptions or EM major.

With progression toward full-thickness necrosis, the erythematous macules assume a grey hue over the next hours to days. Application of tangential mechanical pressure to erythematous zones in this phase may produce detachment of the epidermis from the dermis, referred to as a positive Nikolsky sign. This phenomenon is not specific to SJS/TEN, however, as it is also observed in those with autoimmune bullous diseases. At this time, the skin demonstrates a “wet cigarette paper” appearance (Fig. 24.2). Friction or pressure easily detaches the epidermis, exposing an erythematous, often bleeding or “scalded” dermis. In this second phase, large tracts of epidermal denudation develop. With epidermal cleavage, blisters arise as fluid fills the space between the dermis and epidermis. These flaccid, easily-ruptured blisters may be extended laterally by pressure of the thumb, a feature known as a positive Asboe-Hansen sign. Tense vesicles or bullae may occasionally be observed, typically only in the palmar or plantar regions as the thicker epidermal layer of these surfaces more readily resists pressure.

Epidermal cleavage progresses for 5–7 days. Thereafter, a plateau phase of re-epithelialization begins. Re-epithelialization is generally com-

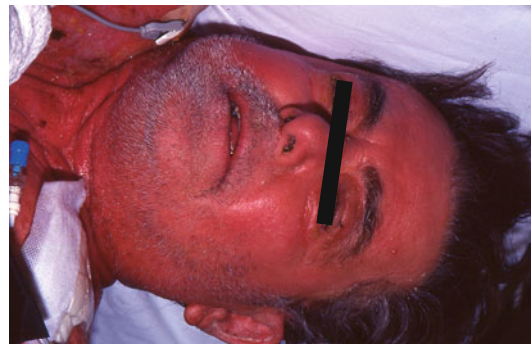

Fig. 24.3 Diffuse erythema with swelling of eyelids, especially on the patient’s left side. There is some early conjunctivitis of right eye. This was due to sulfa antibiotic

plete within 3 weeks. Healing is slower in areas of maceration, pressure, or infection. Skin grafting is not required, as keratinocytes are recruited from reservoirs such as follicles and healthy perilesional epidermis and proliferate.

Mucosal involvement presents as erythema and exquisitely painful erosions of the genital, buccal, and ocular mucosa. At least two mucosal surfaces are generally affected. Mucosal/ocular manifestations typically precede or occur simultaneously with cutaneous signs.

Ocular involvement is present in 50–78 % of cases and may include photophobia, discharge, crusting, eyelid edema (Fig. 24.3), and conjunctivitis, as well as conjunctival membrane or pseudo-membrane formation. Eyelash shedding may also be observed. Oral involvement occurs in 71–100 %

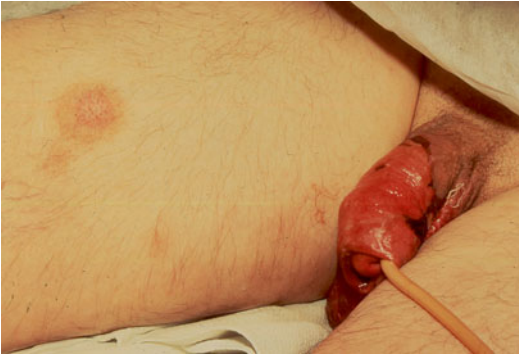

Fig. 24.4 TEN of the genitalia with dramatic stripping of epidermis of the glans and shaft of the penis. The base of the penis shows epidermal denuding, indicating a positive Nikolsky's sign. A urinary catheter has been inserted due to severe dysuria and urinary retention

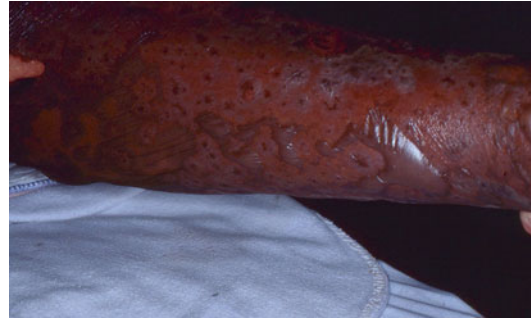

Fig. 24.5 Flaccid bullae and erosive papules over the forearm of a patient with TEN. The skin is being wiped away with a finger over the elbow, showing a positive Nikolsky's sign. The danger of not stopping the offending antibiotic early was the probable cause of end-stage pulmonary disease and death. The patient failed on high-dose intravenous corticosteroids, plasmaphoresis, and intensive topical therapy

of cases. The vermilion border of the lips and oral cavity frequently feature grey-white pseudomembranes and crusts overlying hemorrhagic erosions. Genital involvement (Fig. 24.4), often with associated dysuria, presents in 40–63 %, and may be complicated by dyspareunia, synechia formation, and urethral or anal strictures in rare cases.

Though epidermal necrolysis has been described as “acute skin failure,” multiple internal organ systems are also involved. Pulmonary complications (Fig. 24.5) include bronchiolitis obliterans, subcutaneous emphysema, and acute respiratory distress syndrome (ARDS). Renal involvement can lead to microalbuminuria or overt proteinuria, hematuria, azotemia, and acute renal failure secondary to glomerular and/or renal tubular damage. Gastrointestinal dysfunction secondary to epithelial sloughing may include esophagitis, severe abdominal pain and diarrhea, malabsorption, melena, and even hepatitis or colonic perforation. Anemia and leukopenia are common. Myocarditis and encephalopathy have also been documented.

The most frequent complication of the acute phase of SJS/TEN is sepsis. Compromised epithelial barrier function predisposes patients to infections, which represent the most common cause of mortality. *Pseudomonas* and *Staphylococcus aureus* are the most frequently identified pathogens. However, enterobacteriaceae are isolated

from one-third of positive blood cultures implicating gastrointestinal translocation with mucosal involvement. Multisystem organ failure ensues in roughly one-third of cases.

Sequelae

After resolution of the acute phase, epidermal necrolysis behaves as a chronic disease; long-term complications are more common and severe than previously thought.

Sequelae of imperfect healing are frequent in SJS and TEN. Cutaneous dyschromia and nail dystrophy occur in 62.5 % and 37.5 % of patients, respectively. Diffuse hair loss may also be seen.

Ocular involvement can be severe and blinding. Surprisingly, the diagnosis of TEN does not predict more severe ocular involvement or more frequent late ophthalmological sequelae compared to SJS. Among those with ocular involvement, complications include severe dry eyes in nearly half of cases, trichiasis in 16 %, symblepharon in 14 %, entropion in 5 %, corneal ulceration in 2 %, and visual loss in 5 %.

Oral sequelae include xerostomia, increased salivary acidity, and periodontal disease, as well as gingival inflammation and synechia.

Genital involvement may be complicated by dyspareunia with vaginal itching, dryness, and

Table 24.1 Differential diagnosis

Diagnosis	Distinguishing features
Acute generalized exanthematous pustulosis (AGEP)	Superficial (subcorneal) pustules on an erythematous base Shorter interval between drug exposure and reaction onset
Drug-induced linear IgA bullous dermatosis (LABD)	Tense blisters predominate New blisters arise at margins of erythematous annular lesions (“string of pearls” sign)
Erythema multiforme (EM)	Typical target lesions Extremity predominance Less severe mucosal involvement
Exanthematous (morbilliform) drug eruption	Lacks mucosal involvement Less prominent skin pain
Generalized bullous fixed drug eruption (GBFDE)	More well-defined lesion borders Less prominent mucosal involvement Rapid resolution in 7 – 14 days
Graft-versus-host disease (GVHD)	Post-transplant setting
Kawasaki disease	Differences in mucosal/ocular manifestations
Paraneoplastic pemphigus	Neoplastic association Chronic course
Phototoxic eruption	Photodistribution Recent sun exposure Phototoxic medication exposure
Staphylococcal scalded skin syndrome (SSSS)	Lacks mucosal involvement

bleeding. In males, phimosis may be seen. In rare cases, synechiae and urethral or anal strictures requiring surgical intervention may form.

The differential diagnosis of SJS/TEN includes acute generalized exanthematous pustulosis (AGEP), EM, generalized bullous fixed drug eruption (GBFDE), and staphylococcal scalded skin syndrome (SSSS). These and other diagnoses to be considered in the appropriate clinical setting are detailed in Table 24.1 along with some of their distinguishing clinical features.

Diagnostic Findings

Histopathology

Scattered apoptotic keratinocytes are seen in the basal and immediate suprabasal epidermal layers in the initial phase of SJS or TEN. These findings serve as a microscopic correlate of the clinical grey or dusky coloration, which signals incipient epidermal necrosis and cleavage.

Biopsy of later stage lesions reveals confluent epidermal necrosis, often with underlying subepidermal blisters. In such specimens, sparse perivascular infiltrates with lymphocytic predominance are observed. Cytological analysis demonstrates macrophages and lymphocytes in the epidermis, the majority of which are CD8+. Conversely, lymphocytes located in the papillary dermis are chiefly CD4+.

Laboratory Studies

In general, blood tests are of limited diagnostic utility but aid in management, prognostication, and early identification of complications. Laboratory studies reveal anemia in nearly all cases. Leukopenia, particularly lymphopenia, is likewise common and found in roughly 90 % of cases. Neutropenia portends a poor prognosis, and eosinophilia is typically not observed. In nearly one-third of patients, mild elevation of liver enzymes occurs. Urinalysis reveals proteinuria in half of cases.

Prognosis

The validated SCORTEN scoring system may be employed to assess disease severity and prognosis, as well as guide clinical decision-making. One point is assigned for each of the seven following criteria: (1) age >40 years; (2) comorbid malignancy; (3) tachycardia >120 beats per minute (bpm); (4) initial BSA of detachment >10 %; (5) blood urea nitrogen >28 mg/dL; (6) glucose >252 mg/dL; and (7) bicarbonate

>20 mEq/L. Mortality escalates from 3 % for a patient with 0 or 1 point to 35 % for a patient with 3 points. Predicted mortality for those with ≥ 5 points approaches 90 %. For optimal predictive value, scoring must be repeated on day 3 post-admission.

Treatment

Optimal medical management of SJS and TEN demands prompt recognition and diagnosis as well as immediate withdrawal of the causative drug(s). Even after adjustment for confounders such as patient age, BSA of involvement, and immune status, earlier discontinuation of the culprit medication correlates with a better prognosis. All nonlife-sustaining drugs should be withdrawn in cases where the offending agent is unknown, particularly those administered within 8 weeks of SJS/TEN onset.

Supportive care in the appropriate clinical setting and specific therapy where indicated are also cornerstones of management.

Management in nonspecialized wards is appropriate only for patients with limited cutaneous involvement without rapid progression and a SCORTEN score of 0 or 1. Transfer to burn centers or intensive care units is warranted for patients with a SCORTEN score of 3 or above, as these individuals require therapy that may exhaust the capabilities of general wards. Mortality is reduced with early transfer to a burn unit; such facilities are particularly well-equipped and trained in the care of patients with epidermal loss.

Debridement of blisters is not recommended, and burn centers should be reminded of this by their dermatology referral.

Supportive Care

Supportive care centers on maintaining hemodynamic stability and prompt diagnosis and intervention for life-threatening sequelae. Goals of management essentially parallel those of extensive burns.

Erosions yield sizeable insensible fluid losses and associated hypovolemia and electrolyte abnormalities, thus fluid resuscitation should be rapidly initiated and titrated as necessary. As epidermal cleavage in SJS/TEN usually affects the trunk, sites of central line placement are often involved. Consequently, these sites are predisposed to infection. For this reason, peripheral venous access is preferred.

Ideally, ambient temperatures should be elevated at 82.4–86 °F, or 28–30 °C. Use of aluminum survival sheets and a controlled pressure thermo-regulated bed is preferable to a traditional bed and sheets.

Aseptic precautions are critical given the significant risk of infection, and surveillance for infection should be vigilant in SJS/TEN. Blood, skin, and urine cultures should be obtained at frequent intervals. Though routine antimicrobial prophylaxis is not recommended, antimicrobial therapy should be initiated promptly when infection is suspected.

Daily wound care with enhanced focus on the face, eyes, nose, mouth, ears, interdigital spaces, axillary folds, and anogenital region, optimally with the assistance of a dermatologist (burn unit patients are frequently not seen by a dermatologist but it is recommended), is essential. Topical emollients such as petrolatum should be applied to detached sites, particularly sites under pressure. Isotonic sterile sodium chloride solution may be used to cleanse serous or serosanguinous crusts on the face. Silicone dressings may also be applied to areas of detachment. Silicone dressings may be left in place until re-epithelialization is complete, however, sterile sodium chloride should be used to cleanse the exposed surfaces of these dressings daily. Non-adherent layered dressings such as Exu-Dry™ may also be utilized. Care for areas near orifices such as the mouth, nose, or ears may include topical antibiotic application. Intact regions should remain dry. Movement may precipitate detachment, thus patient manipulation should be minimized. Debridement of the necrotic epidermis is not recommended.

Patients should undergo daily eye exams by an ophthalmologist. Eyelid cleansing with

sterile sodium chloride solution is recommended daily. Antibiotic or antiseptic eye drops to minimize corneal colonization by bacteria, as well as preservative-free ocular emollients and Vitamin A are often administered. Evolving synechiae should be mechanically disrupted. In the acute phase, transplantation of cryopreserved amniotic membrane suppresses inflammation, promotes epithelial healing, and may preclude the development of blinding cicatricial sequelae. Daily cleansing of the nostrils with isotonic sterile sodium chloride solution applied with a sterile cotton swab is advised. Subsequently, a topical antibiotic such as mupirocin should be applied.

Isotonic sterile sodium chloride solution should be used to rinse the mouth several times daily. Provided the areas are not macerated, sterile sodium chloride solution should also be applied to the interdigital spaces and anogenital region daily. If these areas are macerated, 0.5 % silver nitrate solution is suggested.

Other recommended measures include anticoagulation for venous thromboembolism prophylaxis, early initiation of alimentary support, optimally via nasogastric tube, to promote healing of the gastrointestinal tract and reduce the risk of bacterial translocation, and pain management.

Specific Therapy

Various anti-inflammatory and/or immunomodulatory therapies have been employed in light of the pathophysiological basis for TEN and SJS. However, rarity of the two conditions constrains performance of randomized controlled trials. For this reason, the majority of evidence supporting specific SJS or TEN therapies originates from small, uncontrolled trials and series or case reports. Thus no specific interventions have demonstrated compelling proof of efficacy requisite for wide implementation. Overall, the management of severe SJS echoes that of TEN, although individuals with attenuated forms of SJS without rapid progression may require only supportive therapies.

Corticosteroids

Systemic corticosteroids have anchored SJS/TEN management for decades; however use of these agents remains controversial. When administered early in the evolution of SJS/TEN, particularly via pulsed intravenous dosing, corticosteroids may reduce mortality without lengthening healing time. However, results of other studies suggest corticosteroid therapy may actually increase mortality and the incidence of adverse events, specifically sepsis. Therefore corticosteroids are no longer recommended as a mainstay of therapy.

Intravenous Immunoglobulin

Commercial preparations of Intravenous Immunoglobulin (IVIG) include antibodies targeted to Fas which abrogate ligation of FasL, impeding keratinocyte cell death *in vitro*. However, translation of this finding from the bench to the bedside has yielded conflicting results. Several independent studies have demonstrated improved mortality among patients with TEN managed with IVIG. With total IVIG doses of 2.7, 4, and 3.4 g/kg, survival rates were 88 %, 94 %, and 100 %, respectively. In contrast, other studies comparing total IVIG doses of 1.6 or 2.8 g/kg IVIG to supportive therapy alone report no appreciable mortality benefit. In another trial, 2 g/kg of total IVIG revealed no measurable effect on disease progression or rate of re-epithelialization, and no improvement in mortality predicted by SCORTEN. A larger, retrospective analysis conducted in the RegiSCAR cohort confirmed this lack of survival benefit, albeit at a lower IVIG dose. It has been suggested that optimal therapeutic efficacy may not be achieved by total doses of less than 2 g/kg; this may partially account for the discordant results of these trials.

Inconsistent study designs and patient-related variables in studies complicate critical evaluation of IVIG's efficacy. Moreover, the benefit of supportive therapies may confound observations. Accordingly, high doses of IVIG (e.g., 3 mg/kg total administered at 1 mg/kg per day) appear to be a safe, reasonable treatment option. Further

trials must be conducted to better characterize the efficacy of IVIG in epidermal necrolysis.

Plasmapheresis

Plasmapheresis, or plasma exchange, has been performed in SJS/TEN with the objective of rapid removal of the offending drug or its metabolites and pro-inflammatory substances, particularly cytokines. Clinical improvement has been demonstrated in a number of studies evaluating the utility of plasmapheresis. In one cohort refractory to systemic corticosteroids and/or IVIG, plasma exchange halted disease progression with re-epithelialization demonstrated in all four patients. Additional studies are warranted to confirm these promising early results of plasma exchange in epidermal necrolysis.

Cyclophosphamide

The effect of cyclophosphamide (100–300 mg/day), on the course of epidermal necrolysis has been assessed in small case series. Trials of solitary cyclophosphamide therapy as well as combination therapy with cyclosporine and corticosteroids suggest a beneficial impact. However, larger trials are necessary to corroborate these findings.

Cyclosporine

Cyclosporine, a calcineurin inhibitor and T-cell antagonist, has demonstrated favorable effects in several recent trials at doses of 3–4 mg/kg/day. In one recent study conducted among 29 patients, cyclosporine resulted in cessation of disease progression. No increase in infection was found, and cyclosporine was well-tolerated. In this trial and a subsequent independent study, cyclosporine conferred 100 % survival.

Anti-TNF, G-CSF, and NAC

Antibodies directed toward tumor necrosis factor (TNF) have been used with favorable results. However, one prior randomized, blinded, controlled trial assessing the effect of thalidomide, an anti-TNF agent, was terminated due to excess mortality in the thalidomide group. In contrast, subsequent case reports have demonstrated

successful outcomes of TNF blockade in the form of infliximab and etanercept. At any rate, anti-TNF therapy must be used with supreme caution. In patients with TEN and neutropenia, granulocyte colony-stimulating factor (G-CSF) has significantly accelerated re-epithelialization. Several reports have also demonstrated beneficial therapeutic effects of N-acetylcysteine (NAC) administration. Again, additional trials will be required to validate the outcomes of these interventions.

Management of Sequelae

Given the protean nature of SJS/TEN complications, an interdisciplinary approach to care is imperative. Observation of vigilant sun protection practices is critical in the management of the cutaneous dyspigmentation which complicates epidermal necrolysis. Providers must also be alert in the prevention and treatment of ocular complications, with early referral to an ophthalmologist. As vaginal synechiae may not be appreciable until months after epidermal necrolysis onset, early, regular pelvic examination is recommended for female patients. In males, genitourinary manifestations such as penile and urethral erosions and phimosis warrant close urology follow-up. Special attention and prompt referral to specialists is also required for oral, gastrointestinal, and pulmonary involvement.

Conclusions

Moving forward, HLA haplotyping prior to the administration of drugs is likely to be a useful tool for primary prevention of epidermal necrolysis. This principle is illustrated by the FDA-issued recommendation of testing patients with “Asian ancestry” for HLA-B*1502 prior to initiating carbamazepine therapy.

Detailed drug histories identify the offending agent in only 70 % of patients. In cases where the identity of the culprit agent remains in doubt, *ex vivo/in vitro* testing, particularly via the lymphocyte transformation test (LTT)

may be helpful. This test quantifies T-cell proliferation in the presence of suspect drugs. However, this assay is limited by low sensitivity, thus the development of novel methods of culprit drug identification is key.

Suggested Reading

- Arevalo JM, Lorente JA, Gonzalez-Herrada C, Jimenez-Reyes J. Treatment of toxic epidermal necrolysis with cyclosporin A. *J Trauma*. 2000;48(3):473–8.
- Bachot N, Revuz J, Roujeau JC. Intravenous immunoglobulin treatment for Stevens-Johnson syndrome and toxic epidermal necrolysis: a prospective noncomparative study showing no benefit on mortality or progression. *Arch Dermatol*. 2003;139(1):33–6.
- Bastuji-Garin S, Fouchard N, Bertocchi M, Roujeau JC, Revuz J, Wolkenstein P. SCORTEN: a severity-of-illness score for toxic epidermal necrolysis. *J Invest Dermatol*. 2000;115(2):149–53.
- Bolognia JL, Jorizzo JL, Rapini RP. *Dermatology*. Philadelphia: Mosby Elsevier; 2008.
- Brown KM, Silver GM, Halerz M, Walaszek P, Sandroni A, Gamelli RL. Toxic epidermal necrolysis: does immunoglobulin make a difference? *J Burn Care Rehabil*. 2004;25(1):81–8.
- Cartotto R, Mayich M, Nickerson D, Gomez M. SCORTEN accurately predicts mortality among toxic epidermal necrolysis patients treated in a burn center. *J Burn Care Res*. 2008;29(1):141–6.
- Chan HL, Stern RS, Arndt KA, Langlois J, Jick SS, Jick H, et al. The incidence of erythema multiforme, Stevens-Johnson syndrome, and toxic epidermal necrolysis. A population-based study with particular reference to reactions caused by drugs among outpatients. *Arch Dermatol*. 1990;126(1):43–7.
- Chung WH, Hung SI, Yang JY, Su SC, Huang SP, Wei CY, et al. Granulysin is a key mediator for disseminated keratinocyte death in Stevens-Johnson syndrome and toxic epidermal necrolysis. *Nat Med*. 2008;14(12):1343–50.
- Correia O, Delgado L, Ramos JP, Resende C, Torrinha JA. Cutaneous T-cell recruitment in toxic epidermal necrolysis. Further evidence of CD8+ lymphocyte involvement. *Arch Dermatol*. 1993;129(4):466–8.
- de Prost N, Ingen-Housz-Oro S, Duong T, Valeyrie-Allanore L, Legrand P, Wolkenstein P, et al. Bacteremia in Stevens-Johnson syndrome and toxic epidermal necrolysis: epidemiology, risk factors, and predictive value of skin cultures. *Medicine (Baltimore)*. 2010;89(1):28–36.
- de Sica-Chapman A, Williams G, Soni N, Bunker CB. Granulocyte colony-stimulating factor in toxic epidermal necrolysis (TEN) and Chelsea & Westminster TEN management protocol [corrected]. *Br J Dermatol*. 2010;162(4):860–5.
- Endorf FW, Cancio LC, Gibran NS. Toxic epidermal necrolysis clinical guidelines. *J Burn Care Res*. 2008;29(5):706–12.
- Garcia-Doval I, LeCleach L, Bocquet H, Otero XL, Roujeau JC. Toxic epidermal necrolysis and Stevens-Johnson syndrome: does early withdrawal of causative drugs decrease the risk of death? *Arch Dermatol*. 2000;136(3):323–7.
- Goldsmith L, Katz S, Gilchrist B, Paller A, Leffell D, Wolff K. *Fitzpatrick's dermatology in general medicine*. 8th ed. New York: McGraw-Hill; 2012.
- Goulden V, Goodfield MJ. Recombinant granulocyte colony-stimulating factor in the management of toxic epidermal necrolysis. *Br J Dermatol*. 1996;135(2):305–6.
- Harr T, French LE. Stevens-Johnson syndrome and toxic epidermal necrolysis. *Chem Immunol Allergy*. 2012;97:149–66.
- Hetherington S, Hughes AR, Mosteller M, Shortino D, Baker KL, Spreen W, et al. Genetic variations in HLA-B region and hypersensitivity reactions to abacavir. *Lancet*. 2002;359(9312):1121–2.
- Kardaun SH, Jonkman MF. Dexamethasone pulse therapy for Stevens-Johnson syndrome/toxic epidermal necrolysis. *Acta Derm Venereol*. 2007;87(2):144–8.
- Lissia M, Mulas P, Bulla A, Rubino C. Toxic epidermal necrolysis (Lyell's disease). *Burns*. 2010;36(2):152–63.
- Magina S, Lisboa C, Leal V, Palmares J, Mesquita-Guimaraes J. Dermatological and ophthalmological sequels in toxic epidermal necrolysis. *Dermatology (Basel, Switzerland)*. 2003;207(1):33–6.
- McCormack M, Alfirevic A, Bourgeois S, Farrell JJ, Kasperaviciute D, Carrington M, et al. HLA-A*3101 and carbamazepine-induced hypersensitivity reactions in Europeans. *N Engl J Med*. 2011;364(12):1134–43.
- Meneux E, Wolkenstein P, Haddad B, Roujeau JC, Revuz J, Paniel BJ. Vulvovaginal involvement in toxic epidermal necrolysis: a retrospective study of 40 cases. *Obstet Gynecol*. 1998;91(2):283–7.
- Mockenhaupt M, Viboud C, Dunant A, Naldi L, Halevy S, Bouwes Bavinck JN, et al. Stevens-Johnson syndrome and toxic epidermal necrolysis: assessment of medication risks with emphasis on recently marketed drugs. The EuroSCAR-study. *J Invest Dermatol*. 2008;128(1):35–44.
- Ngan V, Oakley A, Dyall-Smith D. Stevens Johnson syndrome & toxic epidermal necrolysis. 2009. <http://dermnetnz.org/reactions/sjs-ten.html>. Accessed 5 May 2014.
- Palmieri TL, Greenhalgh DG, Saffle JR, Spence RJ, Peck MD, Jeng JC, et al. A multicenter review of toxic epidermal necrolysis treated in U.S. burn centers at the end of the twentieth century. *J Burn Care Rehabil*. 2002;23(2):87–96.
- Pereira FA, Mudgil AV, Rosmarin DM. Toxic epidermal necrolysis. *J Am Acad Dermatol*. 2007;56(2):181–200.
- Roujeau JC, Stern RS. Severe adverse cutaneous reactions to drugs. *N Engl J Med*. 1994;331(19):1272–85.
- Roujeau JC, Huynh TN, Bracq C, Guillaume JC, Revuz J, Touraine R. Genetic susceptibility to toxic epidermal necrolysis. *Arch Dermatol*. 1987;123(9):1171–3.
- Roujeau JC, Guillaume JC, Fabre JP, Penso D, Flechet ML, Girre JP. Toxic epidermal necrolysis (Lyell syndrome). Incidence and drug etiology in France, 1981–1985. *Arch Dermatol*. 1990;126(1):37–42.

- Roujeau JC, Kelly JP, Naldi L, Rzany B, Stern RS, Anderson T, et al. Medication use and the risk of Stevens-Johnson syndrome or toxic epidermal necrolysis. *N Engl J Med*. 1995;333(24):1600–7.
- Rzany B, Mockenhaupt M, Stocker U, Hamouda O, Schopf E. Incidence of Stevens-Johnson syndrome and toxic epidermal necrolysis in patients with the acquired immunodeficiency syndrome in Germany. *Arch Dermatol*. 1993;129(8):1059.
- Rzany B, Mockenhaupt M, Baur S, Schroder W, Stocker U, Mueller J, et al. Epidemiology of erythema exsudativum multiforme majus, Stevens-Johnson syndrome, and toxic epidermal necrolysis in Germany (1990–1992): structure and results of a population-based registry. *J Clin Epidemiol*. 1996;49(7):769–73.
- Sassolas B, Haddad C, Mockenhaupt M, Dunant A, Liss Y, Bork K, et al. ALDEN, an algorithm for assessment of drug causality in Stevens-Johnson Syndrome and toxic epidermal necrolysis: comparison with case-control analysis. *Clin Pharmacol Ther*. 2010;88(1):60–8.
- Schneck J, Fagot J-P, Sekula P, Sassolas B, Roujeau JC, Mockenhaupt M. Effects of treatments on the mortality of Stevens-Johnson syndrome and toxic epidermal necrolysis: A retrospective study on patients included in the prospective EuroSCAR Study. *J Am Acad Dermatol*. 2008;58(1):33–40.
- Schwartz RA, McDonough PH, Lee BW. Toxic epidermal necrolysis: part I. Introduction, history, classification, clinical features, systemic manifestations, etiology, and immunopathogenesis. *J Am Acad Dermatol*. 2013a;69(2):173 e1–13; quiz 85–6.
- Schwartz RA, McDonough PH, Lee BW. Toxic epidermal necrolysis: part II. Prognosis, sequelae, diagnosis, differential diagnosis, prevention, and treatment. *J Am Acad Dermatol*. 2013b;69(2):187 e1–16; quiz 203–4.
- Shortt R, Gomez M, Mittman N, Cartotto R. Intravenous immunoglobulin does not improve outcome in toxic epidermal necrolysis. *J Burn Care Rehabil*. 2004;25(3):246–55.
- Valeyrie-Allanore L, Wolkenstein P, Brochard L, Ortonne N, Maitre B, Revuz J, et al. Open trial of ciclosporin treatment for Stevens-Johnson syndrome and toxic epidermal necrolysis. *Br J Dermatol*. 2010;163(4):847–53.
- Yip LW, Thong BY, Lim J, Tan AW, Wong HB, Handa S, et al. Ocular manifestations and complications of Stevens-Johnson syndrome and toxic epidermal necrolysis: an Asian series. *Allergy*. 2007;62(5):527–31.