

## Sternal Osteomyelitis by *Gordonia Bronchialis* in an Immunocompetent Patient after Open Heart Surgery

### Abstract

*Gordonia* is a catalase-positive, aerobic, nocardioform, Gram-positive staining actinomycete that also shows weak acid-fast staining. Several *Gordonia* species are commonly found in the soil. The bacterium has been isolated from the saliva of domesticated/wild dogs as well. In hospitalized patients, most commonly it is found in the setting of intravascular catheter-related infections. However, recent reports show that it is being increasingly isolated from sternal wounds, skin/neoplastic specimens and from pleural effusions. *Gordonia* shares many common characteristics with *Rhodococcus* and *Nocardia*. Ergo, it is commonly misrecognized as *Nocardia* or *Rhodococcus*. Since this pathogen requires comprehensive morphological and biochemical testing, it is often difficult and cumbersome to isolate the species. Broad-range Polymerase Chain Reaction (PCR) and sequencing with genes like 16S rRNA or hsp65 are used to correctly identify the species. Identification is essential for choosing and narrowing the right antimicrobial agent. Herein, we report our experience with a patient who presented with sternal osteomyelitis after infection with this elusive bug.

**Keywords:** *Gordonia bronchialis*, infection, sternal osteomyelitis

*“All things are hidden, obscure and debatable if the cause of the phenomena is unknown, but everything is clear if its cause be known.”*

-Louis Pasteur in *The Germ Theory and Its Application to Medicine and Surgery*

### Introduction

*Gordonia* is a catalase-positive, aerobic, nocardioform, Gram positive staining actinomycete that also shows weak acid-fast staining.<sup>[1]</sup> Several *Gordonia* species are commonly found in the soil.<sup>[2]</sup> The bacterium has been isolated from the saliva of domesticated/wild dogs as well.<sup>[3]</sup> In hospitalized patients, it is most commonly found in the setting of intravascular catheter-related infections. However, recent reports have shown that it has recently been isolated from sternal wounds,<sup>[4]</sup> skin/neoplastic specimens, and from pleural effusions.<sup>[5]</sup> *Gordonia* shares many common characteristics with *Rhodococcus* and *Nocardia*. Therefore, it is commonly misrecognized as *Nocardia* or *Rhodococcus*. Because *Gordonia* requires comprehensive morphological and biochemical testing, it is often difficult and cumbersome to isolate

This is an open access journal, and articles are distributed under the terms of the Creative Commons Attribution-NonCommercial-ShareAlike 4.0 License, which allows others to remix, tweak, and build upon the work non-commercially, as long as appropriate credit is given and the new creations are licensed under the identical terms.

For reprints contact: reprints@medknow.com

the species. It has an incubation period of a minimum of 4 days.<sup>[6]</sup> Broad-range polymerase chain reaction (PCR) and sequencing, with genes like 16S rRNA or hsp65, are used to correctly identify the species.<sup>[7]</sup> Here, we report a patient who presented with sternal osteomyelitis after infection with this elusive bug.

### Case Description

A 74-year-old male patient with past medical history of essential hypertension, benign prostatic hyperplasia, asthma, and coronary artery disease presented with sternal chest pain. Upon examination, he was found to have wound dehiscence and sternal abscess. Patient had undergone a coronary artery bypass grafting (CABG) procedure 3 months back for his CAD. He underwent sternal debridement and removal of one sternal wire 1 month after the CABG. He endorsed minimal drainage from the sternal wound site. No associated fever, chills, nausea, vomiting, or shortness of breath were noted. Computed tomography (CT) scan of the chest showed persistent gas at the median sternotomy site with osseous destruction likely secondary to chronic osteomyelitis with abscess [Figure 1]. Post debridement, specimen was initially identified as a

**How to cite this article:** Ambesh P, Kapoor A, Kazmi DH, Elsheshtawy M, Shetty V, Lin YS, *et al.* Sternal osteomyelitis by *Gordonia bronchialis* in an immunocompetent patient after open heart surgery. *Ann Card Anaesth* 2019;22:221-4.

**Paurush Ambesh,  
Aditya Kapoor<sup>1</sup>,  
Danish H Kazmi<sup>2</sup>,  
Moustafa  
Elsheshtawy<sup>3</sup>,  
Vijay Shetty<sup>3</sup>,  
Yu S Lin<sup>4</sup>,  
Stephan Kamholz**

*Departments of Internal Medicine, <sup>3</sup>Cardiology and <sup>4</sup>Infectious Disease, Maimonides Medical Center, New York City, USA, <sup>1</sup>Department of Cardiology, Sanjay Gandhi Post Graduate Institute of Medical Sciences, <sup>2</sup>Department of Cardiology, Era Medical Institute, Lucknow, India*

### Address for correspondence:

*Dr. Paurush Ambesh,  
Department of Internal  
Medicine,  
Maimonides Medical Center,  
New York City - 11219,  
USA.  
E-mail: paurush17@gmail.com*

### Access this article online

**Website:** www.annals.in

**DOI:** 10.4103/aca.ACA\_125\_18

### Quick Response Code:



*Corynebacterium*; the patient received broad coverage with IV vancomycin and meropenem. The sternal abscess was drained by surgery and deep tissue cultures were sent for special microbiological testing.

**Discussion**

We isolated *G. bronchialis* from sternal deep tissue wound cultures of a patient who had undergone CABG 3 months back. *G. bronchialis* was the only microorganism cultured from the patient, and the patient was the only one with

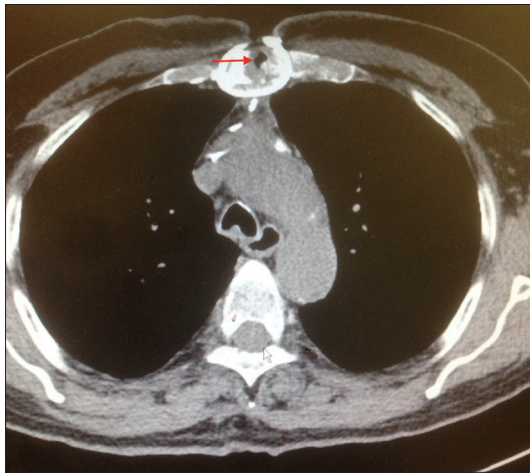


Figure 1: Computed tomography of the chest shows osteomyelitis of the sternum (red arrow)

*G. bronchialis* infection in the hospital at the time. More than one specimen grew the same organism. Therefore, we can safely conclude that it was a true pathogen.

*Gordonia* (previously known as *Gordona*) genus was first isolated from other aerobic actinomycetes in 1971.<sup>[8]</sup> Because awareness about *Gordonia* is slowly increasing, it now comprises a significant minority of aerobic actinomycetes found in humans. One study reported that of 171 aerobic actinomycete isolates sent to the National Institutes of Health from 1996 to 2003, approximately 56% were *Nocardia* spp., 12% *Mycobacteria* spp., 11% *Streptomyces* spp., 8% *Rhodococcus* spp., 6% *Gordonia* spp., 0.6% *Tsukamurella* spp., and 0.6% *Corynebacterium* spp.<sup>[9]</sup>

Since 1971, 29 different *Gordonia* species have been isolated. Though the literature is scarce, there are few published reports of ventriculitis with an underlying ventricular shunt,<sup>[10]</sup> otitis externa and bronchitis,<sup>[11]</sup> arthritis associated with a biological absorbable bone/joint screw,<sup>[12]</sup> breast abscess,<sup>[13,14]</sup> keratitis/conjunctivitis,<sup>[15]</sup> skin and soft tissue infections,<sup>[16,17]</sup> and endocarditis from underlying central venous catheter.<sup>[18,19]</sup> A Spanish hospital published a report on *Gordonia* induced skin abscess, due to needle injection.<sup>[20]</sup> Two cases of peritoneal dialysis-related peritonitis by *Gordonia* have also been reported.<sup>[21,22]</sup>

In our review of the literature, we found only 6 reported cases of *G. bronchialis* sternal infection in humans over

**Table 1: Reported cases of sternal infection by *Gordonia***

Number of cases	Age	Sex	Year	Procedure	Immunity status	Therapy	Treatment duration	Method of identification	Reference
1	64	Female	2016	Mitral valve replacement	Normal	Clindamycin and ceftazidime	8 weeks	16 sRNA sequencing	28
3	47-68	Male/Female	2014	CABG	Normal	Wound debridement and negative pressure wound therapy	Unknown	NA	25
1	69	Female	2014	CABG	Diabetes Mellitus	Vancomycin and Cefotetan; imipenem	8 weeks	16sRNA sequencing	26
1	76	Female	2013	CABG	Normal	Ceftriaxone and ciprofloxacin; wound debridement and VAC	Unknown	16sRNA sequencing	27
3 (Cluster)	56-80	Male	2012	CABG	Diabetes Mellitus (2 cases), Normal (1 case)	Imipenem, moxifloxacin, linezolid and minocycline; wound debridement	60 days (mean), 120 days respectively	16sRNA sequencing	4
7 (cluster)	51-68	Male	1991	CABG	Diabetes mellitus (1 case), Steroid use (1 case), Obesity (3 cases), Prostate cancer (1 case), chronic lung disease (2 cases)	Ciprofloxacin, Cotrimoxazole, Ceftriaxone and Ciprofloxacin	74 days, 122 days, 38 days, 108 days respectively.	Conventional biochemical test	3

the past 26 years [Table 1]. Most of the reported sternal wound infections were due to outbreak in the hospital due to intraoperative transmission from a health care worker. A cluster of 7 cases after coronary artery bypass surgery were traced back to the dog of an operating room nurse. Ciprofloxacin, ceftriaxone, and cotrimoxazole were used as therapy.<sup>[3]</sup> One patient developed wound dehiscence post sternal closure following mitral valve replacement surgery. Samples from the wound site grew *G bronchialis*; clindamycin and ceftazidime were given.<sup>[23]</sup> A cluster of three cases developed sternal osteomyelitis following CABG; they were treated by wound debridement and negative pressure.<sup>[24]</sup> Another case after CABG was treated with vancomycin and cefotetan.<sup>[25]</sup> Similarly ceftriaxone and ciprofloxacin were used in 2013 following CABG.<sup>[26]</sup>

### Salient points of this report

- The importance of correctly identifying *Gordonia* infection cannot be stressed enough. The most common confounding pathogen in making the correct diagnosis, is the coryneform Gram-positive rod<sup>[10]</sup>
- Currently 16S rDNA or hsp65 gene sequencing is used to identify *G. bronchialis* at the species level. Mass spectrometry using matrix-assisted laser desorption ionization-time of flight mass spectrometry allows rapid identification of aerobic actinomycetes from cultured colonies. However, the isolate yielded log score between <2 and ≥1.7 cannot be used to identify at the species level
- No conclusive evidence-based treatment guidelines exist for *G. bronchialis* infection. Minocycline and ciprofloxacin were used in one report.<sup>[27]</sup> In another case, carbapenem or fluoroquinolone in combination with an aminoglycoside was used.<sup>[27]</sup> Trimethoprim-sulfamethoxazole has been reported to have poor efficacy against *Gordonia* species<sup>[28]</sup>
- With the advent of 16S rRNA gene sequencing and matrix-assisted laser desorption ionization-time of flight mass spectrometry (MALDI-TOF MS), *Gordonia* isolation is becoming more common. In the past, *G. bronchialis* infection has been underdiagnosed due to laboratory and technical limitations
- This case report adds to the accumulating evidence for identifying and treating this rare Gram-positive bacterium and urges physicians to be mindful of its idiosyncrasy to cause sternal infections.

### Declaration of patient consent

The authors certify that they have obtained all appropriate patient consent forms. In the form the patient(s) has/have given his/her/their consent for his/her/their images and other clinical information to be reported in the journal. The patients understand that their names and initials will not be published and due efforts will be made to conceal their identity, but anonymity cannot be guaranteed.

### Financial support and sponsorship

Nil.

### Conflicts of interest

There are no conflicts of interest.

### References

1. Arenskötter M, Bröker D, Steinbüchel A. Biology of the metabolically diverse genus *Gordonia*. *Appl Environ Microbiol* 2004;70:3195-204.
2. Shen FT, Goodfellow M, Jones AL, Chen YP, Arun AB, Lai WA, et al. *Gordonia soli* sp. nov., a novel actinomycete isolated from soil. *Int J Syst Evol Microbiol* 2006;56:2597-601.
3. Richet HM, Craven PC, Brown JM, Lasker BA, Cox CD, McNeil MM, et al. A cluster of *Rhodococcus* (*Gordonia*) *bronchialis* sternal-wound infections after coronary-artery bypass surgery. *N Engl J Med* 1991;324:104-9.
4. Wright SN, Gerry JS, Busowski MT, Klochko AY, McNulty SG, Brown SA, et al. *Gordonia bronchialis* sternal wound infection in 3 patients following open heart surgery: Intraoperative transmission from a healthcare worker. *Infect Control Hosp Epidemiol* 2012;33:1238-41.
5. Johnson JA, Onderdonk AB, Cosimi LA, Yawetz S, Lasker BA, Bolcen SJ, et al. *Gordonia bronchialis* bacteremia and pleural infection: Case report and review of the literature. *J Clin Microbiol* 2011;49:1662-6.
6. Drancourt M, Pelletier J, Cherif AA, Raoult D. *Gordonia terrae* central nervous system infection in an immunocompetent patient. *J Clin Microbiol* 1997;35:379-82.
7. Gil-Sande E, Brun-Otero M, Campo-Cerecedo F, Esteban E, Aguilar L, Garcia-de-Lomas J. Etiological misidentification by routine biochemical tests of bacteremia caused by *Gordonia terrae* infection in the course of an episode of acute cholecystitis. *J Clin Microbiol* 2006;44:2645-7.
8. Tsukamura M. Proposal of a new genus, *Gordonia*, for slightly acid-fast organisms occurring in sputa of patients with pulmonary disease and in soil. *J Gen Microbiol* 1971;68:15-26.
9. Poonwan N, Mekha N, Yazawa K, Thunyaharn S, Yamanaka A, Mikami Y. Characterization of clinical isolates of pathogenic *Nocardia* strains and related actinomycetes in Thailand from 1996 to 2003. *Mycopathologia* 2005;159:361-8.
10. Blaschke AJ, Bender J, Byington CL, Korgenski K, Daly J, Petti CA, et al. *Gordonia* species: Emerging pathogens in pediatric patients that are identified by 16S ribosomal RNA gene sequencing. *Clin Infect Dis* 2007;45:483-6.
11. Iida S, Taniguchi H, Kageyama A, Yazawa K, Chibana H, Murata S, et al. *Gordonia otitidis* sp. nov., isolated from a patient with external otitis. *Int J Syst Evol Microbiol* 2005;55:1871-6.
12. Jannat-Khah DP, Halsey ES, Lasker BA, Steigerwalt AG, Hinrikson HP, Brown JM. *Gordonia aarii* infection associated with an orthopedic device and review of the literature on medical device-associated *Gordonia* infections. *J Clin Microbiol* 2009;47:499-502.
13. Werno AM, Anderson TP, Chambers ST, Laird HM, Murdoch DR. Recurrent breast abscess caused by *Gordonia bronchialis* in an immunocompetent patient. *J Clin Microbiol* 2005;43:3009-10.
14. Zardawi IM, Jones F, Clark DA, Holland J. *Gordonia terrae*-induced suppurative granulomatous mastitis following nipple piercing. *Pathology* 2004;36:275-8.
15. Kempf VAJ, Schmalzing M, Yassin AF, Schaal KP, Baumeister D, Arenskötter M, et al. *Gordonia polyisoprenivorans* septicemia in a bone marrow transplant patient. *Eur J Clin Microbiol Infect Dis* 2004;23:226-8.
16. Bakker XR, Spauwen PH, Dolmans WM. Mycetoma of the hand caused by *Gordonia terrae*: A case report. *J Hand Surg Br* 2004;29:188-90.
17. Lai CC, Wang CY, Liu CY, Tan CK, Lin SH, Liao CH, et al. Infections caused by *Gordonia* species at a medical center in Taiwan, 1997 to 2008. *Clin Microbiol Infect* 2010;16:1448-53.

18. Lesens O, Hansmann Y, Riegel P, Heller R, Benaissa-Djellouli M, Martinot M, *et al.* Bacteremia and endocarditis caused by a *Gordonia* species in a patient with a central venous catheter. *Emerg Infect Dis* 2000;6:382-5.
19. Verma P, Brown JM, Nunez VH, Morey RE, Steigerwalt AG, Pellegrini GJ, *et al.* Native valve endocarditis due to *Gordonia polyisoprenivorans*: Case report and review of literature of bloodstream infections caused by *Gordonia* species. *J Clin Microbiol* 2006;44:1905-8.
20. Bartolomé-Álvarez J, Sáez-Nieto JA, Escudero-Jiménez A, Barba-Rodríguez N, Galán-Ros J, Carrasco G, *et al.* Cutaneous abscess due to *Gordonia bronchialis*: Case report and literature review. *Rev Esp Quimioter* 2016;29:170-3.
21. Lam JY, Wu AK, Leung WS, Cheung I, Tsang CC, Chen JH, *et al.* *Gordonia* species as emerging causes of continuous-ambulatory-peritoneal-dialysis-related peritonitis identified by 16S rRNA and *secA1* gene sequencing and matrix-assisted laser desorption ionization-time of flight mass spectrometry (MALDI-TOF MS). *J Clin Microbiol* 2015;53:671-6.
22. Ma TK, Chow KM, Kwan BC, Lee KP, Leung CB, Li PK, *et al.* Peritoneal-dialysis related peritonitis caused by *Gordonia* species: Report of four cases and literature review. *Nephrology* 2014;19:379-83.
23. Rodríguez-Lozano J, Pérez-Llantada E, Agüero J, Rodríguez-Fernández A, Ruiz de Alegria C, Martínez-Martínez L, *et al.* Sternal wound infection caused by *Gordonia bronchialis*: Identification by MALDI-TOF MS. *JMM Case Rep* 2016;3:e005067.
24. Nguyen DB, Gupta N, Aboud-Daoud A, KleKamp BG, Rhone C, Winston T, *et al.* A polymicrobial outbreak of surgical site infections following cardiac surgery at a community hospital in Florida, 2011-2012. *Am J Infect Control* 2014;42:432-5.
25. Chang JH, Ji M, Hong HL, Choi SH, Kim YS, Chung CH, *et al.* Sternal osteomyelitis caused by *Gordonia bronchialis* after open-heart surgery. *Infect Chemother* 2014;46:110-4.
26. Vasquez MA, Marne C, Villuendas MC, Arazo P. Subacute sternal osteomyelitis caused by *Gordonia bronchialis* after open-heart surgery. *Enferm Infecc Microbiol Clin* 2013;31:559-60.
27. Johnson JA, Onderdonk AB, Cosimi LA, Yawetz S, Lasker BA, Bolcen SJ, *et al.* *Gordonia bronchialis* bacteremia and pleural infection: Case report and review of the literature. *J Clin Microbiol* 2011;49:1662-6.
28. Moser BD, Pellegrini GJ, Lasker BA, Brown JM. Pattern of antimicrobial susceptibility obtained from blood isolates of a rare but emerging human pathogen, *Gordonia polyisoprenivorans*. *Antimicrob Agents Chemother* 2012;56:4991-3.