



Review

Safety of active auditory implants in magnetic resonance imaging

Guy Fierens^{a, b, c, 1, 2, *}, Nina Standaert^{d, 1, 2}, Ronald Peeters^e, Christ Glorieux^a, Nicolas Verhaert^{c, d}^a Laboratory of Soft Matter and Biophysics, Department of Physics and Astronomy, KU Leuven, Celestijnenlaan 200D, B-3001, Heverlee, Belgium^b Cochlear Technology Centre, Schaliënhoedreef 20I, B-2800, Mechelen, Belgium^c KU Leuven, Department of Neurosciences, Research Group Experimental Otorhinolaryngology, Herestraat 49, B-3000, Leuven, Belgium^d University Hospitals Leuven, Department of Otorhinolaryngology, Herestraat 49, B-3000, Leuven, Belgium^e University Hospitals Leuven, Department of Radiology, Herestraat 49, B-3000, Leuven, Belgium

ARTICLE INFO

Article history:

Received 16 October 2020

Received in revised form

19 November 2020

Accepted 17 December 2020

Keywords:

MRI Safety
Active hearing implant
Adverse events
Systematic review
Cochlear implant
Radiology

ABSTRACT

Magnetic resonance imaging (MRI) has become the gold standard for the diagnosis of many pathologies. Using MRI in patients with auditory implants can however raise concerns due to mutual interactions between the implant and imaging device, resulting in potential patient risks. Several implant manufacturers have been working towards more MRI safe devices. Older devices are however often labelled for more stringent conditions, possibly creating confusion with patients and professionals. With this myriad of different devices that are implanted in patients for lifetimes of at least 20 years, it is crucial that both patients and professionals have a clear understanding of the safety of their devices. This work aims at providing an exhaustive overview on the MRI safety of active auditory implants.

The available industry standards that are followed by manufacturers are outlined and an overview of the latest scientific developments focusing on the last five years is provided. In addition, based on the analysis of the adverse events reported to the Food and Drug Administration (FDA) and in literature within the past ten years, a systematic review of the most commonly occurring issues for patients with auditory implants in the MRI environment is provided.

Results indicate that despite the release of more MRI conditional active hearing implants on the market, adverse events still occur. An extensive overview is provided on the MRI safety of active auditory implants, aiming to increase the understanding of the topic for healthcare professionals and contribute to safer scanning conditions for patients.

© 2020 PLA General Hospital Department of Otolaryngology Head and Neck Surgery. Production and hosting by Elsevier (Singapore) Pte Ltd. This is an open access article under the CC BY-NC-ND license (<http://creativecommons.org/licenses/by-nc-nd/4.0/>).

Contents

1. Introduction	186
2. Materials and methods	186
3. Results	187
3.1. Physical interactions between implanted devices and MRI scanners	187
3.1.1. Interactions between the implant and the static magnetic field (B_0)	187
3.1.2. Interactions between the implant and the gradient magnetic field (dB/dt)	187
3.1.3. Interactions between the implant and the radiofrequency field (B_{1+RMS})	187
3.2. Standard regulations for labelling implantable devices for use in the MRI environment	188
3.2.1. Magnetically induced forces and torques	189
3.2.2. Heating of the tissue surrounding the implant	189

Abbreviations: ASTM, American Society for Testing and Materials; B_0 , Static magnetic field; B_{1+RMS} , Magnitude of the radiofrequency electromagnetic field; dB/dt, Gradient magnetic field; FDA, Food and Drug Administration; ISO, International Standardization Organization; MRI, Magnetic Resonance Imaging; RF, Radiofrequency; TS, Technical Specification.

* Corresponding author. Celestijnenlaan 200D, box 2416, 3000 Leuven, Belgium.

E-mail address: guy.fierens@kuleuven.be (G. Fierens).

Peer review under responsibility of PLA General Hospital Department of Otolaryngology Head and Neck Surgery.

¹ G. Fierens and N. Standaert contributed equally to this work.

² Guy Fierens and Nina Standaert as joint-first authors for this work.

<https://doi.org/10.1016/j.joto.2020.12.005>

1672-2930/© 2020 PLA General Hospital Department of Otolaryngology Head and Neck Surgery. Production and hosting by Elsevier (Singapore) Pte Ltd. This is an open access article under the CC BY-NC-ND license (<http://creativecommons.org/licenses/by-nc-nd/4.0/>).

3.2.3.	Unintended stimulation	190
3.2.4.	Demagnetization	190
3.2.5.	Device malfunction	190
3.2.6.	Image artefacts	190
3.2.7.	Device labelling	190
3.3.	Review of the state-of-the-art reported in literature	191
3.3.1.	Cochlear implants	191
3.3.2.	Auditory brainstem implants	191
3.3.3.	Bone-conduction devices	191
3.3.4.	Active middle ear implants	192
3.4.	Reported adverse events	193
3.4.1.	MAUDE database	193
3.4.2.	Literature (EMBASE and MEDLINE)	193
4.	Discussion	195
	Funding sources	196
	Declaration of competing interest	196
	Acknowledgements	196
	Supplementary data	196
	References	196

1. Introduction

Active implantable hearing systems such as cochlear, middle ear and bone-conduction devices have become the core of a broadly acknowledged therapy in patients suffering from disabling hearing loss (Nospes, S Mann, 2018). Moreover, the range of indications in which such implants find use has increased dramatically. For example cochlear implants (CI), originally merely implanted single-sided in patients with bilateral deafness, are nowadays being employed bilaterally, both in elderly patients, as well as in younger individuals with residual hearing capacity (Todt et al., 2015; Vanderauwera et al., 2019).

Alongside this trend, magnetic resonance imaging (MRI) has become a widely accepted and preferred imaging technique for many pathologies, due to its capacity to create high-resolution images of soft tissue without the use of ionizing radiation. Consequently, expertise in both the possible use of MRI and hearing implants continues to grow, leading to a remarkable widening in indication range in recent years. Besides the significant likelihood of having to undergo an MRI scan during a patient's life, several of these implanted patients necessitate postoperative follow-up using MRI (Gubbels and McMenemy, 2006).

In the past however, the use of MRI in patients implanted with these devices was contraindicated (Abrams, 1989). Only in the past decade, manufacturers have released devices that can be used in an MRI environment under well-defined conditions. Many patients that have been implanted under these new indication criteria will require follow-up with MRI during the course of their lives (Bawazeer et al., 2019; Carlson et al., 2015; Crane et al., 2010), both for pathologies unrelated to the hearing problem as well as for hearing pathologies like neurofibromatosis type 2 (Evans et al., 2009; Walton et al., 2014).

The aim of this work is to increase the understanding on the MRI safety of active implantable hearing devices in scanners with static magnetic field strengths of 1.5 Tesla (T) and 3 T, which are currently the most commonly used field strengths worldwide (Cosmus and Parizh, 2011; Srinivasan et al., 2019). A brief overview of the physical interactions between the scanner and the devices possibly causing patient risk are discussed. This is followed by an overview of how device manufacturers try to demonstrate device safety by complying with industry standards. Next, recent advancements in hearing implant technologies are discussed, focusing on the past

five years. Finally, a systematic review and comprehensive overview of adverse events is provided, by analysing events reported to the FDA and in literature within the past ten years. We conclude with an evaluation of the current insights, the research methods presently applied and a proposal for future work to allow evaluating all possible safety risks related to implantable hearing solutions.

2. Materials and methods

In the following, regulations and industry standards that are required for manufacturers of active implantable hearing systems to demonstrate device safety in the MRI environment are reviewed, together with the most important physical parameters that influence MRI scanning. Relevant literature published in the past five years has been examined to provide insights into the most recent advances in technology. The present review can therefore be considered as an update of the review published by Azadarmaki et al., in 2014 (Azadarmaki et al., 2014a).

Manufacturers, importers or users of medical devices report adverse events related to a particular device to the Manufacturer and User Facility Device Experience (MAUDE) database of the FDA. An adverse event is defined by the FDA as “any undesirable experience associated with the use of a medical product in a patient” (Erhardt et al., 2018; Food and Drug Administration, 2016a). Manufacturers are required to report adverse events with their products according to the FDA Medical Device Reporting (MDR) regulation, Code of Federal Regulation (CFR) title 21 part 803 (Food and Drug Administration, 2019). Reports filed in this database within the past ten years, which are related to the use of active implantable hearing systems in MRI, were collected in January 2020 and reviewed. The MAUDE database was searched using five distinct strings: “MRI hearing implant”, “MRI Cochlear”, “MRI MED-EL”, “MRI Oticon”, “MRI Advanced Bionics”, supplemented with searches performed for companies that are historically linked with these manufacturers: “MRI Phonak”, “MRI Neurelec”, “MRI DigiSonic” and “MRI Otologics”. A search was performed for each year separately, in order to limit the amount of hits and ensure all relevant data could be read out correctly. Returned events (N = 678) were extracted to spreadsheets, which were then combined into a single report. In addition, information was collected on the reporter of each event. Duplicate (N = 8) and adverse events not

related to active auditory implants ($N = 46$) were removed by searching the “Manufacturer”, “Brand name” and “Event description” fields for relevant keywords (see [table A1](#) for the keywords used, appendix 1 which can be consulted in the Supplemental Digital Content of this article). Next, the selected adverse events ($N = 624$) were manually organized and sorted based on manufacturer and adverse event type.

Adverse events reported in literature were systematically collected and reviewed by searching the Medical English Literature database (MEDLINE, U.S. National Library of Medicine, Bethesda, MD, US) and the Excerpta Medica database (EMBASE, Elsevier, Amsterdam, NL) in February 2020 using Medical Subject Headings (MeSH-terms) and free text terms. The Mesh-terms and free text terms that were applied are listed in the supplementary information of this paper. Articles were selected according to the Preferred Reporting Items for Systematic Reviews and Meta-Analyses (PRISMA) framework ([Moher et al., 2009](#)) (see [Fig. 1](#)). A total of 229 articles were found when searching both databases. Cross-referencing between the different database searching was performed, resulting in additional 13 references.

The search was limited to articles published between January 2009 and December 2019. English literature and both original research articles and review articles were included. Secondly, we only included articles with evidence level of $\geq Q3$ (journal ranking quartiles within a subdiscipline using the SJR citation index). Duplicate articles ($N = 29$), which appeared in different Mesh Terms searches, were removed. Articles that provide background information, focus on non-relevant research areas or describe experimental results from in-silico or cadaveric trials were excluded ($N = 161$). The full text has been screened for 52 articles. Additional background articles ($N = 8$), non-relevant articles ($N = 3$) and a conference contribution of a later published paper ($N = 3$) have been removed. An overview of the included articles ($N = 38$) selected by two raters (G.F and N.S.) is presented in a list in the supplementary information of this work.

3. Results

The following paragraphs summarize the different MRI safety aspects for patients with active auditory implants using four different subparagraphs, starting with the physical interactions between the implant and the MRI scanner. Next, an overview of the currently active industry standards is provided, followed by a peer-review of relevant literature. Finally, an overview is presented on the most common adverse events based on data extracted from the FDA and current literature.

3.1. Physical interactions between implanted devices and MRI scanners

The static magnetic field (B_0), the gradient field (dB/dt) and the radiofrequency field (B_{1+RMS}) that are present during scanning can, individually or combined, lead to a number of possible interactions that cause harm to all patients undergoing MRI. For patients implanted with metallic medical devices or devices containing permanent magnets, a number of additional risks arise.

In the following paragraphs, the physics that causes interactions between the MRI scanner and the implant is discussed. There is an extensive amount of literature and information available on these phenomena ([Panych and Madore, 2018](#); [Suetens, 2017](#)), and the reader is referred to this work for more information. The present work focuses on providing information on how scanner settings/parameters influence risk to patients.

3.1.1. Interactions between the implant and the static magnetic field (B_0)

In the presence of a (varying) magnetic flux, generated by a magnetic field B_0 , forces and torques are exerted on metallic and magnetic components. The magnitude of the force is proportional to the spatial variations of B_0 and to the magnitude of B_0 (for metallic objects) or the magnet strength (for magnets) ([Panych and Madore, 2018](#)). In the context of an object in or near an MRI scanner, the magnitude of these forces can be reduced by (i) avoiding locations with a high spatial variation of B_0 , typically occurring around the edge of the bore and (ii) avoiding the use of a permanent magnet or temporarily removing it from the device. The magnitude of the torque is proportional to B_0 and to the sine of the angle between B_0 and the (induced) magnetic field of the implanted component. The torque can be reduced by (i) reducing the misalignment between magnets or magnetized parts and B_0 and (ii) removing permanent magnets. In addition to inducing forces and torques, the B_0 field might also result in a partial demagnetization of implanted permanent magnets. Demagnetization of the implanted magnet can lead to insufficient retention of external sound processors or accessories. The amount of demagnetization depends on the magnitude of the external magnetic field, the material properties of the permanent magnet and the relative angle between B_0 and the magnet's magnetization vector. To reduce the risk of demagnetization the manufacturer guidelines should be followed, and the misalignment between both magnetization vectors should be kept to a minimum.

3.1.2. Interactions between the implant and the gradient magnetic field (dB/dt)

Interactions between the implant and **dB/dt** are to a large extent related to the generation of eddy currents. These induced currents lead to two distinct interactions that could cause patient harm. First, these electrical currents flowing on conductive surfaces inevitably lead to electrical losses. These losses lead to Joule heating on the surface, which increases the device temperature. The following local increase in tissue temperature is however considered to be significantly lower compared to temperature increases due to interactions with the RF field as indicated in the following paragraph ([Panych and Madore, 2018](#)). The second interaction relates to the fact that these current loops result in a magnetic moment due to the Ampère effect. Dynamic forces and torques are generated similarly as the magnetically induced forces and torques described above that follow the dB/dt pulses. Both gradient-induced heating and vibrations can be reduced by diminishing the magnitude of the gradient field. This can be done by (i) limiting the dB/dt value in the scanner settings and (ii) positioning the implant as close as possible to the scanner isocentre.

3.1.3. Interactions between the implant and the radiofrequency field (B_{1+RMS})

Due to Faraday induction, electric fields are generated in conductive media that interact with the RF field (with an amplitude B_1). These electrical fields in turn create eddy currents, which result in energy dissipation similar to what was described above. The presence of a highly conducting implant in the body has impact on the distribution of the electric field within the body and create high electric field densities in the tissues surrounding the implant. The dissipation of energy at these sites is higher, leading to a local temperature increase. The magnitude of these interactions with the RF field can be made smaller by reducing the global specific absorption ratio (SAR) or the average effective RF magnetic field generated by the RF transmit coil (B_{1+RMS}) parameter in the scanner settings. Note that the B_{1+RMS} parameter is only dependent on pulse sequence parameters and not influenced by the patient,

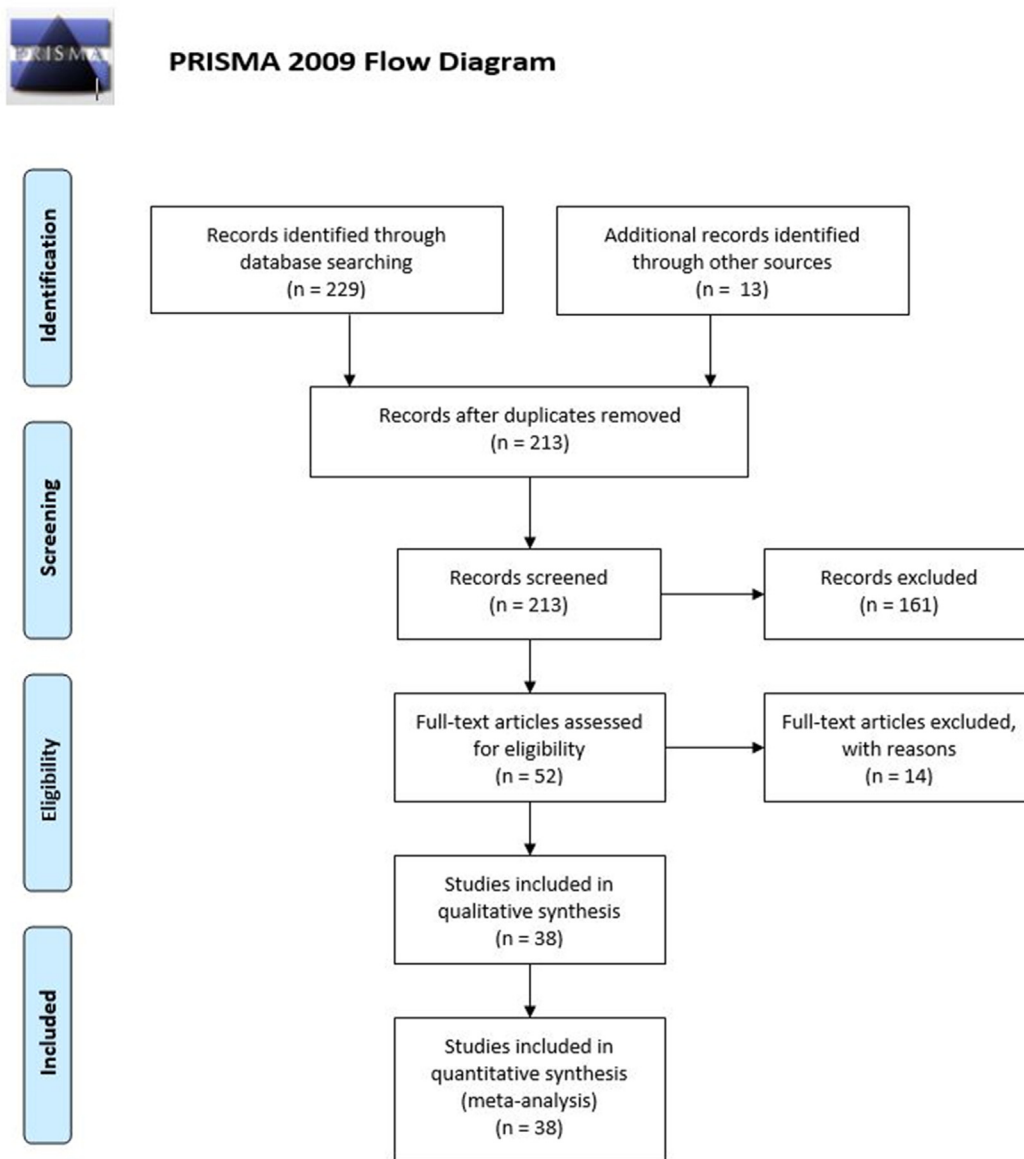


Fig. 1. Overview of the selection of different articles using the PRISMA flow diagram (2009).

providing a more general metric compared to global SAR. The peak local SAR could differ significantly with the global SAR (Chen and Steckner, 2017).

Interactions with the B_0 field, RF field, dB/dt or a **combination of the three** can also result in malfunction of the device for example when induced voltages or currents alter device performance or when the magnetic field resets device memory. These effects cannot easily be mitigated, but it is recommended to verify device performance after the MRI examination.

3.2. Standard regulations for labelling implantable devices for use in the MRI environment

Since the introduction of MRI, a number of standards and guidelines have been developed to ensure the safety of patients and personnel during MRI (Delfino and Woods, 2016; Shellock et al., 2009). An overview of the most important safety assessment and labelling standards governing active implantable hearing systems in the MRI environment is provided in Table 2. The combination of

insights obtained during the testing prescribed in these standards will lead to a comprehensive product label for use in clinical practice that indicate the safe operating conditions of the device during MRI.

For active implants, i.e. implants that “rely for their functioning on a source of electrical energy or any source of power other than that directly generated by the human body or gravity” (FDA, 2019; ISO, 2014), the most important standard is the technical specification ISO/TS 10974 (ISO, 2018). This technical specification has undergone a major update in 2018 and contains the most relevant tests to be performed to assess device safety during 1.5 T MRI exposure. Expanding the scope to also address 3 T MRI systems will be challenging (Delfino and Woods, 2016), but nonetheless the experimental methods described in the standard can be useful for other types of medical devices or scanner field strengths (FDA, 2019). A recent review discusses some of the key standardization aspects for the generic active implantable device (Al-Dayeh et al., 2020). In this work the focus lies on active auditory implants.

Table 1
Magnetic resonance (MR) labelling terminology used by the US Food and Drug administration (ASTM International 2013b; Commission 2014).




Term	Definition	Symbol
MR Safe	An item that poses no known hazards resulting from exposure to any MR environment. MR Safe items are composed of materials that are electrically nonconductive, nonmetallic, and nonmagnetic.	
MR Conditional	An item with demonstrated safety in the MR environment within defined conditions. At a minimum, address the conditions of the static magnetic field, the switched gradient magnetic field and the radiofrequency fields. Additional conditions, including specific configurations of the item, may be required.	
MR Unsafe	An item that poses unacceptable risks to the patient, medical staff or other persons within the MR environment.	

Table 2
Overview of the most important industry standards describing safety assessment and labelling for the use of active hearing systems in the MRI environment.

Standard	Topic/Description related to MRI
ISO/TS 10974:2018(E) (ISO 2018)	Collection of standard test methods to assess the safety of active implantable medical devices in a 1.5 T MRI scanner.
IEC62570:2014 (Commission 2014)	Integrates the unmodified text of ASTM F2503-13 (ASTM International 2013b) regarding implant labelling.
ISO14708-1:2014 (ISO 2014)	Specify that the device labelling information should also include information about the device safety in the MR environment, using the standard terms defined in ASTM F2503.
ASTM F2052-15:2015 (ASTM International 2015)	Standard test method for evaluating magnetically induced forces.
ASTM F2119-07:2013 (ASTM International 2013a)	Standard test method for evaluating image artefacts.
ASTM F2182-11a (ASTM International 2019)	Standard test method for measuring RF induced heating near passive implants. Used as a basis to develop the test method for active implants described in ISO/TS 10974.
ASTM F2213-17:2017 (ASTM International 2017)	Standard test method for measuring magnetically induced torque.
ASTM F2503-13 (ASTM International 2013b)	Standard practice for marking medical devices and other items for safety in MRI. Definition of the categories “MR Safe”, “MR Unsafe” and “MR Conditional” and their corresponding symbols.
BS EN 45502-2-3 (2010) (BSI 2010)	Describes a number of potential hazards and required tests for cochlear and auditory brainstem implants.
EN 45502-1:2015 (BSI, 2015)	Regulates markings on the device and its packaging. Protection from harm to patients caused by different hazards.
ANSI/AAMI CI86:2017 (AAMI 2017)	Safety requirements for cochlear implant systems, including the testing of safety aspects of CIs in MRI with references to a number of other standards.

ISO/TS 10974 describes the most significant hazards for patients resulting from scanner-device interactions: heating of the device via interactions with the RF field or the gradient field, device vibration, magnetically induced forces and torques, device malfunction and unintended stimulation. The latter is considered to be caused by gradient field-induced extrinsic electric potentials or RF field-induced rectified lead voltages (ISO, 2018). Artefacts obscuring the obtained images, possibly reducing the diagnostic value of the images, are not considered to be hazardous to patients by the standard. Image artefacts are considered to be a potential source of harm in the ANSI/AAMI CI86 standard (AAMI, 2017) for CI, and in addition to the risks stated above, this standard also considers weakening or demagnetization of the implant retention magnet to be a possible source of harm.

3.2.1. Magnetically induced forces and torques

References are made within ISO/TS 10974 to technical standards describing test methods for passive implantable medical devices. The standard relies on ASTM F2052 (ASTM International, 2015) and

ASTM F2213 (ASTM International, 2017) to determine the magnitude of **magnetically induced forces and torques**, respectively. Both standards present test methods to determine the magnitude of these forces and torques and compare them to respectively the force and torque exerted on the device due to gravity. This however is not an acceptance criterion, since the means of device fixation, together with the properties of the surrounding tissue, influences the allowable force and torque magnitudes (ASTM International, 2017; FDA, 2019). As reported in Table 2, the British/European standard BS EN 45502-2-3 (BSI, 2010) provides more concrete guidance by stating that magnetically induced forces below 10 N or forces that do not lead to implant displacement can be regarded as acceptable.

3.2.2. Heating of the tissue surrounding the implant

Heating of tissue surrounding the implant results from two contributing factors: RF-induced heating and gradient-field induced heating (ASTM International, 2019).

3.2.2.1. Heating of the tissue surrounding the implant – RF induced heating. Previously, the test method to assess **RF-induced tissue heating** was described in ASTM F2182 (ASTM International, 2019; BSI, 2010). For active implantable medical devices, the 2018 update of ISO/TS 10974 also led to the inclusion of an updated test method for RF-heating (ISO, 2018). The standard describes the risk to patients to be a function of absolute temperature, the duration of the exposure to elevated temperatures and individual implant considerations (ISO, 2018). Predicting the exact in-situ temperature rise is a complex process due to the large number of contributing variables. Assessing patient risk due to RF-heating is therefore a conservative approach consisting of a combination of computer simulations and experiments in a conductive gel-filled phantom. Depending on the size of the implant and the preferred degree of realism one of four tiers can be selected, each with an increasing degree of complexity and realism. Tiers 3 and 4 are applicable to any active implant, irrespective of the implant dimension (ISO, 2018). Tier 3 provides more conservative results and requires less complex simulations compared to tier 4 (ISO, 2018). Tier 3 involves electromagnetic modelling of the tangential electric field along the device's pathway, together with the development and validation of a computer model, in which the implant is placed inside a human-shaped rectangular container that is filled with a gel having a similar electrical conductivity to human tissue (ISO, 2018). Simulations are performed to identify potential hotspots around the implant site. Temperature sensors are then mounted at the location of these hotspots in the physical test setup. When radiating with RF energy, the temperature increase as a function of time can be measured. As a result, a maximum permitted RF exposure per unit of time can be derived, which can subsequently be reported in the device's MRI safety guidelines. In current MRI safety guidelines of active hearing implants, this value is reported in the form of whole-body averaged SAR or head average SAR. However, the maximum allowable B_{1+RMS} electromagnetic field can also be used (Commission, 2010).

3.2.2.2. Heating of the tissue surrounding the implant – gradient induced heating. The second contributor to tissue heating is **gradient-induced heating**. In contrast to RF heating, gradient field induced heating leads to increased temperatures within the implant itself, which is then dissipated to the surrounding tissue. Test methods to assess the risk of harmful gradient field heating have been described in ISO/TS 10974 (ISO, 2018). These methods require mounting the implant in a gel-filled container similar to the RF heating. Temperature sensors are mounted on locations that are expected to heat up significantly like large conductive surfaces (the implant casing) or other previously identified hotspots. The implant is then exposed to switching gradient fields with an amplitude and direction that is representative of the worst-case for that specific implant. Similar to RF heating, the manufacturer can opt for one of two tiers, making a trade-off between a more conservative or realistic approach. As indicated above, the expected magnitude of gradient heating is significantly less compared to RF induced heating (Panych and Madore, 2018).

3.2.3. Unintended stimulation

Till today, **unintended output** of devices during MRI is considered to be the result of an unintended electric potential that leads to stimulation of the tissue surrounding a tissue-facing electrode. In ISO/TS 10974, this is considered to be the result of two different interactions: gradient-induced extrinsic electric potentials, and RF field-induced rectified lead voltages. In the former, the gradient electric field generates an electric potential between spatially separated electrically conductive materials. This can be between the different electrode contacts of a CI electrode (intra-

lead), between the CI electrode and the reference electrode (inter-lead) or between one of the electrodes and the implant casing (ISO, 2018). Unintended stimulation of the tissue can occur when the induced potential leads to a current loop through the device and the tissue. In general, this occurs when the impedance between the different conductive components is low. RF field-induced rectified lead voltages are a result of induced lead voltages gaining an amplitude that can cause non-linear circuit elements to start conducting. This in turn can result in voltage pulses being induced on electrodes in contact with surrounding tissues causing unintended stimulation. Test methods to assess the risk of unintended output due to RF field-induced rectified voltages are based on injecting an RF voltage of known amplitude and phase onto a number of specified locations on the lead and other conducting surfaces (ISO, 2018). Test methods are defined in ISO/TS 10974:2018 (ISO, 2018) and referenced by ANSI/AAMI:CI86 (AAMI, 2017) for cochlear and auditory brainstem implants. British/European standard BS/EN 45502-2-3 regarding requirements for cochlear and brainstem implants however recommends measuring the induced voltage on electrode contacts using a specific test setup within a clinical MRI scanner during a worst-case pulse sequence (BSI, 2010).

3.2.4. Demagnetization

Demagnetization of the implanted retention magnet may lead to an insufficient retention force needed to keep the external sound processor coil in place. For CI, ANSI/AAMI CI86 (AAMI, 2017) recommends reporting on the percentage of magnet weakening after one and ten exposures in the implant labelling. British/European standard BS EN 45502-2-3 (BSI, 2010) considers demagnetization of the implant magnet to be acceptable if the manufacturer is able to provide an alternative fixation method.

3.2.5. Device malfunction

A more general risk for patients with implants during MRI scanning is that their device **malfunctions** during or after the scan. Due to interactions with the static, RF, gradient field or a combination of the different fields, the functionality of the device can be temporarily or permanently altered. Technical specification ISO/TS 10974 (ISO, 2018) describes test methods to assess possible malfunctions due to individual and combined magnetic fields. British/European standard BS/EN 45502-2-3 (BSI, 2010) limits testing of implant malfunction to combined field testing and monitoring if the device behavior post-MRI still complies to the manufacturer specifications (BSI, 2010). ANSI/AAMI CI86 (AAMI, 2017) considers malfunction to be a result of gradient-field induced vibrations, neglecting other contributing factors.

3.2.6. Image artefacts

Although not considered as a risk by ISO/TS 10974 (ISO, 2018), manufacturers are required to determine the extent of **image artefacts** on MRI images to allow reporting on artefact sizes in the device labeling (AAMI, 2017; FDA, 2019). Technical standard ASTM F2119-07 (ASTM International, 2013a) describes a standard test method to acquire images and measure the extent of these artefacts in an artificial phantom. By adapting the slice selection and frequency encoding gradient, a worst-case setting is obtained. Gradient echo images are then acquired for reporting in the device safety guidelines, which are assumed to present the absolute worst case. Mention of suggestions to minimize the extent of the artefact is not required.

3.2.7. Device labelling

Depending on the magnitude of scanner-device interactions, a device can receive a **label** in one of three categories (ASTM International, 2013b; Commission, 2014). These categories are:

“MR Safe”, “MR Conditional” or “MR Unsafe” and indicate that a device can be scanned in any type of MRI scanner without risk and without specific rules and preparation, only under specific conditions, or under no circumstances, respectively (Table 1). This labelling needs to be included in the instructions for use, patient information card, package inserts, the MRI procedure manual and in the patient and physician manuals of the device (ASTM International, 2013b; Commission, 2014; FDA, 2019; ISO, 2018). If a device is considered to be MR Safe or MR Unsafe, clear statements must be made on the patient card including the symbol defined in ASTM F2503 (ASTM International, 2013b) and/or IEC 62570 (Commission, 2014) and a statement indicating the (un)safe behavior of the device in a particular scanner type (FDA, 2019). Note that only parameters that are “affecting the safety” are required to be listed by ASTM F2503 (ASTM International, 2013b). For MR Conditional devices, the respective symbol needs to be shown, together with an accompanying statement and the allowed circumstances defined by a number of parameters (FDA, 2019; ISO, 2018, 2014):

1. Nominal values of the allowed static magnetic field strengths.
2. Maximum spatial field gradient.
3. Permitted RF exposure, i.e. coil type, RF excitation, maximum allowable whole-body or local SAR and the maximum permitted B_{1+RMS} value.
4. Permitted time-varying gradient field exposure defined as the maximum gradient slew rate (T/m/s) per axis and the maximum spatial encoding gradient amplitude (mT/m) per axis.
5. Limits on scan duration.
6. Scan exclusion zones indicated on a figure.
7. Additional essential information to ensure a safe operation within the MR environment.
8. A statement directing users to the current MR conditional labelling (e.g. URL and phone number) (ISO, 2018).
9. A final statement to resolve any other missing parameter information such as: “If information about a specific parameter is not included, there are no conditions associated with that parameter.” (FDA, 2019)

Additional statements are applicable specifically for hearing implants (AAMI, 2017):

10. Information on image artefacts, including an image of the head in an axial view, showing the slice with the largest artefact. For devices with removable magnets, images shall be shown both with the magnet in place and with the magnet removed. Image parameters used to acquire the shown images shall be reported as well (AAMI, 2017).
11. Include a declaration regarding the risk of demagnetization (AAMI, 2017).
12. Instructions to be followed before and/or after the MRI examination, e.g. the application of a head bandage or removal of the implant magnet (F. Hassepas et al., 2014).

The FDA has released several guidance documents in the last decade describing the MRI safety and risk assessments of passive devices (Food and Drug Administration, 2016b; Woods, 2014). A recent draft guideline on “Testing and Labeling Medical Devices for Safety in the Magnetic Resonance (MR) Environment” (FDA, 2019) provides guidance on MR safety, compatibility assessments and labelling information for all medical devices for use in the MR environment. The document also provides an overview of applicable standards, available guidance documents and MRI-induced hazards. In addition, the draft guidance document provides recommendations to clarify MRI safety information of medical devices, as described above.

3.3. Review of the state-of-the-art reported in literature

3.3.1. Cochlear implants

The external sound processor and other accessories of all CIs are considered MR unsafe and must be removed (Azadarmaki et al., 2014a). Furthermore, it is recommended to remove the magnet when the anatomic area of interest is close to the implant (Srinivasan et al., 2019) to avoid artefacts obstructing the anatomical region of interest (Edmonson et al., 2018).

Devices that have recently been released contain a rotatable magnet (Med-El Synchrony) or four smaller rotatable magnets (Advanced Bionics HiRes Ultra 3D) that allow a proper alignment of the internal magnet with B_0 (Cass et al., 2019). A recent study documented no magnet-related complications, such as discomfort or magnet displacement, in patients implanted with a CI with a diametric magnet due to elimination of outward magnet torque (Young et al., 2020). The Cochlear Nucleus Profile Plus implant is equipped with a novel magnet, allowing MRI up to 3 T without the need for magnet removal or use of a splint. Another approach to avoid magnet dislocation is shown in the Oticon Neuro Zti CI, where the magnet is screwed into the implant housing. The housing is in turn fixed onto the skull using screws.

An overview of all CI models mentioned above with the corresponding allowed maximum MRI field strength is shown in Table 3 (Baumgartner et al., 2001; Crane et al., 2010; Fritsch and Mosier, n. d.; Gubbels and McMenomey, 2006; Hochmair, 2001; Hospital and Schmerber, 2003; Migirov and Wolf, 2013; Nospes, S Mann, 2018; Tam et al., 2013; Teissl et al., 1998; 1999; Walton et al., 2014; Youssefzadeh et al., 1998).

Older CI models from all manufacturers that are not mentioned in the previous paragraphs are labelled MRI unsafe.

3.3.2. Auditory brainstem implants

Auditory brainstem implants (ABI) consist of a surgically implanted magnet with an electrode placed in the brainstem at the cochlear nucleus (Tam et al., 2010; Tysome et al., 2012). All ABI's have been evaluated and meet international EN45502 safety guidelines for MR scanning up to 1.5 T (Walton et al., 2014). Three ABI systems are currently on the market: Cochlear Nucleus ABI541, Med-El Synchrony ABI and Med-El Concerto ABI.

An overview of the applicable guidelines for these devices is provided in Table 4 below.

3.3.3. Bone-conduction devices

Bone-conduction devices (BCD) provide mechanical or acoustic stimulation and can be divided into “skin-drive” and “direct-drive” devices (Azadarmaki et al., 2014a; Reinfeldt et al., 2015).

Skin-drive BCD's transmit vibrations through the skin onto the skull are considered to be passive transcutaneous devices (Reinfeldt et al., 2015). Passive transcutaneous devices, such as the Medtronic Sophono and Cochlear Baha Attract, contain an implanted magnet (Jansson et al., 2015; Siegert, 2011; Siegert and Kanderske, 2013).

Direct-drive BCD's transmit vibrations directly to the skull bone and are categorized as either percutaneous or active transcutaneous devices (Reinfeldt et al., 2015). Percutaneous direct-drive BCD's, such as the Cochlear Baha Connect and Oticon Ponto system, consist of an implanted fixture and abutment, which is attached to the external sound processor. These implants are MR conditional up to 3.0 T (Oticon Medical, Information for MR professionals. <http://www.oticonmedical.com/~asset/cache.ashx?id=11507&type=14&format=web>. Accessed October 26, 2013.,” n.d., “RadiographerRadiographer”—MRI for BAHA patients. <http://www.cochlear.com/wps/wcm/connect/36c71ca0-963b-4786-a0a0-072b4090908e/E818971Baha1MRI1Information%2C1GB.pdf?>

Table 3
Overview of the guidelines when scanning cochlear implants (Srinivasan et al., 2019). N/A: Not Applicable.

Manufacturer	Model	Maximum MRI field strength (T)	Magnet removal	Head bandage
Med-El	Concerto	1.5	Not possible	Mandatory
	Sonata	1.5	Not possible	Mandatory
	Pulsar	1.5	Not possible	Mandatory
	C40	1.5	Not possible	Mandatory
	Synchrony	3.0	Not required	Optional
Cochlear	Nucleus Freedom	1.5	Not required	Mandatory
		3.0	Required	N/A
	Nucleus 22	1.5	Not required	Mandatory
		3.0	Required	N/A
	Nucleus 24	1.5	Not required	Mandatory
		3.0	Required	N/A
	Nucleus CI500	1.5	Not required	Mandatory
		3.0	Required	N/A
	Nucleus Profile Plus	1.5	Not required	Optional
		3.0	Not required	Optional
Advanced Bionics	HiRes 90 K Advantage	1.5	Not required	Mandatory
		3.0	Required	N/A
	HiRes Ultra	1.5	Not required	Mandatory
		3.0	Required	N/A
Oticon	HiRes Ultra 3D	1.5	Not required	Optional
		3.0	Not required	Optional
	Neuro Zti	1.5	Not required	Mandatory
		3.0	Required	Mandatory
Digisonic		1.5	Not required	Mandatory

MOD=AJPERES&CONVERT_TO=url&CACHEID=36c71ca0-963b-478 6-a0a0-072b4090908e. Accessed Oct, n.d.), although one study even implied MRI safety up to 9.4T (Fritsch et al., 2008). In active transcutaneous direct-drive BCD’s, such as Med-El Bonebridge, the Oticon Sentio (previously known as the Bone Conduction Implant (BCI)) and the Cochlear Osia system, the transducer is implanted underneath the skin (Reinfeldt et al., 2015). The behaviour of the Med-El Bonebridge in MRI has been described by several authors, mostly focusing on image artefact reduction in cadavers (Steinmetz et al., 2014; Utrilla et al., 2020; Wimmer et al., 2019) and in patients (Yang et al., 2018).

An overview of all bone-conduction devices mentioned above with the corresponding allowed maximum MRI field strength is given in Table 5 (Cochlear, 2019; Nospes et al., 2013; Pross et al., 2018).

3.3.4. Active middle ear implants

Active middle ear implants (AMEI) provide acoustic stimulation using an actuator coupled to the patient’s ossicles or round window (Azadarmaki et al., 2014a; Wimmer et al., 2019). Examples include the Med-El Vibrant Soundbridge (VSB), Ototronix Maxum, Envoy Medical Esteem and Cochlear Carina 2, which are currently the only AMEI on the market (Azadarmaki et al., 2014a).

In vitro studies have reported floating mass transducer (FMT) dislocation of the Med-El VSB type 502 when scanning at 1.5 T (Jesacher et al., 2010; Todt et al., 2011), which has led to a new generation of the VSB (type 503) showing neither positional nor

functional changes at 1.5 T during a temporal bone study (Schnabl et al., 2016).

The Ototronix Maxum is an AMEI consisting of a surgically implanted electromagnetic actuator attached to the ossicular chain. The implant was considered MR unsafe due to several observed side effects (Dyer et al., 2002). An in vivo study however reported that the implant is MR conditional up to 0.3 T, when guidelines considering patient positioning are strictly followed (Pelosi et al., 2014).

The Envoy Medical Esteem is an AMEI using a piezoelectric actuator, which is inert in a magnetic field. This design is considered MR conditional up to 3.0 T. Updates from FDA concerning recommendations for the usage of MR in implanted patients should be taken into account (Seidman et al., 2019).

The Cochlear Carina 2 System is a fully implantable system for patients with moderate to severe sensorineural or mixed hearing loss and has been on the market until May 2020. From an MRI safety perspective, this device is labelled MR unsafe (Nospes et al., 2013). A recently published temporal bone study has indicated that the risk of an MRI-induced dislocation of the Carina 2 actuator is limited (Fierens et al., 2020). Recent work uses the Carina 2 system as a test case in the development of an MRI-safe vibrometer which can be used to assess the risk of unintentional output during scanning (Fierens et al., 2019). The Cochlear Codacs, MET and Carina 1 Systems were also labelled MR unsafe.

An overview of all AMEI’s mentioned above with the corresponding allowed maximum MRI field strength is given in Table 6.

Table 4
Overview of the guidelines when scanning auditory brainstem implants.

Manufacturer	Model	Maximum MRI field strength (T)	Magnet removal	Head bandage
Med-El	Concerto ABI	1.5	Not possible	Mandatory
	Synchrony ABI	1.5	Not required	Optional
Cochlear	Nucleus ABI24	1.5	Not required	Mandatory
		3.0	Mandatory	Not required
	Nucleus ABI541	1.5	Not required	Mandatory
		3.0	Mandatory	Not required

Table 5
Overview of the guidelines when scanning bone-conduction devices.

Manufacturer	Model	Maximum MRI field strength (T)	Magnet removal
Cochlear	Baha Attract	1.5	Not required
	Baha Connect	3.0	Not applicable
	Osia	1.5	Not required
		3.0	Required
Med-El	Bonebridge	1.5	Not required
Medtronic	Sophono	3.0	Not required
Oticon	Ponto	3.0	Not required
	BCI (Sentio)	Not labelled for use in MRI	

3.4. Reported adverse events

3.4.1. MAUDE database

A total of 624 adverse events related to the use of MRI in patients with active auditory implants have been filed between 2009 and 2019. Most of these events were reported by the manufacturers themselves (95%, N = 595), and only a minority was reported by individuals or user facilities (5%, N = 29). For 376 (60%) events, the year of occurrence was mentioned in the report. In general the amount of adverse events occurring increased on a yearly basis, which is likely related to the yearly increase in patient population with auditory implants (Shew et al., 2019). The minimum of adverse events reported was 12 in 2010, while the maximum number of events occurring in a year was in 2018 (N = 67). For 2014 and 2016 there was a slight decrease in the number of adverse events. Fig. 2 below shows the occurrence of adverse events over time. For 247 entries no date of occurrence was given.

When categorizing the adverse events per device type, it turns out that the majority of events have occurred with CI (N = 592), while reports for bone conduction (N = 15), middle ear (N = 13) and auditory brainstem issues (N = 2) are rare. For five events no device type was reported. As more CI's are in use today compared to bone conduction and middle ear implants it can be expected that relative occurrence of adverse events won't differ significantly between the product groups. Estimating relative measures is unfortunately impossible as it is unknown how many devices are implanted at a given time.

Dislocation of the internal magnet of active auditory implants is the most commonly reported adverse event type (N = 384), often being explicitly reported in combination with a painful experience for the patient (N = 59). Pain surrounding the implant site has also been described (N = 48), without referring to any resulting magnet dislocations. Demagnetization of the implant magnet is less common (N = 8). Manufacturers often recommend removing the implant magnet before an MRI procedure. In practice, this recommendation is only rarely followed (we only found N = 18 cases reported). In the majority of these reports, adverse events related to the explantation procedure were described like a tear in the silicone around the magnet (N = 3) or were associated with physiological events (N = 11) like inflammation or an allergic reaction to the non-magnetic replacement plug.

In a total of 130 event reports (21%), it was mentioned whether or not the manufacturer instructions had been used. Manufacturer guidelines were followed approximately half the time (47%, N = 61), while approximately forty percent of cases (N = 49) indicated that guidelines were not followed. For twenty cases (15%) the description was unclear whether guidelines had been followed. Combined with the 494 (79%) events where there was no mention of the manufacturer guidelines, it was unclear in more than 82% of events whether or not the prescribed guidelines had been followed.

Next to issues related to the implantable magnet, the most commonly reported adverse event is the explantation of the complete device prior to MRI (N = 110), which has mostly occurred because of non-use of the device or on the patient's request.

Other, less common adverse events are device malfunction after the procedure (N = 24), tissue heating (N = 5), device migration (N = 4), obstruction of the acquired images due to artefacts (N = 3), unintentional output (N = 4), dislocation of a middle-ear actuator (N = 2), a loss of osseointegration for bone-anchored devices (N = 1) or a lack of clear guidance (N = 1).

3.4.2. Literature (EMBASE and MEDLINE)

A total amount of 229 adverse events, related to the use of MRI in patients with active auditory implants, are described in literature within the past ten years. The full results of the adverse events found in literature can be consulted in the Supplemental Digital Information connected to this article. 339 patients underwent a total amount of 529 MRIs. The majority of the adverse events described in literature occurred with CI (N = 179) followed by middle ear (N = 30) and auditory brain stem implants (N = 4). No adverse events have been reported for bone conduction devices. For 15 events it was not specified if either a CI or ABI was used.

The most frequently documented adverse event is pain, including discomfort and pressure (N = 88) occurring in about 17% of the total reported MRI scans. More than half of those patients were wearing a head bandage (N = 50). The patient could not complete MRI in 32% of those cases (N = 27). Nonetheless, most patients favoured scanning with the magnet in situ, over surgical magnet removal (Pross et al., 2018).

Pain increase is not significantly associated to the scan duration, nor the body part being imaged, or the patient's body mass index (Pross et al., 2018). Administration of oral sedatives is proposed by

Table 6
Overview of the guidelines when scanning active middle ear implants.

Manufacturer	Model	Maximum MRI field strength (T)
Cochlear	Carina 1	MR Unsafe
	Carina 2	MR Unsafe
	Codacs	MR Unsafe
	MET	MR Unsafe
		3.0
Envoy Medical	Esteem	3.0
Med-El	Vibrant Soundbridge (VSB) type 503	1.5
Ototronix	Maxum	0.3

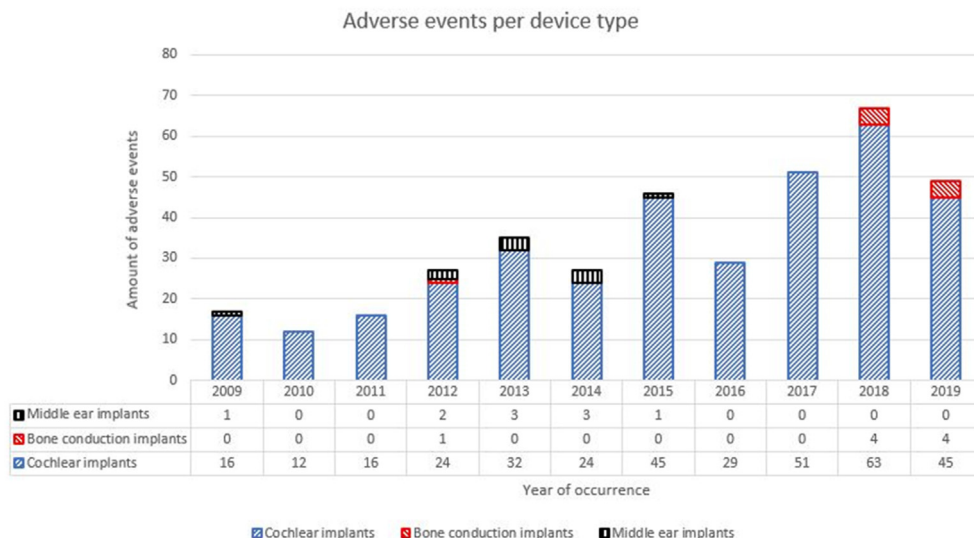


Fig. 2. Adverse events reported per year for each device category with known dates of occurrence.

some authors (Crane et al., 2010; Kim et al., 2015), however pain remains a major concern in implanted patients undergoing MRI (Shew et al., 2019).

The second most reported adverse event is dislocation of the internal magnet (N = 58), including magnet polarity reversal (N = 11) and magnet rotation or canting (N = 5). Movement of the magnet during MRI occurred in approximately 11% of the total of MRIs reported. Magnet polarity reversal is expected to be caused by a physical realignment of the internal magnet with the B₀ field (Jeon et al., 2012) and is therefore included in the group of dislocations.

A tight head bandage to prevent dislocation is often prescribed in device guidelines, though there are controversial opinions as to what extent a head wrap eliminates this risk (Broomfield et al., 2013; Carlson et al., 2015; Cass et al., 2019; Cuda et al., 2013b; Hassepas et al., 2014; Kim et al., 2015; Shew et al., 2019). Similarly, in our data, the majority of the dislocations occurred despite using a head bandage (N = 49; 83%), resulting in additional skin ulceration around the magnet site in one case. Some authors advise head x-ray for all patients with implants after undergoing MRI (Cuda et al., 2013a; F. Hassepas et al., 2014) in order to correctly localize the magnet before bandage application.

Manual manipulation without surgery has been described when the magnet was dislocated or canted (Carlson et al., 2015; Walker et al., 2018), though most cases require revision surgery through an open approach (Broomfield et al., 2013; Cuda et al., 2013a; F. Hassepas et al., 2014; Kim et al., 2015; Shew et al., 2019; Walker et al., 2018; Young et al., 2016). In one case an endoscopic assisted repositioning of a dislocated CI magnet was described (Leong and Yuen, 2018). In case of magnet polarity reversal, reversing the external magnet may solve the problem (Carlson et al., 2015; Jeon et al., 2012; Kim et al., 2015; Young et al., 2016), yet sometimes surgical repositioning is required (Carlson et al., 2015; Öztürk et al., 2017).

In a retrospective case study of 1706 patients implanted with a CI, Hassepas et al. concluded that MRI-induced magnet dislocation is the main reason for revision surgery (Frederike Hassepas et al., 2014).

Two cases of MRI-induced silastic tearing of the silicone casing have been reported. In the first case, the CI was replaced by a new device (Walker et al., 2018), while in the second patient the tear area was stabilized with sutures through the implant bed without the need for re-implantation (Demir et al., 2019).

Other, less common adverse events, such as altered device performance (N = 5), unintended acoustic output (N = 6), demagnetization (N = 4), actuator dislocation (N = 6), sound perception (N = 1) and subcutaneous movement of implant receiver (N = 1), are also described.

New designs with freely rotatable magnets, such as Med-El Synchrony, Advanced Bionics HiRes Ultra 3D and Cochlear Nucleus Profile Plus, have been launched, permitting the internal magnet to realign with B₀. This reduces the magnetically induced torque and thereby diminishes the chance of demagnetization and occurrence of pain (Cass et al., 2019). Multiple studies document the absence of pain and other adverse events with these devices in both 1.5 and 3 T MRI, even without the use of a headband (Cass et al., 2019; Shew et al., 2019; Todt et al., 2017, 2018). Realignment of the magnet with external accessories might however require several attempts after MRI (Cass et al., 2019). Nonetheless, clinical data of these devices are scarce (Demir et al., 2019).

Although it is not considered a main concern for regulatory bodies, the appearance of image artefacts are of great concern by clinicians as they reduce image quality (Crane et al., 2010; Kim et al., 2015). The internal magnet causes a region of signal void and image distortion due to loss of coherence, sometimes leading to diagnostic invaluable images when the anatomic region of interest is within the artefact (Cass et al., 2019).

In total, 52 occurrences of image artefacts have been reported in literature within the past ten years. The extent of the artefacts is related to the implant type, the strength of the magnetic field and the MRI sequence used (Majdani et al., 2009). For example, T1- and T2-weighted imaging obtained with spin echo techniques show smaller artefacts compared to images obtained with gradient echo techniques, due to its refocusing pulse which reduces the dephasing and loss of coherence produced by the magnet (Hargreaves et al., 2011). Depending on the sequence used and the implant involved, authors report mean artefact sizes ranging between 5.5 and 8.4 cm (Cass et al., 2019; Crane et al., 2010; Kim et al., 2015; Walker et al., 2018). Thus, reported artefact sizes vary greatly in literature with scarce information regarding the measurement technique. Cass et al. proposes a standardized method in which artefact size is reported in radii at the image level of maximal signal loss (Cass et al., 2019).

Furthermore, diagnostic evaluation is not only determined by artefact size, but also by the location of the artefact (Cass et al., 2019). Especially when imaging the brain or the ipsilateral

internal auditory canal, the artefact could obscure part of the anatomical region of interest and optimized pulse sequences should be recommended to keep the artefacts to a minimum. Depending on the post-operative needs for imaging an implant candidate, the responsible surgeon can improve the visibility of key anatomical regions, like the ipsilateral internal auditory canal, by placing the implant >9 cm posterior-superiorly from the external auditory canal. It should be noted that this may differ from children (Todd et al., 2015).

Optimization of the image artefacts can be performed by using metal artefact reducing sequences as SEMAC-VAT (Steinmetz et al., 2014; Utrilla et al., 2020; Wimmer et al., 2019) or by using a number of conventional techniques to optimize image quality: increasing receiver bandwidth, switching the frequency- and phase-encoding direction, reducing slice thickness, increasing the matrix size or using fast spin echo techniques (Jungmann et al., 2017). A recent study showed that with proper scanner settings, differences could be observed to distinguish modiolar and lateral wall electrodes in CI (Sudhoff et al., 2020).

Despite the fact that it does not meet our inclusion criteria, it is necessary to mention that a recently published prospective study assessing MRI magnet-related complications obtained similar results and refers to several articles which are also cited here (Tam et al., 2020).

4. Discussion

The above presented overview of the main topics concerning the MRI safety of active auditory implants aims to provide a clear overview for healthcare professionals. With regard to the physical phenomena that cause mutual interactions between implants and MRI scanners, the analysis provides a high-level overview focused on providing the required background information. Based on these insights, an overview of the applicable industry standards could be compiled, together with an extensive overview of adverse events.

Before, during or after an MRI examination, several interactions may occur that can cause patient harm: the induction of forces/torques that can cause device migration, local heat dissipation due to interactions of the device with the dynamic electromagnetic fields, device malfunction, etc. The manufacturers must assess the severity and likelihood of the occurrence of a number of these interactions prior to obtaining a device label for MRI. Regarding active implantable devices, technical specification ISO/TS 10974:2018 (ISO, 2018) presents the most complete overview of required tests (Al-Dayeh et al., 2020). In addition, ten additional standards have been identified, together with three FDA-issued documents that provide guidance on specific aspects of MRI safety of active implantable auditory devices. Even though manufacturers are obliged to comply with all applicable standards, it should be mentioned that there is no single standard covering the complete list of required tests and reporting specifications. All relevant standards are focusing on electrically stimulating devices like cochlear and auditory brainstem implants. Device-specific risks for acoustically stimulating devices such as bone conduction implants and middle ear implants are therefore not completely covered in these documents. One possibly harmful interaction that is not incorporated in these standards is the risk of unintentional output of acoustic devices, which could present a patient with auditory sensations during an MRI examination. Regarding cochlear and auditory brainstem implants containing permanent magnets, only ANSI/AAMI CI86:2017 (AAMI, 2017) requires manufacturers to assess the risk of demagnetization due to interactions with the static magnetic field of the scanner. For other device types, there is no requirement to assess this risk even though a number of active transcutaneous bone conduction implants and middle ear implants

are equipped with permanent magnets. In addition, the standard does not require performing these tests at body temperature. Demagnetization is a temperature-dependent phenomenon, where an increased temperature increases the amount of demagnetization when exposed to a certain external magnetic field. This can be directly derived from the magnetization curves or BH-curve of a magnetic material. The obtained results in these prescribed tests could therefore be an underestimation of the in-vivo situation. Current efforts regarding labelling aim to improve and harmonize the labelling information provided by manufacturers. Having complete and uniform information available for all different implants can be expected to assist healthcare professionals to take all necessary precautions in order to reduce patient risk as much as possible.

Currently, the lack of clear information and/or patient preparation contributes to the occurrence of adverse events during MRI. Only in 61 of the total of 624 events reported to the FDA there was a clear statement indicating that manufacturer guidelines had been followed. The most common adverse event type reported to the FDA and the second most common in literature is the dislocation of the internal magnet due to magnetically induced forces and torques. Even in cases where the magnet is not migrating, this often causes pain and distress to patients during scanning, leading to the procedure being ended prematurely. Manufacturers often recommend removal of the implantable magnet both to reduce the risk of magnet dislocation and improve the image quality in the tissue surrounding the implant location. Alternatively, a head bandage and/or splint can be used to reduce the risk of magnet dislocation. This measure has however not always been successful, possibly in part due to a misaligned splint (Crane et al., 2010).

Within the last years, significant advancements have been made regarding the use of MRI in patients with hearing implants. Manufacturers have been working towards safer solutions, bringing to market some new innovative products and research has led to greater insights into the root cause(s) of potential risk to patients and personnel during MRI, and strategies to reduce their occurrence and impact. It should be taken into account however that safety guidelines could vary across regions and that clinicians should always refer to the guidelines that apply to their region (Azadarmaki et al., 2014b). Considering the number of recently released products that allow easier access to MRI like the Advanced Bionics HiRes Ultra 3D, the Cochlear Profile Plus Implant Series or the Oticon Medical Neuro Zti there is a need to enlarge the clinical evidence base with respect to the daily use and the patient experience with these products during MRI. Innovation in this space will likely continue in the next years and increasing the clinical evidence base is key in ensuring safe MRI scanning of patients with all newly released technologies. Despite the advancements in implant technology with respect to MRI safety, a yearly increase in adverse events could be observed (Fig. 2). It can be expected that this yearly increase corresponds mainly to the increasing number of implanted patients (Srinivasan et al., 2019) in combination with the fact that not all patients that are implanted today are equipped with the latest technology. The exact number of adverse events is assumed to differ from the numbers reported in this work as it is unlikely that all events occurring globally are consistently reported to the authorities. It can however be assumed that the presented data is a proper sample of the complete number of events and that it offers a proper view on the most important adverse event types and their rate of occurrence.

In summary, a concise overview was presented covering all aspects related to the MRI safety of active auditory implants. Based on the provided physical background, insights on the risks and safety of exposing patients with active auditory implants to an MRI scan was provided. From the complete literature review and FDA

database it can be concluded that despite manufacturers guidelines and labelling, adverse events still occur, showing the high need for increased understanding of the topic for healthcare professionals and uniform labelling guidelines. The main consideration to make with this study is that it is inherently impossible to prove “safety” as such, but that with adequate precautionary measures the risk for the patient can be kept to a minimum. Future research should work towards improving the insights regarding device-specific risks like unintended output of acoustically stimulating implants and its impact on the patient’s residual hearing.

Funding sources

GF received funding from Flanders Innovation and Entrepreneurship (HBC. 2018.0184) and Cochlear Ltd. NV receives funding from Research Foundation Flanders (FWO 1804816N) as a senior clinical investigator.

Declaration of competing interest

GF is an employee of Cochlear Ltd.

Acknowledgements

The present work has been performed with the support of Flanders Innovation and Entrepreneurship (HBC. 2018.0184) and Cochlear Ltd.

Appendix A. Supplementary data

Supplementary data to this article can be found online at <https://doi.org/10.1016/j.joto.2020.12.005>

References

- Aami, 2017. Cochlear Implant Systems - Safety, Performance and Reliability. ANSI/AAMI CI86:2017. AAMI. <https://doi.org/10.5594/j17740>.
- Abrams, H.L., 1989. Cochlear implants are a contraindication to MRI. *J. Am. Med. Assoc.*
- Al-Dayeh, L., Rahman, M., Venook, R., 2020. Practical aspects of MR imaging safety test methods for MR conditional active implantable medical devices. *Magn. Reson. Imag. Clin. N. Am.* 28, 559–571. <https://doi.org/10.1016/j.mric.2020.07.008>.
- ASTM International, 2019. ASTM F2182–19, Standard Test Method for Measurement of Radio Frequency Induced Heating on or Near Passive Implants during Magnetic Resonance Imaging.
- ASTM International, 2017. ASTM F2213–17, Standard Test Method for Measurement of Magnetically Induced Torque on Medical Devices in the Magnetic Resonance Environment.
- ASTM International, 2015. ASTM F2052–15, Standard Test Method for Measurement of Magnetically Induced Displacement Force on Medical Devices in the Magnetic Resonance Environment.
- ASTM International, 2013a. ASTM F2119–07(2013), Standard Test Method for Evaluation of MR Image Artifacts from Passive Implants.
- ASTM International, 2013b. ASTM F2503–13, Standard Practice for Marking Medical Devices and Other Items for Safety in the Magnetic Resonance Environment.
- Azadarmaki, R., Tubbs, R., Chen, D.A., Shellock, F.G., 2014a. MRI information for commonly used otologic implants: review and update. *Otolaryngol. Head Neck Surg.* 512–519. <https://doi.org/10.1177/0194599813518306>.
- Azadarmaki, R., Tubbs, R., Chen, D.A., Shellock, F.G., 2014b. MRI information for commonly used otologic implants: review and update. *Otolaryngol. Head Neck Surg.* 150, 512–519. <https://doi.org/10.1177/0194599813518306>.
- Baumgartner, W.D., Youssefzadeh, S., Hamzavi, J., Czerny, C., Gstoettner, W., 2001. Clinical application of magnetic resonance imaging in 30 cochlear implant patients, pp. 818–822.
- Bawazeer, N., Vuong, H., Riehm, S., Veillon, F., Charriot, A., 2019. Magnetic resonance imaging after cochlear implants. *J. Otolaryngol.* 14, 22–25. <https://doi.org/10.1016/j.joto.2018.11.001>.
- Broomfield, S.J., Cruz, M. Da, Gibson, W.P.R., Broomfield, S.J., Cruz, M. Da, Gibson, W.P.R., 2013. Cochlear Implants and Magnetic Resonance Scans: A Case Report and Review Cochlear Implants and Magnetic Resonance Scans: A Case Report and Review 0100. <https://doi.org/10.1179/1754762811Y.00000000027>.
- BSI, 2010. Active Implantable Medical Devices. Particular Requirements for Cochlear and Auditory Brainstem Implant Systems. BS EN 45502–2–3:2010.
- Carlson, M.L., Neff, B.A., Link, M.J., Lane, J.I., Watson, R.E., McGee, K.P., Bernstein, M.A., Driscoll, C.L.W., 2015. Magnetic resonance imaging with cochlear implant magnet in place: safety and imaging quality. *Otol. Neurotol.* 36, 965–971. <https://doi.org/10.1097/MAO.0000000000000666>.
- Cass, N.D., Honce, J.M., O’Dell, A.L., Gubbels, S.P., 2019. First MRI with new cochlear implant with rotatable internal magnet system and proposal for standardization of reporting magnet-related artifact size. *Otol. Neurotol.* 40, 883–891. <https://doi.org/10.1097/MAO.0000000000002269>.
- Chen, X., Steckner, M., 2017. Electromagnetic computation and modeling in MRI. *Med. Phys.* 44, 1186–1203. <https://doi.org/10.1002/mp.12103>.
- Cochlear, 2019. Osia MRI Compatibility – Cochlear Americas.
- Commission, I.E., 2014. IEC 62570, Standard Practice for Marking Medical Devices and Other Items for Safety in the Magnetic Resonance Environment.
- Commission, I.E., 2010. IEC 60601 Part 2-33: Particular Requirements for the Basic Safety and Essential Performance of Magnetic Resonance Equipment for Medical Diagnosis.
- Cosmus, T.C., Parizh, M., 2011. Advances in whole-body MRI magnets. *IEEE Trans. Appl. Supercond.* 21, 2104–2109. <https://doi.org/10.1109/TASC.2010.2084981>.
- Crane, B.T., Gottschalk, B., Kraut, M., Aygun, N., Niparko, J.K., 2010. Magnetic Resonance Imaging at 1.5 T after Cochlear Implantation.
- Cuda, D., Murri, A., Succo, G., 2013a. Focused tight dressing does not prevent cochlear implant magnet migration under 1.5 Tesla MRI. *Acta Otorhinolaryngol. Ital.* 33, 133–136.
- Cuda, D., Murri, A., Succo, G., Hospital, S.L., 2013b. Focused tight dressing does not prevent cochlear implant magnet migration under 1.5 Tesla MRI, pp. 133–136.
- Delfino, J.G., Woods, T.O., 2016. New developments in standards for MRI safety testing of medical devices. *Curr. Radiol. Rep.* 4, 28. <https://doi.org/10.1007/s40134-016-0155-y>.
- Demir, E., Dursun, E., Olgun, L., 2019. Can MRI-induced silastic casing tear be repaired without the need for cochlear implant replacement? *Int. J. Pediatr. Otorhinolaryngol.* 124, 161–163. <https://doi.org/10.1016/j.ijporl.2019.06.005>.
- Dyer, R.K., Dormer, K.J., Hough, J.V.D., Nakmal, U., Wickham, R., 2002. Biomechanical influences of magnetic resonance imaging on the SOUNDTEC Direct System implant. *Otolaryngol. Head Neck Surg.* 127, 520–530. <https://doi.org/10.1067/mhn.2002.129895>.
- Edmonson, H.A., Carlson, M.L., Patton, A.C., Watson, R.E., 2018. MR imaging and cochlear implants with retained internal magnets: reducing artifacts near highly inhomogeneous magnetic fields. *Radiographics* 38, 94–106. <https://doi.org/10.1148/rg.2018170135>.
- Erhardt, J.B., Fuhrer, E., Gruschke, O.G., Leupold, J., Wapler, M.C., Hennig, J., Stieglitz, T., Korvink, J.G., 2018. Should patients with brain implants undergo MRI? *J. Neural. Eng.* 15. <https://doi.org/10.1088/1741-2552/aab4e4>.
- Evans, D.G.R., Baser, M.E., Reilly, B.O., Rowe, J., Gleeson, M., Saeed, S., King, A., Kerr, R., Thomas, N., Irving, R., Macfarlane, R., Ferner, R., Mcleod, R., Ramsden, R., Kerr, R., Thomas, N., Irving, R., Macfarlane, R., Ferner, R., Mcleod, R., Moffat, D., Ramsden, R., 2009. Management of the Patient and Family with Neurofibromatosis 2: a Consensus Conference Statement 8697. <https://doi.org/10.1080/02688690500081206>.
- FDA, 2019. Testing and Labeling Medical Devices for Safety in the Magnetic Resonance (MR) Environment Draft Guidance for Industry and Food and Drug Administration Staff 23.
- Fierens, G., Verhaert, N., Benoudiba, F., Bellin, M., Ducreux, D., Papon, J.-F., Nevoux, J., 2020. Stability of the standard inco coupling of the Carina middle ear actuator after 1.5T MRI. *PLoS One* 1–10. <https://doi.org/10.1371/journal.pone.0231213>.
- Fierens, G., Walraevens, J., Peeters, R., Verhaert, N., Glorieux, C., 2019. Feasibility study for measuring unintended acoustic stimulation during MRI. In: Conference Abstract Presented on the 7th International Conference on Bone Conduction and Related Technologies, Miami, USA. Miami Beach.
- Food and Drug Administration, 2019. Code of Federal Regulations, Title 21 - Food and Drugs.
- Food and Drug Administration, 2016a. What Is a Serious Adverse Event? ([WWW Document]).
- Food and Drug Administration, 2016b. Assessment of Radiofrequency- Induced Heating in the Magnetic Resonance (MR) Environment for Multi-Configuration Passive Medical Devices Guidance for Industry andAnd, Guidance for Industry Staff. Food and Drug Administration.
- Fritsch, M.H., Mosier, K.M., n.d. MRI Compatibility Issues in Otology 335–340.
- Fritsch, M.H., Naumann, I.C., Mosier, K.M., 2008. BAHA devices and magnetic resonance imaging scanners. *Otol. Neurotol.* 29, 1095–1099. <https://doi.org/10.1097/MAO.0b013e31818201fd>.
- Gubbels, S.P., McMenomey, S.O., 2006. Safety study of the Cochlear Nucleus?? 24 device with internal magnet in the 1.5 Tesla magnetic resonance imaging scanner. *Laryngoscope* 116, 865–871. <https://doi.org/10.1097/01.MLG.00000216807.03225.CE>.
- Hargreaves, B.A., Worters, P.W., Pauly, K.B., Pauly, J.M., Koch, K.M., Gold, G.E., 2011. Metal-induced artifacts in MRI. *Am. J. Roentgenol.* 197, 547–555. <https://doi.org/10.2214/AJR.11.7364>.
- Hassepas, F., Stabenau, V., Arndt, S., Beck, R., Bulla, S., Grauvogel, T., Aschendorff, A., 2014. Magnet dislocation: an increasing and serious complication following MRI in patients with cochlear implants. *RoFo Fortschritte auf dem Gebiet der Rontgenstrahlen und der Bildgeb. Verfahrenstechnik* 186, 680–685. <https://doi.org/10.1055/s-0033-1356238>.
- Hassepas, Frederike, Stabenau, V., Maier, W., Arndt, S., Laszig, R., Beck, R., Aschendorff, A., 2014. Revision surgery due to magnet dislocation in cochlear implant patients: an emerging complication. *Otol. Neurotol.* 35, 29–34. <https://doi.org/10.1097/MAO.0b013e31818201fd>.

- doi.org/10.1097/MAO.0b013e3182a5d2c5.
- Hochmair, E.S., 2001. MRI safety of Med-El C40/C40+ cochlear implants. *Cochlear Implants Int.* 2, 98–114. <https://doi.org/10.1002/cii.42>.
- Hospital, G., Schmerber, S., 2003. Is magnetic resonance imaging still a contraindication in cochlear-implanted patients?, pp. 293–294. <https://doi.org/10.1007/s00405-002-0568-5>.
- ISO, 2018. Assessment of the safety of magnetic resonance imaging for patients with an active implantable medical device. ISO/TS 10974:2018. *Int. Organ. Stand.* 2018.
- ISO, 2014. Implants for Surgery — Active Implantable Medical Devices — Part 1: General Requirements for Safety, Marking and for Information to Be provided by the Manufacturer. ISO 14708-1:2014.
- Jansson, K.J., Hakansson, B., Reinfeldt, S., Rigato, C., Eeg-Olofsson, M., 2015. Magnetic resonance imaging investigation of the bone conduction implant - a pilot study at 1.5 Tesla. *Med. Dev. Evid. Res.* 8, 413–423. <https://doi.org/10.2147/MDER.S90704>.
- Jeon, J.H., Bae, M.R., Chang, J.W., Choi, J.Y., 2012. Reversing the polarity of a cochlear implant magnet after magnetic resonance imaging. *Auris Nasus Larynx* 39, 415–417. <https://doi.org/10.1016/j.anl.2011.04.018>.
- Jesacher, M.O., Kiefer, J., Zierhofer, C., Fauser, C., 2010. Torque measurements of the ossicular chain: implication on the MRI safety of the hearing implant vibrational soundbridge. *Otol. Neurotol.* 31, 676–680. <https://doi.org/10.1097/MAO.0b013e3181d2d3f3>.
- Jungmann, P.M., Agten, C.A., Pfirrmann, C.W., Sutter, R., 2017. Advances in MRI around metal. *J. Magn. Reson. Imag.* 46, 972–991. <https://doi.org/10.1002/jmri.25708>.
- Kim, B.G., Kim, J.W., Park, J.J., Kim, S.H., Kim, H.N., Choi, J.Y., 2015. Adverse events and discomfort during magnetic resonance imaging in cochlear implant recipients. *JAMA Otolaryngol. Neck Surg.* 141, 45. <https://doi.org/10.1001/jamaoto.2014.2926>.
- Leong, W.J.C., Yuen, H.W., 2018. Dislocation of cochlear implant magnet during 1.5 Tesla magnetic resonance imaging despite head bandaging, and its repositioning using an endoscopic approach. *J. Laryngol. Otol.* 132, 943–945. <https://doi.org/10.1017/S002221518001421>.
- Majdani, O., Rau, T.S., Götz, F., Zimmerling, M., Lenarz, M., Lenarz, T., Labadie, R., Leinung, M., 2009. Artifacts caused by cochlear implants with non-removable magnets in 3T MRI: phantom and cadaveric studies. *Eur. Arch. Oto-Rhino-Laryngol.* 266, 1885–1890. <https://doi.org/10.1007/s00405-009-0994-8>.
- Migirov, L., Wolf, M., 2013. Magnet Removal and Reinsertion in a Cochlear Implant Recipient Undergoing Brain MRI 1–5. <https://doi.org/10.1159/000346239>.
- Moher, D., Liberati, A., Tetzlaff, J., Altman, D.G., Group, T.P., 2009. Preferred reporting items for systematic reviews and meta-analyses: the PRISMA statement. *PLoS Med.* 6, e1000097.
- Nospes, S., Mann, W., 2018. MRI in patients with auditory implants equipped with implanted magnets - an update: overview and procedural management. *Radiologie* 53, 1026–1032. <https://doi.org/10.1007/s00117-018-0462-9>.
- Nospes, S., Mann, W., Keilmann, A., 2013. Magnetresonanztomographie bei Patienten mit magnetversorgten Hörimplantaten: Überblick und prozedurales Management. *Radiologie* 53, 1026–1032. <https://doi.org/10.1007/s00117-013-2570-x>.
- Oticon Medical. Information for MR professionals. <http://www.oticonmedical.com/~asset/cache.ashx?id=11507&type=14&format=web>. (Accessed 26 October 2013) [WWW Document], n.d.
- Öztürk, E., Doruk, C., Orhan, K.S., Çelik, M., Polat, B., Güldiken, Y., 2017. A rare complication of cochlear implantation after magnetic resonance imaging: reversion of the magnet. *J. Craniofac. Surg.* 28, e372–e374. <https://doi.org/10.1097/SCS.00000000000003724>.
- Panych, L.P., Madore, B., 2018. The physics of MRI safety. *J. Magn. Reson. Imag.* 47, 28–43. <https://doi.org/10.1002/jmri.25761>.
- Pelosi, S., Carlson, M.L., Glasscock, M.E., 2014. Implantable hearing devices: the ototronix MAXUM system. *Otolaryngol. Clin.* 47, 953–965. <https://doi.org/10.1016/j.otc.2014.08.003>.
- Pross, S.E., Ward, B.K., Sharon, J.D., Weinreich, H.M., Aygun, N., Francis, H.W., 2018. A prospective study of pain from magnetic resonance imaging with cochlear implant magnets in situ. *Otol. Neurotol.* 39, e80–e86. <https://doi.org/10.1097/MAO.0000000000001661>.
- s Instructions—MRI for BAHAs Patients. http://www.cochlear.com/wps/wcm/connect/36c71ca0-963b-4786-a0a0-072b4090908e/E818971Baha1MRI1Information%2C1GB.pdf?MOD=AJPERES&CONVERT_TO=url&CACHEID=36c71ca0-963b-4786-a0a0-072b4090908e. Accessed (Oct [WWW Document], n.d).
- Reinfeldt, S., Hakansson, B., Taghavi, H., Eeg-Olofsson, M., 2015. New developments in bone-conduction hearing implants: a review. *Med. Dev. Evid. Res.* 8, 79–93. <https://doi.org/10.2147/MDER.S39691>.
- Schnabl, J., Wolf-Magele, A., Pok, S.M., Hirtler, L., Heinz, G., Sprinzl, G.M., 2016. Magnetic resonance imaging compatibility of a new generation of active middle ear implant: a clinically relevant temporal bone laboratory study. *Otol. Neurotol.* 37, e222–e227. <https://doi.org/10.1097/MAO.0000000000001097>.
- Seidman, M.D., Janz, T.A., Shohet, J.A., 2019. Totally implantable Active middle ear implants. *Otolaryngol. Clin.* 52, 297–309. <https://doi.org/10.1016/j.otc.2018.11.011>.
- Shellock, F.G., Woods, T.O., Crues, J.V., 2009. MR labeling information for implants and devices: explanation of terminology. *Radiology* 253, 26–30. <https://doi.org/10.1148/radiol.2531091030>.
- Shew, M., Wichova, H., Lin, J., Ledbetter, L.N., Staecker, H., 2019. Magnetic resonance imaging with cochlear implants and auditory brainstem implants: are we truly practicing MRI safety? *Laryngoscope* 129, 482–489. <https://doi.org/10.1002/lary.27516>.
- Siebert, R., 2011. Partially implantable bone conduction hearing aids without a percutaneous abutment (otomag): technique and preliminary clinical results. *Adv. Oto-Rhino-Laryngol.* 71, 41–46. <https://doi.org/10.1159/000323720>.
- Siebert, R., Kanderske, J., 2013. A new semi-implantable transcutaneous bone conduction device: clinical, surgical, and audiological outcomes in patients with congenital ear canal atresia. *Otol. Neurotol.* 34, 927–934. <https://doi.org/10.1097/MAO.0b013e31828682e5>.
- Srinivasan, R., So, C.W., Amin, N., Jaikaransingh, D., D'Arco, F., Nash, R., 2019. A review of the safety of MRI in cochlear implant patients with retained magnets. *Clin. Radiol.* <https://doi.org/10.1016/j.crad.2019.06.011>.
- Steinmetz, C., Mader, I., Arndt, S., Aschendorff, A., Laszig, R., Hassepass, F., 2014. MRI artefacts after Bonebridge implantation. *Eur. Arch. Oto-Rhino-Laryngol.* 271, 2079–2082. <https://doi.org/10.1007/s00405-014-3001-y>.
- Sudhoff, H., Riemann, C., Gehl, H.B., Todt, I., 2020. MRI pattern of various cochlear implant electrodes in vivo. *Ann. Otol. Neurotol.* 3–7. <https://doi.org/10.1055/s-0040-1708796>.
- Suetens, P., 2017. *Fundamentals of Medical Imaging*, third ed. Cambridge University Press. <https://doi.org/10.1017/9781316671849>.
- Tam, Y.C., Graves, M.J., Black, R.T., Kenway, B., Donnelly, N., Gray, R.F., Axon, P.R., Joubert, I., 2010. Magnetic resonance imaging in patients with cochlear implants and auditory brain stem implants. *Cochlear Implants Int.* 48–51. <https://doi.org/10.1179/146701010X12726366067734>.
- Tam, Y.C., Graves, M.J., Black, R.T., Kenway, B., Gray, R.F., Axon, P.R., Joubert, I., Chuen, Y., Graves, M.J., Black, R.T., Kenway, B., Tam, Y.C., Joubert, I., 2013. Magnetic Resonance Imaging in Patients with Cochlear Implants and Auditory Brain Stem Implants. *Magnetic Resonance Imaging in Patients with Cochlear Implants and Auditory Brain Stem Implants* 0100. <https://doi.org/10.1179/146701010X12726366067734>.
- Tam, Y.C., Lee, J.W.Y., Gair, J., Jackson, C., Donnelly, N.P., Tysome, J.R., Axon, P.R., Bance, M.L., 2020. Performing MRI scans on cochlear implant and auditory brainstem implant recipients: review of 14.5 Years experience. *Otol. Neurotol.* 41, e556–e562. <https://doi.org/10.1097/MAO.0000000000002569>.
- Teissl, C., Kremser, C., Hochmair, E.S., Hochmair-Desoyer, I.J., 1999. Magnetic resonance imaging and cochlear implants: compatibility and safety aspects. *J. Magn. Reson. Imag.* [https://doi.org/10.1002/\(SICI\)1522-2586\(199901\)9:1<26::AID-JMRI4>3.0.CO;2-H](https://doi.org/10.1002/(SICI)1522-2586(199901)9:1<26::AID-JMRI4>3.0.CO;2-H).
- Teissl, C., Kremser, C., Hochmair, E.S., Hochmair-Desoyer, I.J., 1998. Cochlear implants: in vitro investigation of electromagnetic interference at MR imaging - compatibility and safety aspects. *Radiology.* <https://doi.org/10.1148/radiology.208.3.9722849>.
- Todt, I., Rademacher, G., Grupe, G., Stratmann, A., Ernst, A., Mutze, S., Mittmann, P., 2018. Cochlear implants and 1.5 T MRI scans: the effect of diametrically bipolar magnets and screw fixation on pain. *J. Otolaryngol. - Head Neck Surg.* 47, 10–13. <https://doi.org/10.1186/s40463-017-0252-9>.
- Todt, I., Rademacher, G., Mittmann, P., Wagner, J., Mutze, S., Ernst, A., 2015. MRI artifacts and cochlear implant positioning at 3 T in vivo. *Otol. Neurotol.* 36, 972–976. <https://doi.org/10.1097/MAO.0000000000000720>.
- Todt, I., Rademacher, G., Wagner, F., Schedlbauer, E., Wagner, J., Basta, D., Ernst, A., 2011. MRI safety of the floating mass transducer. *Cochlear Implants Int.* 12 (Suppl. 1) <https://doi.org/10.1179/146701011x13001036693395>.
- Todt, I., Tittel, A., Ernst, A., Mittmann, P., Mutze, S., 2017. Pain free 3 T MRI scans in cochlear implantees. *Otol. Neurotol.* 38, e401–e404. <https://doi.org/10.1097/MAO.0000000000001569>.
- Tysome, J.R., MacFarlane, R., Durie-Gair, J., Donnelly, N., Mannion, R., Knight, R., Harris, F., Vanat, Z.H., Tam, Y.C., Burton, K., Hensiek, A., Raymond, F.L., Moffat, D.A., Axon, P.R., 2012. Surgical management of vestibular schwannomas and hearing rehabilitation in neurofibromatosis type 2. *Otol. Neurotol.* 33, 466–472. <https://doi.org/10.1097/MAO.0b013e318248eaa>.
- Utrilla, C., Gavilán, J., García-Raya, P., Calvino, M., Lassaletta, L., 2020. MRI after Bonebridge implantation: a comparison of two implant generations. *Eur. Arch. Oto-Rhino-Laryngol.* <https://doi.org/10.1007/s00405-020-06380-2>.
- Vanderauwera, J., Hellems, E., Verhaert, N., 2019. *Reviewing Research Insights on the Neural Effects of Auditory Deprivation and Restoration in Unilateral Hearing Loss*, pp. 1–19.
- Walker, B., Norton, S., Phillips, G., Christianson, E., Horn, D., Ou, H., 2018. Comparison of MRI in pediatric cochlear implant recipients with and without retained magnet. *Int. J. Pediatr. Otorhinolaryngol.* 109, 44–49. <https://doi.org/10.1016/j.ijporl.2018.03.013>.
- Walton, J., Donnelly, N.P., Tam, Y.C., Joubert, I., Durie-Gair, J., Jackson, C., Mannion, R.A., Tysome, J.R., Axon, P.R., Scoffings, D.J., 2014. MRI without magnet removal in neurofibromatosis type 2 patients with cochlear and auditory brainstem implants. *Otol. Neurotol.* 35, 821–825. <https://doi.org/10.1097/MAO.0000000000000330>.
- Wimmer, W., Hakim, A., Kiefer, C., Pastore-Wapp, M., Anschuetz, L., Caversaccio, M.D., Wagner, F., 2019. MRI Metal artifact reduction sequence for auditory implants: first results with a transcutaneous bone conduction implant. *Audiol. Neurotol.* 24, 56–64. <https://doi.org/10.1159/000500513>.
- Woods, T.O., 2014. Guidance for industry and FDA staff establishing safety and compatibility of passive implants in the magnetic resonance (MR) environment. *U.S. Food Drug Adm.* 1–7.
- Yang, J., Wang, Z., Huang, M., Chai, Y., Jia, H., Wu, Y., Dai, Y., Li, Y., Wu, H., 2018. BoneBridge implantation in patients with single-sided deafness resulting from vestibular schwannoma resection: objective and subjective benefit evaluations.

- Acta Otolaryngol. 138, 877–885. <https://doi.org/10.1080/00016489.2018.1469789>.
- Young, N.M., Hoff, S.R., Ryan, M., 2020. Impact of cochlear implant with diametric magnet on imaging access, safety, and clinical care. *Laryngoscope* 1–5. <https://doi.org/10.1002/lary.28854>.
- Young, N.M., Rojas, C., Deng, J., Burrowes, D., Ryan, M., 2016. Magnetic resonance imaging of cochlear implant recipients. *Otol. Neurotol.* 37, 665–671. <https://doi.org/10.1097/MAO.0000000000001053>.
- Youssefzadeh, S., Baumgartner, W., Dorffner, R., Gstöttner, W., Trattnig, S., 1998. MR compatibility of Med EL cochlear implants: clinical testing at 1.0 T. *J. Comput. Assist. Tomogr.* <https://doi.org/10.1097/00004728-199805000-00002>.