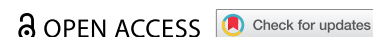




CASE REPORT



## A rare case of an infected aortoiliac graft complicated with *Eggerthella lenta* bacteremia and septic shock

Harith A. Alataby <sup>a</sup>, Lloyd G. Muzangwa<sup>a</sup>, Muhamed K. Atere <sup>a</sup>, Joseph Bibawy <sup>b</sup>, Keith T. Diaz<sup>a,b,c</sup> and Jay M. Nfonoyim<sup>a,b,c</sup>

<sup>a</sup>Department of Medicine, Richmond University Medical Center, Staten Island, NY, USA; <sup>b</sup>Department of Radiology, Richmond University Medical Center, Staten Island, NY, USA; <sup>c</sup>Department of Critical Care, Richmond University Medical Center, Staten Island, NY, USA

### ABSTRACT

We describe the successful medical management of an infected aorto-bi-iliac endograft. In this case report, we provide an example of a patient with an infected aorto-bi-iliac endograft and how appropriate medical management may result in a positive outcome. We report a case of a 67-year-old man with several medical comorbidities who developed aorto-bi-iliac endograft infection one year after graft placement. The patient presented to our E.R. with fever, lethargy, tachycardia, tachypnea, and hypotension. The diagnosis of an infected endograft was established after excluding any other possible source of infection plus the strong radiological evidence by computed tomographic scan and WBCs labeled Indium-111 tropo-lone scan. Blood cultures revealed the development of *Eggerthella lenta*, *Escherichia coli* Extended-spectrum beta-lactamase (ESBL), and *Enterococcus Faecalis*. To our knowledge, this is a rare case of an infected endograft and bacteremia due to *Eggerthella lenta*. After the administration of vancomycin and Meropenem, no improvements were noted to the patient's clinical condition. However, upon the administration of Tigecycline, the patient's clinical condition improved. Two days later, repeat blood cultures were negative.

After completion of the course of antibiotics and stabilization of other comorbidities, the patient was discharged home with long term antibiotic therapy under close control of inflammation markers.

### ARTICLE HISTORY

Received 13 February 2020  
Accepted 13 July 2020

### KEYWORDS

Aortoiliac graft; endovascular aneurysm repair (EVAR); sepsis; *Eggerthella lenta*; infected Aortoiliac graft management

## 1. Introduction

Infection of aortoiliac endograft is, to date, a rare complication after endovascular aneurysm repair (EVAR) [1,2,3]. Endograft infection with an aorto-duodenal fistula is usually the reported long-term complication of (EVAR) [4,5]. Staphylococcus species, Streptococcus species, and Escherichia coli were the most common isolated microorganisms [6]. Staphylococcus species are the most common responsible pathogens [7].

The diagnosis of an infected endograft is based on an association of clinical symptoms, radiologic imaging, and microbial cultures. Angio-computed tomography is currently the gold-standard technique for diagnosis. Low-grade infection sometimes requires nuclear medicine imaging to make a correct diagnosis [8]. As the number of patients with endovascular aneurysm repair has increased over the last decade, the number of patients with endograft infection might also have increased [9,10]. However, no guideline defines the treatment of endograft infection [9].

Surgical treatment with complete explantation of the infected endograft seems to be the preferred management in selected patients [1,11].

Supportive medical treatment without surgical intervention is thought to have significant associated mortality [1]. There are sporadic case reports; however, difficulties remain in ensuring prompt diagnosis and determining the optimum treatment strategy. Conservative, non-resectional management of graft infection is still a reasonable solution for selected patients, as those with significant comorbidities [12], or those where the implanted aortic graft is in a location that precludes excision without causing a high likelihood of morbidity and/or mortality [13,14].

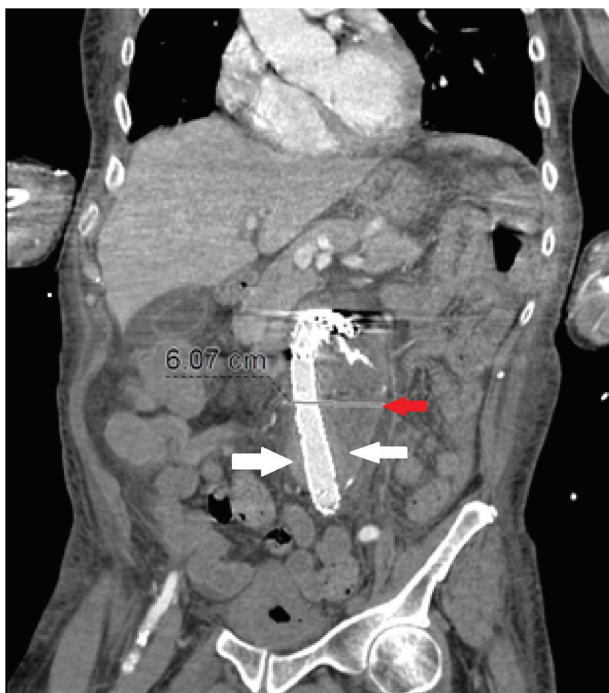
## 2. Case presentation

The patient is a 67-year-old male with several medical comorbidities who presented to our E.D. with fever, lethargy, tachycardia, tachypnea, and hypotension. The patient had aorto-bi-iliac graft replacement placement for Abdominal Aortic Aneurysm(AAA) one year prior. AAA repair was complicated with paraplegia and graft leaking treated with embolization. On physical examination, the patient was minimally responsive unable to maintain the airway with minimal peri-umbilical tenderness with deep

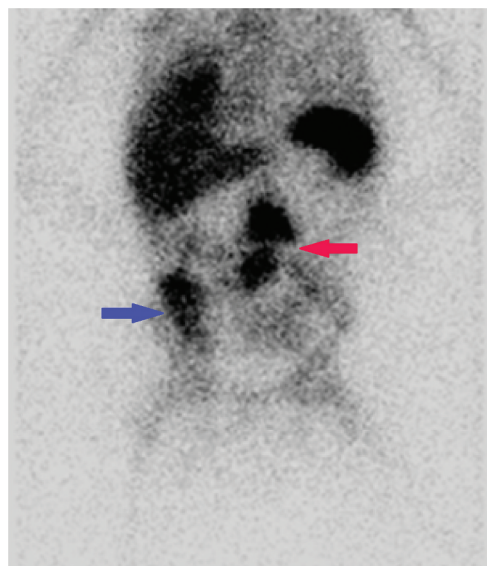
palpation without peritoneal signs. Emergent intubation was done, and the patient was transferred to the medical critical care unit.

White blood cell count was 17,000/ $\mu$ L; Hemoglobin 9.6 g/dL, platelet count 300,000/ $\mu$ L, BUN 66 mg/dL, Cr 2.1 mg/dL, minimal elevation of troponin and normal level of electrolytes. Diagnosis of severe sepsis and septic shock of unknown source was made. The patient received empirical treatment of vancomycin and Meropenem. Urine cultures, respiratory culture were all negative for any bacterial growth; however, blood culture demonstrated *Eggerthella lenta*, *Escherichia coli* Extended-spectrum beta-lactamase (ESBL), and *Enterococcus Faecalis*. A transesophageal echocardiogram was performed and revealed no vegetation. Abdominal computed tomography (C.T.) with contrast demonstrated inflammatory changes around aorto-bi-iliac graft, as shown in Figure 1 with no aortoenteric fistula. To identify the inflammation site impression, Indium-111 WBC scan was performed and showed abnormally increased activity in the mid to lower abdomen in the midline also shown in Figure 2.

Vascular surgery extensively evaluated the patient for graft replacement surgery. However, given the unstable condition of the patient, vascular interventions were deferred. Due to the patient's frail condition, we chose a less invasive and conservative strategy. Seven days' course of IV antibiotics vancomycin (1 g daily) and Meropenem (1 g twice a day)



**Figure 1.** C.T. abdomen and pelvis with IV contrast reveals an approximately 6 cm infra-renal aortic aneurysm repaired with an intra-aortic stent-graft placement (red arrow). There was noted to be a subtle peri-aortic enhancement that represents edema and would indicate an infected graft (white arrow).



**Figure 2.** Indium-111 WBC scan: Autologous WBCs labeled Indium-111 tropolone administered intravenously reveals increased uptake in the mid-abdomen (Red arrow) in the region of the intra-aortic graft signifying increased inflammatory activity consistent with infection at the 24-hour scan. Increased uptake in the right lower abdomen (blue arrow) represents colitis. Otherwise, there is normal uptake in the liver, spleen, and bone marrow.

were administered; however, the patient continued to have a spiking of fever and was unable to be weaned from mechanical ventilation. Repeat blood culture drawn during the same period grew the same bacteria (*Eggerthella lenta*, *Escherichia coli* Extended-spectrum beta-lactamase (ESBL), and *Enterococcus Faecalis*). The antibiotic regimen was changed to Tigecycline (50 mg twice a day), which was administered for 14 days. Two days after conducting Tigecycline, repeat blood cultures were negative. After completion of the course of antibiotics and stabilization of other comorbidities, the patient was discharged home with long term antibiotic therapy under close control of inflammation markers.

### 3. Discussion

The incidence of endograft infection is below 1%, with a mortality rate of 25% [15]. Publications report high mortality after conservative therapy of endograft infection. There is evidence for lower mortality in patients who underwent surgery [6,9]. The gold standard for aortic endograft infection includes the excision of infected endograft, debridement, and reconstruction. However, these methods are not always the best option for patients with poor clinical status [16]. Although the consensus is that infected graft material should always be removed [17].

This case shows that there may be a role for conservative treatment in selected cases of patients with an infected endograft [18]. Expert opinion previously

suggested removal of the infected graft, anatomical revascularization, and antibiotic therapy are important for long term survival after aortic endograft infection [19]. Conservative therapy is only warranted in patients unsuitable for surgical treatment [12,20,21].

Another very important aspect, in this case, is the *Eggerthella lenta* bacteremia in the absence of an aortoenteric fistula. *Eggerthella lenta* is an anaerobic, non-sporulating, Gram-positive bacilli from the normal human gut flora that can occasionally be implicated in invasive diseases. The evidence of the presence of colitis in the Indium-111 WBC scan could be the source of *Eggerthella lenta* bacteremia also could be supported by the demonstration of the other two bacteria (*Escherichia coli* Extended-spectrum beta-lactamase (ESBL), and *Enterococcus Faecalis*) that all consider as normal gastrointestinal flora [22].

Nuclear medicine imaging can be used to aid and make a correct diagnosis [8,23]. In our case, C. T. abdomen and pelvis with IV contrast reveals an approximately 6 cm infra-renal aortic aneurysm repaired with an intra-aortic stent-graft placement. There was noted to be a subtle peri-aortic enhancement that represents edema and would indicate an infected graft, as shown in Figure 1. Similarly, autologous WBCs labeled Indium-111 tropolone administered intravenously reveals increased uptake in the mid-abdomen at the region of the intra-aortic graft signifying increased inflammatory activity consistent with infection at 24-hour scan, as shown in Figure 2.

#### 4. Conclusion

We describe a case of successful medical management of an infected endograft in our patient. There is a role for conservative treatment in selected cases of patients with infected endograft such as our patient. We also highlight the need for a multidisciplinary approach for the management of infected endograft. Nuclear medicine imaging can be used to aid and make a correct diagnosis. Long term antibiotic therapy under close control of inflammation markers is needed post conservative treatment of infected endograft.

#### Disclosure statement

No potential conflict of interest was reported by the authors.

#### Funding

No fund was provided to perform this case study

#### A statement of manuscript approval

We (the Authors) approve that the manuscript was read and approved by all of us (the Authors), and we believe that the manuscript represents honest work.

#### Contribution

H. Alataby, L. Muzangwa, and M. Atere participated in patient care, collected the data, guided the literature search, and wrote the manuscript, K. Diaz and J. Nfonoyim edited and reviewed the manuscript, and J. Bibawy provided the radiologic imagings and explanations.

#### Purpose

We are reporting this case for its rarity. We highlight the difficulties and challenges in the management of such infections in settings where surgical management is high risk. We also describe our successful medical management of an infected endograft in our patient.

#### ORCID

Harith A. Alataby  <http://orcid.org/0000-0002-5311-2888>  
 Muhamed K. Atere  <http://orcid.org/0000-0001-9393-7182>  
 Joseph Bibawy  <http://orcid.org/0000-0002-5111-4863>

#### References

- [1] Argyriou C, Georgiadis GS, Lazarides MK, et al. Endograft infection after endovascular abdominal aortic aneurysm repair: a systematic review and meta-analysis. *J Endovasc Ther.* 2017;24(5):688–697.
- [2] Schaefer JF, Donas KP, Panuccio G, et al. Outcomes of surgical explantation of infected aortic grafts after endovascular and open abdominal aneurysm repair. *Eur J Vasc Endovasc Surg.* 2019;57(1):130–136.
- [3] Murphy EH, Szeto WY, Herdrich BJ, et al. The management of endograft infections following endovascular thoracic and abdominal aneurysm repair. *J Vasc Surg.* 2013;58(5):1179–1185.
- [4] Lickman D, Winterborn R, Hardman J, et al. Infected endograft with endograft-duodenal fistula following endovascular repair of abdominal aortic aneurysm. *EJVES Extra.* 2011;22(2):e12–e14.
- [5] Chaufour X, Gaudric J, Goueffic Y, et al. A multicenter experience with infected abdominal aortic endograft explantation. *J Vasc Surg.* 2017;65(2):372–380.
- [6] Moulakakis KG, Sfyroeras GS, Mylonas SN, et al. Outcome after preservation of infected abdominal aortic endografts. *J Endovasc Ther.* 2014;21(3):448–455.
- [7] Bakoyiannis CN, Georgopoulos SE, Tsekouras NS, et al. Fungal infection of aortoiliac endograft: a case report and review of the literature. *Ann Vasc Surg.* 2007;21(2):228–231.
- [8] Setacci C, Chisci E, Setacci F, et al. How to diagnose and manage infected endografts after endovascular aneurysm repair. *Aorta (Stamford).* 2014;2(6):255–264.
- [9] Betz T, Töpel I, Steinbauer M, et al. Management of endograft infection after EVAR and TEVAR - a case

- series and literature review. *Zentralbl Chir.* 2017;142(5):506–515.
- [10] Fiorani P, Speziale F, Calisti A, et al. Endovascular graft infection: preliminary results of an international enquiry. *J Endovasc Ther.* 2003;10(5):919–927.
- [11] Fatima J, Duncan AA, de Grandis E, et al. Treatment strategies and outcomes in patients with infected aortic endograft. *J Vasc Surg.* 2013;58(2):371–379.
- [12] Laohapensang K, Arworn S, Orrapin S, et al. management of the infected aortic endograft. *Semin Vasc Surg.* 2017;30(2–3):91–94.
- [13] de Donato G, Setacci F, Galzerano G, et al. Prosthesis infection: prevention and treatment. *J Cardiovasc Surg (Torino).* 2014;55(6):779–792.
- [14] Fernandez Prendes C, Riedemann Wistuba M, Zanabili Al-Sibbai AA, et al. Infra-renal aortic endograft infection: a single-center experience. *Vasc Endovascular Surg.* 2019;53(2):132–138.
- [15] Cernohorsky P, Reijnen MMPJ, Tielliu IFJ, et al. The relevance of aortic endograft prosthetic infection. *J Vasc Surg.* 2011;54(2):327–333.
- [16] Yoneyama F, Sato F, Sakamoto H, et al. Preservation of the infected thoracic aortic endograft with thoracoscopic drainage and continuous irrigation. *Gen Thorac Cardiovasc Surg.* 2019;67(2):259–262.
- [17] Kahlberg A, Grandi A, Loschi D, et al. A systematic review of infected descending thoracic aortic grafts and endografts. *J Vasc Surg.* 2019;69(6):1941–1951 e1.
- [18] Nakai M, Sato H, Sato M, et al. Successful endovascular treatment of iliac arteriovesical fistula with secondary stent-graft infection. *J Vasc Interv Radiol.* 2013;24(9):1409–1412.
- [19] Smeds MR, Duncan AA, Harlander-Locke MP, et al. treatment and outcomes of aortic endograft infection. *J Vasc Surg.* 2016;63(2):332–340.
- [20] Fan EY, Judelson DR, Schanzer A. Explantation of infected thoracic endovascular aortic repair. *J Vasc Surg Cases Innov Tech.* 2018;4(4):307–310.
- [21] Wang SK, Fajardo A, Motaganahalli RL, et al. Successful treatment of an infected zenith fenestrated endograft without explantation. *Vasc Endovascular Surg.* 2018;52(7):569–572.
- [22] Jehangir W, Sanabria F, Singh Z, et al. Enteric fistulous communication with an aortobifemoral graft permitting for *Eggerthella lenta* colonization. *J Glob Infect Dis.* 2015 Oct-Dec;7(4):170–172.
- [23] Berchiolli R, Mocellin DM, Marconi M, et al. Ruptured mycotic aneurysm after intravesical instillation for bladder tumor. *Ann Vasc Surg.* 2019;59:310 e7–310 e11.