

Assessment of endodontically treated teeth by using different radiographic methods: an ex vivo comparison between CBCT and other radiographic techniques

Kemal Özgür Demiralp, Kıvanç Kamburoğlu*, Kahraman Güngör, Selcen Yüksel**, Gokcen Demiralp***, Özlem Üçok

Department of Dentomaxillofacial Radiology, Faculty of Dentistry, Gazi University, Ankara, Turkey

*Department of Dentomaxillofacial Radiology, Faculty of Dentistry, Ankara University, Ankara, Turkey

**Department of Biostatistics, Faculty of Medicine, Ankara University, Ankara, Turkey

***Department of Endodontics, Tepebasi Dental Health Center, Ankara, Turkey

ABSTRACT

Purpose: To compare different radiographic methods for assessing endodontically treated teeth.

Materials and Methods: Root canal treatments were applied in 120 extracted mandibular teeth, which were divided into four groups: (1) ideal root canal treatment (60 teeth), (2) insufficient lateral condensation (20 teeth), (3) root canals filled short of the apex (20 teeth), (4) overfilled root canal treatment (20 teeth). The teeth were imaged using intraoral film, panoramic film, digital intraoral systems (CCD and PSP), CCD obtained with portable X-ray source, digital panoramic, and CBCT images obtained at 0.3 mm³ and 0.2 mm³ voxel size. Images were evaluated separately by three observers, twice. Kappa coefficients were calculated. The percentage of correct readings obtained from each modality was calculated and compared using a t-test (p < 0.05).

Results: The intra-observer kappa for each observer ranged between 0.327 and 0.849. The inter-observer kappa for each observer for both readings ranged between 0.312 and 0.749. For the ideal root canal treatment group, CBCT with 0.2 mm³ voxel images revealed the best results. For insufficient lateral condensation, the best readings were found with periapical film followed by CCD and PSP. The assessment of teeth with root canals filled short of the apex showed the highest percentage of correct readings by CBCT and CCD. For the overfilled canal treatment group, PSP images and conventional periapical film radiographs had the best scores.

Conclusion: CBCT was found to be successful in the assessment of teeth with ideal root canal treatment and teeth with canals filled short of the apex. (*Imaging Sci Dent 2012; 42 : 129-37*)

KEY WORDS: Root Canal Therapy; Radiography, Dental; Cone-Beam Computed Tomography

Introduction

For successful endodontic treatment, the root canal system should be isolated from the periodontal ligament space and bone by sealing it completely with an appropriate root filling material. Thereby, endodontic effects that threaten the health of periapical tissues can be eliminated.¹ The main aim of root canal treatment is completely removing debris

and microorganisms from root canal system and then filling it with a material which is biologically inert and has stability in length.²

Successful endodontic treatment mainly depends on disinfection of the root canal system, prevention of leakage of bacteria from the oral environment to the periapical tissues, and the complete filling of the root canal system until the apical constriction in three dimensions with an inert, stable in length, and biologically coherent material.³ Properly performed root canal fillings also prevent contamination with bacteria from coronal leakage.⁴ Ideal root canal filling material should adapt to the root canal wall perfectly and all canals should be filled with homogenized gutta-

Received March 1, 2012; Revised June 11, 2012; Accepted June 30, 2012

Correspondence to : Dr. Kıvanç Kamburoğlu

Department of Dentomaxillofacial Radiology, Faculty of Dentistry, Ankara University, 06500, Beşevler, Ankara, Turkey

Tel) 90-312-2965632, Fax) 90-312-2123954, E-mail) dtkivo@yahoo.com

Copyright © 2012 by Korean Academy of Oral and Maxillofacial Radiology

This is an Open Access article distributed under the terms of the Creative Commons Attribution Non-Commercial License (<http://creativecommons.org/licenses/by-nc/3.0/>) which permits unrestricted non-commercial use, distribution, and reproduction in any medium, provided the original work is properly cited.

Imaging Science in Dentistry • pISSN 2233-7822 eISSN 2233-7830

percha.⁵

Two-dimensional conventional and digital intraoral radiography are most commonly used for the assessment of endodontic treatments. Digital radiography was shown to be beneficial in endodontic treatments. Regardless of the intraoral system used, the two-dimensional nature of images limits the information that can be obtained and their diagnostic value is dependent upon beam angulation, superimposition of anatomical structures, and patient-related factors.⁶ Upon radiographic evaluation, depending on the X-ray beam angulation and tooth position, even an improper root canal treatment with insufficient condensation and adaptation can be assumed appropriate.⁷ Conventional intraoral film consists of silver halide crystals in order to produce analog images. On the other hand, digital intraoral systems include a photostimulable phosphor-coated plate (PSP), a solid state silicon chip such as a charge-coupled device (CCD), and a complementary metal oxide semiconductor (CMOS) that uses a scintillator layer to convert X-rays to light. PSP absorbs and stores the energy from X-rays. This energy is released as phosphorescence when stimulated by another light of an appropriate wavelength. These systems offer reduced radiation dosage, shorter exposure time, image enhancement, and ease of storage, retrieval, and communication.⁸⁻¹⁰

Recently, portable hand-held dental X-ray units have become available in the dental field. Their small camera-like design and light weight make them easy to use, especially for forensic and military purposes. Their integrated battery supplies the electrical power for convenient cordless operation. Furthermore, this wireless power supply makes the devices more independent of fixed electric current sources. Together with digital image sensors, this type of machine ensures quick and fully digitized data collection.^{11,12} A previous study found that the use of a NOMAD hand-held device resulted in a very low radiation exposure to the patient and operator, and the measured doses were below recommended limits.¹³

There are also numerous film-based and digital panoramic systems in routine clinical practice. Panoramic radiography is a simple method of obtaining images by synchronous rotation of the X-ray source and image receptor around the stationary patient. Broad coverage of both jaws and teeth are obtained without anatomical detail available on intraoral periapical radiographs.¹⁴⁻¹⁶

If two-dimensional conventional radiographic methods are insufficient and fail to provide the necessary information, cone beam computed tomography (CBCT) imaging should be taken into consideration.¹⁷ CBCT uses a cone-

shaped X-ray beam centered on a two-dimensional (2D) sensor to scan a 180°-360° rotation around the patient's head to acquire a full 3D volume of data. The main advantage of using CBCT for endodontic applications is that it can provide three dimensional (3D) views which intraoral and panoramic radiography cannot provide.^{17,18} Although CBCT eliminates many disadvantages of intraoral radiography, it must be taken into consideration that the patient receives higher radiation doses compared with intraoral and panoramic radiography. Therefore, the CBCT should be used only if conventional methods are not useful for diagnostic accuracy.^{17,18}

Considering the importance of radiographic root canal treatment assessment and possible differences between various radiographic methods, the aim of this *ex vivo* study was to assess the diagnostic potential of intraoral conventional and digital radiography, panoramic radiography, and CBCT in the detection of teeth with ideal or non-ideal root canal treatment.

Materials and Methods

Our study included 120 mandibular incisors (n=48), canines (24), and premolars (48), single rooted teeth with and without dental caries that had been extracted for periodontal or orthodontic reasons. The teeth were cleansed of calculus and debris, disinfected in 2% NaOCl solution for 20 minutes and stored in distilled water. Root pulps were removed by use of trinerve. Afterwards, the working length was determined with a #15 H file and was pushed to the foramen until the file was visible and then pulled back 1 mm. A #40 H file at the apical third and a #80 H file at the coronal third were used with the step back technique. During the preparation, the root canals were irrigated with 2 mL EDTA and 2 mL 2.5% NaOCl using dental injectors. Finally, 2 mL 2.5% NaOCl, 2 mL saline, 2 mL 17% EDTA, and 2 mL saline were applied. After irrigation, all of the canals were dried with paper points (Sure-endo, Sure Dent Corp., Seongnam, Korea).

The teeth were divided into four groups according to the type of root canal treatment applied: (1) ideal root canal treatment (60 teeth), (2) insufficient lateral condensation (20 teeth), (3) root canals filled short of the apex (20 teeth), and (4) overfilled root canals (20 teeth). All of the specimens were filled with AH26 (Dentsply Maillefer, Tulsa, OK, USA) and gutta percha with the lateral condensation technique according to its group specifications. After the gutta percha was cut, all of the specimens were stored in petri plates with damp cotton at 37°C to harden the root

canal filling material. Randomly selected teeth were placed in the appropriate sockets of dry mandibles in groups of 10 (four incisors, two canines, and four premolars) with their crowns visible and proximal surfaces in contact where possible. The selected dry mandible had two molars on the right and one molar on the left side. A 2 cm thick plastic glove filled with distilled water was placed around the dry mandible in order to simulate soft tissue. The teeth were imaged by use of the following methods: 1. intraoral conventional radiograph using film, 2. panoramic radiograph using film, 3. digital intraoral systems (CCD and PSP), 4. direct digital radiograph (CCD) obtained with portable X-ray unit, 5. digital panoramic radiograph, and 6. CBCT images obtained with 0.3 mm^3 and 0.2 mm^3 voxel size. All intraoral images were obtained with a standardized paralleling technique and a focus-receptor distance of 30 cm.

1. Intraoral conventional radiographs were taken using a Heliodont DS (Sirona, Bensheim, Germany) X-ray unit operated at 70 kVp and 7 mA for 0.40 seconds with Kodak (Kodak, Rochester, NY, USA) E-speed (#2 sized) film.

2. Conventional panoramic radiographs were taken using a Planmeca Proline (Planmeca Co., Helsinki, Finland) operated at 75 kVp and 10 mA.

Intraoral and panoramic films were processed immediately after exposure using a Velopex, (Extra-X Medivance Instruments Ltd., London, UK) automatic processing machine and fresh chemicals according to the manufacturer's specifications.

3. Digital intraoral images were obtained with the same X-ray unit used for film images, Heliodont DS (Sirona, Bensheim, Germany) operated at 70 kVp and 7 mA. The digital intraoral systems were a Dr. Suni (#1 sized) direct digital intraoral CCD sensor (Suni Medical Imaging, San Joe, CA, USA) with 0.08 seconds exposure time and a #2 sized Digora Optime (Digora, Tuusula, Finland) PSP digi-

tal intraoral system, which included a feature that automatically erased residual image signals with 0.08 seconds exposure time. The exposed phosphor plates were scanned immediately after exposure.

4. Direct digital radiograph (DDR) obtained with portable X-ray source technique

Direct digital intraoral images were also obtained using a #1 sized Dr. Suni direct digital intraoral CCD sensor with a portable X-ray unit Dexcowin DX3000 (Dexcowin Co., Seoul, Korea) operated at 60 kVp and 1 mA for 0.08 seconds.

5. Digital panoramic radiography

Digital panoramic images were exposed with a Planmeca Proline XC (Planmeca Co., Helsinki, Finland) panoramic X-ray unit operated at 60 kVp and 4 mA.

6. CBCT images

CBCT images were obtained using an ILUMA ultra cone beam CT scanner (3M Imtec, Ardmore, OK, USA) with a $24.4 \times 19.5 \text{ cm}$ amorphous silicon flat-panel image detector and a cylindrical volume of reconstruction up to $21.2 \times 14.2 \text{ cm}$. Images were obtained at 120 kVp, 3.8 mA with an exposure time of 40 seconds. Thereafter, volumetric data were reconstructed with voxel sizes of 0.3 mm^3 and 0.2 mm^3 to provide serial coronal and sagittal sections.

Figure 1 shows the examples of the intraoral radiographs of the mandibular teeth with different root canal treatments applied. Figures 2A and B show the conventional and digital panoramic images, respectively, of the same group of teeth shown in Figure 1. Figure 3 shows the images obtained with a CBCT unit reconstructed by 0.2 mm^3 voxel of the teeth shown in Figure 1.

All images were evaluated separately by two oral radiologists and one endodontist. The intra-observer agreement was assessed by having each observer view all of the images twice, with a two week interval between viewings to

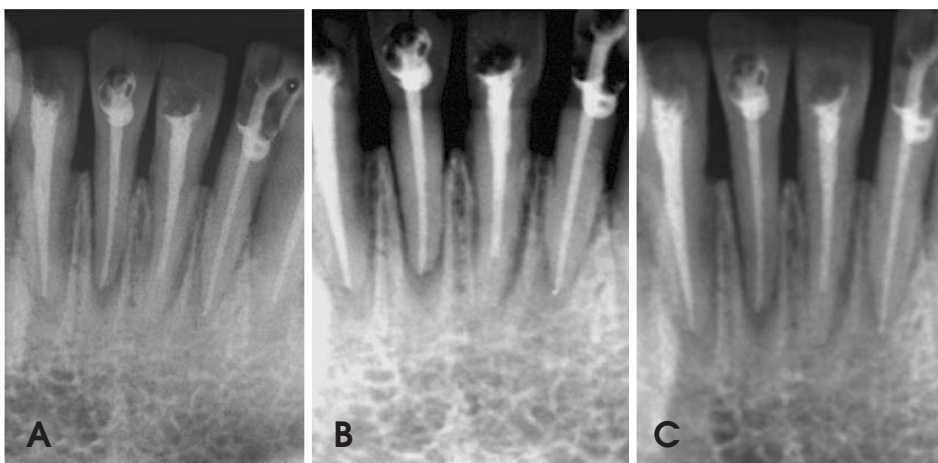


Fig. 1. The images show the different root canal treatments obtained from intraoral techniques. A. Conventional periapical film (Kodak E Speed), B. CCD sensor (Dr. Suni), C. PSP sensor (Digora). From the left: right mandibular lateral incisor with ideal root canal treatment, right mandibular central incisor with insufficient condensation, left mandibular central incisor tooth with root canals filled short of the apex and left mandibular lateral incisor with overfilled root canal treatment.

eliminate memory bias. All of the observers were informed of the evaluation criteria. All of the images were viewed at random in a dimly lit room. The visibility of the enamel, bone trabeculation, and dentine were used as the indicators of image quality for all imaging techniques and were decided upon with the consensus of all of the observers. The

conventional images were evaluated against a light box using a 2 × magnifier. All digital images were evaluated on a 17 inch Philips Energy Star monitor (Philips Electronics Industries Ltd., Taoyuan County, Taiwan) set at a screen solution of 1,440 × 900 pixels and 32 bit color depth using each system's own software and enhancement tools.

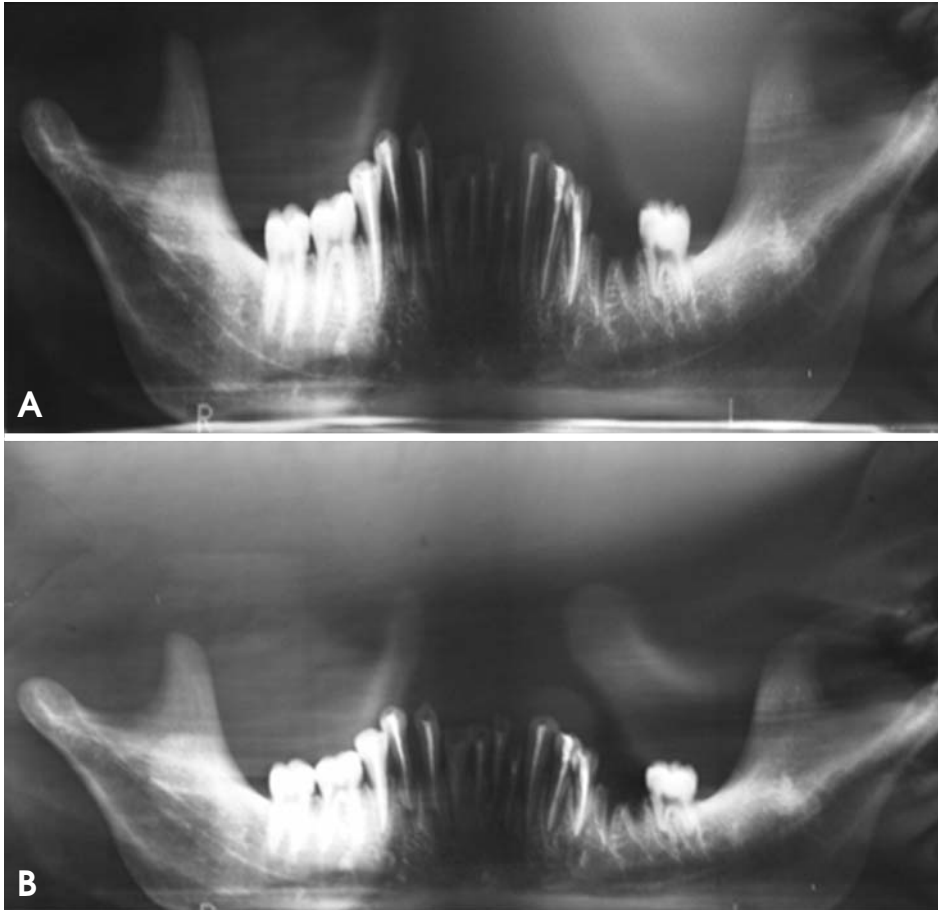


Fig. 2. Conventional panoramic film (A) and digital panoramic image (B) show the same group of teeth shown in Fig. 1.

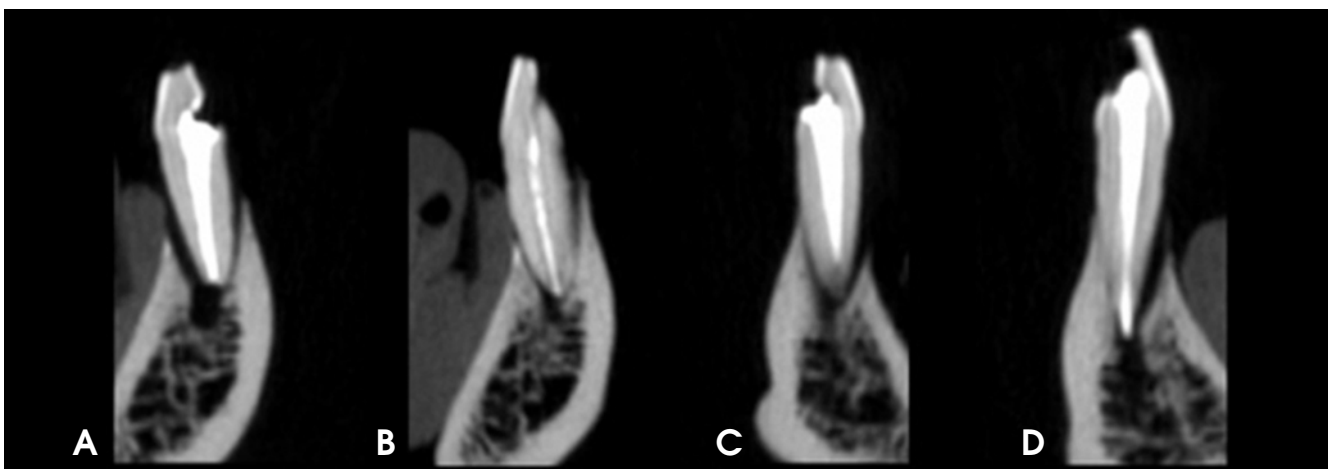


Fig. 3. Images obtained with CBCT unit reconstructed by 0.2 mm³ voxels of the teeth shown in Figure 1. A. Ideal root canal treatment. B. Insufficient condensation. C. Root canals filled short of the apex. D. Overfilled root canal treatment.

The weighted kappa coefficients were calculated to assess intra- and inter-observer agreements for each image set. Kappa values were calculated according to the following criteria: <0.10, no agreement; 0.10-0.40, poor agreement; 0.41-0.60, significant agreement; 0.61-0.80, strong agreement; 0.81-1.00, excellent agreement, and these values were calculated by MedCalc statistical software (MedCalc Software, Mariakerke, Belgium). For all observer assessments, the percentage of correct readings obtained from each modality was calculated for each root canal treatment type. SPSS 15.0 (SPSS Inc., Chicago, IL, USA) was used for analyses and the t-test was used for comparison of modalities with the significance level set at $p < 0.05$.

Results

The intra-observer kappa coefficients calculated for each observer using the radiological method ranged between

0.327 and 0.849, showing, in general, strong agreement (Table 1). The inter-observer kappa coefficients calculated for each observer using the radiological method for the first readings ranged between 0.312 and 0.748, showing significant agreement (Table 2). The inter-observer kappa coefficients calculated for each observer using the radiological method for the second reading ranged between 0.369 and 0.749; again strong inter-observer agreements were found for all methods showing significant agreement (Table 3). The significant Kappa values obtained from the observers' correct assessment percentage obtained for each root canal treatment type by imaging modality were taken into consideration for all observers.

Table 4 shows the correct assessment percentage for the teeth with ideal root canal treatment. For the teeth in the ideal root canal treatment group, the CBCT with 0.2 mm³ voxel images revealed the best results, while the portable X-ray with CCD had the worst results: CBCT (0.2 mm³)

Table 1. Intra-observer kappa coefficients calculated for each observer by radiological method

Method	Observer 1	Observer 2	Observer 3
CBCT (Iluma) (0.3 mm ³ voxel)	0.719-0.053	0.731-0.057	0.569-0.073
Digital panoramic	0.660-0.058	0.473-0.069	0.773-0.057
Conventional periapical	0.725-0.053	0.631-0.062	0.661-0.061
Conventional panoramic	0.701-0.055	0.327-0.071	0.737-0.057
CCD with fixed X-ray source	0.759-0.048	0.483-0.064	0.658-0.059
PSP (Digora)	0.849-0.039	0.673-0.058	0.744-0.054
CCD (Dr. Suni) with portable X-ray source	0.793-0.045	0.615-0.058	0.677-0.056
CBCT (Iluma) (0.2 mm ³ voxel)	0.823-0.048	0.781-0.056	0.678-0.065

Table 2. Inter-observer kappa coefficients by radiological method for first reading

Method	Obs1-Obs2	Obs1-Obs3	Obs2-Obs3
CBCT (Iluma) (0.3 mm ³ voxel)	0.421-0.067	0.573-0.062	0.610-0.067
Digital panoramic	0.403-0.069	0.492-0.065	0.519-0.071
Conventional periapical	0.499-0.066	0.579-0.063	0.462-0.069
Conventional panoramic	0.312-0.067	0.462-0.064	0.463-0.067
CCD with fixed X-ray source	0.492-0.064	0.559-0.062	0.401-0.067
PSP (Digora)	0.585-0.059	0.569-0.063	0.579-0.061
CCD (Dr. Suni) with portable X-ray source	0.429-0.065	0.563-0.062	0.451-0.066
CBCT (Iluma) (0.2 mm ³ voxel)	0.563-0.067	0.747-0.056	0.748-0.057

Table 3. Inter-observer kappa coefficients by radiological method for second reading

Method	Obs1-Obs2	Obs1-Obs3	Obs2-Obs3
CBCT (Iluma) (0.3 mm ³ voxel)	0.369-0.071	0.436-0.066	0.557-0.070
Digital panoramic	0.419-0.067	0.444-0.067	0.578-0.069
Conventional periapical	0.612-0.059	0.506-0.066	0.657-0.061
Conventional panoramic	0.410-0.070	0.377-0.069	0.639-0.064
CCD with fixed X-ray source	0.570-0.058	0.493-0.060	0.749-0.054
PSP (Digora)	0.578-0.058	0.476-0.062	0.709-0.058
CCD (Dr. Suni) with portable X-ray source	0.449-0.064	0.518-0.059	0.560-0.063
CBCT (Iluma) (0.2 mm ³ voxel)	0.595-0.069	0.584-0.069	0.613-0.072

Table 4. Percentage of correct assessments for teeth with ideal root canal treatment, insufficient lateral condensation, filled short of the apex, and overfilled root canal treatment

	Conventional periapical	Portable X-ray with CCD	CCD (Dr. Suni)	PSP (Digora)	Conventional panoramic	Digital panoramic	CBCT at 0.2 mm ³	CBCT at 0.3 mm ³
Ideal root canal treatment	76.7	63.9	66.7	78.9	80.6	82.8	88.3	76.1
Insufficient lateral condensation	48.3	33.3	40.0	40.0	20.0	15.0	23.0	16.7
Filled short of the apex	98.3	96.7	100.0	98.3	85.0	86.7	100.0	100.0
Overfilled	76.7	71.7	75.0	78.3	60.0	53.3	58.3	43.3

> digital panoramic > conventional panoramic > PSP > conventional periapical film > CBCT (0.3 mm³) > CCD > portable X-ray with CCD. Statistically significant differences were found between CBCT (0.3 mm³) and both the portable X-ray with CCD (p=0.01) and CBCT (0.2 mm³) (p=0.004). There were statistically significant differences between digital panoramic and both CCD with a fixed X-ray source (p<0.001) and portable X-ray with CCD (p<0.001). There were also significant differences between CBCT (0.2 mm³) and all of the following: PSP (p=0.03), CCD (p<0.0001), portable X-ray with CCD (p<0.0001), and conventional periapical film (p=0.009). Statistically significant differences were found between conventional periapical film and both CCD with a fixed X-ray source (p=0.047) and portable X-ray with CCD (p=0.009). There were also significant differences between conventional panoramic and both CCD with a fixed X-ray source (p=0.003) and portable X-ray with CCD (p<0.001). In addition, significant differences between PSP and both CCD with a fixed X-ray source (p=0.01) and portable X-ray with CCD (p=0.002) were found.

Table 4 shows the correct assessment percentage for teeth with insufficient lateral condensation. The assessment of teeth with insufficient lateral condensation showed the most correct percentage of readings for conventional periapical film followed by CCD and PSP. The lowest percentage of correct assessments was obtained with digital panoramic followed by CBCT at 0.3 mm³ voxel resolution and conventional panoramic: film > PSP = CCD > portable X-ray with CCD > CBCT (0.2 mm³) > conventional panoramic > CBCT (0.3 mm³) > digital panoramic. Statistically significant differences were found between the conventional periapical film and both CBCT at 0.2 mm³ (p=0.0076) and CBCT at 0.3 mm³ (p<0.001). Statistically significant differences were also found between digital panoramic and all of the following: portable X-ray with CCD (p=0.032), digital panoramic and CCD with a fixed X-ray source (p=0.004), digital panoramic and PSP (p=0.004), and digital

panoramic and conventional periapical (p<0.001). There were statistically significant differences between conventional panoramic and the following: CCD (p=0.02), PSP (p=0.02), and conventional periapical film (p=0.002). In addition, significant differences between CBCT at 0.3 mm³ and both CCD (p=0.006) and PSP (p=0.006) were found.

Table 4 shows the correct assessment percentage for teeth with root canals filled short of the apex. Assessment of teeth with root canals filled short of the apex showed the highest percentage of correct readings for CBCT images and CCD images. The lowest percentage of correct assessments was obtained with the conventional and digital panoramic images: CBCT (0.2 mm³) = CBCT (0.3 mm³) = CCD > PSP = film > portable X-ray with CCD > digital panoramic > conventional panoramic. Statistically significant differences were found between conventional panoramic film and all of the following: CBCT at 0.2 mm³ (p=0.005), CBCT at 0.3 mm³ (p=0.005), portable X-ray with CCD (p=0.048), CCD with a fixed X-ray source (p=0.005), PSP (p=0.02), and conventional periapical film (p=0.02). Statistically significant differences were also found between the digital panoramic and both CBCT at 0.2 mm³ (p=0.01) and CBCT at 0.3 mm³ (p=0.01).

Table 4 also shows the correct assessment percentage for teeth with overfilled root canals. For the overfilled root canal treatment group, PSP images and conventional periapical film radiographs had the best scores whereas CBCT at 0.3 mm³ and digital panoramic images had the lowest scores (PSP > Film > CCD > portable X-ray with CCD > conventional panoramic > CBCT (0.2 mm³) > digital panoramic > CBCT (0.3 mm³)). Statistically significant differences were found between CBCT (0.3 mm³) and the following: portable X-ray with CCD (p=0.002), CBCT (0.3 mm³) and CCD with a fixed X-ray source (p<0.001), CBCT (0.3 mm³) and PSP (p<0.001), and CBCT (0.3 mm³) and conventional periapical film (p<0.001). There were also statistically significant differences between the digital panoramic and the following: conventional periapical film

($p=0.01$), PSP ($p=0.007$), and CCD with a fixed X-ray source ($p=0.02$). In addition, significant differences between CBCT at 0.2 mm^3 and both CCD ($p=0.006$) and PSP ($p=0.03$) were found.

Discussion

The aim of the present study was to assess the accuracy of root canal treatment with several radiographic techniques used in clinical dentistry. The present research found different results for different methods for different canal treatment options. To our knowledge, this study was the first trial to compare CBCT with different two-dimensional techniques in terms of root canal filling accuracy. Although we found a higher percentage of correct readings for CBCT compared to other modalities when evaluating teeth with root canals filled short of the apex, CBCT was inferior to intraoral modalities when evaluating teeth with overfilled root canal fillings and teeth filled with insufficient condensation.

A significant issue that can affect the image quality and diagnostic accuracy of CBCT images is the scatter and beam hardening artifacts caused by high density adjacent structures, such as metal posts, restorations, and root filling materials.¹⁹ However, it is clear that there are many specific situations where the 3D images produced by CBCT facilitates diagnosis and influences treatment. The usefulness of CBCT cannot be disputed. It is a valuable task-specific imaging modality, producing minimal radiation exposure to the patient and providing maximal information to the clinician. Clinicians should use CBCT only when the need for imaging cannot be met adequately by lower dose conventional dental radiography or alternate imaging modalities.²⁰

The image quality of panoramic radiographs taken digitally and conventionally was found to be similar.²¹ It has been suggested that panoramic radiographs cannot be used alone in order to detect periapical lesions, marginal bone loss, or caries.²² In our study, conventional panoramic radiographs were incompetent especially in the detection of insufficient lateral condensation and overfilled root canal treatment. Although panoramic radiography is not the method of choice for the assessment of root canal treatment, it is commonly available in routine practice and is especially useful when a broad view of both jaws is required. It was very difficult to standardize images by placing the mandible in the focal trough, as mentioned above, especially in this *ex vivo* model. However, we assessed the panoramic images because of their frequent use in clinical

practice. The high percentage of correct assessments for ideal root canal treatment may be due to the fact that with panoramic imaging observers were unable to assess the anterior area and they readily rated most canals as ideally filled.

The image quality to detect the periodontal ligament, root ending, and bone trabeculations was better in conventional radiographs than conventional panoramic radiographs. However, in terms of the image quality of root canal morphology and endodontic filling materials, there were no differences between those methods.²³ We found that there were no statistically significant differences between conventional periapical radiographs and conventional panoramic radiographs for the assessment of ideal root canal treatment ($p>0.05$).

A study²⁴ compared digital images obtained with a portable X-ray source (ADX-4000) and conventional bite-wings according to their diagnostic quality. Digital 3.5 inch images were displayed on the built-in monitor of the ADX 4000 and digital 17 inch images were viewed on a 17 inch monitor; both methods had similar results.²⁴ In a similar study, it was found that a combination of Nomad[®] with PSP gave the best scores for image MinRay[®], AnyRay[®], and Rextar[®] X-Ray devices in combination with PSP, CCD, or CMOS sensors.¹¹ Another study revealed that images have better quality with a combination of a fixed X-ray source and PSP than with portable X-ray units.¹² Also, it was found that radiological image quality was significantly higher for the phosphor quality, and Rextar[®] with Sopix2[®] was the best option to enhance portability.¹¹ The authors also found that the combination of Nomad[®] with PSP showed the best results for image quality compared with the CMOS digital receptor system.¹² In the present study, a portable X-ray unit was used with a CCD sensor. We obtained similar results with a portable X-ray unit and CCD compared with CCD with a fixed X-ray unit and PSP for root canal treatment assessment.

For the evaluation of root canal length with endodontic files, conventional radiographs showed better scores than PSP (Digora Optime-Digora, Tuusula, Finland) and RVG (Trophy, Vincennes, France) images.^{25,26} In the present study, in assessment of root canal treatment, there was no statistically significant difference between phosphor plate images and conventional radiographs ($p>0.05$).

A study revealed that PSP plates showed better image quality than CBCT. This might originate from the higher spatial resolution obtained with Digora Optime compared with CBCT.²⁷ These results were in line with our findings, which suggested that phosphor plate images were better

than CBCT images for the assessment of the insufficient lateral condensation and overfilled root canal treatment groups.

A previous study showed that for the detection of external root resorption, CBCT (0.3 mm³ resolution) is the best option when exposure dosage is considered.²⁸ We obtained CBCT images with 0.2 mm³ and 0.3 mm³ resolution. In the present study, CBCT images obtained with 0.2 mm³ voxels were, in general, better than the CBCT images obtained with 0.3 mm³ voxels, which may be explained by better visibility of the root canals due to the smaller voxel size.

A study found that the ratio of the detection of root canal treatment 1-2 mm short of the apex using periapical radiographs was 88%, 89.3%, and 95% for the anterior, premolar, and molar, respectively, but the ratios for CBCT were 70%, 73.7%, and 79%.²⁹ In our study, the assessment of teeth with root canals filled short of the apex showed the best correct percentage of readings for CBCT images at both voxels and for CCD images. The lowest percentages of correct assessments for short root canal fillings were obtained with conventional and digital panoramic images. Also, we obtained the best results for all systems when assessing teeth with root canals filled short of the apex. Since the canal treatment was shorter than 2 mm from the apex, it was easier to detect and observers mainly focused on the canal treatment shortage.

In a study aiming to evaluate the gaps in root canal treatment, it was found that gaps greater than 350 microns can be visualized by all imaging techniques, but for smaller gaps, the intraoral digital technique had better scores than the analog technique and CBCT imaging.³⁰ In our study, the assessment of teeth with insufficient lateral condensation showed the highest percentage of correct readings using conventional periapical film, followed by CCD and PSP. The lowest percentage of correct assessments was obtained with digital panoramic radiography, followed by CBCT at 0.3 mm³ voxel resolution and conventional panoramic radiography. However, we did not assess the dimensions of the gap with objective criteria; only observers' readings were assessed. Therefore, our results were more subjective.

A study compared root canal treatments according to their length and homogeneity. For single-rooted teeth, PSP image quality was found to be equal to conventional radiography and to be better than CBCT.³¹ In line with this study assessing insufficient lateral condensation, our study showed that PSP image quality was similar to CCD and better than CBCT images. The spatial resolution of Digora Op-

time (PSP) is 12.5 lp/mm and CBCT images are 2 lp/mm. This is likely to be the reason for the difference.

For tooth and root length measurement, CBCT produced more accurate results than periapical radiographs, and also 0.2, 0.3, and 0.4 mm³ resolution CBCT images were not statistically different.³² This study demonstrated that there was not a statistically significant difference between 0.2 mm³ and 0.3 mm³ resolution CBCT images only when assessing teeth in the root canal treatment short of the apex group. In the other assessment groups, 0.2 mm³ voxel images outperformed 0.3 mm³ voxel resolution images.

Although CBCT has the strong potential to replace intraoral techniques for the assessment of teeth in three dimensions, higher radiation doses, lower resolution and lack of availability compared to two-dimensional systems precludes its routine use. Newer CBCT systems offer the advantage of narrow field imaging with lower doses and better image quality.

In conclusion, the CBCT chosen for this study was found to be successful in the assessment of teeth with ideal root canal treatment and teeth with canals filled short of the apex. However, CBCT revealed inferior results compared to intraoral techniques when assessing teeth with insufficient condensation and teeth with overfilled canal treatment.

References

1. Santos SM, Soares JA, Costa GM, Brito-Júnior M, Moreira AN, de Magalhães CS. Radiographic parameters of quality of root canal fillings and periapical status: a retrospective cohort study. *J Endod* 2010; 36 : 1932-7.
2. Hülsmann M, Peters OA, Dummer PM. Mechanical preparation of root canals: shaping goals, techniques and means. *Endod Topics* 2005; 10 : 30-76.
3. Sundqvist G, Figdor D, Persson S, Sjögren U. Microbiologic analysis of teeth with failed endodontic treatment and the outcome of conservative re-treatment. *Oral Surg Oral Med Oral Pathol Oral Radiol Endod* 1998; 85 : 86-93.
4. Delivanis PD, Mattison GD, Mendel RW. The survivability of F43 strain of *Streptococcus sanguis* in root canals filled with guta-percha and Procosol cement. *J Endod* 1983; 9 : 407-10.
5. Schilder H. Filling root canals in three dimensions. *J Endod* 2006; 32 : 281-90.
6. Shearer AC, Horner K, Wilson NH. Radiovisiography for length estimation in root canal treatment: an in-vitro comparison with conventional radiography. *Int Endod J* 1991; 24: 233-9.
7. Kersten HW, Wesselink PR, Thoden van Velzen SK. The diagnostic reliability of the buccal radiograph after root canal filling. *Int Endod J* 1987; 20 : 20-4.
8. Tsesis I, Kamburoğlu K, Katz A, Tamse A, Kaffe I, Kfir A. Comparison of digital with conventional radiography in detection of vertical root fractures in endodontically treated maxil-

- lary premolars: an ex vivo study. *Oral Surg Oral Med Oral Pathol Oral Radiol Endod* 2008; 106 : 124-8.
9. Kamburoğlu K, Barenboim SF, Kaffe I. Comparison of conventional film with different digital and digitally filtered images in the detection of simulated internal resorption cavities-an ex vivo study in human cadaver jaws. *Oral Surg Oral Med Oral Pathol Oral Radiol Endod* 2008; 105 : 790-7.
 10. Kamburoğlu K, Tsesis I, Kfir A, Kaffe I. Diagnosis of artificially induced external root resorption using conventional intraoral film radiography, CCD, and PSP: an ex vivo study. *Oral Surg Oral Med Oral Pathol Oral Radiol Endod* 2008; 106 : 885-91.
 11. Pittayapat P, Oliveira-Santos C, Thevissen P, Michielsen K, Bergans N, Willems G, et al. Image quality assessment and medical physics evaluation of different portable dental X-ray units. *Forensic Sci Int* 2010; 201 : 112-7.
 12. Pittayapat P, Thevissen P, Fieuwes S, Jacobs R, Willems G. Forensic oral imaging quality of hand-held dental X-ray devices: comparison of two image receptors and two devices. *Forensic Sci Int* 2010; 194 : 20-7.
 13. Goren AD, Bonvento M, Biernacki J, Colosi DC. Radiation exposure with the NOMAD portable X-ray system. *Dentomaxillofac Radiol* 2008; 37 : 109-12.
 14. Ladeira DB, Cruz AD, Almeida SM, Bóscolo FN. Evaluation of the panoramic image formation in different anatomic positions. *Braz Dent J* 2010; 21 : 458-62.
 15. Noujeim M, Prihoda T, McDavid WD, Ogawa K, Seki K, Okano T, et al. Pre-clinical evaluation of a new dental panoramic radiographic system based on tomosynthesis method. *Dentomaxillofac Radiol* 2011; 40 : 42-6.
 16. Ogawa K, Langlais RP, McDavid WD, Noujeim M, Seki K, Okano T, et al. Development of a new dental panoramic radiographic system based on a tomosynthesis method. *Dentomaxillofac Radiol* 2010; 39 : 47-53.
 17. Dawood A, Patel S, Brown J. Cone beam CT in dental practice. *Br Dent J* 2009; 207 : 23-8.
 18. Patel S. New dimensions in endodontic imaging: Part 2. Cone beam computed tomography. *Int Endod J* 2009; 42 : 463-75.
 19. Kamburoğlu K, Murat S, Yüksel SP, Cebeci AR, Horasan S. Detection of vertical root fracture using cone-beam computerized tomography: an in vitro assessment. *Oral Surg Oral Med Oral Pathol Oral Radiol Endod* 2010; 109 : e74-81.
 20. Kamburoğlu K, Ilker Cebeci AR, Gröndahl HG. Effectiveness of limited cone-beam computed tomography in the detection of horizontal root fracture. *Dent Traumatol* 2009; 25 : 256-61.
 21. Parissis N, Angelopoulos C, Mantegari S, Karamanis S, Masood F, Tsirlis A. A comparison of panoramic image quality between a digital radiography storage phosphor system and a film-based system. *J Contemp Dent Pract* 2010; 11 : E009-16.
 22. Molander B. Panoramic radiography in dental diagnostics. *Swed Dent J Suppl* 1996; 119 : 1-26.
 23. Alexander JB, Andrews JD. A comparison between xeroradiographs and conventional radiographs as an aid in root canal therapy for maxillary molars. *Oral Surg Oral Med Oral Pathol* 1989; 67 : 443-8.
 24. Ulusu T, Bodur H, Odabaş ME. In vitro comparison of digital and conventional bitewing radiographs for the detection of approximal caries in primary teeth exposed and viewed by a new wireless handheld unit. *Dentomaxillofac Radiol* 2010; 39 : 91-4.
 25. Lozano A, Forner L, Llena C. In vitro comparison of root-canal measurements with conventional and digital radiology. *Int Endod J* 2002; 35 : 542-50.
 26. Friedlander LT, Love RM, Chandler NP. A comparison of phosphor-plate digital images with conventional radiographs for the perceived clarity of fine endodontic files and periapical lesions. *Oral Surg Oral Med Oral Pathol Oral Radiol Endod* 2002; 93 : 321-7.
 27. Baksi BG, Soğur E, Gröndahl HG. LCD and CRT display of storage phosphor plate and limited cone beam computed tomography images for the evaluation of root canal fillings. *Clin Oral Investig* 2009; 13 : 37-42.
 28. Liedke GS, da Silveira HE, da Silveira HL, Dutra V, de Figueiredo JA. Influence of voxel size in the diagnostic ability of cone beam tomography to evaluate simulated external root resorption. *J Endod* 2009; 35 : 233-5.
 29. Moura MS, Guedes OA, De Alencar AH, Azevedo BC, Estrela C. Influence of length of root canal obturation on apical periodontitis detected by periapical radiography and cone beam computed tomography. *J Endod* 2009; 35 : 805-9.
 30. Huybrechts B, Bud M, Bergmans L, Lambrechts P, Jacobs R. Void detection in root fillings using intraoral analogue, intraoral digital and cone beam CT images. *Int Endod J* 2009; 42 : 675-85.
 31. Soğur E, Baksi BG, Gröndahl HG. Imaging of root canal fillings: a comparison of subjective image quality between limited cone-beam CT, storage phosphor and film radiography. *Int Endod J* 2007; 40 : 179-85.
 32. Sherrard JF, Rossouw PE, Benson BW, Carrillo R, Buschang PH. Accuracy and reliability of tooth and root lengths measured on cone-beam computed tomographs. *Am J Orthod Dentofacial Orthop* 2010; 137 : S100-8.