

# Nipple-sparing mastectomy with immediate breast reconstruction – early complications and outcomes of the treatment

Artur Bocian<sup>1</sup>, Piotr Kędzierawski<sup>2,3</sup>, Krzysztof Kurczych<sup>1</sup>, Przemysław Jasnowski<sup>4</sup>, Daniel Maliszewski<sup>5</sup>, Agnieszka Kołacińska<sup>6</sup>

<sup>1</sup>Department of Surgical Oncology, Holycross Cancer Centre, Kielce, Poland

<sup>2</sup>Institute of the Health Sciences, *Collegium Medicum*, Jan Kochanowski University, Kielce, Poland

<sup>3</sup>Department of Radiotherapy, Holycross Cancer Centre, Kielce, Poland

<sup>4</sup>Department of Surgical Oncology with Sub-unit for the Treatment of Breast Diseases, The Holy Virgin Mary Provincial Specialist Hospital, Częstochowa, Poland

<sup>5</sup>Department of Surgical Oncology, Janusz Korczak Provincial Specialist Hospital, Słupsk, Poland

<sup>6</sup>Department of Head and Neck Cancer Surgery, Breast Cancer Unit, Medical University of Łódź, Poland

## Abstract

**Aim of the study:** To assess the early complications and outcomes of the treatment of patients undergoing nipple-sparing mastectomy (NSM) with immediate breast reconstruction.

**Material and methods:** A retrospective study was performed on 120 patients who underwent 130 NSM (10 bilateral) procedures between 1.01.2015 and 31.12.2017 in two oncology centers in Poland. In 80 patients a breast cancer was recognized. Sixteen patients underwent operations on the basis of being carriers of the *BRCA1* mutation. The follow-up period ranged from 10 to 34 months. The NSM procedures were performed with or without skin reduction and a free nipple-areola complex (NAC) transplant, with 130 prosthetic devices inserted subpectorally. Breast cancer patients followed the standard protocol for adjuvant therapy.

**Results:** The patients for risk-reducing mastectomies were younger. Prevalent histology was no special type (NST) in 60 out of 80 patients, mean tumor – NAC distance was 43.3 mm. The prevalent biological subtype was Luminal B HER2-negative. Adjuvant management consisted of chemotherapy in 61 and radiotherapy in 35 patients. We noted 14 cases of complications, 13 in the cancer group, and 1 in the non-cancer group. Skin necrosis was the most common. The mean time for the appearance of the complications was 2.8 months. No local recurrences were observed.

**Conclusions:** NSM is a safe and effective surgical option for qualified patients with breast cancer and in risk-reducing mastectomies.

**Key words:** breast cancer, *BRCA1*, subcutaneous mastectomy, immediate breast reconstruction.

## Introduction

The progress in prompt and detailed breast diagnostics has enabled more reliable preoperative cancer staging and increased the variety of appropriate treatment options [1]. Among these options, nipple-sparing mastectomy (NSM) with an immediate breast reconstruction provides oncological safety and a favorable cosmetic outcome in particular cases [2]. It does not adversely affect the timing of the adjuvant treatment. Moreover, it has become a preferable option in specific clinical settings, such as breast cancers characterized by multifocality or multicentricity.

The term subcutaneous mastectomy is becoming increasingly common in studies regarding therapeutic options in the treatment of breast cancer [3-7], gynecomastia [8], the chest-wall contour change in transgender patients [9], risk-reducing prophylactic mastectomies, such as in *BRCA* gene mutation [10] and other rare indications [11, 12]. The presented paper analyses patients with breast cancers or *BRCA* mutation carriers. We aim to assess the postoperative findings in a cohort of patients undergoing this procedure, to evaluate complications and the correctness of the qualification of the patients for surgical treatment.

Corresponding author:

Piotr Kędzierawski, PhD, Department of Radiotherapy, Holycross Cancer Centre, 3 Artwińskiego St., 25-734 Kielce, Poland, e-mail: [piotrkedzierawski@wp.pl](mailto:piotrkedzierawski@wp.pl)

Submitted: 23.04.2020

Accepted: 8.06.2020

### Material and methods

The study group consisted of 120 patients who underwent 130 NSM with a submuscular implant placement or tissue expanders between 1.01.2015 and 31.12.2017. The procedures took place in two hospitals in Poland: The Holycross Cancer Centre in Kielce (84 patients, 19 of them without cancer, 9 patients with bilateral mastectomy), and the Breast Cancer Unit in Mikotaj Kopernik Memorial Specialistic Center of Oncology and Traumatology in Lodz (36 patients, 21 of them without cancer, 1 patient with bilateral mastectomy).

The clinical and histopathological data were studied retrospectively. The group was divided into two subgroups: 80 patients diagnosed with cancer and 40 patients without cancer. The follow-up period was between 10 and 34 months (median 24 months). The surgical procedures were either therapeutic, for patients with cancer, or risk-reducing mastectomies (RRM), performed in *BRCA1* mutation carriers. All patients underwent NSM. These were either performed as subcutaneous mastectomies, with conservation of the nipple-areola complex (NAC) or as skin-reduction mastectomies (SRM), with a free NAC transplant.

The patients were qualified for the aforementioned procedures when there was no cancer infiltration on the breast skin envelope, including NAC. In each case, separate histology specimens from the retro-areolar areas were examined with postoperative paraffin studies. No frozen

intraoperative specimens were examined. When cancer infiltration was observed, the NAC was excised under local anesthesia in a post-operative out-patient clinic.

In 126 procedures, silicone microtextured implants placed under the pectoralis major muscle were used. Tissue expanders were used in four cases due to concerns regarding tissue pressure.

In the postoperative period, closed suction drains were used until drainage fell to less than 30 ml, or no longer than 10 days. One drain was used under the implant as a standard. In the case of axillary lymphadenectomy, an additional drain was provided. The length of antibiotic prophylaxis was continued until the removal of the drains. The antibiotic choice was concordant with local hospital policies.

The breast cancer patients received appropriate adjuvant treatment according to standard indications (chemotherapy, immunotherapy, hormone therapy, radiotherapy).

### Statistical analysis

The basic statistical measures (minimal, maximal, medium) for continuous features or frequencies and the percentage for original and quality features were used in the study. Mann-Whitney U test was used for features whose statistical division was not a common one for the evaluation of variables in two tested groups.

The Cox proportional hazard model was used to determine risk factors of complications. The following risk factors were included: preoperative and postoperative chemotherapy, hormone therapy, radiotherapy, smoking, obesity, comorbidities. A *p*-value < 0.05 was considered statistically significant.

We have not asked for approval of the Ethics Committee due to the retrospective character of the analysis. Upon admission to hospital, the written consent of the patients to be used in the study was obtained.

### Results

The cancer group consisted of 80 patients, with 84 mastectomies for oncological treatment (83 breast cancers and 1 case of malignant tumor phyllodes). The non-cancer group included 40 patients for other causes (risk-reducing mastectomies). The follow-up period was between 10 and 34 months (median 24 months).

The mean age of all patients in both groups was 44.4 years (range 20 to 74).

The patients in the healthy (non-cancer) group were significantly younger (Mann-Whitney U test, *p* = 0.007) (Fig. 1). The majority of patients (113) were non-smokers, two were former smokers, and five were current smokers. Seven patients were obese (BMI > 30), while the other patients had a normal BMI. In 54 patients, *BRCA1* mutation was confirmed pre-operatively. In four patients with breast cancer, different mutations were detected (*CHEK2*

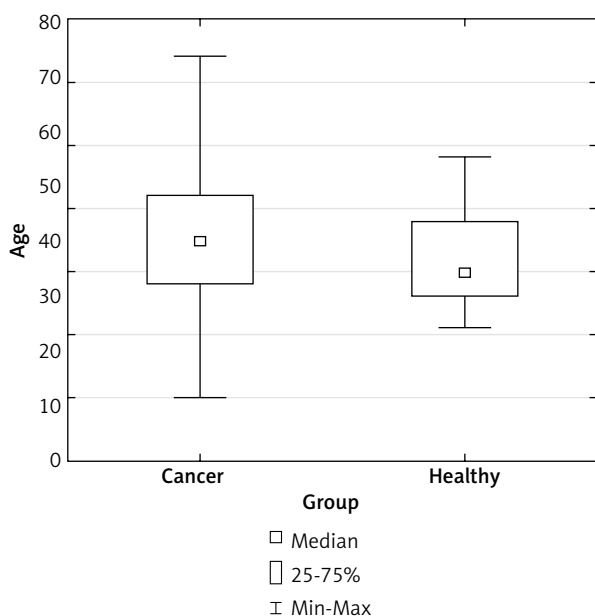


Fig. 1. Age in the study group

in 2 patients, *NOD* in 1 patient). The most common comorbidity was arterial hypertension (Table 1).

Most patients in the cancer group were in stage T1 or T2. Multifocality or multicentricity was observed in 35 patients. In the cancer group, the mean distance between tumor and NAC was 43.3 mm (range 0 mm to 200 mm), while a larger distance (100-120 mm) was observed in 15 women. The diameter depends on the position of the skin incision. In 49 patients N0 status was staged. Two patients were diagnosed with distant metastases preoperatively. One patient was diagnosed with liver metastases but demonstrated a complete response to preoperative chemotherapy. Another patient was diagnosed with bone metastases; however, the disease had been stabilized with hormone therapy and the patient opted for NSM. The dominant tumor gradings were G2 (31 patients) and G3 (24 patients). The most common pathological finding was breast cancer of no special type (NST) (60 patients). Luminal types were prevalent. The clinical and histopathological data are given in Table 2.

**Surgery and adjuvant therapies**

In cancer patients, adjuvant treatment was used (Table 3). Two patients were irradiated in the past following a breast-conserving therapy and currently operated due to recurrence. The mastectomies were bilateral in 10 patients (Fig. 2). In one patient they were performed during the same procedure, while for others, the mean period between the procedures was 133 days (range 21 to 293 days).

**Oncological safety**

The surgery and its complications did not delay the standard adjuvant therapy. No patient demonstrated local recurrence in our short follow-up. No histological report after RRM identified breast cancer. Despite no radiological evidence, post-operative histopathological

**Table 1.** Comorbidities in all patients

Comorbidity	Number of patients
Arterial hypertension	17
Coronary disease	1
Cerebro-vascular disease	1
Deep vein thrombosis with pulmonary embolism in anamnesis	1
Hypothyroidism	8
Glaucoma	2
Diabetes mellitus	4
Bronchial asthma	2
Previous breast operation	9

examination revealed cancer nipple involvement in six patients. In these cases, NAC was removed in an out-patient clinic under local anesthesia.

**Complications**

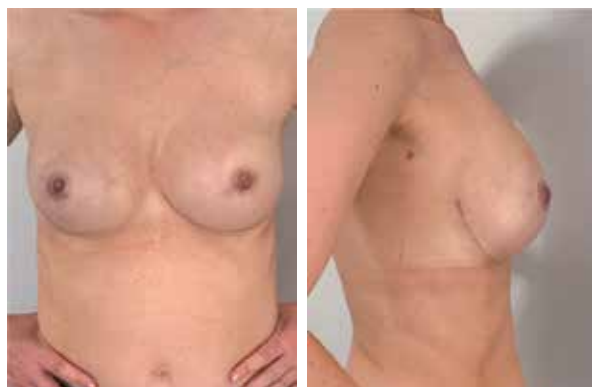We noted 14 cases of complications, 13 in the cancer group, and 1 in the non-cancer group. The mean time for the appearance of the complications was 2.8 months (range 0.1 month to 17 months). A capsule contracture

**Table 2.** Characteristics of the cancer group

Factor	Number	Percent
<b>T stage</b>		
Tis	12	14
T0	3	4
T1	31	37
T2	32	39
T3	5	6
<b>Multifocality</b>		
No	49	58
Yes	35	42
<b>N stage</b>		
N0	49	59
N1	27	33
N2	4	5
N3	3	4
<b>Grading</b>		
G1	14	17
G2	31	37
G3	24	29
NG1	4	5
NG2	6	7
No data	4	5
<b>Histopathology</b>		
Carcinoma in situ	12	14
Mixed type of cancer	4	5
No special type	60	71
Lobular cancer	7	8
<b>Biological subtype of the cancer</b>		
Luminal A	15	18
Luminal B HER2 negative	22	26
Luminal B HER2 positive	7	8
Non-luminal HER2 positive	6	7
Triple negative	11	13
Ductal carcinoma in situ	12	14
Data incomplete	11	13

**Table 3.** Types of adjuvant therapies in the cancer group

Oncological treatment	Adjuvant chemotherapy	Neoadjuvant chemotherapy	Radiotherapy
Nipple-sparing mastectomy	39	11	31
Skin-reducing mastectomy	7	4	4
Total	46	15	35



**Fig. 2.** A patient after bilateral pre-pectoral subcutaneous mastectomy

was noted in three women who were treated with postoperative radiotherapy. In four cases, tissue expanders were used instead of implants to prevent excessive tissue pressure. Skin flap necrosis was recorded in two patients after skin-reduction mastectomy (one of whom received radiotherapy) and in three patients after NSM (two of whom received radiotherapy, and one received chemotherapy). Skin flap necrosis necessitated the removal of the implant in two out of five patients with skin necrosis, i.e. one diabetic and one obese patient. Skin necrosis was observed in one diabetic patient treated with an expander, necessitating its removal. Full-thickness necrosis of the NAC was observed in one woman after SRM and in three following NSM. In 1 smoker necrosis was observed. An implant dislocation was noted in two patients after NSM (Table 4). In the non-cancer group, superficial necrosis around the areola was noted. In a multivariate Cox regression analysis

**Table 4.** Complications after the treatment including post-radiotherapy complications

Complication	Total number	Post-radiotherapy
Capsule contracture	3	2
Skin necrosis after SRM	2	1
Skin necrosis after NSM	3	2
Skin necrosis necessitating expander removal	1	0
Full thickness necrosis of NAC after SRM	1	0
Full thickness necrosis of NAC after NSM	3	0
Implant dislocation	2	1

SRM – skin-reducing mastectomy, NSM – nipple-sparing mastectomy, NAC – nipple-areola complex

smoking was the factor which increased the risk of complications over twenty times (Table 5).

## Discussion

### Indications for subcutaneous mastectomy

In 2015-2017 in the Holycross Cancer Centre 773 mastectomies were performed, including 186 subcutaneous mastectomies with immediate reconstruction, which represented 24% of all mastectomies. The qualification for this procedure should be very prudent, because not every woman is a subject of this particular form of treatment. The style of life of the patient, comorbidities, age, body mass index, and forecasted oncological treatment can influence treatment outcomes.

### Necrosis of the nipple-areola complex and skin

The combination of broad tissue undermining and a long skin wound can cause several complications. In the present study, nipple-areolar necrosis was observed. These are mentioned by other authors as the most common complications following a nipple-sparing technique [13, 14]. The safest area for surgical incision seemed to be the one performed in the lower quadrants of the breast [13]. Some new surgical strategies have been presented to avoid and resolve the necrosis of the NAC or skin [15].

### Radiotherapy with nipple-sparing mastectomy

A considerable percentage of studied patients who presented ischemic changes of the skin envelope had previously undergone radiotherapy. Radiotherapy is

**Table 5.** Cox regression analysis – complication risk factors

Covariate	p-value	Exp(b)	95% CI of Exp(b)
Preoperative chemotherapy	0.0866	0.2641	0.0576 to 1.2112
Hormone therapy	0.6633	1.3320	0.3664 to 4.8415
Radiotherapy	0.1522	2.9743	0.6690 to 13.2236
Postoperative chemotherapy	0.2159	0.2664	0.0328 to 2.1652
Smoking	0.0265	21.3790	1.4286 to 319.9474
Obesity	0.0584	5.6805	0.9402 to 34.3194
Comorbidities	0.5835	0.7060	0.2034 to 2.4507

mandatory for many patients with breast cancer; however, its side effects may be detrimental to the esthetic result of the NSM [16]. Interestingly, although an implant can reduce the radiotherapy dose, it does not appear to affect survival rates [17]. The optimal strategy is one based on a multidisciplinary approach at the stages of planning, treatment, and follow-up, with the patient included in the decision-making process.

### ***Breast implant capsular fibrosis***

Capsule formation around an implant is a well-known and extensively studied phenomenon [18]. Unfortunately, for the time being, there is no successful preventive measure. In our material, this complication necessitated another operation.

### ***Nipple-sparing mastectomy after previous breast procedures***

Previous interventions on the operated breast did not exclude the patient from NSM. It is regarded as a safe procedure [19].

### ***Further surgery after nipple-sparing mastectomy***

At times, more than one intervention is required for a favorable result [20]. Although some of the patients from our group underwent further procedures to improve the esthetic effect, these were performed outside our breast cancer units and the data are hence unavailable.

### ***Oncological safety***

Cancer relapses after subcutaneous mastectomies are rare [3, 4, 7, 21] as is the case in our present material. Such favorable outcomes may be attributed to a more detailed work-up of the patients for NSM and by the selection of less advanced cases, such as the exclusion of cases with skin involvement [2].

### ***Malignant infiltration of the nipple-areola complex***

During the present study, radiology studies and postoperative pathology reports were used to assess cancer infiltration of the NAC, as described previously [22]. Wong et al. report that the simultaneous excision of the nipple and an inferolateral incision could increase the incidence of skin flap necrosis [23]. In the present study, care was taken not to interrupt the delicate network of vessels in the 1 cm area around the areola. Postoperative paraffin histology examinations of the retro-areolar specimens were performed. In case of a positive finding, the NAC

excisions were delayed until out-patient appointments. Other authors report the use of intraoperative frozen sections of the retro-areolar specimens for histology assessment and immediate NAC excisions in case of positive findings [5, 24]. Other studies suggest a classical counterindication for sparing the NAC complex; a two-centimeter distance between the tumor and the nipple, as indicated by the ultrasound scan and/or the magnetic resonance imaging, might not be necessary [25]. In case of a positive result for cancer histology in the retro-areolar shavings, excision of the nipple alone seems to give the best esthetic results. However, in those patients, we would recommend removing the whole NAC area.

### ***Smoking and diabetes***

Smoking and diabetes seem to be important risk factors for ischemic skin flap changes in the presented material and this view is shared in the literature [26]. Frey et al. even give precise cut-off points: the risk increases for > 10 pack-years smoking and/or < 5 YTO (years-to-quitting) before NSM [27].

### ***Breast size and obesity as risk factors***

New independent risk factors for complications have been provided in the literature [28]. This is a mass of the postoperative specimen of > 700 g, distance from the inframammary fold to the nipple of >10 cm, and the width of the breast base of > 15 cm. It is possible that, in such cases, the surgeon could be more ready to use a larger implant or a tissue expander, and cause higher tissue tension. This could be the cause of the skin flap necrosis observed in one of the obese patients included in the study.

### ***Standard adjuvant treatment with nipple-sparing mastectomy***

At the beginning of the study, all the patients were informed about the potential complications associated with NSM procedures and were allowed to give informed consent. Standard guidelines for adjuvant therapy were applied during preoperative and postoperative scenarios for all patients with NSM. The proceedings were compliant with the data in the literature [29]. It has been reported that chemotherapy may show different effects in NSM, and hence there is a need for more precise clinical data [30].

### ***Conclusions***

The NSM is a safe and valuable surgical option for suitable patients with breast cancer and in risk-reducing prophylactic mastectomies.

## Disclosure

The authors report no conflict of interest.

## References

- Freeman MD, Gopman JM, Salzberg CA. The evolution of mastectomy surgical technique: from mutilation to medicine. *Gland Surg* 2018; 7: 308-315.
- Rancati A, Gercovich FG. Introduction to conservative mastectomies. *Gland Surg* 2015; 4: 449-452.
- Colwell AS, Christensen JM. Nipple-Sparing Mastectomy and Direct-to-Implant Breast Reconstruction. *Plast Reconstr Surg* 2017; 140: 445-505.
- Özkurt E, Tükenmez M, Güven E, et al. Favorable Outcome with Close Margins in Patients Undergoing Nipple/Skin Sparing Mastectomy with Immediate Breast Reconstruction: 5-year Follow-up. *Balkan Med J* 2018; 35: 84-92.
- Chan YH, Yau WM, Cheung PS. Oncological Safety and Technical Feasibility of Nipple-Sparing Mastectomy for Breast Cancer: The Hong Kong Experience. *World J Surg* 2018; 42: 1375-1383.
- Singla A, Singla A, Lai E, Caminer D. Subcutaneously Placed Breast Implants after a Skin-Sparing Mastectomy: Do We Always Need ADM? *Plast Reconstr Surg Glob Open* 2017; 5: e1371.
- Smith BL, Tang R, Rai U, et al. Oncologic Safety of Nipple-Sparing Mastectomy in Women with Breast Cancer. *J Am Coll Surg* 2017; 225: 361-365.
- Innocenti A, Melita D, Mori F, et al. Management of Gynecomastia in Patients With Different Body Types: Considerations on 312 Consecutive Treated Cases. *Ann Plast Surg* 2017; 78: 492-496.
- Top H, Balta S. Transsexual Mastectomy: Selection of Appropriate Technique According to Breast Characteristics. *Balkan Med J* 2017; 34: 147-155.
- Maeshima Y, Oseto K, Katsuragi R, et al. Experience with Bilateral Risk-Reducing Mastectomy for an Unaffected BRCA Mutation Carrier. *J Breast Cancer* 2016; 19: 218-221.
- Agochukwu NB, Wong L. Diabetic Mastopathy: A Systematic Review of Surgical Management of a Rare Breast Disease. *Ann Plast Surg* 2017; 78: 471-475.
- Laitano FF, Neto FL, Zerwes FP. Bilateral giant juvenile fibroadenomas of the breasts—a rare indication for bilateral skin reducing mastectomy. *Gland Surg* 2016; 5: 435-438.
- Ahn SJ, Woo TY, Lee DW, et al. Nipple-areolar complex ischemia and necrosis in nipple-sparing mastectomy. *Eur J Surg Oncol* 2018; 44: 1170-1176.
- Choi M, Frey JD, Alperovich M, et al. “Breast in a Day”: Examining Single-Stage Immediate, Permanent Implant Reconstruction in Nipple-Sparing Mastectomy. *Plast Reconstr Surg* 2016; 138: 184e-191e.
- Accurso A, Rocco N, Accardo G, et al. Innovative Management of Implant Exposure in ADM/Implant-Based Breast Reconstruction with Negative Pressure Wound Therapy. *Aesthetic Plast Surg* 2017; 41: 36-39.
- Laporta R, Longo B, Sorotos M, et al. Breast reconstruction following nipple-sparing mastectomy: clinical outcomes and risk factors related complications. *J Plast Surg Hand Surg* 2017; 51: 427-435.
- Bjöhle J, Onjukka E, Rintelä N, et al. Post-mastectomy radiation therapy with or without implant-based reconstruction is safe in terms of clinical target volume coverage and survival – A matched cohort study. *Radiother Oncol* 2019; 131: 229-236.
- Lin AJ, Karinja SJ, Bernstein JL, et al. In Search of a Murine Model of Radiation-Induced Periprosthetic Capsular Fibrosis. *Ann Plast Surg* 2018; 80 (Suppl 4): S204-S210.
- Olson J, Anderson LA, Ying J, et al. Nipple Sparing Mastectomy in Patients With Prior Breast Scars: Is It Safe? *Ann Plast Surg* 2017; 78: 22-27.
- Choi M, Frey JD, Salibian AA, Karp NS. Nipple-Areola Complex Malposition in Nipple-Sparing Mastectomy: A Review of Risk Factors and Corrective Techniques from Greater than 1000 Reconstructions. *Plast Reconstr Surg* 2017; 140: 247e-257e.
- Shimo A, Tsugawa K, Tsuchiya S, et al. Oncologic outcomes and technical considerations of nipple-sparing mastectomies in breast cancer: experience of 425 cases from a single institution. *Breast Cancer* 2016; 23: 851-860.
- Mastroianni M, Lin AM, Smith BL, et al. Austen WG Jr, Colwell AS. Nipple Loss following Nipple-Sparing Mastectomy. *Plast Reconstr Surg* 2016; 138: 24e-30e.
- Wong L, Wilson RM, Snapp WK, et al. Nipple Pathology in Total Skin-Sparing Mastectomy: Implications for Immediate Reconstruction. *Ann Plast Surg* 2016; 76 (Suppl 4): S340-S343.
- Suarez-Zamora DA, Barrera-Herrera LE, Palau-Lazaro MA, et al. Accuracy and interobserver agreement of retroareolar frozen sections in nipple-sparing mastectomies. *Ann Diagn Pathol* 2017; 29: 46-51.
- Dent BL, Miller JA, Eden DJ, et al. Tumor-to-Nipple Distance as a Predictor of Nipple Involvement: Expanding the Inclusion Criteria for Nipple-Sparing Mastectomy. *Plast Reconstr Surg* 2017; 140: 1e-8e.
- Casella D, Calabrese C, Orzalesi L, et al. Current trends and outcomes of breast reconstruction following nipple-sparing mastectomy: results from a national multicentric registry with 1006 cases over a 6-year period. *Breast Cancer* 2017; 24: 451-457.
- Frey JD, Alperovich M, Levine JP, et al. Does Smoking History Confer a Higher Risk for Reconstructive Complications in Nipple-Sparing Mastectomy? *Breast J* 2017; 23: 415-420.
- Ukleikins S, Irmejs A, Gilis A, et al. Body mass index and nipple preservation are major contributors to satisfaction and aesthetic outcome rates after implant-based immediate breast reconstruction. *Contemp Oncol (Pozn)* 2019; 23: 96-99.
- Frey JD, Choi M, Karp NS. The Effect of Neoadjuvant Chemotherapy Compared to Adjuvant Chemotherapy in Healing after Nipple-Sparing Mastectomy. *Plast Reconstr Surg* 2017; 139: 10e-19e.
- Altundag K. Breast Cancer Molecular Subtypes and Chemotherapy Schedules Used in Neoadjuvant or Adjuvant Setting May Show Different Effects in Nipple-Sparing Mastectomy. *Plast Reconstr Surg* 2017; 140: 495e.