

## Physician-modified fenestrated endograft for postdissection thoracoabdominal aortic aneurysm following provisional extension to induce complete attachment and renal artery stenting

Anand V. Ganapathy, MD, MEng, Jonathan C. Cash, MD, Gregory A. Magee, MD, MSc, Kenneth R. Ziegler, MD, and Sukgu M. Han, MD, MS, *Los Angeles, CA*

### ABSTRACT

We have described a patient with a history of type A-II dissection repair, who subsequently underwent thoracic endovascular aortic repair with distal bare metal dissection stents (provisional extension to induce complete attachment) and renal artery stenting for malperfusion. During the next 3 years, the thoracoabdominal aorta had continued to enlarge to 6.9 cm, despite false lumen embolization and thoracic endovascular aortic repair extension. Given the continued aortic enlargement, physician-modified fenestrated endovascular aortic repair was performed within the prior aortic and renal stents with successful aneurysm sealing. The results from the present case have illustrated that continued aneurysmal degeneration can occur after provisional extension to induce complete attachment and that subsequent physician-modified fenestrated endovascular aortic repair is feasible. (*J Vasc Surg Cases Innov Tech* 2022;8:367-71.)

**Keywords:** Aneurysmal degeneration; Aortic dissection; Aortic remodeling; Fenestrated endovascular aortic repair; Malperfusion; PETTICOAT; Provisional extension to induce complete attachment

Thoracic endovascular aortic repair (TEVAR) has emerged as the first-line treatment of complicated type B aortic dissections. Although the proximal extent of type A aortic dissections is often treated with open aortic reconstructions, TEVAR provides a treatment option for the descending thoracic segments. Provisional extension to induce complete attachment (PETTICOAT) using uncovered stents in the true lumen is thought to promote true lumen expansion and aortic remodeling.<sup>1</sup> The reported benefits of PETTICOAT include decreased malperfusion-related mortality and reintervention and increased true lumen expansion and/or false lumen thrombosis compared with TEVAR alone.<sup>2</sup>

In the present report, we have described the case of a patient with a postdissection extent I thoracoabdominal aortic aneurysm (TAAA) that had continued to increase

in size for 3 years after the initial open type A aortic dissection followed by PETTICOAT and renal stenting, despite subsequent distal extension of TEVAR and false lumen embolization. To achieve a complete seal, a physician-modified fenestrated endograft (PMEG) was performed within the PETTICOAT and renal stents. In the present report, we have shared some technical tips for device modification and implantation. The patient provided written informed consent for the report of his case details and imaging studies. The results from the present case and others were reported to the U.S. Food and Drug Administration, leading to approval of a physician-sponsored investigational device exemption (No. G200159).

### CASE REPORT

A 77-year-old man had undergone emergent ascending aortic and hemiarch repair with debranching of the innominate and left carotid arteries for an acute type A-II dissection extending into the right common femoral and left external iliac arteries.<sup>3</sup> His postoperative course had been complicated by renal failure requiring hemodialysis and resulting in bilateral lower extremity paraparesis. A computed tomography angiogram (CTA) after repair demonstrated distal aortic arch dilation to 4.9 cm, perfusion of the celiac and two right renal arteries by the false lumen with delayed contrast enhancement, and dissection of the left renal artery (*Fig 1*). With these findings, left carotid to axillary bypass was performed, followed by TEVAR in zones 0 to 4, using Zenith alpha thoracic stent grafts (Cook Medical Inc, Bloomington, IN) combined with PETTICOAT stenting in zones 5 to 9, using bare metal Zenith dissection stents (Cook Medical Inc) for renal malperfusion and lower extremity paraparesis. The

From the Comprehensive Aortic Center, Keck Hospital of USC, University of Southern California.

Author conflict of interest: G.A.M. and S.M.H. have a consulting association with W. L. Gore & Associates; all honoraria are paid to the University of Southern California, with no personal income from these relationships. S.H.H. also has a consulting association with Cook Medical. A.V.G., J.C.C., and K.R.Z. have no conflicts of interest.

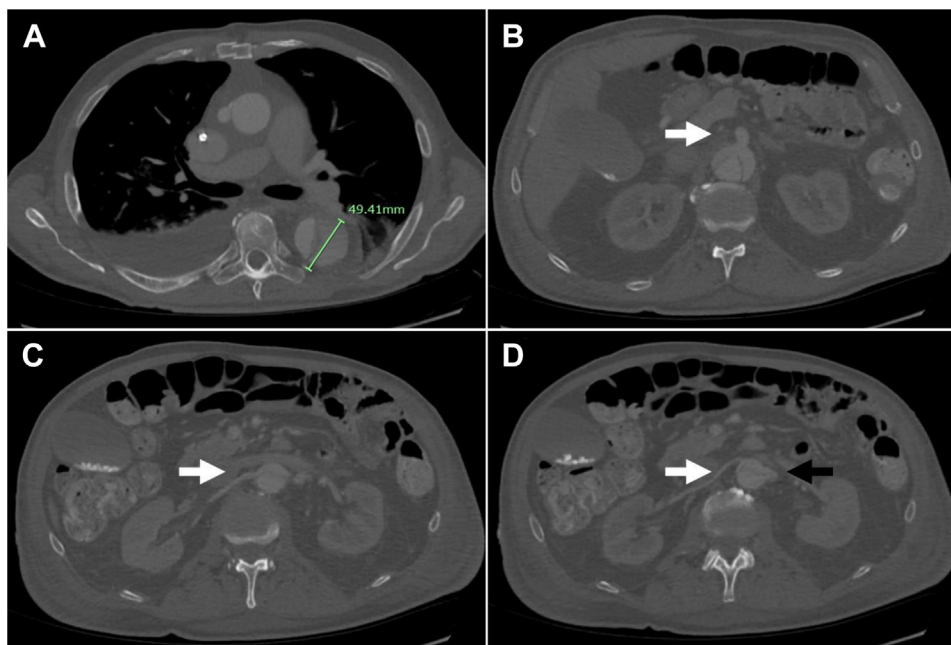
Correspondence: Sukgu M. Han, MD, MS, Division of Vascular Surgery and Endovascular Therapy, University of Southern California, 1520 San Pablo St, Ste 4300, Los Angeles, CA 90033 (e-mail: [sukgu.han@med.usc.edu](mailto:sukgu.han@med.usc.edu)).

The editors and reviewers of this article have no relevant financial relationships to disclose per the Journal policy that requires reviewers to decline review of any manuscript for which they may have a conflict of interest.

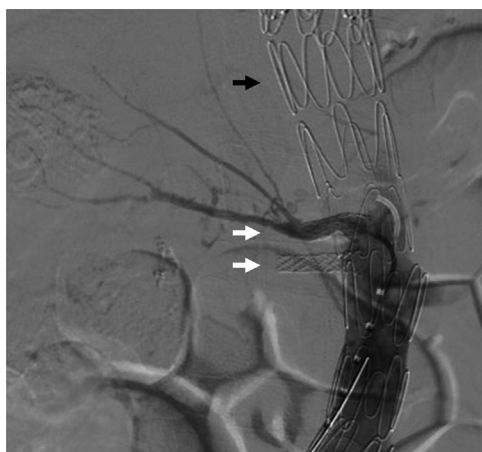2468-4287

© 2022 The Authors. Published by Elsevier Inc. on behalf of Society for Vascular Surgery. This is an open access article under the CC BY-NC-ND license (<http://creativecommons.org/licenses/by-nc-nd/4.0/>).

<https://doi.org/10.1016/j.jvscit.2022.04.015>



**Fig 1.** **A**, Axial view of computed tomography angiogram (CTA) after open ascending and transverse aortic repair showing distal aortic arch dilation to 4.9 cm. **B**, CTA showing false lumen perfusion of the celiac artery (*white arrow*). **C**, CTA showing false lumen perfusion of the inferior right renal artery (*white arrow*). **D**, CTA showing false lumen perfusion of the superior right renal artery (*white arrow*) and dissection of the left renal artery (*black arrow*).



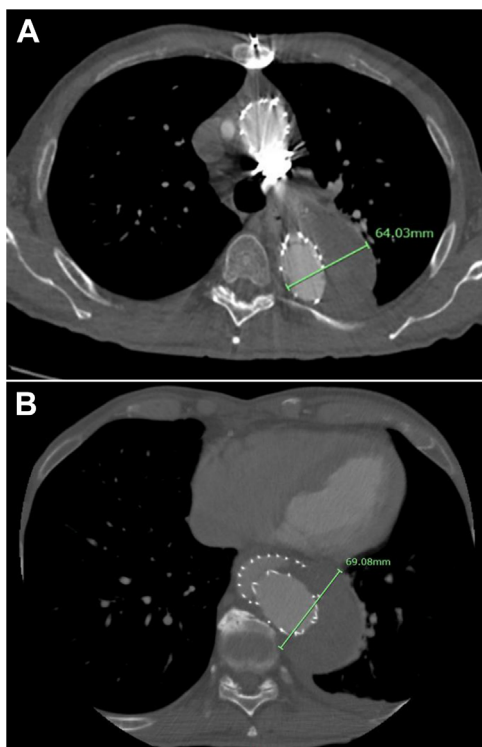
**Fig 2.** Digital subtraction angiogram of the thoracic endovascular aortic repair (TEVAR) with provisional extension to induce complete attachment (PETTICOAT) stenting using bare metal Zenith dissection stents (*black arrow*) and iCast stenting of the duplicated right renal arteries (*white arrows*).

axillary artery was chosen as the bypass target owing to dissection of the left subclavian artery. The duplicated right renal arteries were both stented using iCast covered stents (Atrium Medical, Hudson, NH) across the PETTICOAT stents (Fig 2). The subsequent CTA demonstrated true lumen expansion across the thoracoabdominal segment and improved contrast enhancement of the right kidney through widely patent stents.

At 4 months of follow-up, the patient had experienced full recovery of his renal and lower extremity function. However, the CTA showed false lumen expansion to 6.4 cm and persistent retrograde false lumen flow from multiple fenestrations across the abdominal aorta (Fig 3, A). Therefore, distal extension TEVAR using tapered Zenith alpha thoracic stent grafts was performed within the PETTICOAT stents to create a distal seal and prevent retrograde false lumen flow. The patient recovered well without complications.

Two years later, he presented with chest and back pain in the setting of further expansion of the thoracoabdominal aorta to 6.9 cm, with persistent false lumen perfusion through multiple septal fenestrations across the thoracoabdominal segment (Fig 3, B), despite a stable aortic diameter at the prior follow-up 6 months previously. The treatment options, including open thoracoabdominal aortic repair, abdominal debranching, and total endovascular repair using a PMEG, were considered. Because of his comorbidities, including prior renal failure, and the patient's wish to avoid further open aortic surgery, the use of a PMEG was planned. His symptoms resolved, and he was discharged home for elective repair.

A prophylactic lumbar drain was placed, and a PMEG was constructed with five anatomically specific fenestrations targeting the celiac, superior mesenteric, two right renal, and left renal arteries on a tapered 38-32 × 217-mm Zenith Alpha thoracic stent graft on the back table. Various degrees of temporary diameter-constraining ties were added to a trigger wire rerouted along the posterior aspect of the stent graft (Fig 4, A and B) to preserve a working space for target vessel catheterization. The device was



**Fig 3.** **A**, Axial computed tomography angiogram (CTA) at 4 months of follow-up after thoracic endovascular aortic repair (TEVAR) showing false lumen expansion of the distal aortic arch to 6.4 cm. **B**, CTA at 2 years after TEVAR deployment when the patient had presented with chest and back pain in the setting of further expansion of the thoracoabdominal aorta to 6.9 cm secondary to continued false lumen perfusion from a septal fenestration around the TEVAR extension.

reintroduced into its delivery sheath with the assistance of multiple silk sutures.

With the patient under general anesthesia, open exposure of the bilateral proximal superficial femoral arteries was performed, and a temporary femoral conduit using a 10-mm Dacron graft was placed on the left superficial femoral artery to allow for rapid restoration of leg perfusion in the setting of the prior open pseudoaneurysm and sartorius flap. Before the introduction of the fenestrated aortic stent graft, the main right renal artery was catheterized from the right femoral access for balloon protection against inadvertent crushing during aortic stent graft introduction and deployment (Fig 4, C). After cannulation of both right renal arteries, the PETTICOAT stents were gently expanded with a compliant balloon to increase the true lumen space with low concern for aortic rupture with balloon expansion. The fenestrated stent graft was introduced from the left femoral approach and unsheathed, aligning each fenestration to its target vessel. The visceral–renal vessels were sequentially catheterized using a contralateral femoral approach (Fig 4, D). Next, the fenestrated stent graft was fully deployed and balloon molded, rupturing the dissection septum

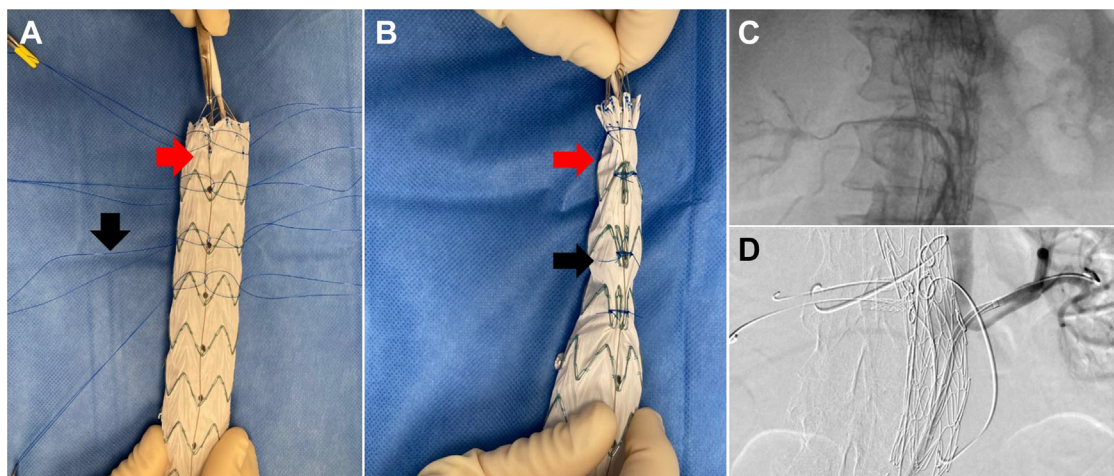
across the thoracoabdominal aorta. Bridging stents were deployed and flared across each fenestration using Viabahn VBX (W. L. Gore & Associates, Flagstaff, AZ) for the left renal artery, iCast stents (Atrium Medical) for both right renal arteries and superior mesenteric artery, and an iCast stent extended distally with a VBX stent for the celiac arteries. Subsequently, bifurcated Excluder stent grafts (W. L. Gore & Associates) were deployed into the common iliac arteries to complete the repair. The total fluoroscopy time was 78 minutes, with 110 mL of contrast used. His postoperative course was uncomplicated, and his chest and back pain resolved. The patient was discharged home on postoperative day 5, free of major complications. He had remained well at 14 months of follow-up. A surveillance CTA demonstrated complete aneurysm sealing without endoleak formation and a decrease in the aneurysm size to 6.3 cm (Fig 5).

### DISCUSSION

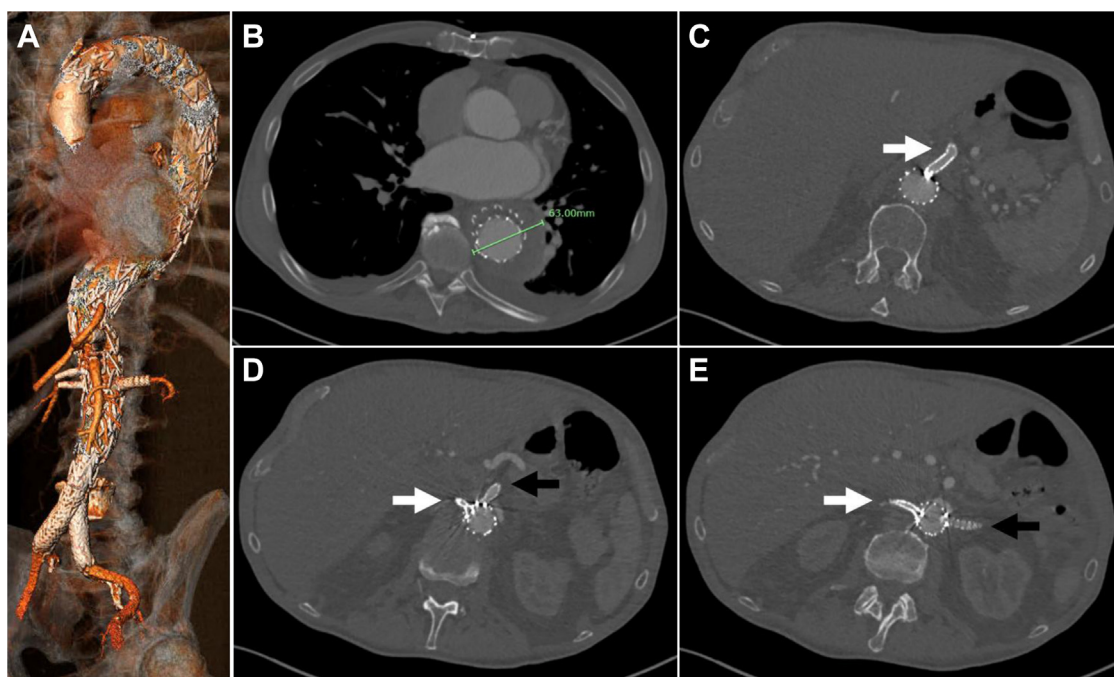
After TEVAR for aortic dissections, nearly one half of the patients will develop aneurysmal degeneration of the thoracoabdominal aorta or will require aortic reintervention at long-term follow-up.<sup>4-6</sup> Thoracoabdominal true lumen reinforcement using PETTICOAT stents has demonstrated improved short-term outcomes for patients with malperfusion and encouraging midterm aortic remodeling, mainly defined by stented true lumen expansion and thoracic false lumen thrombosis. As yet to be determined, however, is the long-term risk of TAAAs developing in patients who have undergone PETTICOAT and the effects of the PETTICOAT stents on the subsequent treatment options for TAAAs.

The technical feasibility of fenestrated endovascular aortic repair after PETTICOAT stenting was demonstrated by Barbante et al,<sup>7</sup> who described a custom-manufactured four-vessel fenestrated stent graft to treat one patient with postdissection TAAA. However, custom-manufactured fenestrated devices require time for manufacturing and shipping and remain investigational, with limited access in the United States, and thus unsuitable for urgent cases.<sup>8-10</sup> In the present report, we have described the use of a PMEG technique, with successful navigation of the thoracoabdominal aorta containing five target vessels, two of which had been previously stented. We believe that three technical tips contributed to the technical success. First, during the modification step, temporary diameter-constraining ties were applied to various degrees along the body of the stent graft (Fig 4, A and B). These ties resulted in a reverse tapered fenestrated stent graft on unsheathing, preserving the working space to catheterize the target vessels. Sequential deployment of the fenestrated endograft and target vessel catheterization from an upper extremity access was less suitable because the innominate and left carotid arteries had been debranched with bypass grafts originating low in the ascending aorta. Second, ballooning the PETTICOAT stent to expand the working





**Fig 4.** **A**, Physician-modified fenestrated endograft (PMEG) with five anatomically specific fenestrations for the visceral vessels created on a tapered Zenith alpha thoracic stent graft. Temporary diameter-constraining ties (*black arrow*) were added to a trigger wire (*red arrow*) for temporary diameter reduction during deployment. **B**, Modified fenestrated endograft showing partial constraint with temporary ties (*black arrow*). **C**, Catheterization of the main right renal artery for balloon protection against inadvertent crushing during deployment of the PMEG. **D**, Digital subtraction angiogram showing catheterization of the dissected left renal artery after deployment of the modified stent graft with alignment of each fenestration to its target vessel with sequential catheterization of each visceral–renal vessel.



**Fig 5.** Surveillance computed tomography angiograms (CTAs) showing endografts with complete aneurysm sealing without endoleak development and a decrease in aneurysm size to 6.3 cm. **A**, Three-dimensional reconstruction of the endovascular aortic repair. **B**, Decrease in aneurysm size to 6.3 cm in axial view. **C**, Abdominal aorta with a celiac artery stent (*white arrow*). **D**, Abdominal aorta with superior mesenteric artery stent (*black arrow*) and superior right renal stent (*white arrow*). **E**, Abdominal aorta with inferior right (*white arrow*) and left (*black arrow*) renal stents.

space within the stented thoracoabdominal true lumen before introduction of the fenestrated stent graft reduced the risk of catching the PETTICOAT struts and deforming them during implantation. This ballooning

was performed with gentle pressure without the goal of complete repeat lamination of the dissected aorta. Third, precatheterization of a renal artery stent prepared us to perform balloon angioplasty in case

manipulation of the fenestrated stent graft had crushed the renal stent.

## CONCLUSIONS

Postdissection TAAAs can occur after TEVAR and the use of PETTICOAT stents. A PMEG can be used within the previous PETTICOAT and renal artery stents. Our technical tips include the addition of various degrees of temporary diameter-constraining ties during modification to create a tapered device during deployment, balloon expansion of the PETTICOAT stents, and preatherization of previously placed branch stents. Long-term follow-up is needed to assess the durability of the described technique.

## REFERENCES

1. Nienaber CA, Kische S, Zeller T, Rehders TC, Schneider H, Lorenzen B, et al. Provisional extension to induce complete attachment after stent-graft placement in type B aortic dissection: the PETTICOAT concept. *J Endovasc Ther* 2006;13:738-46.
2. Matsuoka T, Hashizume K, Honda M, Harada D, Ohno M, Ikebata K, et al. The provisional extension to induce complete attachment technique is associated with abdominal aortic remodeling and reduces aorta-related adverse events after aortic dissection. *J Vasc Surg* 2021;74:45-52.e1.
3. Lombardi JV, Hughes GC, Appoo JJ, Bavaria JE, Beck AW, Cambria RP, et al. Society for Vascular Surgery (SVS) and Society of Thoracic Surgeons (STS) reporting standards for type B aortic dissections. *J Vasc Surg* 2020;71:723-47.
4. Fattori R, Montgomery D, Lovato L, Kische S, Di Eusanio M, Ince H, et al. Survival after endovascular therapy in patients with type B aortic dissection. *JACC Cardiovasc Interv* 2013;6:876-82.
5. Conrad MF, Carvalho S, Ergul E, Kwolek CJ, Lancaster RT, Patel VI, et al. Late aortic remodeling persists in the stented segment after endovascular repair of acute complicated type B aortic dissection. *J Vasc Surg* 2015;62:600-5.
6. Giles KA, Beck AW, Lala S, Patterson S, Back M, Fatima J, et al. Implications of secondary aortic intervention after thoracic endovascular aortic repair for acute and chronic type B dissection. *J Vasc Surg* 2019;69:1367-78.
7. Barbante M, Sobocinski J, Maurel B, Azzaoui R, Martin-Gonzalez T, Haulon S. Fenestrated endografting after bare metal dissection stent implantation. *J Endovasc Ther* 2015;22:207-11.
8. Oderich GS, Ribeiro MS, Sandri GA, Tenorio ER, Hofer JM, Mendes BC, et al. Evolution from physician-modified to company-manufactured fenestrated-branched endografts to treat pararenal and thoracoabdominal aortic aneurysms. *J Vasc Surg* 2019;70:31-42.e7.
9. Starnes BW, Heneghan RE, Tatum B. Midterm results from a physician-sponsored investigational device exemption clinical trial evaluating physician-modified endovascular grafts for the treatment of juxtarenal aortic aneurysms. *J Vasc Surg* 2017;65:294-302.
10. Sobocinski J, d'Utra G, O'Brien N, Midulla M, Maurel B, Guillou M, et al. Off-the-shelf fenestrated endografts: a realistic option for more than 70% of patients with juxtarenal aneurysms. *J Endovasc Ther* 2012;19:165-72.

Submitted Feb 21, 2022; accepted Apr 25, 2022.