



Case report

## Orbital alveolar echinococcosis: A case report

Mohammad Taher Rajabi <sup>a</sup>, Saeed Mohammadi <sup>a</sup>, Narges Hassanpoor <sup>a,\*</sup>,  
Seyedeh Simindokht Hosseini <sup>a</sup>, Narges Shahbazi <sup>b</sup>, Seyed Ziaeddin Tabatabaie <sup>a</sup>,  
Mohammad Bagher Rajabi <sup>a</sup>

<sup>a</sup> Eye Research Center, Farabi Eye Hospital, Tehran University of Medical Sciences, Tehran, Iran

<sup>b</sup> Cancer Institute, Imam Khomeini Hospital, Tehran University of Medical Sciences, Tehran, Iran

Received 29 March 2017; revised 3 July 2017; accepted 21 September 2017

Available online 9 November 2017

### Abstract

**Purpose:** To report a rare case of orbital alveolar echinococcosis in Iran.

**Methods:** A 23-year-old woman with multi-lobular mass lesion in the right orbit underwent excisional biopsy via a deep lateral orbitotomy approach. The pathologic investigation of the lesion was a multilobulated cystic lesion shown where the cyst wall structure was compatible with alveolar Hydatid cyst in histopathology. Clinical course, surgical, and medical management of the disease is noted briefly in the case of orbital involvement of the alveolar echinococcosis.

**Results:** Patient was treated with anti-fungal medication, and the cysts were successfully removed by a surgical excision.

**Conclusion:** Although orbital alveolar echinococcosis is extremely rare, it is noteworthy to study its clinical manifestations and radiological examinations to be able to make a true diagnosis.

Copyright © 2017, Iranian Society of Ophthalmology. Production and hosting by Elsevier B.V. This is an open access article under the CC BY-NC-ND license (<http://creativecommons.org/licenses/by-nc-nd/4.0/>).

**Keywords:** Orbit; Echinococcosis; Alveolar; Hydatid cyst

### Introduction

Hydatid disease rarely involves the orbits, but the orbital involvement can occur in less than 1% of the population.<sup>1</sup> Similar to most of the orbital mass lesions, it presents itself as a painless unilateral proptotic eye.<sup>2</sup> Alveolar echinococcosis is a chronic zoonotic infection which is mostly caused by larval stage of *Echinococcus multilocularis* (*E. multilocularis*). The most common organ affected is the liver, and involvement of orbit is very rare.<sup>3,4</sup> Almost all mentioned

cases of orbital echinococcosis in the literature are uniloculated. Multiloculated cyst or alveolar echinococcosis is extremely rare in orbital region. Alveolar cysts are more likely to cause complications and are harder to treat in comparison with other hydatid cysts.<sup>5,6</sup> Patients should be diagnosed by clinical symptoms and orbital imaging to avoid complications.

### Case report

A 23-year-old woman came to Farabi Eye Hospital, Tehran, Iran complaining of progressive proptosis of right eye for the past 3 months (Fig. 1). The patient had no history of trauma, convulsion or loss of consciousness. She has also had no history of orbital surgery.

Although, visual acuity of both eyes were 10/10, the slit-lamp examination of anterior segment was normal and funduscopy showed no pathological alteration, the patient had

The authors declare that they have no financial interest in the subject matter or materials discussed in this manuscript.

Authors obtained informed consent from the patient to publish the photos.

\* Corresponding author. Eye Research Center, Farabi Eye Hospital, Qazvin Square, Tehran, 1336616351, Iran.

E-mail address: [nargeshassanpoor@gmail.com](mailto:nargeshassanpoor@gmail.com) (N. Hassanpoor).

Peer review under responsibility of the Iranian Society of Ophthalmology.

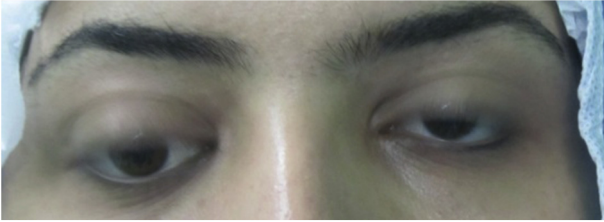

Fig. 1. The patient with proptosis and inferior displacement of the globe of right eye.

severe proptosis (13-mm difference in exophthalmometry) and infero-nasal globe displacement.

Magnetic resonance imaging (MRI) was done to investigate the cause of proptosis. There was a multiloculated cystic structure which had low intensity signal in T1 (Fig. 2: A and B) that displaced globe inferiorly. In T2 images, this cystic structure had high intensity signal (Fig. 2: C and D), and peripheral rim enhancement was seen after gadolinium injection (Fig. 2B). Due to the mentioned features of the lesion, the most probable diagnosis was hydatid cyst. The complete blood count (CBC) and erythrocyte sedimentation rate (ESR) were in normal range and Casoni test, ELISA and indirect haemagglutination (IHA) showed no sign of echinococcus infection.

Surgical en-bloc excision of the cyst was performed on the patient to prevent cyst-rupture and dissemination of the cyst's content into the orbit (Fig. 3). Since the MRI showed that the lesion is extended up to orbital apex, we decided to use “deep lateral orbitotomy” in this patient. The surgeon was able to access the superior orbital fissure with a deep lateral orbitotomy.

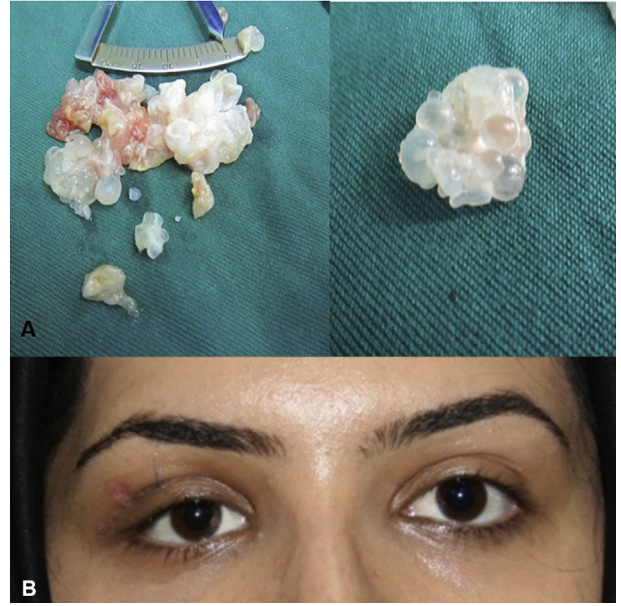

Fig. 3. The completely removed multiloculated hydatid cyst (A). Follow-up of the patient one week later (B). No recurrence was seen also at 1-year follow-up.

In addition, because our patient had no systemic involvement in clinical examination in both first and last follow-ups, and nothing abnormal was found in investigation of the internal viscera such as liver and spleen by ultrasonography, this presentation is considered the primary orbital presentation of the *E. multilocularis*. Systemic Albendazole was administered in a standard dosage (10 mg/Kg) for 3 months to prevent

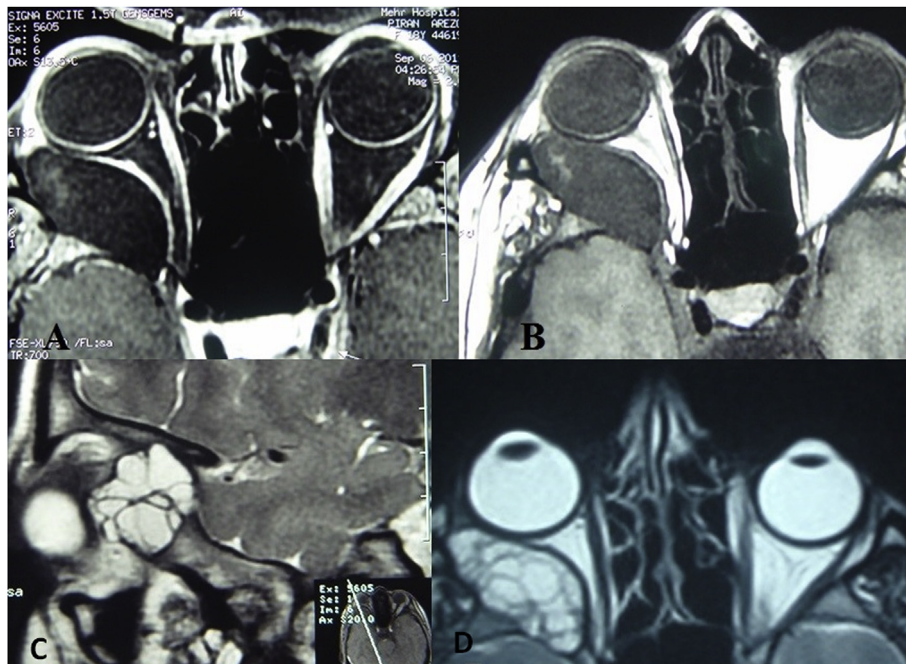


Fig. 2. T1-weighted axial magnetic resonance imaging (MRI) with fat suppression (A) showing an extraconal fusiform lesion that is hypointense in nature and has eroded the lateral wall of the orbit. (B) showing “ring” enhancement of the lesion after gadolinium injection. T2-weighted sagittal (C) and axial (D) MRI of the orbit shows well-defined multiloculated cystic lesion with high-intensity signal and hypointense ring as fibrotic capsule around the lesion.

recurrence of the hydatid cyst. The patient has been under observation for 4 years to this date, and no recurrence or systemic involvement has been revealed.

Histopathological study revealed the nature of cyst wall as a typical wall structure of Echinococcal cyst (Fig. 4) composed of two layers which are products of the parasite: the innermost germinal layer (Fig. 4-left) and the faintly stained chitinous membrane called laminated membrane (Fig. 4-right). The internal layer was the pathognomonic finding and no scolex was found. (Fig. 4).

A written consent was obtained from the patient in order to publish the images.

## Discussion

Echinococcosis is an infection that is caused by the genus *Echinococcus*. There are 4 important species of this genus which are of concern for public health: 1-Cystic echinococcosis, the most common type, is caused by *Echinococcus granulosus*. 2-Alveolar echinococcosis is caused by *E. multilocularis*. Rarely, *Echinococcus vogeli* (3) and *Echinococcus oligarthrus* (4) cause polycystic echinococcosis too.<sup>5,6</sup>

Orbital hydatid cysts are mainly caused by *E. granulosus* and other species rarely affect the orbital area.<sup>6–8</sup> Alveolar echinococcosis caused by *E. multilocularis*, which mainly affects liver and other organs are contaminated by direct extension of the parasite to adjacent organs or dissemination of larvae via blood or lymphatic vessels. Lungs and brain are the most commonly involved regions in extrahepatic involvement.<sup>7,9</sup> Involvement of other organs such as skeletal muscles, musculature of heart, and orbit is extremely rare.<sup>5</sup> In the life cycle of echinococcus tapeworm, canids are definitive hosts and ungulates are intermediate hosts. There are some aberrant hosts such as humans and primates that are dead ends of the life cycle of the worm.<sup>10</sup> *Echinococcus* is distributed mainly in temperate regions, such as some parts of Europe and Asia (especially Mediterranean area, Middle East, central Asia and China). Australia, several parts of America, and north and east Africa are also endemic for the tapeworm.<sup>11,12</sup> Iran, located in Middle East, is an endemic country for hydatidosis with reported prevalence rate of 0.61–2 in 100,000 populations.

Shoaei et al. studied 81 patients with hydatid cyst between 2003 and 2012 in Tehran and showed that abdominal pain was the most common complaints among patients. Other common complaints were cough, dyspnea, icterus, chest pain, dyspepsia, back pain, and seizure. There was no report of any orbital hydatid cyst in this study.<sup>12</sup> In 2014, Rajabi et al. reported 8 cases of orbital hydatid cyst in Iran which were found in the extraconal space (two of the patients), intraconal space (three of the patients), lacrimal gland (one of the patients), medial rectus (one of the patients), and intraosseous of orbital wall (one of the patients),<sup>7</sup> but there was no report of any alveolar hydatid cyst among them. Bagheri et al.<sup>13</sup> presented first orbital alveolar echinococcosis in Iran in 2010 in an 8-year-old boy, and this report is the second presented alveolar echinococcosis of orbit to date in Iran.

Clinical findings, lab data, and orbital imaging of the patient brought up the diagnosis of echinococcosis, considering dermoid and epidermoid cyst, abscess, sinus mucocele, hematic cyst, teratoma, lymphangioma, inclusion cyst, schwannoma, paraganglioma, and other cystic lesions in the orbit as differential diagnosis.<sup>1,14</sup> After surgical excision, the diagnosis of orbital alveolar echinococcosis was confirmed by pathologic evaluation. Physicians should maintain a high index of suspicion for hydatidosis when approaching a patient with proptosis due to several important standpoints especially in endemic area: rupture of hydatid cyst during operation may cause anaphylactic shock, dissemination, and implantation of scolices. These complications can be more serious in orbit in comparison with other parts of the body. Therefore, preoperative diagnosis and complete excision of the intact cyst are important. Because of limited space in the orbital cavity, mass effect of slowly growing cyst may include the optic nerve involvement and impaired vision, making early diagnosis and removal of the cyst of utmost importance in this aspect.<sup>15,16</sup>

Although, orbital hydatid cyst is very rare and associates less than 1% of the prevalence of hydatidosis,<sup>1</sup> we suggest that it should be considered one of the reasons of proptosis, limited eye movements, diplopia, orbital bone erosion, optic disc swelling, and atrophy, especially in endemic areas such as Iran. In suspected cases, careful examination, appropriate imaging, and lab data should be requested.




Fig. 4. Pathology slide (H&E), two layers which are products of the parasite, the innermost germinal layer (left), and the faintly stained chitinous membrane called laminated membrane (right).

## References

- Betharia SM, Sharma V, Pushker N. Ultrasound findings in orbital hydatid cysts. *Am J Ophthalmol*. 2003;135(4):568–569.
- Somay H, Emon ST, Orakdogan M, Berkman MZ. A primary orbital hydatid cyst. *Case Reports/J Clin Neurosci*. 2012;19(6):898–900.
- Vuitton DA, Brunetti E. Cystic and alveolar echinococcosis: fraternal twins both in search of optimal treatment. In: Sing A, ed. *Zoonoses – Infections Affecting Humans and Animals*. Berlin: Springer Netherlands; 2015:715–747.
- Grosso G, Gruttadauria S, Biondi A, Marventano S, Mistretta A. World-wide epidemiology of liver hydatidosis including the Mediterranean area. *World J Gastroenterol*. 2012;18(13):1425–1437.
- Eckert J, Gemmell MA, Meslin FX, Pawlowski ZS. *WHO/OIE Manual on Echinococcosis in Humans and Animals: A Public Health Problem of Global Concern*. Paris, France: WHO/OIE; 2001:20–71.
- Moro P, Schantz PM. Echinococcosis: a review. *Int J Infect Dis*. 2009;13(2):125–133.
- Rajabi MT, Bazvand F, Makateb A, Hosseini S, Tabatabaie SZ, Rajabi MB. Orbital hydatid cyst with diverse locality in the orbit and review of literature. *Arch Iran Med*. 2014;17(3):207–210.
- Pirooz MS. Hydatid cysts of the orbit: 7 cases, 1973-1980. *Orbit*. 1983;2(1):65–68.
- Kammerer WS, Schantz PM. Echinococcal disease. *Infect Dis Clin North Am*. 1993;7(3):605.
- Eckert J, Deplazes P. Biological, epidemiological, and clinical aspects of echinococcosis, a zoonosis of increasing concern. *Clin Microbiol Rev*. 2004;17(1):107–135.
- Otero-Abad B, Torgerson PR. A systematic review of the epidemiology of echinococcosis in domestic and wild animals. *PLoS Negl Trop Dis*. 2013;7(6):e2249.
- Shoae S, Rezvanizadeh M, Haghighi M, Yousefi H. Epidemiological, clinical and paraclinical study of hydatid cysts in three educational medical centers in 10 years. *Nov Biomed*. 2016;4(1):28–33.
- Bagheri A1, Fallahi MR, Yazdani S, Rezaee Kanavi M. Two different presentations of orbital echinococcosis: a report of two cases and review of the literature. *Orbit*. 2010;29(1):51–56.
- Lentzsch AM, Gobel H, Heindl LM. Primary orbital hydatid cyst. *Ophthalmology*. 2016;123(7):1410.
- Turgut AT, Turgut M, Kosar U. Hydatidosis of the orbit in Turkey: results from review of the literature 1963-2001. *Int Ophthalmol*. 2004;25(4):193–200.
- Betharia SM, Pushker N, Sharma V, Avinash M, Kashyap S. Disseminated hydatid disease involving orbit, spleen, lung and liver. *Int J Ophthalmol*. 2002;216(4):300–304.