

A giant benign clear cell hidradenoma on the anterior trunk

Gulsen Tukenmez Demirci,¹
 Guldehan Atis,¹ Ilknur Kivanç Altunay,¹
 Damlanur Sakiz²

¹Dermatology Department and
²Pathology Department, Sisli Etfal
 Training and Research Hospital, Istanbul,
 Turkey

Abstract

Clear cell hidradenoma (CCH) is an uncommon variant of benign cutaneous adnexal tumors. These tumors are clinically asymptomatic, solitary dermal nodules. They occur most frequently on the scalp, face abdomen and extremities. Growth is slow and malignant change is rare. 45-year-old woman presented with a nodule which had begun 4 years ago as a small nodular asymptomatic lesion and had a central ulceration and a minimal hemorrhagic discharge on her anterior abdomen wall. On dermatologic examination there was a 6.5×5×4 cm non-tender, soft reddish purple nodule, with lobular appearance and ulceration. In the laboratory investigations, all hematologic and biochemical tests were normal. A computed tomography (CT) scan demonstrated a cystic tumor with lobulated contour with contrast enhancement. The lesion was excised totally. In histopathological examination, the tumor was composed of biphasic smaller dark polygonal cells and larger clear cells and coarse nuclear chromatine. There were duct like structures. Immunohistochemical investigation was done for the suspicion of malignancy. Cytoplasm of clear cells and of duct like structures showed PAS-positive and d-PAS resistant staining. There was a positive reaction to epithelial membrane antigen and carcinoembryonic antigen. The mitotic index in Ki 67 examination was low. All these findings confirmed the diagnosis of benign CCH.

Introduction

Clear cell hidradenoma (CCH) is an uncommon variant of benign cutaneous adnexal tumors, originating from eccrine glands, although there are some reports supporting an apocrine derivation.^{1,2} CCH is referred by various terms, such as nodular hidradenoma, eccrine acrospiroma, solid cystic hidradenoma, clear cell acrospiroma, clear cell myoepithe-

lioma and eccrine sweat gland adenoma. These tumors are clinically asymptomatic, solitary dermal nodules, measuring 0.5-3 cm. The scalp, face abdomen and extremities are the most frequently involved areas.³ The skin covering these lesions are usually normal in appearance, however, red to blue discoloration and occasionally ulceration can be seen.⁴ Growth is slow and malignant change is rare.³ We report, herein, a giant benign CCH similar to a metastatic skin cancer.

Case Report

We report a case of 45-year-old woman presented with a giant nodule with a central ulceration and a minimal hemorrhagic discharge on her anterior abdomen wall (Figure 1A). It had begun 4 years ago as a small nodular asymptomatic lesion without ulceration and had grown rapidly previous year.

On dermatologic examination, there was a 6.5×5×4 cm non-tender, soft reddish purple nodule, with lobular appearance and ulceration on its surface (Figure 1B). On dermoscopic examination, irregular scar like whitish areas and a polymorphous vascular pattern including irregular reddish-purple areas mimicking lacunar appearance of hemangiomas with thick hair pin vessels at the periphery were observed (Figure 2).

Her physical examination was normal. She had no prior medical problem and no family history of malignancy.

Laboratory investigations including all hematologic and biochemical tests showed no abnormality. A CT scan demonstrated a cystic tumor with lobulated contour with contrast enhancement. It was located to subcutaneous tissue and unrelated to abdominal wall muscles and there was no evidence of metastatic disease. The lesion was excised totally with wide margins. In histopathological examination the tumor was composed of biphasic smaller dark polygonal cells and larger clear cells and coarse nuclear chromatine (Figure 3). Eosinophilic hyalinized fibrous stroma interspersed within the tumor as branching trabeculae. There were duct like structures (Figure 4). Immunohistochemical investigation was done for the suspicion of malignancy. Cytoplasm of clear cells and of duct like structures showed PAS-positive and d-PAS resistant staining. There was a positive reaction to epithelial membrane antigen and carcinoembryonic antigen. The mitotic index in Ki 67 examination was low. All these findings confirmed the diagnosis of CCH. No other treatment was given after the surgery. Nevertheless, a follow up program was scheduled considering the possibility of a recurrence.

Correspondence: Gulsen Tukenmez Demirci
 Sisli Etfal Eğitim ve Araştırma Hastanesi
 Dermatoloji Kliniği 19 Mayıs Cad. Etfal sok. Sisli
 34377, Istanbul, Turkey.
 Tel: +90.212.3735000 - Fax: +90.212.3535976.
 E-mail: gulsentukenmez@yahoo.com

Key words: clear cell hidradenoma, benign, neoplasm.

Conflict of interest: the authors have no conflict of interest.

Received for publication: 10 June 2011.

Accepted for publication: 23 September 2011.

This work is licensed under a Creative Commons Attribution NonCommercial 3.0 License (CC BY-NC 3.0).

©Copyright G.T. Demirci et al., 2011
 Licensee PAGEPress, Italy
 Dermatology Reports 2011; 3:e45
 doi:10.4081/dr.2011.e45

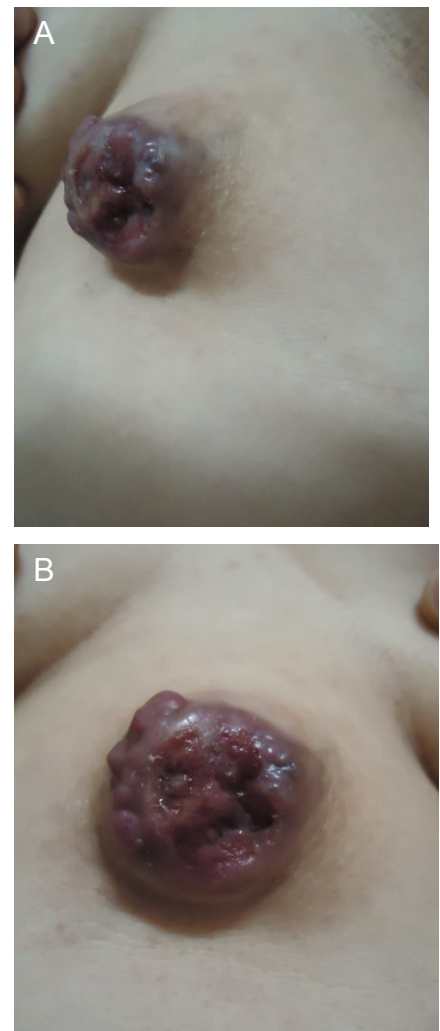


Figure 1. A,B. A giant nodule with a central ulceration on the anterior abdomen wall.

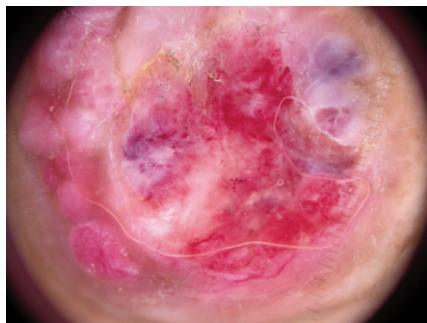


Figure 2. Irregular reddish-purple areas with irregular scattered whitish scar-like areas and hair pin vessels.

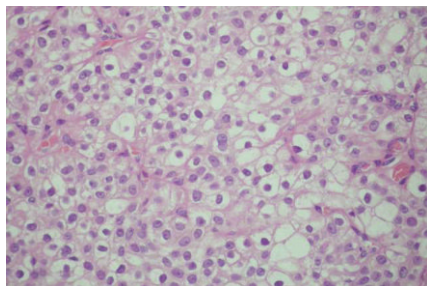


Figure 3. Biphasic smaller dark polygonal cells and larger clear cells and coarse nuclear chromatin. Hematoxylin and eosin stain; original magnification (200x).

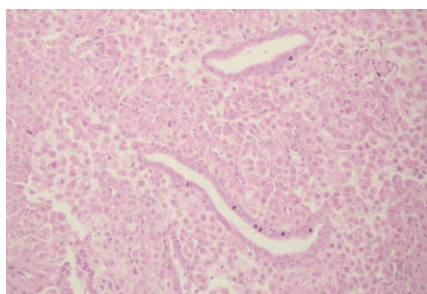

Figure 4. Eosinophilic hyalinized fibrous stroma interspersed within the tumour. A duct like structure lined by cuboidal to round tumor cells. Hematoxylin and eosin stain; original magnification (100x).

Discussion

Malignant transformation in CCH is uncommon. While benign CCHs usually occur small, asymptomatic nodules, malignant CCHs are aggressive tumors in biological behavior and likely to occur in larger diameters than benign CCHs.^{5,6} There is a single case report in the literature, in which the patient had a benign CCH in unusual size.⁷

Most of the tumors reported in the literature are small round red or skin colored nodules or sometimes subcutaneous lesions are misdiagnosed as epidermoid cysts.⁸ Ulcer formation is also rare. Our patient's lesion was initially considered to be a cutaneous metastasis or a malignant cutaneous tumor such as angiosarcoma, dermatofibrosarcoma protuberans because of large ulcerated lobular appearance. Ulcerated lobular appearance was also interesting in our patient, which probably sprang from size of the tumor.

Dermoscopic features of these tumors have very rarely been described. Yoshida et al defined the dermoscopic features of two CCHs.⁹ They saw whitish, red and purple areas unlike those of hemangiomas with linear and hairpin like vessels at the periphery. In fact, so-called polymorphous vascular appearance has been previously described in some benign and malignant tumors as well.^{5,6} It is very likely that these areas present hemorrhagic cystic spaces of CCH. Our dermoscopic findings were similar to their findings. Dermoscopic examination might be only a helpful diagnostic method in preliminary diagnosis of these tumors.

Although surgical excision appears to be curative in these tumors, it should be kept in mind that close follow up is essential because of the possibility of a recurrence and silent local malignant change.¹⁰

References

1. Taylor ST, Perone JB, Kaddu S et al. Appendage tumors and hamartomas of the skin. In Wolff K, Lowell A, Goldsmith S. et al. Fitzpatrick's Dermatology in General Medicine. 7th ed; Vol I; New York. Mc Graw Hill. 2003;897-8.
2. Obadiat NA, Alsaad OK, Ghazarian D. Skin adnexial neoplasms-part 2: An approach to tumours of cutaneous sweat glands. *J Clin Pathol* 2007;60:145-9.
3. Mackie RM, Calonje E. Tumours of the skin appendages. In Burns T, Breathnach S, Cox N et al. Rook's textbook of dermatology. 7th ed; Vol II; Oxford. Blackwell Science 2004;3721-2.
4. Schweitzer WJ, Goldin HM, Bronson DM, et al. Ulcerated tumor on the scalp: clear cell adenoma. *Arc Dermatol* 1989;125:985-9.
5. Ozawa T, Fujiwara M, Nose K et al. Clear cell hidradenoma of the forearm in a young boy. *Pediatr Dermatol* 2005;22:450-2.
6. Ohta M, Hiramato M, Fuji M, Togo T. Nodular Hidradenocarcinoma on the scalp of a young woman: a case report and review of the literature. *Dermatol Surg* 2004;30:1265-8.
7. Yu G, Goodloe S Jr, D'Angelis CA et al. Giant clear cell hidradenoma of the knee. *J Cutan Pathol* 2010;37:e37-41.
8. Sakuma T, Ohashi H, Kawano K. Nodular hidradenoma masquerading an epidermal cyst. *JEADV* 2008;22:900-1.
9. Yoshida Y, Nakashima K, Yamamoto O. Dermoscopic features of clear cell hidradenoma. *Dermatology* 2008;217:250-1.
10. Will Ryan, Coldiron B, Coldiron B. Recurrent clear cell hidradenoma of the foot. *Dermatol Surg* 2000;26:685-6.