

Received: 2019.07.07
Accepted: 2019.08.19
Published: 2019.10.26

Diffuse Deep T-Wave Inversions Following a Generalized Seizure

Authors' Contribution:
Study Design A
Data Collection B
Statistical Analysis C
Data Interpretation D
Manuscript Preparation E
Literature Search F
Funds Collection G

ABEF **Graeme Proserpi-Porta**
ABEF **Christopher Oleynick**

Cumming School of Medicine, University of Calgary, FMC North Tower, Calgary, Alberta, Canada

Corresponding Author: Graeme Proserpi-Porta, e-mail: graeme.proserpiporta@ucalgary.ca
Conflict of interest: None declared

Patient: Female, 44
Final Diagnosis: Stress induced cardiomyopathy
Symptoms: Seizure
Medication: —
Clinical Procedure: —
Specialty: Cardiology

Objective: Mistake in diagnosis





Background: Stress cardiomyopathy (SCM) is a transient dysfunction of the left ventricle due to physical or emotional triggers that produces a range of electrocardiogram (ECG) changes. While ST-segment elevation or depression often leads to more urgent investigation and diagnosis, T-wave inversions can result in delayed diagnosis.

Case Report: A 44-year-old woman with a prior left middle cerebral artery septic embolic stroke from endocarditis resulting in residual dense right sided hemiparesis and aphasia was admitted to the hospital for treatment of *Staphylococcus aureus* bacteremia. While hospitalized, she experienced a generalized seizure that was aborted with lorazepam and then loaded with phenytoin. Her ECG following the seizure showed a prolonged QT interval, for which her methadone that she was stabilized on during hospitalization was held. Her ECG to follow-up on her QT interval 25 h following the seizure showed new diffuse symmetric deep T-wave inversions. While initially believed to be due to the either the discontinuation of methadone or initiation of phenytoin, retrospective analysis revealed that these changes were more suggestive of a missed SCM.

Conclusions: We report a patient who experienced a generalized seizure resulting in diffuse, symmetric, deep T-wave inversions that were incorrectly attributed to medication effects before identifying the likely diagnosis of SCM. Fortunately for this patient, there were no consequences of the delayed diagnosis, but this case emphasises the importance of considering SCM following a generalized seizure in any patient with ECG abnormalities.

MeSH Keywords: Electrocardiography • Seizures • Takotsubo Cardiomyopathy

Full-text PDF: <https://www.amjcaserep.com/abstract/index/idArt/918566>

 1181   1  8



Background

Stress cardiomyopathy (SCM) is defined as a transient dysfunction of the left ventricle due to physical or emotional triggers, such as seizures, that cause electrocardiogram (ECG) changes and typically mild elevations in cardiac enzymes, carrying a 30 day mortality of 4–6% [1,2]. Epilepsy is a common condition that has a lifetime prevalence of 7.6 per 1000 persons, with 57% of these patients having generalized seizures [3]. SCM following seizures can present with ECG findings of ST-segment elevation or depression, ventricular tachycardia or fibrillation, and T-wave inversions, with T-wave inversions being present in approximately 40% of patients with seizure SCM [4]. We report the case of a patient with a pre-existing septal embolic stroke who was found to have diffuse deep electrocardiogram T-wave inversions following a generalized seizure, which were incorrectly diagnosed due to confounding medications, but in hindsight should have had urgent cardiac imaging, as the diagnosis was most suggestive of a stress cardiomyopathy.

Case Report

A 44-year-old woman was admitted to the hospital for treatment of *Staphylococcus aureus* bacteremia caused by ongoing intravenous opioid use complicated by L4/L5 discitis. She had completed 14 days of intravenous antibiotics following negative blood cultures and had a transesophageal echocardiogram that showed no evidence of infectious endocarditis. On a prior admission, the patient had been successfully treated for

Staphylococcus aureus infectious endocarditis that embolized to her left middle cerebral artery resulting in residual dense right-sided hemiparesis and aphasia. She was stabilized on methadone during her prior hospitalization for her opioid use disorder. While admitted to hospital, the patient became unresponsive and developed right upward eye deviation followed by generalized tonic-clonic convulsions lasting 5 min before being aborted with intravenous lorazepam (1 mg). The patient then received a loading dose of intravenous phenytoin (20 mg/kg). During the seizure, the patient had a brief episode of tachycardia and hypertension, which quickly returned to the patient's baseline within hours of the seizure and remained stable during the remainder of her admission. She denied any shortness of breath, angina, or angina equivalents following the seizure and had no new focal neurologic signs or symptoms.

An ECG was performed 20 min following the seizure, which showed a heart rate of 96 bpm, sinus rhythm, a pre-existing left anterior fascicular block, and a prolonged QTc interval of 533 ms. Due to the prolonged QT interval seen on this ECG, the patient's methadone was stopped. A repeat ECG 25 h after the seizure was performed to follow up on the QT interval (Figure 1), which showed sinus bradycardia at a rate of 53 bpm, a persistent left anterior fascicular block, and new diffuse, symmetric, deep T-wave inversions in limb leads I, II, aVF, aVL, and aVR, as well as precordial leads V1-V6. An electroencephalogram 1 day following her seizure showed moderate suppression in the left hemisphere, consistent with the underlying structural lesion and mild generalized slowing with no epileptiform discharges.

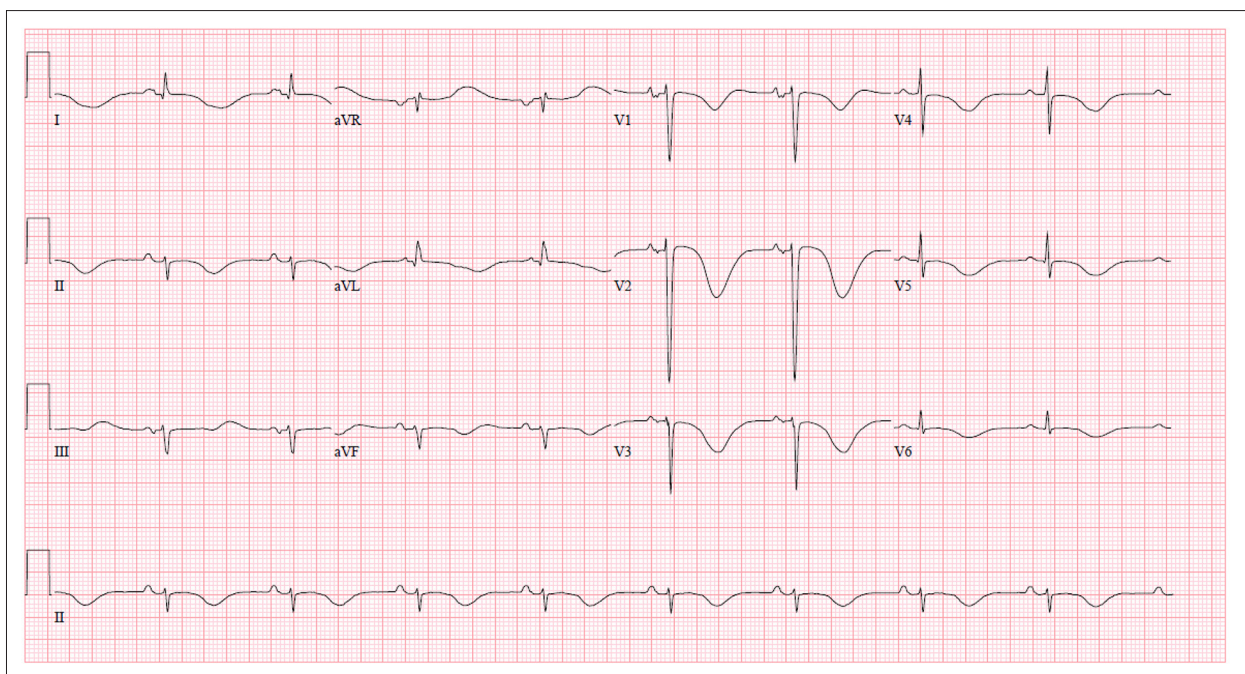


Figure 1. A 12-lead electrocardiogram 25 h following onset of seizure (25 mm/s, 10 mV/mm, 100 Hz).

Bloodwork revealed extended electrolytes, renal function, and hepatic function that were stable and within normal limits. The patient's high-sensitivity troponin T from 1 day prior to the seizure was 7 ng/L and her repeat immediately following the seizure was elevated to 15 ng/L (0–14 ng/L) and 16 ng/L 24 h later. A computed tomography (CT) scan of her head 28 h following the seizure showed a chronic left middle cerebral artery infarction with no interval change. Given the temporal relationship with the ECG changes and the patient's medication changes, she was started on extended-release morphine to avoid opioid withdrawal, and the phenytoin was discontinued and levetiracetam was initiated.

Serial ECGs were performed following the diffuse T-wave inversions, which showed gradual improvement until 11 days after the seizure, when the ECG returned to the patient's baseline. After reviewing the case, it was felt that a SCM was more compatible with the clinical and biochemical findings. Therefore, on day 11 following the seizure, a bedside cardiac ultrasound was performed to examine the left and right ventricular function, which by that time was normal.

Discussion

We report the case of a patient who experienced a generalized tonic-clonic seizure and who developed diffuse, symmetric, deep T-wave inversions on ECG 25 h later that, in hindsight, is suggestive of a SCM. The patient had no electrolyte abnormalities, no clinical evidence of cardiac or respiratory abnormalities, and her repeat CT head showed no interval change, but she had been recently started on phenytoin and her methadone had been stopped. Given the temporal relationship between the discontinuation of methadone and initiation of phenytoin with the diffuse, deep T-wave inversions, it was initially believed that these pharmacologic agents were causative. While acute precipitated methadone withdrawal can cause T-wave inversions and SCM, this is unlikely in this case based on the pharmacokinetics of methadone [5]. Although ECG changes can occur with supratherapeutic phenytoin levels, no reports have directly linked phenytoin to the ECG abnormalities seen in this case. The minimal troponin elevation above the normal range, lack of significant hemodynamic changes, and confounding medications made the diagnosis of SCM more difficult to identify and delayed in our patient. Stollberger et al.

showed that T-wave inversions are present in approximately 40% of patients with seizure-related SCM, and more commonly result in a delayed diagnosis of SCM compared to other ECG findings [4]. Ramaraj et al. showed that the degree of left ventricular dysfunction is correlated with troponin elevation, which is likely why this patient did not show significant cardiovascular signs or symptoms following the seizure [6]. Similar to this case, Namgung et al. showed that T-wave inversions typically appear 24 h following the seizure and disappear by day 10 [7]. Although not performed until SCM was considered as a potential etiology of her ECG abnormalities, our patient's ventricular function was normal on day 11 by bedside cardiac ultrasound. This is consistent with a study by Shaikh et al. that showed that the median time to left ventricular dysfunction is 7 days [8]. Due to the delayed diagnosis of SCM, we were unable to confirm the classic apical left ventricular dysfunction, but in hindsight, this patient's clinical, biochemical, and ECG findings are more suggestive of an SCM caused by the generalized seizure. Fortunately for this patient, there was no hemodynamic consequence of delayed consideration of SCM and the patient recovered to her neurologic and cardiovascular baseline.

Conclusions

This case summarizes the diagnostic challenges in a patient with diffuse T-wave inversions following a generalized seizure, and outlines the importance of performing urgent cardiac imaging to rule out an SCM. Diffuse T-wave inversions have a broad differential, including cardiac, respiratory, intracranial, electrolyte, and medication etiologies. An ECG should be considered following a generalized seizure to screen for SCM, especially when any cardiac symptoms, hemodynamic changes, or elevated cardiac enzymes are present. ECG changes caused by SCM include ST-segment elevation or depression, ventricular arrhythmias, and diffuse T-wave inversions. SCM should be considered early in any patient with diffuse T-wave inversions as it has a 30-day mortality rate of 4–6%. Cardiac imaging should be performed immediately when ECG abnormalities are seen following a seizure to screen for SCM.

Conflicts of interests

None.

References:

1. Stiermaier T, Thiele H, Eitel I: Prognosis in patients with Takotsubo cardiomyopathy. *JACC Heart Failure*, 2016; 4(6): 519–20
2. Ghadri JR, Wittstein IS, Prasad A et al: International expert consensus document on Takotsubo syndrome (Part I): Clinical Characteristics, Diagnostic Criteria, and Pathophysiology. *Eur Heart J*, 2018; 39(22): 2032–46
3. Fiest KM, Sauro KM, Wiebe S et al: Prevalence and incidence of epilepsy: A systematic review and meta-analysis of international studies. *Neurology*, 2017; 88(3): 296–303
4. Stollberger C, Sauerberg M, Finsterer J: Immediate versus delayed detection of Takotsubo syndrome after epileptic seizures. *J Neurol Sci*, 2019; 397: 42–47
5. Saiful FB, Lafferty J, Jun CH et al: Takotsubo cardiomyopathy due to iatrogenic methadone withdrawal. *Rev Cardiovasc Med*, 2011; 12(3): 164–67
6. Ramaraj R, Sorrell VL, Movahed MR: Levels of troponin release can aid in the early exclusion of stress-induced (takotsubo) cardiomyopathy. *Exp Clin Cardiol*, 2009; 14(1): 6–8
7. Namgung J: Electrocardiographic findings in Takotsubo cardiomyopathy: ECG evolution and its difference from the ECG of acute coronary syndrome. *Clin Med Insights Cardiol*, 2014; 8: 29–34
8. Shaikh N, Sardar M, Jacob A et al: Possible predictive factors for recovery of left ventricular systolic function in Takotsubo cardiomyopathy. *Intractable Rare Dis Res*, 2018; 7(2): 100–5