

A case of a delayed granulomatous reaction on the face following microneedling: A case report

SAGE Open Medical Case Reports
JCMS Case Reports
Volume 10: 1–3
© The Author(s) 2022
Article reuse guidelines:
sagepub.com/journals-permissions
DOI: 10.1177/2050313X221102489
journals.sagepub.com/home/sco



Emma Heck  and Danya Traboulsi 

Abstract

Background: Microneedling is a common non-invasive procedure used for a variety of dermatologic conditions. It is associated with a low rate of adverse events which are typically temporary. Hypersensitivity reactions, including granuloma formation, are a rare adverse event, with only 10 cases previously reported.

Case Summary: We report a case of a 49-year-old female who presented with asymptomatic edematous erythematous annular plaques on her left cheek following a microneedling procedure in which a Vitamin C cosmeceutical was applied to the skin beforehand. Skin biopsy confirmed non-necrotizing granulomatous dermatitis with negative tissue cultures. Systemic workup for sarcoidosis was negative.

Conclusion: Delayed facial granulomatous reaction is an uncommon adverse event following microneedling. Increased risk may be related to peri-procedure use of cosmeceuticals such as Vitamin C. Given the popularity of microneedling, and that it is an unregulated procedure, it is important for dermatologists to be aware of this possible sequela in order to counsel patients appropriately and understand management options.

Keywords

Microneedling, adverse events, granulomatous reaction, granulomas

Introduction

Microneedling is a common non-invasive procedure in which fine needles are used to puncture the epidermis. These microchannels act as a controlled skin injury, stimulating the dermal wound healing cascade with minimal epidermal damage. Through the repair of these microwounds, growth factors are released, and collagen production is stimulated. Thus, microneedling has become a popular treatment choice in the realm of facial rejuvenation as well as for a myriad of other dermatologic concerns. Studies have shown microneedling safety and efficacy for the treatment of acne scarring, surgical scars, rhytides, melasma, photodamage, skin rejuvenation, hyperhidrosis, alopecia and for facilitation of transdermal drug delivery.^{1,2}

The limited side effects of microneedling contribute to its popularity among patients looking for a safe and efficacious procedure with minimal down time. Adverse events (AEs) are rare and generally temporary, including pin-point bleeding that resolves within minutes of the procedure, mild erythema, edema, scaling, mild pain, and post-inflammatory dyspigmentation. Hypersensitivity reactions, including granuloma formation, are rarely reported events with risk related

to the use of topical products applied prior to the procedure.^{1–3} We report the 11th case of a delayed facial granulomatous reaction following a microneedling procedure.

Case report

A 49-year-old female presented to outpatient dermatology with a 2-month history of an erythematous asymptomatic facial eruption. The eruption started on her left cheek 2 weeks after undergoing microneedling at a local MediSpa. Perioperatively, a vitamin C serum was applied to her face. The only other product applied was an over-the-counter face mask the evening before the onset of the eruption. The patient was otherwise systemically well. She was healthy and on no medications. Physical exam

Division of Dermatology, Department of Medicine, University of Calgary, AB, Canada

Corresponding Author:

Danya Traboulsi, Division of Dermatology, Department of Medicine, University of Calgary, Suite 201, 3110 17th Ave SW, Calgary, AB T3E 2C4, Canada.

Email: dtraboulsi@qmed.ca



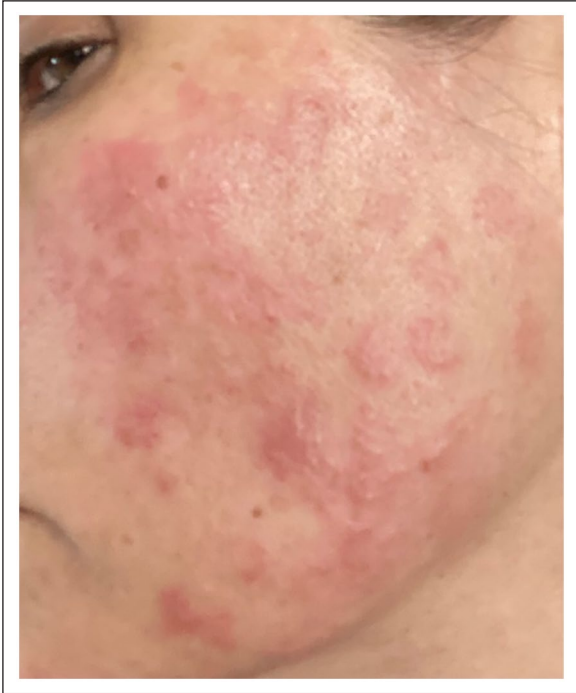

Figure 1. Ill-defined erythematous edematous annular plaques with no overlying superficial skin change on the left cheek.

demonstrated edematous erythematous annular plaques with no overlying superficial skin change on the left cheek (Figure 1). She had no lymphadenopathy.

A biopsy taken from the left cheek showed non-necrotizing granulomatous dermatitis. Tissue stains (periodic-acid-Schiff, Fite and Ziehl-Neelsen) were negative, and tissue culture was negative for fungus, bacteria, and mycobacteria. No polarizable material was observed. A systemic workup to rule out sarcoidosis was all within normal limits including complete blood count, renal and liver function tests, liver enzymes, C-reactive protein, antinuclear antibody, immunoglobulins, angiotensin converting enzyme level, ionized calcium, and chest X-ray. Ophthalmology found no ocular findings suggestive of sarcoidosis.

She was diagnosed with a delayed facial granulomatous reaction to microneedling. Initial treatment with topical clobetasol 0.1% ointment twice daily for 6 weeks resulted in some improvement, but not clearance. Subsequent treatment with intralesional triamcinolone acetonide 5 mg/mL attained subtle further improvement. The patient was then prescribed doxycycline 100 mg PO bid, but moved provinces and never initiated antibiotics. At the time of writing, she indicated her rash was still visible but declined further referral to dermatology in her new province.

Discussion

We report a unique case of a delayed facial granulomatous reaction to microneedling. This is a rare complication, with

only 10 previous cases found upon review of the literature.^{4–11} Soltani-Arabshahi et al. originally described three similar cases of women who developed facial granulomas following microneedling, with evidence of foreign body-type granulomas on biopsy and a positive patch test reaction to vitamin C serum in two cases. They hypothesized that these cases represented true delayed-type hypersensitivity granulomas secondary to an immunologic response after intradermal tattooing of an antigenic topical product.⁴ In other cases, the needles themselves have been the antigenic source for post-microneedling cutaneous reactions, with patients demonstrating an allergy to nickel on patch testing.^{5,6} We suspect a similar mechanism underlying our patient's presentation, with either the vitamin C topical or the nickel in the needle acting as the antigen source.⁵ Unfortunately, she relocated provinces before further investigations could be pursued.

Reported therapies for facial granulomatous reactions following microneedling include topical, intralesional and oral corticosteroids, topical calcineurin inhibitors, and oral tetracyclines (doxycycline and minocycline).^{4–8} Based on our search of the limited case reports, the efficacy of these therapies is variable. A case of granulomatous dermatitis following microneedling of striae distensae on the thigh was successfully treated with oral fumaric acid ester (Fumaderm®).⁹ More recently, Martin and Huang¹⁰ reported successful treatment of microneedling-associated granulomatous dermatitis with Methotrexate.

In the assessment of these patients, other aetiologies of granulomatous inflammation must be excluded, including infections, sarcoidosis, and foreign body reactions. Our patient had negative tissue stains and cultures, and a negative sarcoidosis workup. In Soltani-Arabshahi et al.'s⁴ original report of granulomatous dermatitis following microneedling, polarizable material was observed in the biopsy specimen, whereas in subsequent reports, similar to our case, no polarizable material was observed.¹⁰ Whether the granulomatous reactions following microneedling represent foreign body reactions to the cosmeceutical injected into the skin during the procedure, true allergic type IV hypersensitivity reactions, or an overlap between the two processes is unclear.

We report a case of a delayed facial granulomatous reaction to microneedling. The frequent perioperative use of cosmeceuticals such as vitamin C serum may contribute to the risk of this reaction, since the channels created during the procedure create a gateway for antigen particle deposition into the dermis. Given the popularity of microneedling, and that it is an unregulated procedure, it is important for dermatologists to be aware of this possible sequela in order to counsel patients appropriately and understand management options.

Acknowledgements

The authors thank Dr Thomas Brenn for his review and assistance with the pathology of the case.

Declaration of conflicting interests

The author(s) declared no potential conflicts of interest with respect to the research, authorship, and/or publication of this article.


Funding

The author(s) received no financial support for the research, authorship, and/or publication of this article.

Informed consent

Patient provided consent for publication of the case report and images.

ORCID iDs

Emma Heck  <https://orcid.org/0000-0002-5055-5771>

Danya Traboulsi  <https://orcid.org/0000-0002-8258-5203>

References

1. Alster TS and Graham PM. Microneedling: a review and practical guide. *Dermatol Surg* 2018; 44(3): 397–404.
2. Hou A, Cohen B, Haimovic A, et al. Microneedling: a comprehensive review. *Dermatol Surg* 2017; 43(3): 321–339.
3. Gowda A, Healey B, Ezaldein H, et al. A systematic review examining the potential adverse effects of microneedling. *J Clin Aesthet Dermatol* 2021; 14(1): 45–54.
4. Soltani-Arabshahi R, Wong JW, Duffy KL, et al. Facial allergic granulomatous reaction and systemic hypersensitivity associated with microneedle therapy for skin rejuvenation. *JAMA Dermatol* 2014; 150(1): 68–72.
5. Yadav S and Dogra S. A cutaneous reaction to microneedling for postacne scarring caused by nickel hypersensitivity. *Aesthet Surg J* 2016; 36(4): NP168–NP170.
6. Pratsou P and Gach J. Severe systemic reaction associated with skin microneedling therapy in 2 sisters: a previously unrecognized potential for complications? *J Am Acad Dermatol* 2013; 68(Suppl. 1): AB219.
7. Moshiri A, Solotoff S, Nguyen C, et al. Facial granulomatous dermatitis after microneedling therapy. In: *24th world congress of dermatology*, 10–15 June 2019, Milan, <https://www.wcd2019milan-dl.org/abstract-book/documents/abstracts/03-aesthetic-cosmetic-dermatology/facial-granulomatous-dermatitis-after-microneedling-1869.pdf> (accessed 15 July 2021).
8. Cervantes J, Hafeez F and Badiavas EV. Erythematous papules after microneedle therapy for facial rejuvenation. *Dermatol Surg* 2019; 45(10): 1337–1339.
9. Eisert L, Zidane M, Waigandt I, et al. Granulomatous reaction following microneedling of striae distensae. *J Dtsch Dermatol Ges* 2019; 17(4): 443–445.
10. Martin ED and Huang WW. Resolution of microneedling-associated granulomatous dermatitis with oral methotrexate. *JAAD Case Rep* 2021; 10: 96–98.
11. Demaree E, Cleaver D, Cleaver L, et al. 16622 Granulomatous reaction to microneedling. *JAAD* 2020; 83(6): AB67.