

Dysembryoplastic Neuroepithelial Tumor of the Infratentorial Multiple Lesions: A Case Report and Review of the Literature

Kiyohide KAKUTA,¹ Kenichiro ASANO,¹ Norihito SHIMAMURA,¹
Akira KUROSE,² and Hiroki OHKUMA^{1,3}

¹Department of Neurosurgery, Hirosaki University Graduate School of Medicine, Hirosaki, Aomori, Japan

²Department of Anatomic Pathology, Hirosaki University Graduate School of Medicine, Hirosaki, Aomori, Japan

³Department of Neurosurgery, National Hospital Organization, Hirosaki National Hospital, Hirosaki, Aomori, Japan

Abstract

A dysembryoplastic neuroepithelial tumor (DNT) is a benign neoplasm that usually occurs in the supratentorial cerebral cortex. Here, we report a rare case of an infratentorial DNT in a 42-year-old woman who presented with dizziness and a gait disturbance. Magnetic resonance imaging of the lesion demonstrated hyperintensity on T2-weighted images and hypointensity on T1-weighted images of the left cerebellar hemisphere with a multifocal lesion. Macroscopically, the lesion appeared soft, avascular, and slightly torose at the cortical surface. Histologically, dysplastic disorganization of the cortex and floating neurons were observed. The pathological and immunochemical features of this case agree with the diagnosis of a DNT. The lesion partially included cortical heterotopia, which is a novel observation in an infratentorial DNT. On the basis of the previous reports, we discussed the surgical resection of the infratentorial DNT.

Keywords: dysembryoplastic neuroepithelial tumor, cerebellar tumor, infratentorial tumor

Introduction

A dysembryoplastic neuroepithelial tumor (DNT) is a benign lesion that corresponds to a World Health Organization (WHO) grade I tumor and has the characteristics of a hamartoma. DNT usually manifests in the temporal lobe as a glial-neuronal tumor¹⁾ and is associated with drug-resistant partial seizures. In unusual cases, DNTs have been reported to occur in the posterior fossa and instead present with ataxia or vertigo.²⁻⁴⁾ We present a case of an infratentorial DNT and discuss the strategy of adequate treatment based on previous reports.

Case Report

A 47-year-old woman was admitted with a 3-month history of dizziness and a gait disturbance, but no ataxia or nystagmus (Karnofsky performance status [KPS] 80%). The

patient had no family history of central neuronal system abnormalities or other relevant disease. Computed tomography (CT) showed a low-density area and calcification of the left cerebellar hemisphere (Fig. 1a). No enhancement was observed on CT. Magnetic resonance imaging (MRI) also showed multiple lesions of the left cerebellar hemisphere and vermis (Fig. 1b-d); the lesions appeared as hypointensities on T1-weighted images and hyperintensities on T2-weighted images. No enhancement was observed after gadolinium injection. Cerebral angiography showed no tumor stain in a six-vessel study, and a thallium single-photon emission computed tomography (TI-SPECT) scan showed no abnormal uptake. Accordingly, a low-grade glioma was assumed as the preoperative diagnosis. Written informed consent was obtained from the patient before surgery.

A left-sided suboccipital craniectomy was performed. Macroscopically, the lesion appeared soft, avascular, and

Received November 9, 2021; Accepted February 4, 2022

Copyright © 2022 The Japan Neurosurgical Society

This work is licensed under a Creative Commons Attribution-NonCommercial-NoDerivatives International License.

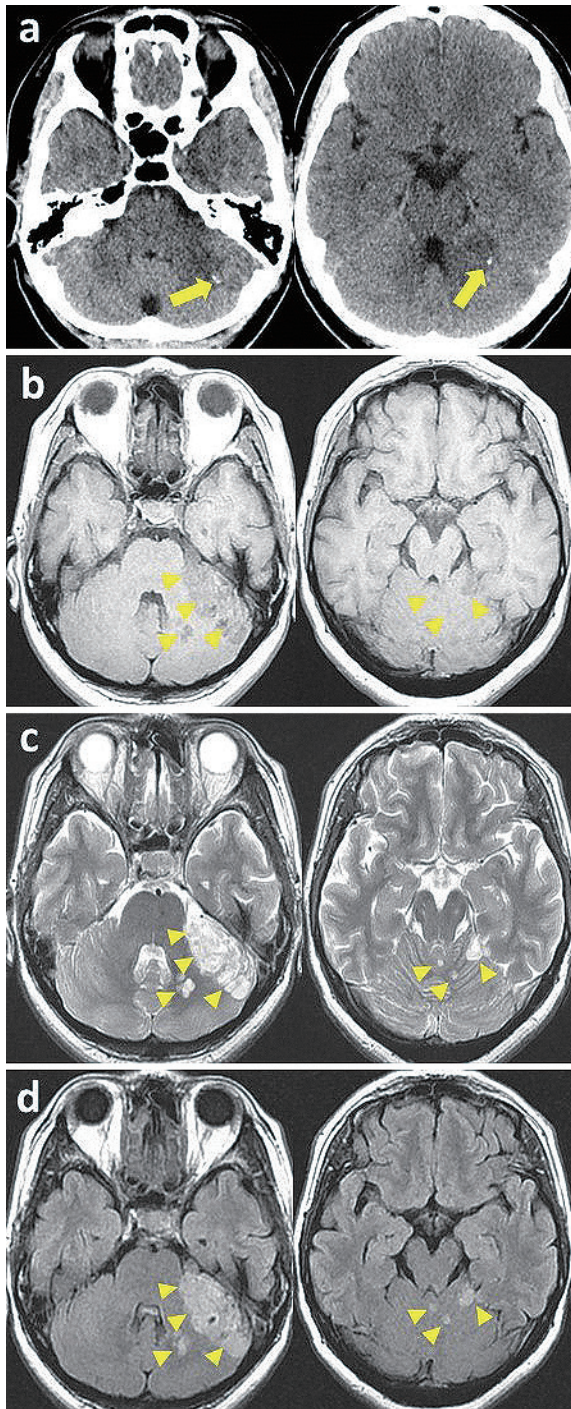


Fig. 1 (a) Preoperative computed tomography (CT) scan showing a low-density area containing a focal calcified hyperdense lesion in the left cerebellar hemisphere (arrows). (b-d) Preoperative magnetic resonance imaging (MRI) scan showing multiple lesions in the left cerebellar hemisphere and vermis (arrowheads). (b) T1-weighted image showing hypointensity. (c) T2-weighted and (d) fluid-attenuated inversion recovery (FLAIR) image showing hyperintensity. Notably, there is no peri-tumoral edema or space-occupying effect.

slightly torose at the cortical surface. The boundary was well defined but could not detached from the cerebellar hemisphere (Fig. 2a). These findings supported the conclusion that the lesion was an intra-axial tumor. This lesion showed barely visible 5-aminolevulinic acid (5-ALA) fluorescence (Fig. 2b). Several pieces of the left cerebellar hemisphere were removed for biopsy (Fig. 2c). The intraoperative frozen section diagnosis was cortical dysplasia, and the operation was therefore terminated. The patient had no postoperative complications. The symptoms improved spontaneously. She was discharged from the hospital on postoperative day 12 (KPS 100%).

A histological examination of the lesion showed oligodendrocyte-like cells (OLCs), with round medium-sized nuclei that were distributed over a wide range (Fig. 3 a). The background was edematous, with a viscous consistency, and small myxoid cystic lesions including differentiated neurons, which corresponded to “floating neuron,” were observed (Fig. 3b). A chicken-wire-like vascular pattern was also identified. These features satisfied the criteria of a DNT, and the part of the lesion containing cells that resembled neurons was considered to be equivalent to cortical heterotopia. Neurons in various stages of differentiation with round nuclei, defined nucleoli, and eosinophilic reticulum were intermixed with OLCs (Fig. 3c).

A part of the lesion extended into the cerebellar cortex. On immunohistochemistry, olig2 labeling indicated the presence of OLCs (Fig. 3d). Chromogranin A (Fig. 3e) and neuronal nuclei (NeuN) labeling indicated differentiated neurons. The neuropil around the cells was positive for synaptophysin. Neurons within the cortical heterotopia were positive for chromogranin A, NeuN, and olig2. The MIB-1 staining index was less than 1%. Glial fibrillary acidic protein (GFAP)-positive cell processes were densely observed throughout the lesion (Fig. 3f). Sanger sequencing revealed no mutations in IDH-1, IDH-2, BRAF and TERT genes (Supplementary Fig. 1a-d). Multiplex ligation-dependent probe amplification (MLPA) analysis revealed that neither IDH mutation nor 1p19q codeletion had been detected in the lesion (Supplementary Fig. 1e). This genetic profile suggests that the lesion is negative for oligodendroglioma. Given these histological and genetic characteristics, the lesion was determined to be a DNT that extended into the cerebellar cortex, contained neurons at various stages of differentiation, and involved cortical heterotopia.

Discussion

A DNT was first identified in 1988 in temporal lobectomy specimens removed for the treatment of epilepsy.¹⁾ A DNT was initially observed as a group of tumors with superficial resemblance to small oligodendroglioma and considered to be hamartomatous. Later, however, Daumas-Duport et al. proposed the concept of a DNT with characteristics consistent with the WHO-classified glial-neuronal

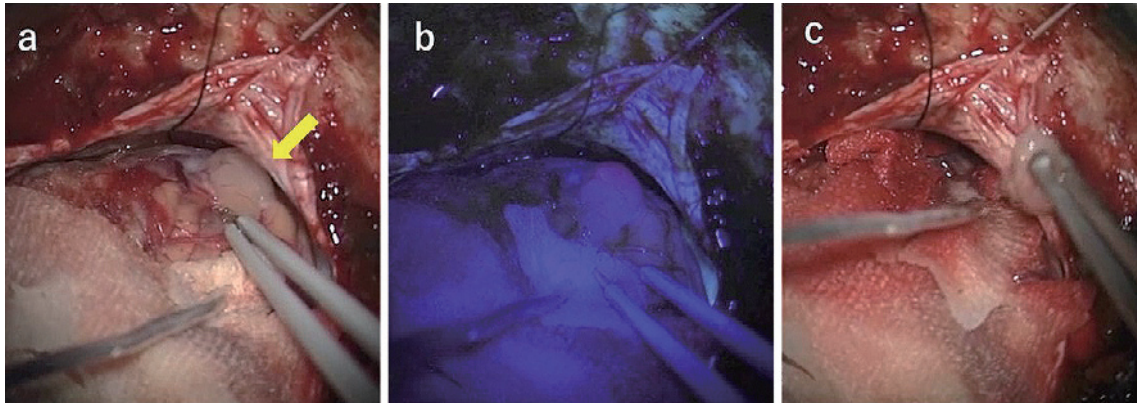


Fig. 2 Intraoperative photograph during resection of the left cerebellar tumor. (a) The lesion (arrow) was gray and well circumscribed. (b) The lesion was observed with slight fluorescence induced by 5-aminolevulinic acid (5-ALA). (c) Partial resection was performed.

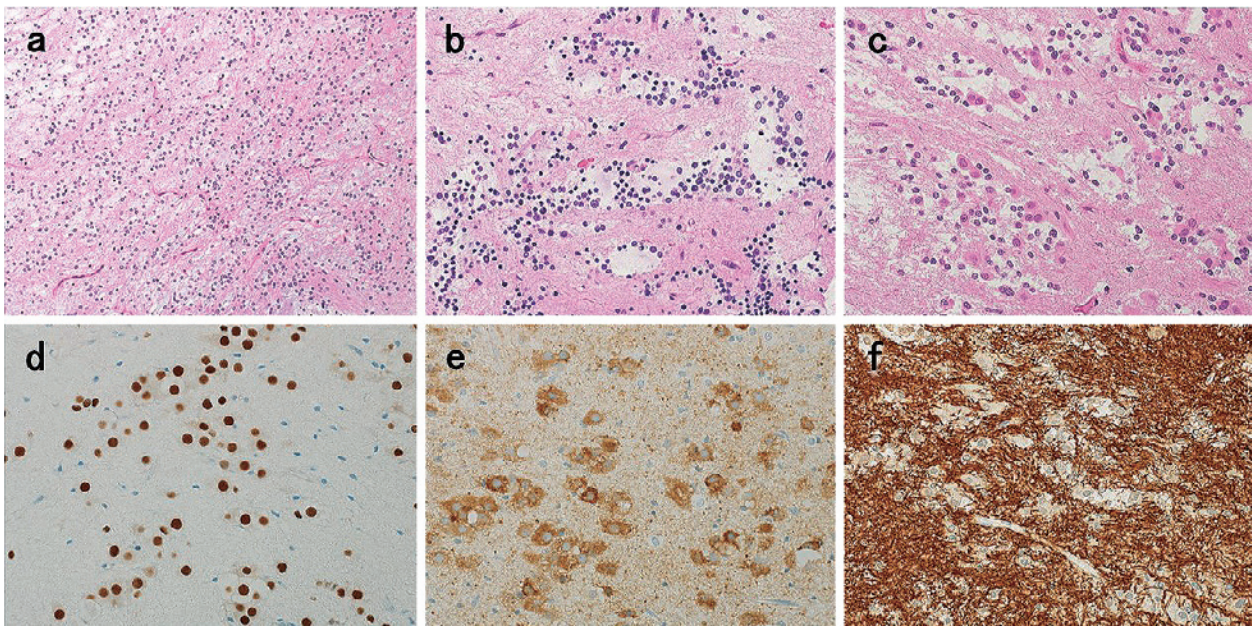


Fig. 3 (a) Photomicrography of the lesion shows oligodendrocyte-like cells (OLCs) and specific neuroglial elements distributed over a wide range (hematoxylin–eosin stain [H&E], $\times 40$). (b) Floating neurons are observed in the myxoid interstitial tissue (H&E, $\times 100$). (c) Neurons at various stages of differentiation are observed with round nuclei, defined nucleoli, and eosinophilic reticulum intermixed with OLCs (H&E, $\times 200$). (d) Olig2-positive cells ($\times 200$). (e) Chromogranin A-positive cells ($\times 200$). (f) Glial fibrillary acidic protein (GFAP)-positive cell processes are densely observed throughout the lesion ($\times 200$).

neoplasm (grade I).¹⁾ A DNT is indeed a benign, mixed glial-neuronal neoplasm characterized by an intracortical location, multinodular architecture, and heterogeneous cellular composition.¹⁾ The most important histological hallmark of DNT is the specific glioneuronal element, which is a structure formed by bundles of axons lined with small OLCs and oriented in columns perpendicular to the cortical surface. Between these columns, floating neurons can be observed, which are neurons with normal cytology that appear to float in a pale, eosinophilic matrix.^{5,6)} The OLCs express glial markers, including the S-100 protein and glial transcription factor Olig2. GFAP is absent in OLCs,

whereas the stellate astrocytes within the specific glioneuronal element are positive for GFAP.⁷⁾

A DNT is generally located in the temporal lobe, and it is associated with early-onset complex partial seizures that progress to medically intractable epilepsy before the age of 20 years.¹⁾ In previous reports, there is a slight sex predominance among male.⁷⁾ The typical age of clinical presentation ranges between 2 and 23 years,^{1,8,9)} with 85% of patients under the age of 15 years;¹⁾ however, DNTs have been reported as early as 16 months¹⁰⁾ and as late as 75 years.¹¹⁾ The most common location is in the temporal lobe (62%),^{1,9,12-15)} but DNTs can be detected in any lobe of the

Table 1 Reported cases of infratentorial DNTs

Author	Age (years)	Sex	Location	Region	Initial symptoms	Operation	Clinical course
Kuchelmeister et al. ²⁾	28	Female	Vermis	Single	Vertigo	Gross total removal	Uneventful
Fujimoto et al. ³⁾	44	Female	Right cerebellar hemisphere, vermis, tonsil, brainstem	Multiple	Ataxia	Right cerebellar hemisphere lobectomy, tonsillectomy	Uneventful
Yasha et al. ⁴⁾	20	Male	Cerebellar tonsil	Single	Ataxia	Decompression of the lesion, third ventriculostomy	No clinical progression
Leung et al. ²²⁾	10	Female	Right temporal lobe, bilateral thalamus, right cerebellar hemisphere, pons	Multiple	Epilepsy	Right temporal lobectomy	Improved
Han et al. ²³⁾	10	Female	Right temporal lobe, basal ganglia, thalamus, cerebellum, periventricular white matter	Multiple	Seizure, mild intellectual disability	Right temporal tumor removal	Seizure free
Kurtkaya-Yapicier et al. ²⁴⁾	51	Male	Midbrain tectum	Single	Headache, gait ataxia	Gross total removal	Improved
Vaquero et al. ²⁵⁾	21	Female	Left cerebellar hemisphere	Single	Gait instability, headache, diplopia	Gross total removal	Symptom free
Litrico et al. ²⁶⁾	26	Female	Left cerebellar hemisphere	Single	Vertigo	Partial resection	NA
Nair et al. ²⁷⁾	25	Male	Right cerebellar hemisphere	Single	Headache, visual impairment	Gross total removal	Symptom free
Sunwoo and Kim ²⁸⁾	61	Male	Left cerebellar hemisphere	Single	Abnormal oculographic movement	ND	ND
Taylor et al. ²⁹⁾	34	Female	Vermis	Multiple	Vertigo, headache, truncal ataxia	ND	ND
McWilliams et al. ³⁰⁾	8	Male	Bilateral cerebellar hemisphere, right temporal lobe	Multiple	Headache, vomit	Biopsy (right temporal lobe)	ND
Yuan et al. ³¹⁾	2	Female	Cerebellums	Single	Gait instability	Gross total removal	No recurrence
Present case	47	Female	Left cerebellar hemisphere, vermis	Multiple	Dizziness	Biopsy	Improved

NA: not described

brain, with 31% occurring in the frontal lobe and 7% in the parietal and occipital lobes.^{1,9,16,17)} Supratentorial DNTs are generally found in young patients with partial complex epilepsy, but they have also been associated with other manifestations, such as learning difficulties,¹⁸⁾ headache,¹⁹⁾ and psychosis.²⁰⁾ In contrast, several cases of DNT have been reported in an unusual anatomical location (e.g., septum pellucidum,²¹⁾ basal ganglia,^{22,23)} brain stem,^{3,22,24)} or cerebellum^{2-4,22,23,25-31)}), and associated symptoms included ataxia, nausea, vomiting, vertigo, and dizziness. Interestingly, no reported cases of infratentorial DNT have involved epilepsy.

The radiological appearance of DNT on non-enhanced

CT is a cortical or subcortical focal mass that is moderately to markedly hypodense³²⁻³⁴⁾ and occasionally isodense or hyperdense.^{32,33,35)} Calcification can be observed inside the tumor in 11%-36% of patients.^{1,16,32,33,36)} On MRI, a DNT appears as a hypointense cortical mass on T1-weighted imaging (T1WI) in 95% of cases³²⁾ and as a hyperintense mass on T2-weighted imaging (T2WI) in 100% of cases.³²⁻³⁵⁾ Angiography can show normal findings (54%-100%),^{1,37-40)} even in lesions with bleeding.⁴¹⁾ A DNT displays neovascularization in 10.2% of cases^{1,6,36)} and can be avascular in 15.3% of cases, producing a shift of normal structures in 12.8% of cases.^{1,5)} Abe et al. reported that a DNT does not produce abnormal uptake on Tl²⁰¹-SPECT, but it shows hy-

poperation on I¹²³-IMP-SPECT or Tc^{99m}-HMPAO-SPECT.³⁶⁾ In the present case, the typical appearance of DNT was seen on CT, MRI, angiography, and Tl²⁰¹-SPECT, but I¹²³-IMP-SPECT was not performed.

To date, 13 cases of infratentorial DNT have been reported in the literature (Table 1).^{2-4,22-31)} Three reports were combined with supratentorial lesions.^{22,23,30)} In the other 10 cases, DNTs were located focally in the infratentorial cortex, and associated symptoms included vertigo²⁾ and ataxia.^{3,4)} Taken together with the present case report, infratentorial DNTs do not appear to be associated with epilepsy. Surgical treatment was recommended in 11 patients,^{2-4,22,24-27,30,31)} 5 patients underwent complete resection,^{2,24,25,27,31)} 3 patients underwent partial resection or biopsy,^{3,4,26)} and 3 patients underwent remote lesion removal (right temporal lobectomy).^{22,23,30)} Long-term clinical follow-up demonstrated no evidence of recurrence and a stable clinical course. Histopathologically, these 13 cases exhibited features of abnormal layer morphology and OLCs. An infratentorial DNT with cortical heterotopia has not been reported previously; thus, this is the first report of such pathology.

From an oncological point of view, a DNT is a highly stable lesion.⁴²⁾ There are two possible malignant transformations of DNT: spontaneous malignant transformation⁴³⁾ or transformation suspected to occur in association with chemotherapy and radiotherapy.⁴⁴⁾ Although malignant transformation is rare, complete resection is the recommended treatment strategy for a supratentorial DNT to treat associated epilepsy. In a patient series evaluated by Stanescu et al., DNTs did not recur following complete resection over a 4.5-year follow-up period in 92% of patients, and growth of the residual lesion did not occur in 6 patients after partial resection.³²⁾ In addition, the malignant transformation of an infratentorial DNT is rare, and it therefore remains unclear whether complete resection is indicated. The clinical presentation of an infratentorial DNT (e.g., ataxia, vertigo, or headache) can be an uneventful clinical course.^{3,4,31)} In our patient, the symptoms were relieved even though the resection range was limited to biopsy. As there was little mass effect on MRI and the symptoms of dizziness were nonspecific, the possibility that the infratentorial DNT in this case was an incidental tumor should be considered. Total resection is not considered absolutely necessary in infratentorial DNTs. Good outcomes have also been reported in cases with intact infratentorial lesions.^{22,23)} These previous reports suggest that it is more appropriate to select diagnostic resection than total removal for infratentorial DNTs if the procedure can disturb infratentorial brain function. Although it is extremely rare in such cases, regular image follow-up is necessary considering the possibility of malignant transformation. It is thus necessary to accumulate and review additional reports of infratentorial DNTs to recommend an appropriate treatment strategy.

Supplementary Material

<https://doi.org/10.2176/jns-nmc.2021-0350>

Acknowledgments

I gratefully acknowledge the work of past and present members of our department.

Conflicts of Interest Disclosure

The authors declare that they have no conflict of interest.

References

- 1) Daumas-Duport C, Scheithauer BW, Chodkiewicz JP, Laws ER Jr, Vedrenne C: Dysembryoplastic neuroepithelial tumor: a surgically curable tumor of young patients with intractable partial seizures. Report of thirty-nine cases. *Neurosurgery* 23: 545-556, 1988
- 2) Kuchelmeister K, Demirel T, Schlörer E, Bergmann M, Gullotta F: Dysembryoplastic neuroepithelial tumour of the cerebellum. *Acta Neuropathol* 89: 385-390, 1995
- 3) Fujimoto K, Ohnishi H, Tsujimoto M, Hoshida T, Nakazato Y: Dysembryoplastic neuroepithelial tumor of the cerebellum and brainstem. Case report. *J Neurosurg* 93: 487-489, 2000
- 4) Yasha TC, Mohanty A, Radhesh S, Santosh V, Das S, Shankar SK: Infratentorial dysembryoplastic neuroepithelial tumor (DNT) associated with Arnold-Chiari malformation. *Clin Neuropathol* 17: 305-310, 1998
- 5) Wierzbica-Bobrowicz T, Schmidt-Sidor B, Zabek M, Szpak GM, Lechowicz W: Dysembryoplastic neuroepithelial tumor. A case report. *Folia Neuropathol* 37: 162-166, 1999
- 6) Daumas-Duport C: Dysembryoplastic neuroepithelial tumours. *Brain Pathol* 3: 283-295, 1993
- 7) Louis DN, Ohgaki H, Wiestler OD, Cavenee WK: WHO Classification of Tumours of the Central Nervous System, ed 4. Lyon, International Agency for Research on Cancer, 2016
- 8) Wolf HK, Wiestler OD: Surgical pathology of chronic epileptic seizure disorders. *Brain Pathol* 3: 371-380, 1993
- 9) Aronica E, Leenstra S, Van Veelen CW, et al.: Glioneural tumor and medically intractable epilepsy: a clinical study with long-term follow-up of seizure outcome after surgery. *Epilepsy Res* 43: 179-191, 2001
- 10) Villarejo F, Álvarez-Sastre C, Martínez-Quiñones JV, Colomar P, Martín-Gamero AP, Pérez-Díaz C: Dysembryoplastic neuroepithelial tumours. *Rev Neurol* 29: 810-814, 1999
- 11) Gottschalk J, Korves M, Skotzek-Konrad B, Goebel S, Cervos-Navarro J: Dysembryoplastic neuroepithelial micro-tumor in a 75-year-old patient with long-standing epilepsy. *Clin Neuropathol* 12: 175-178, 1993
- 12) Aronica E, Yankaya B, Jansen GH, et al.: Inotropic and metabotropic glutamate receptor protein expression in glioneural tumours from patients with intractable epilepsy. *Neuropathol Appl Neurobiol* 27: 223-237, 2001
- 13) Honavar M, Janota I, Polkey CE: Histological heterogeneity of dysembryoplastic neuroepithelial tumour: identification and differential diagnosis in a series of 74 cases. *Histopathology* 34: 342-356, 1999
- 14) Reis JL, Vasconcelos C, Rancel R, et al.: Dysembryoplastic

- neuroepithelial tumors. *Rev Neurol* 30: 436-441, 2000
- 15) Pasquier B, Peoc HM, Fabre-Bocquentin B, et al.: Surgical pathology of drug-resistant partial epilepsy: a 10-year-experience with a series of 327 consecutive resections. *Epileptic Disord* 4: 99-119, 2002
 - 16) Raymond AA, Halpin SF, Alsanjari N, et al.: Dysembryoplastic neuroepithelial tumour: features in 16 patients. *Brain* 117: 461-475, 1994
 - 17) Daumas-Duport C, Varlet P, Bacha S, Beuvon F, Cervera-Pierot P, Chodkiewicz JP: Dysembryoplastic neuroepithelial tumors non-specific histological forms - a study of 40 cases. *J Neurooncol* 41: 267-280, 1999
 - 18) Nolan MA, Sakuta R, Chuang N, et al.: Dysembryoplastic neuroepithelial tumors in childhood: long-term outcome and prognosis features. *Neurology* 62: 2270-2276, 2004
 - 19) Hamada H, Kurimoto M, Nagai S, Asahi T, Hirashima Y, Endo S: A rare cases of dysembryoplastic neuroepithelial tumor in occipital lobe presenting with only headache. *J Clin Neurosci* 10: 276-278, 2003
 - 20) Escosa-Bagé M, Villarejo-Ortega FJ, Pérez-Jiménez MA, González-Mediero I: Psychosis a case of temporal lobe epilepsy associated with dysembryoplastic neuroepithelial tumor. *Rev Neurol* 38: 643-646, 2004
 - 21) Baisden BL, Brat DJ, Melhem ER, Rosenblum MK, King AP, Burger PC: Dysembryoplastic neuroepithelial tumor-like neoplasm of the septum pellucidum: a lesion often misdiagnosed as glioma: report of 10 cases. *Am J Surg Pathol* 25: 494-499, 2001
 - 22) Leung SY, Gwi E, Ng HK, Fung CF, Yam KY: Dysembryoplastic neuroepithelial tumor: a tumor with small neuronal cells resembling oligodendroglioma. *Am J Surg Pathol* 18: 604-614, 1994
 - 23) Han JY, Yum MS, Kim EH, Hong S, Ko TS: A rare case of dysembryoplastic neuroepithelial tumor combined with encephalocraniocutaneous lipomatosis and intractable seizures. *Korean J Pediatr* 59: S139-S144, 2016
 - 24) Kurtkaya-Yapici O, Elmaci I, Boran B, Kilic T, Sav A, Pamir MN: Dysembryoplastic neuroepithelial tumor of the midbrain tectum: a case report. *Brain Tumor Pathol* 19: 97-100, 2002
 - 25) Vaquero J, Saldana C, Coca S, Zurita M: Complex form variant of dysembryoplastic neuroepithelial tumor of the cerebellum. *Case Rep Pathol* 2012: 718651, 2012
 - 26) Litrico S, Desjardins T, Dran G, Michiels JF, Paquis P: Infratentorial localisation of a dysembryoplastic neuroepithelial tumor. A case report. *Neurochirurgie* 50: 47-52, 2004 (French)
 - 27) Nair P, Pal L, Jaiswal AK, Behari S: Lhermitte-Duclos disease associated with dysembryoplastic neuroepithelial tumor differentiation with characteristic magnetic resonance appearance of "tiger striping". *World Neurosurg* 75: 699-703, 2011
 - 28) Sunwoo JS, Kim JS: Cerebellar dysembryoplastic neuroepithelial tumor: report of a case and review of the literature. *J Neurol* 264: 2318-2321, 2017
 - 29) Taylor JK, Kim AH, Folkerth RD, Black PM: The development of ring-shaped contrast enhancement in a case of cerebellar dysembryoplastic neuroepithelial tumor: case report. *Neurosurgery* 63: E609-E610; discussion E610, 2008
 - 30) McWilliams GD, SantaCruz K, Hart B, Clericuzio C: Occurrence of DNET and other brain tumors in Noonan syndrome warrants caution with growth hormone therapy. *Am J Med Genet* 170: 195-201, 2016
 - 31) Yuan F, Zheng T, Yang H, Tang Y, Tang G, Chen G: Dysembryoplastic neuroepithelial tumour in the cerebellum: case report and literature review. *Br J Neurosurg* 35: 40-42, 2021
 - 32) Stanescu Cosson R, Varlet P, Beuvon F, et al.: Dysembryoplastic neuroepithelial tumors: CT, MR findings and imaging follow-up: a study of 53 cases. *J Neuroradiol* 28: 230-240, 2001
 - 33) Ostertun B, Wolf HK, Campos MG, et al.: Dysembryoplastic neuroepithelial tumors: MR and CT evaluation. *AJNR Am J Neuroradiol* 17: 419-430, 1996
 - 34) Kuroiwa T, Kishikawa T, Kato A, Ueno M, Kudo S, Tabuchi K: Dysembryoplastic neuroepithelial tumors MR findings. *J Comput Assist Tomogr* 18: 352-356, 1994
 - 35) Kuroiwa T, Bergey GK, Rothman MI, et al.: Radiologic appearance of the dysembryoplastic neuroepithelial tumor. *Radiology* 197: 233-238, 1995
 - 36) Abe M, Tabuchi K, Tsuji T, Shiraishi T, Koga H, Takagi M: Dysembryoplastic neuroepithelial tumor: report of three cases. *Surg Neurol* 43: 240-245, 1995
 - 37) Shimbo Y, Takahashi H, Havano M, Kumagai T, Kameyama S: Temporal lobe lesion demonstrating features of dysembryoplastic neuroepithelial tumor and ganglioglioma: a transitional form? *Clin Neuropathol* 16: 65-68, 1997
 - 38) Scott RM, di Rocco C, Canady A, Gonzalez-Portillo G, Sotrel A: How would you treat this patient?: dysembryoplastic neuroepithelial tumor. *Surg Neurol* 46: 23-27, 1996
 - 39) Reiche W, Kolles H, Eymann R, Feiden W: Dysembryoplastic neuroepithelial tumor (DNT): pattern of neuroradiologic findings. *Radiologe* 36: 884-889, 1996
 - 40) Koeller KK, Dillon WP: Dysembryoplastic neuroepithelial tumors: MR appearance. *AJNR Am J Neuroradiol* 13: 1319-1325, 1992
 - 41) Thom M, Gomez-Anson B, Revesz T, et al.: Spontaneous intraleisional haemorrhage in dysembryoplastic neuroepithelial tumours: a series of five cases. *J Neurol Neurosurg Psychiatry* 67: 97-101, 1999
 - 42) Daumas-Duport C, Varlet P: Dysembryoplastic neuroepithelial tumors. *Rev Neurol* 159: 622-636, 2003
 - 43) Hammond RR, Duggal N, Woulfe JM, Girvin JP: Malignant transformation of a dysembryoplastic neuroepithelial tumor: case report. *J Neurosurg* 92: 722-725, 2000
 - 44) Rushing EJ, Thompson LD, Mena H: Malignant transformation of a dysembryoplastic neuroepithelial tumor after radiation and chemotherapy. *Ann Diagn Pathol* 7: 240-244, 2003

Corresponding author: Kiyohide Kakuta, MD, PhD

Department of Neurosurgery, Hirosaki University Graduate School of Medicine, 5 Zaifu-cho, Hirosaki-shi, Aomori 036-8562, Japan.

e-mail: kakuta.k@outlook.com