

Main Article

Ms W Yeung takes responsibility for the integrity of the content of the paper

Cite this article: Yeung W, Vakharia N, Johnatty C, Achar P, Kasbekar AV. Feasibility study of the Vitom 3D exoscope in ENT surgery using an animal model: relevance to coronavirus disease 2019. *J Laryngol Otol* 2021; 1–8. <https://doi.org/10.1017/S0022215121001626>

Accepted: 5 May 2021

Key words:

COVID-19; Exoscope; Personal Protective Equipment; Otolology; Surgery; Safety

Author for correspondence:

Ms Winnie Yeung, Department of Otorhinolaryngology, Head and Neck Surgery, Nottingham University Hospitals NHS Trust, Derby Road, Nottingham NG7 2UH, UK
E-mail: winnie.yeung@nhs.net

Abstract

Objective. The application of a 4K display resolution three-dimensional exoscope system (Vitom 3D) was evaluated to determine the feasibility of adopting the system in ENT surgery in the coronavirus disease 2019 era and beyond.

Methods. Eighteen ENT surgeons performed structured otological tasks on fresh-frozen sheep heads using the Vitom 3D. Structured feedback of the participants' experience was analysed.

Results. Seventy-four per cent and 94 per cent of participants reported that the Vitom 3D was ergonomic and comfortable to use respectively. Whilst colour fidelity and image quality were very good, 50 per cent of participants reported image distortion and pixilation at the highest magnification. All participants agreed that there was an increased educational value to exoscope technology. Half the participants preferred the microscope over the Vitom 3D for fine otological work, which may reflect the learning curve.

Conclusion. The Vitom 3D exoscope is a promising and viable alternative for performing otological surgery when using full personal protective equipment in the coronavirus disease 2019 era.

Introduction

Otolaryngologists are at risk from the coronavirus disease 2019 (Covid-19) infection because of the aerosol-generating procedures performed by the specialty.¹ It is thought that the Covid-19 virus can be transmitted through the middle ear and mastoid cavity. The current best practice is for otolaryngologists to don a filtering facepiece code 3 (FFP3) respirator and full-face protection for aerosol-generating work.² The additional use of personal protective equipment (PPE) poses new challenges for otological surgery, where the use of a traditional microscope for magnification is usually required. Specific eye protection such as goggles, face shields or hoods have compromised visualisation through the microscope eye piece. Given the increased distance of the eye to the microscope eye piece, the surgeon's field of vision is often reduced by more than 50 per cent.³ This renders operating conditions arguably perilous as nearby structures are not adequately visualised.

The three-dimensional (3D) exoscope was first introduced to otolaryngology almost a decade ago.⁴ With the development of the 4K (approximately 4000 pixels) display resolution, application of this technology to the field of neuro-otological surgery has gained momentum.⁵ Manufacturers declare that the 3D exoscope allows the surgeon to operate whilst viewing the surgical field at high magnification on a high-resolution display screen, negating the need to look down a microscope with a reduced field of vision. It is also claimed that the exoscope permits a more ergonomic operating position for the surgeon, and unparalleled visualisation for assistants and observers.⁶

Fewer than a dozen publications have explored the use of 3D exoscope systems in ENT surgery, of which less than half reviewed its use in otological surgery (Table 1).^{5–15} Although several prospective, observational studies^{5,7,9} and retrospective case reports^{8,9,12} exist, the majority are single-patient case reports. All case studies have reported satisfactory patient outcomes, with no significant intra-operative or post-operative complications reported associated with use of 3D exoscope systems. However, there has been no qualitative work to formally analyse the user experience of 4K resolution 3D exoscope systems to date.

This study assessed the efficacy and functionality, and the surgeon's experience, of using the Vitom 3D exoscope system (Karl Storz, Tuttlingen, Germany) whilst wearing PPE during primarily otological surgery on a sheep's head model. We aimed to evaluate the potential feasibility of adopting the Vitom 3D system more widely by ENT surgeons, to facilitate safe otological surgery in the Covid-19 era and beyond.

Materials and methods

Ethical approval was obtained from the Nottingham Health Science Centre Research Prioritisation Committee. The Vitom 3D exoscope was configured for use (Figures 1a

Table 1. Existing literature exploring the use of 3D exoscope systems in ENT surgery

Paper title	Authors	Year	Study type	Sample size (n)	Specialty	Results
Exolaryngoscopy: a new technique for laryngeal surgery	Carlucci <i>et al.</i> ⁷	2012	Prospective observational study	12	Laryngology	<ul style="list-style-type: none"> – All cases had predicted result – Stroboscopy & post-op voice showed good resolution of phonatory problems – Laryngeal biopsies were easy to obtain
The use of the exoscope in lateral skull base surgery: advantages and limitations	Garneau <i>et al.</i> ⁸	2019	Retrospective case series	6	Otology	<ul style="list-style-type: none"> – No intra-operative complications – 1 patient experienced CSF leak in immediate post-op period requiring return to operating theatre – 1 patient with House–Brackmann grade I progressed to post-op House–Brackmann grade III – No need for microscope use
Initial experience with 3-D exoscope-assisted transmastoid and lateral skull base surgery	Smith <i>et al.</i> ⁹	2019	Prospective observational study	11	Otology	<ul style="list-style-type: none"> – 1 case involved exclusive use of Vitom 3D – 6 cases involved exclusive use of Orbeye exoscope system (Olympus, Tokyo, Japan) – 4 cases also used microscope or endoscope – No post-op complications – Mastoidectomies deftly navigated with exoscope
3D exoscopic surgery of lateral skull base	Rubini <i>et al.</i> ¹⁰	2020	Retrospective control–case series	12	Otology	<ul style="list-style-type: none"> – 9 procedures exclusively performed with exoscope – 12 procedures exclusively performed with microscope – 3 procedures performed with exoscope & microscope – No statistically significant time difference – 1 patient from exoscope exclusive group had endoscopic examination after resection, which revealed residual tumour
Internal maxillary to middle cerebral artery bypass using an anterior tibial artery graft, performed using a 3D exoscope: 2-dimensional operative video	Patel <i>et al.</i> ¹¹	2020	Case report	1	Anterior skull base	<ul style="list-style-type: none"> – No complications noted
Using a 4K-3D exoscope for upper airway stimulation surgery: proof-of-concept	Patel <i>et al.</i> ¹²	2020	Retrospective case series	3	ENT	<ul style="list-style-type: none"> – Increased operative time; should reduce with practice – Improved communication & instrument exchange
Transoral floor of mouth lipoma resection: a technical multimedia analysis	Kalmar <i>et al.</i> ¹³	2020	Case report	1	Head & neck	<ul style="list-style-type: none"> – No complications
Free flap microvascular anastomosis in head and neck reconstruction using a 4K-3D exoscope system (Vitom 3D)	De Virgilio <i>et al.</i> ⁵	2020	Prospective observational study	10	Head & neck	<ul style="list-style-type: none"> – 100% free flap survival rate – 1 patient experienced compressive neck haematoma requiring neck exploration – 1 patient suffered post-op seroma
Repair of a temporal bone encephalocele with the surgical exoscope	Garneau <i>et al.</i> ¹⁴	2020	Case report	1	Otology	<ul style="list-style-type: none"> – No intra-operative complications – Able to complete procedure without microscope use – Increased operative time
Vitom 4K-3D exoscope: a preliminary experience in thyroid surgery	Kullar <i>et al.</i> ¹⁵	2021	Case report	1	Thyroid	<ul style="list-style-type: none"> – No complications noted
Using a 4K three-dimensional-3D exoscope system (Vitom 3D) for mastoid surgery during the coronavirus disease 2019 pandemic	Ally <i>et al.</i> ⁶	2021	Case report	1	Otology	<ul style="list-style-type: none"> – No complications noted

3D = three-dimensional; post-op = post-operative; CSF = cerebral spinal fluid

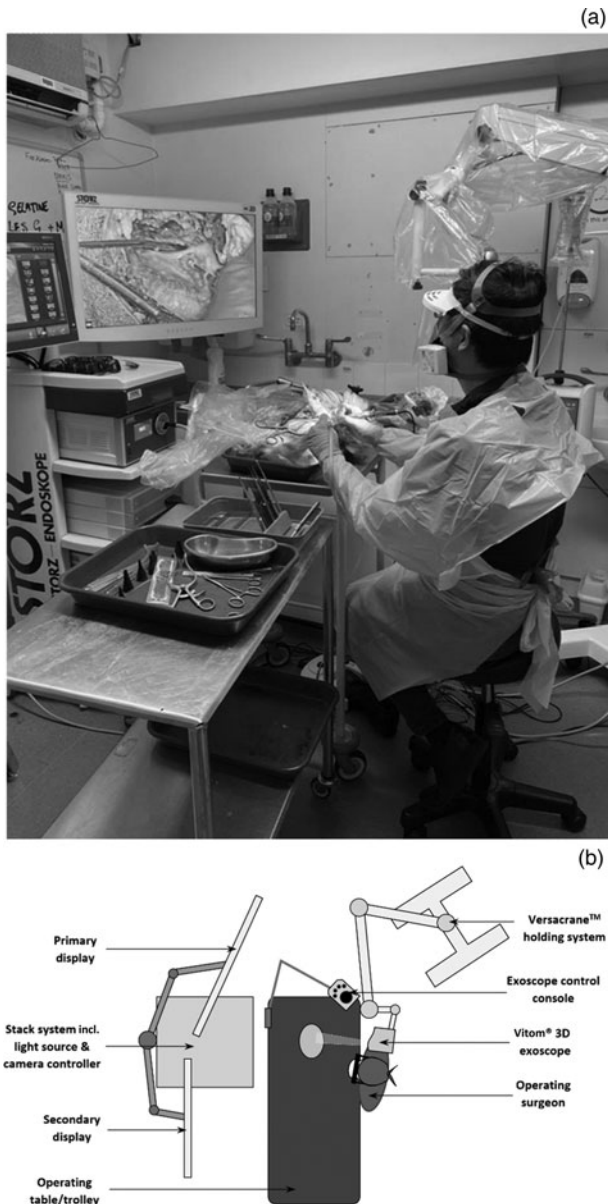


Fig. 1. (a) A photograph of the Vitom 3D exoscope in use in the wet laboratory. (b) Schematic diagram demonstrating setup of the Vitom 3D system from a bird's-eye view.

and **b**), along with an otological drill (Medtronic, Minneapolis, Minnesota, USA), suction equipment and standard ear surgery instruments in a wet laboratory.

Participants, consisting of faculty members from the ENT department, were invited to simulate mastoid bone drilling on fresh-frozen sheep heads using the Vitom 3D exoscope. Participants viewed two short videos demonstrating the use of the Vitom 3D system and a journal article explaining the anatomy of sheep temporal bones¹⁶ beforehand. The surgeons were provided with 3D glasses, and PPE consisting of an FFP3 face mask (or equivalent respirator), visor, gown and gloves. A hands-on demonstration of the Vitom 3D exoscope system ensured that participants were able to independently control the position and magnification of the camera.

Once familiar with the exoscope device, participants performed a series of structured tasks on the fresh-frozen specimens. These tasks included: (1) soft tissue preparation to approach the mastoid; (2) temporal bone drilling to access the middle ear; (3) identification, manipulation and removal

Table 2. Demographic details for study participants

Characteristic	Participants (n (%))
Gender	
– Male	13 (72)
– Female	5 (28)
Age (years)	
– 20–29	2 (11)
– 30–39	8 (44)
– 40–49	5 (28)
– 50–59	2 (11)
– 60+	1 (6)
Grade	
– Consultant (attending physician)	7 (39)
– Senior registrar (senior resident)	8 (44)
– Junior registrar (junior resident)	3 (17)
Clinical ENT experience	
– 1–5 years	2 (11)
– 6–10 years	7 (39)
– 11–15 years	4 (22)
– 16–20 years	2 (11)
– >21 years	3 (17)

of the ossicles; and (4) further drilling into the inner-ear structures.

Participants also trialled drilling without a visor or eye shield, instead wearing the 3D glasses or lenses alone, in order to assess the effect of the visor on 3D vision.

On completion of the assigned tasks, all participants completed feedback detailing their individual experience. The feedback was analysed by the authors.

Three head and neck surgeons from the department were invited to perform a superficial parotidectomy procedure on the defrosted sheep heads using the Vitom 3D, in addition to the structured otological tasks outlined above. Further feedback from a head and neck perspective was obtained from this subgroup.

Results

Eighteen surgeons participated in the study to evaluate use of the Vitom 3D exoscope system (Table 2). The majority of participants (72 per cent) were male and of senior grade.

Ergonomics and comfort

The feedback was overwhelmingly positive for ergonomics and comfort, with 'agree' or 'strongly agree' making up between 78 per cent and 94 per cent of responses respectively (Figure 2). Participants' comments included: 'I feel this is a great system for otologists with neck, back or visual problems'; and 'It would be beneficial if the working distance could be increased; at the moment the camera can get in the way of the surgeon's head'.

Image quality

Responses to image quality were varied, with more negative comments regarding image quality at high magnification (Figure 3). With a digital zoom range between $\times 8$ and $\times 30$

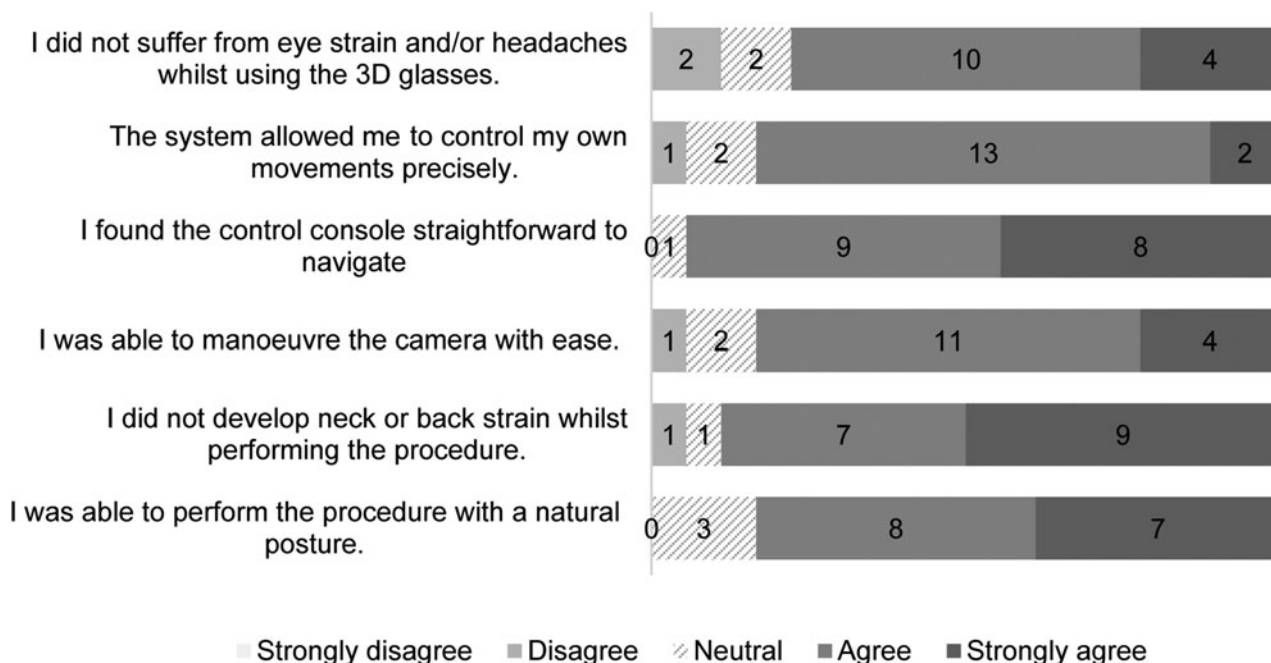


Fig. 2. Graph showing participants' responses to ergonomics and comfort using the Vitom 3D. 3D = three-dimensional

magnification, half of the participants felt that they experienced image distortion and pixilation at the highest magnification. Two-thirds of participants felt that the image quality was adequate to perform the assigned task. Responses to image focus, level of magnification, brightness and 3D imaging were positive in the majority. Participants' comments included: 'Colour fidelity and clarity was good at low magnification; however, it was more difficult to discern (e.g. stapes footplate) structures well at high magnification'; and 'Visualising an entire operation on the 4K resolution display is a massive advantage of the Vitom 3D'.

Surgeon experience

Sixty-seven per cent of participants agreed that they felt confident using the Vitom system, whilst 28 per cent gave a neutral response and one respondent disagreed (Figure 4). Half of the participants agreed or strongly agreed that wearing full PPE did not interfere with their ability to operate using the Vitom 3D, and three-quarters agreed or strongly agreed that their operative experience was more acceptable whilst wearing full PPE compared to a traditional microscope. Forty-four per cent of respondents agreed or strongly agreed that they were able to visualise anatomical details equally well with the Vitom 3D system in full PPE, compared to a microscope, with 17 per cent returning a neutral response and 39 per cent disagreeing. Two-thirds of participants agreed or strongly agreed that they would be able to utilise an assistant in a beneficial way using Vitom 3D. Participants' comments included: 'Really enjoyed the 3D element – judging distance was really easy'; and 'Slight learning curve as with all new technology, but pleasurable to use.'

Teaching and training

Two-thirds of participants agreed or strongly agreed that, as a trainee, they were better able to appreciate how anatomical structures are arranged in space with the Vitom 3D display (Figure 5). Almost all participants agreed or strongly agreed that being able to see an entire procedure being performed

on the Vitom 3D system provides educational value. Participants' comments included: 'Beautiful views for the whole team, but far better for an open procedure than down the ear canal'.

All trainers felt that the system was invaluable for demonstrating a procedure and pointing out relevant anatomical structures on the Vitom 3D display. Importantly, 82 per cent of trainers agreed or strongly agreed that they would be more inclined to allow their trainees to perform greater portions of an operation when using Vitom 3D. Thirty-nine per cent agreed or strongly agreed that, with time and practice, the Vitom 3D system could be equal or superior for ear surgery than using a traditional microscope whilst wearing full PPE; 28 per cent of participants disagreed with this statement and 33 per cent returned a neutral response.

Comparison to microscope for fine work

When directly comparing Vitom 3D to a traditional microscope for fine work in otological surgery, half of participants felt that the Vitom 3D was not as good as the microscope, 22 per cent felt that it was better or much better, and 28 per cent returned a neutral response (Figure 6). Participants' comments included: 'Interesting device; I'm sure it has a niche, but it doesn't allow the dynamic view that the microscope provides'; 'Difficult to always assess depth with the Vitom 3D vision, especially for fine middle or inner ear related work'; and 'Very good for basic mastoid procedures'.

Perspective on head and neck oncological surgery

Although this study was not designed to focus on head and neck procedures, this section was included to provide additional insight into the overall usability of the Vitom 3D exoscope. Feedback in this domain was variable. Two of the three head and neck surgeons surveyed reported loupe magnification to be superior to the Vitom 3D when undertaking open head and neck procedures (e.g. parotidectomy, laryngectomy and neck dissection) whilst wearing full PPE. In contrast, two of the three surgeons reported the Vitom 3D to be

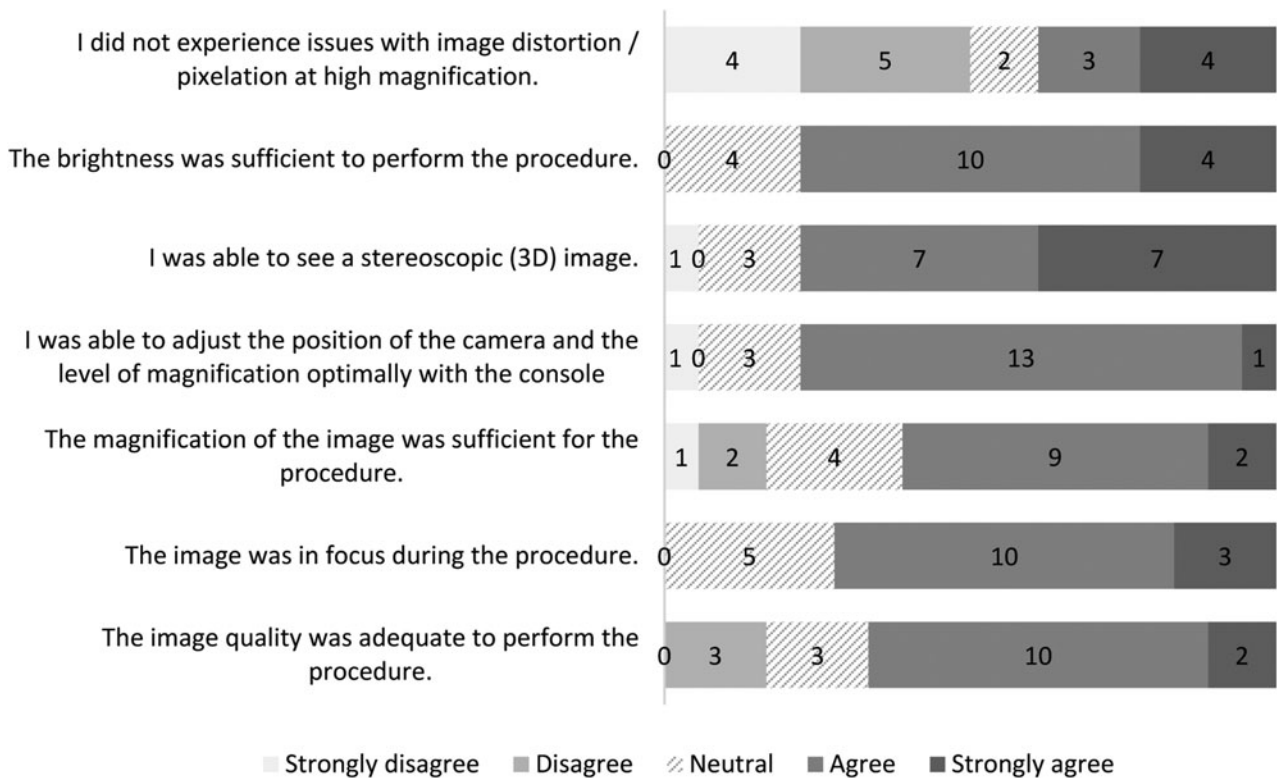


Fig. 3. Graph showing participants' responses to image quality using the Vitom 3D. 3D = three-dimensional

preferable to the microscope when undertaking transoral procedures (e.g. panendoscopy and oropharyngeal resections) whilst wearing full PPE. All three surgeons felt that the magnification of the Vitom 3D was sufficient for head and neck oncological surgery. Two-thirds agreed that the colour differentiation between tissues and depth of perception using Vitom 3D was good for head and neck surgery.

Discussion

This study, with a level of evidence of 4, assessed the feasibility of performing otological surgery using the Vitom 3D exoscope, instead of the traditional operating microscope, whilst donned in full PPE. The literature has demonstrated the safe use of 3D exoscope systems in a range of ENT operations, including lateral skull base work and mastoid surgery, through a series of published case reports^{6,14,15} and retrospective case-control series.^{8,10,12} Our qualitative study was designed to complement the existing body of published work on exoscope systems, by assessing the experience of ENT surgeons at different stages of their career.

Musculoskeletal problems and strain on the cervical spine is a familiar occupational hazard seen in otologists related to prolonged use of the microscope.¹⁷ Studies have revealed a high rate of neck and upper limb strain among endoscopic and laparoscopic surgeons.¹⁸ Whilst the basic ergonomic principles to avoid such strains are difficult to employ in practice when operating with a microscope, they can however be adopted whilst working with exoscopes.

In this study, the feedback regarding ergonomics and comfort using the Vitom 3D exoscope was overwhelmingly positive. Eighty-three per cent of participants agreed or strongly agreed that they were able to perform the procedure with a natural posture, and 89 per cent did not develop neck or back strain. Any measures to improve this has the potential

to reduce the significant healthcare costs and morbidity associated with this common problem.¹⁹ Although the ability to operate comfortably in a natural posture is an advantage, there are no ergonomic assessment studies in the literature with the Vitom 3D exoscope because of its novelty. Ninety-four per cent of participants in our study found manipulating the console straightforward and intuitive, and 83 per cent felt that the Vitom 3D system allowed precise control of their movements. This ease of manoeuvrability could be attributed to the lightweight 3D camera system as compared to the bulky microscope, along with the control console that allows fine adjustment of the camera position and magnification.

The majority of critical feedback concerned the image quality. Whilst most participants (94 per cent) were able to view a stereoscopic image with the supplied 3D glasses and with the Vitom 3D exoscope system set to '3D' mode, this was not universal. For all participants, 3D vision was also marginally affected when a clear plastic visor was worn over the 3D glasses, which appeared to distort the stereoscopic image. Moreover, two responders (11.1 per cent) felt that the use of 3D glasses made them feel nauseated and precipitated headaches. This is consistent with the findings of a study by Read and Bohr,²⁰ in which 14 per cent of users experienced adverse effects with stereoscopic 3D vision. Although the image brightness was deemed sufficient by most responders, a small number found the light intensity to be less than optimal when visualising structures down a narrow structure such as an ear canal. Half of the participants experienced problems with image distortion and pixilation at high magnification.

The Vitom 3D uses both optical and digital zoom; when the latter is deployed at the highest levels of magnification, it can result in some image degradation due to pixilation. Whilst the camera can be repositioned closer to the surgical field to reduce reliance on digital zoom, it may hinder the surgeon's

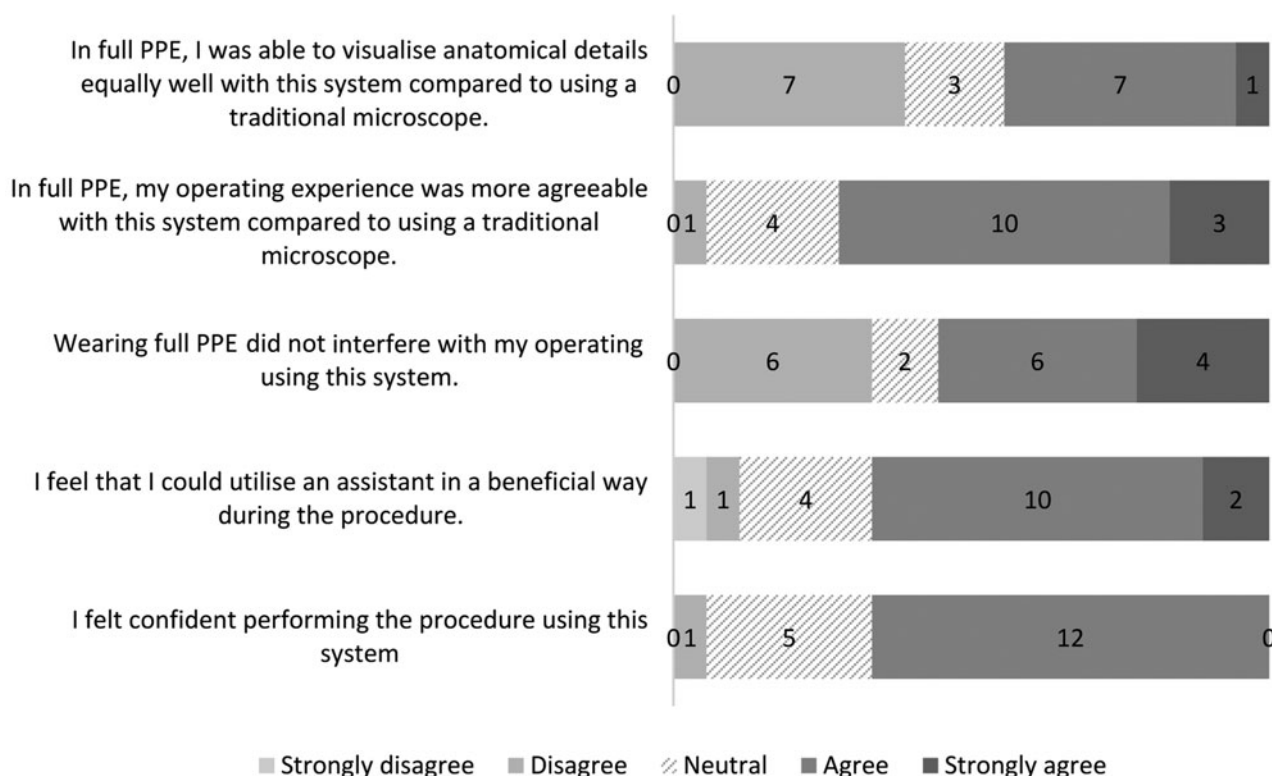


Fig. 4. Graph showing participants' responses to overall operative experience using the Vitom 3D. PPE = personal protective equipment

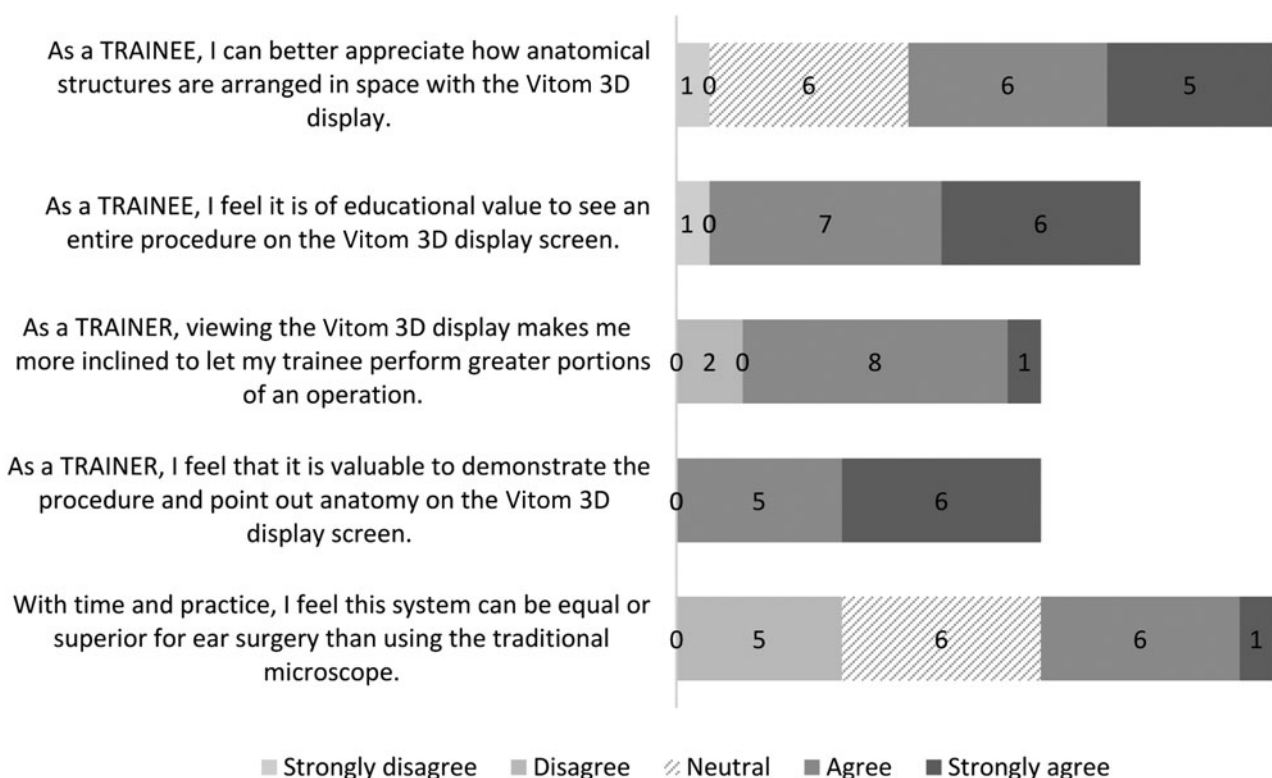


Fig. 5. Graph showing participants' responses to using the Vitom 3D for teaching and training.

access to the operative target. As a result, 17 per cent of surgeons in this study did not feel that the image quality or the magnification were adequate for performing the fine middle-ear procedures requested of them, such as manipulation of the ossicular chain. Whilst Ally *et al.*⁶ did not find this to be a problem during their combined approach

tympanoplasty case study, they did experience glare when looking down the ear canal with a speculum associated with the brightness of the Vitom 3D camera system. Our work found that the glare could be minimised in such cases by reducing the brightness to the desired level via the Vitom 3D system's control console.

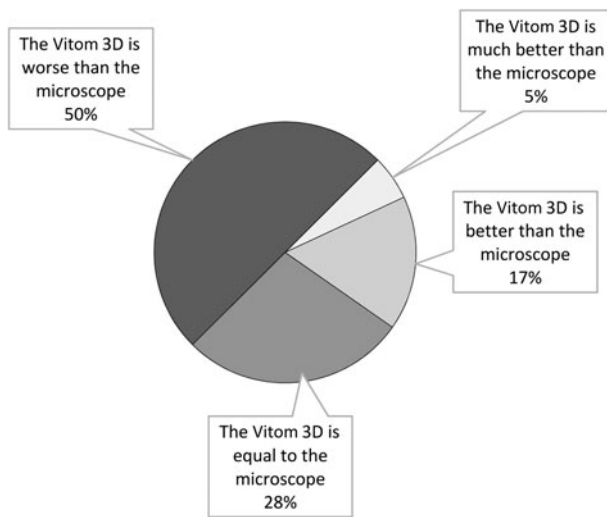


Fig. 6. Pie chart showing participants' responses when comparing the Vitom 3D to a traditional microscope for undertaking fine work in otological surgery.

When considering the overall operating experience in the context of wearing full PPE, responses were highly variable among the group. Sixty-one per cent of participants felt that they could visualise the anatomy to the same detail with the Vitom 3D exoscope as when using a traditional microscope. The vast majority of responders (94 per cent) found operating with the Vitom 3D exoscope more agreeable compared to using a traditional microscope whilst wearing PPE. However, 33 per cent of participants still felt PPE interfered with their operating. This could be because of a number of additional factors, including the uncomfortable nature of wearing a FFP3 mask, eye shield and goggles.

Training and education hold the biggest advantages of using the Vitom 3D system compared to using a standard microscope. Ninety-four per cent of trainees agreed that it was of great educational value to be able to appreciate how various anatomical structures are arranged in space when viewing the same screen as the surgeon throughout the operation. In addition, all members of staff present in the operating theatre were able to share the same view and have an immersive experience. Frykman *et al.*²¹ reported a high satisfaction rate amongst operating theatre staff when using an exoscope system, engaging staff to better anticipate the surgeons' next moves when deploying the Vitom system in paediatric surgery. All trainer participants felt it was helpful for pointing out relevant and important anatomical structures to their trainees on the Vitom 3D display screen. Eighty-two per cent of trainers reported being more likely to let their trainees perform greater portions of the operation, thanks to better visualisation on the 4K resolution screen.

- The Vitom 3D exoscope system is a promising and viable alternative to the microscope for performing otological surgery
- When used with personal protective equipment in the context of the coronavirus disease 2019 era, the system offers an ergonomic and comfortable setup for the operating surgeon
- Published case series have demonstrated its safe use in otology, anterior skull base and head and neck surgery, with satisfactory patient outcomes
- Advantages of the Vitom 3D include intuitive controls and unrivalled intra-operative views, which greatly enhance the teaching experience for both trainers and trainees
- Some users have reported image distortion and pixilation at high magnification as potential shortcomings

Participants reported that the main strengths of the Vitom 3D exoscope system were: ease of use, comfort and the ability to maintain an unrestricted view of the operative field whilst wearing PPE. However, given the limitations of projecting a high-fidelity image at the highest magnification with pixilation, most surgeons surveyed (89 per cent) expressed a preference for the traditional microscope for fine work in otological surgery. A case series on 3D exoscopic surgery in the lateral skull base by Rubini *et al.*¹⁰ described similar limitations with low lighting in small surgical corridors and problems with pixilation at high magnification. We felt that, overall, the use of the Vitom 3D system has more advantages than the microscope when operating within the context of the Covid-19 pandemic when full PPE is required.

The exoscope has recently successfully been used for total thyroidectomy;¹⁵ the study concluded that the system can provide a safe method of carrying out thyroid surgery. The three head and neck surgeons who took part in our study were generally optimistic about the Vitom 3D system. Two of the surgeons felt that the colour differentiation between tissues and level of magnification offered by the Vitom 3D system was good for head and neck surgery. As a result, when wearing full PPE, two of the three surgeons found the system preferable for undertaking transoral work compared to using the microscope. However, the same number felt that loupe magnification was superior to the Vitom 3D when undertaking open head and neck surgery.

Limitations

Sheep heads were chosen as substitutes for this research project given the poor accessibility to human temporal bones during the pandemic. Although there are similarities between sheep and human temporal bone anatomy, as per a comparison by Péus *et al.*,²² the substantial differences in middle-ear anatomy may potentially have been a factor in the poor visualisation of ossicles at high magnification. Moreover, the study did not involve a direct comparison between the Vitom 3D exoscope and the microscope; the results may therefore be subject to recall bias. The relatively small number of participants surveyed meant that robust statistical analysis could not be carried out on the acquired data.

Conclusion

The Vitom 3D exoscope is a promising and potentially viable alternative for performing otological surgery compared to the operating microscope. The Vitom 3D exoscope is easy to manoeuvre and intuitive to control using the accompanying console, and it offers an ergonomic and comfortable setup for the operating surgeon. Even when used with full PPE, it allows a wide, unrestricted operative field. Some participants found the lighting inadequate when visualising structures down deep and narrow surgical corridors; others reported issues of image distortion and pixilation at very high magnification. The latter is especially relevant to otological surgery. There may well be a learning curve to consider, but these findings will need to be corroborated with further larger scale studies. In keeping with previously published work, our study showed that both trainees and trainers found viewing the same image on the Vitom 3D display screen in real-time to be of exceptional educational value in surgical training.

Acknowledgements. The authors would like to thank the Trent Simulation and Clinical Skills Centre for allowing use of their facilities to carry out the work and for sourcing the sheep heads. This work was supported by the Nottingham Ears Charity.

Competing interests. The Vitom 3D system was loaned to the department by Karl Storz for the purposes of this study, but the company did not take part in the planning, performance or analysis of the work, or the manuscript preparation.

References

- Gordon SA, Deep NL, Jethanamest D. Exoscope and personal protective equipment use for otologic surgery in the era of COVID-19. *Otolaryngol Head Neck Surg* 2020;**163**:179–81
- ENTUK and BSO Guidance for undertaking otological procedures during COVID-19 pandemic. In: <https://www.entuk.org/guidance-undertaking-otological-procedures-during-covid-19-pandemic-0> [10 June 2021]
- Lawrence RJ, O'Donoghue G, Kitterick P, O'Donoghue K, Hague R, Mitchell L *et al.* Recommended personal protective equipment for cochlear implant and other mastoid surgery during the COVID-19 era. *Laryngoscope* 2020;**130**:2693–9
- Cheng HT, Ma H, Tsai CH, Hsu WL, Wang TH. A three-dimensional stereoscopic monitor system in microscopic vascular anastomosis. *Microsurgery* 2012;**32**:571–4
- De Virgilio A, Iocca O, Di Maio P, Mercante G, Mondello T, Yiu P *et al.* Free flap microvascular anastomosis in head and neck reconstruction using a 4K three-dimensional exoscope system (VITOM 3D). *Int J Oral Maxillofac Surg* 2020;**49**:1169–73
- Ally M, Kullar P, Mochloulis G, Vijendren A. Using a 4K three-dimensional exoscope system (Vitom 3D) for mastoid surgery during the coronavirus disease 2019 pandemic. *J Laryngol Otol* 2021;**135**:273–5
- Carlucci C, Fasanella L, Ricci Maccarini A. Exolaryngoscopy: a new technique for laryngeal surgery. *Acta Otorhinolaryngol Ital* 2012;**5**:326–8
- Garneau JC, Laitman BM, Cosetti MK, Hadjipanayis C, Wanna G. The use of the exoscope in lateral skull base surgery: advantages and limitations. *Otol Neurotol* 2019;**40**:236–40
- Rubini A, Di Gioia S, Marchioni D. 3D exoscopic surgery of lateral skull base. *Eur Arch Otorhinolaryngol* 2020;**277**:687–94
- Smith S, Kozin ED, Kanumuri VV, Barber SR, Backous D, Flávio Nogueira J *et al.* Initial experience with 3-dimensional exoscope-assisted transmastoid and lateral skull base surgery. *Otolaryngol Head Neck Surg* 2019;**160**:364–7
- Patel NV, Ligas B, Gandhi S, Ellis J, Ortiz R, Costantino P *et al.* Internal maxillary to middle cerebral artery bypass using an anterior tibial artery graft, performed using a 3-dimensional exoscope: 2-dimensional operative video. *Oper Neurosurg (Hagerstown)* 2020;**19**:E187
- Patel VA, Goyal N. Using a 4K-3D Exoscope for upper airway stimulation surgery: proof-of-concept. *Ann Otol Rhinol Laryngol* 2020;**129**:695–8
- Kalmar CL, Patel VA, Slonimsky G. Transoral floor of mouth lipoma resection: a technical multimedia analysis. *Am J Otolaryngol* 2020;**41**:102572
- Garneau JC, Laitman BM, Cosetti MK, Hadjipanayis C, Wanna GB. Repair of a temporal bone encephalocele with the surgical exoscope. *Otol Neurotol* 2020;**41**:561
- Kullar P, Tanna R, Ally M, Vijendren A, Mochloulis G. VITOM 4K 3D exoscope: a preliminary experience in thyroid surgery. *Cureus* 2021;**13**:e12694
- Gurr A, Pearson MD, Dazert S. Lambs' temporal bone anatomy under didactic aspects [in Portuguese]. *Braz J Otorhinolaryngol* 2011;**77**:51–7
- Babar-Craig H, Banfield G, Knight J. Prevalence of back and neck pain amongst ENT consultants: national survey. *J Laryngol Otol* 2003;**117**:979–82
- Ramakrishnan VR, Montero PN. Ergonomic considerations in endoscopic sinus surgery: lessons learned from laparoscopic surgeons. *Am J Rhinol Allergy* 2013;**27**:245–50
- Grant KMK, Vo T, Tiong LU. The painful truth: work-related musculoskeletal disorders in Australian surgeons. *Occup Med (Lond)* 2020;**70**:60–3
- Read JC, Bohr I. User experience while viewing stereoscopic 3D television. *Ergonomics* 2014;**57**:1140–53
- Frykman PK, Freedman AL, Kane TD, Cheng Z, Petrosyan M, Catchpole K. A study of VITOM in pediatric surgery and urology: evaluation of technology acceptance and usability by operating team and surgeon musculoskeletal discomfort. *J Laparoendosc Adv Surg Tech A* 2017;**27**:191–6
- Péus, D, Dobrec, I, Pfiffner, F, Sim JH. Comparison of sheep and human middle-ear ossicles: anatomy and inertial properties. *J Comp Physiol A* 2020;**206**:683–700