

[CASE REPORT]

Dyspnea and Wheezing as the Earliest Manifestations of Severe Fever with Thrombocytopenia Syndrome: The First Case Report

Shun Yamashita, Naoko E Katsuki, Masaki Tago and Shu-ichi Yamashita

Abstract:

A 64-year-old Japanese woman developed fatigue, dyspnea, and wheezing in July. Although she had been undergoing treatment for chronic obstructive pulmonary disease for six days, she was transferred to our hospital with delirium and diarrhea. On admission, she had an eschar of 3 mm in diameter on her anterior chest. Polymerase chain reaction of her blood and eschar specimens led to the diagnosis of severe fever with thrombocytopenia syndrome. Chest computed tomography showed ground-glass opacities, suggesting noncardiogenic pulmonary edema or viral pneumonia. This is the first case report of severe fever with thrombocytopenia syndrome beginning with dyspnea and wheezing.

Key words: severe fever with thrombocytopenia syndrome, wheeze, dyspnea, noncardiogenic pulmonary edema, viral pneumonia

(Intern Med 58: 2731-2735, 2019)

(DOI: 10.2169/internalmedicine.2660-19)

Introduction

The first case of severe fever with thrombocytopenia syndrome (SFTS) was reported in China in 2011. SFTS is a type of viral hemorrhagic fever caused by SFTS virus (SFTSV), which is a tick-borne virus in the genus *Phlebotomus* and family *Bunyaviridae* (1). SFTS begins to manifest with a high fever after a 5- to 14-day incubation period following infection. Before being cured, patients with SFTS experience three stages: a fever (5-11 days), multiple organ failure (7-14 days), and convalescence (11-19 days) (2). SFTS is a severe disorder with a mortality rate of 6.3% to 30.0% (3, 4), and the average duration from onset to death is 9 days (3). In addition to a high fever, it usually starts with digestive symptoms, such as vomiting or diarrhea, and subsequently shows central nervous system manifestations in the multiple organ failure stage (2). Laboratory data usually reveal thrombocytopenia, which is a characteristic feature of SFTS, along with a high creatine kinase level, liver dysfunction, kidney dysfunction, hematuria, or proteinuria (2). SFTS with respiratory symptoms as the primary manifestation is

extremely rare, and only one such case has been reported. In that case, SFTS started with coughing and sputum production (5).

We herein report the first case of SFTS that started with dyspnea and wheezing. Because SFTS is a critical disease with high mortality, it is important to recognize these symptoms as rare but possible early manifestations.

Case Report

A 64-year-old woman with a smoking history of 1,716 pack-years and no history of visiting a doctor or undergoing a health checkup for more than a decade developed fatigue in July. She was often bitten by ticks that had infested her unconfined pet dog, which freely ran around and walked the mountains on a daily basis. When she visited a primary care hospital for the evaluation of dyspnea 4 days after onset, she also had a high fever of 38.6°C and a low oxygen saturation level of 88% on room air. Her condition was diagnosed as acute exacerbation of chronic obstructive pulmonary disease due to complicated acute bronchitis. This diagnosis was based on the presence of wheezing in both lung fields with-

Table. Laboratory Data on Admission

Complete blood cell count		Biochemical parameters			
White blood cells	3.8 ×10 ³ /μL	Total protein	5.6 g/dL	Sodium	133 mEq/L
Band form	20.5 %	Albumin	2.9 g/dL	Potassium	4.2 mEq/L
Segmented	42.5 %	BUN	11.7 mg/dL	Chlorine	101 mEq/L
Red blood cells	458 ×10 ⁴ /μL	Creatinine	0.69 mg/dL	Ferritin	3,245 ng/mL
Hemoglobin	13.7 g/dL	Total bilirubin	0.4 mg/dL	sIL-2R	1,504 U/mL
Hematocrit	40.3 %	AST	117 U/L	Urinalysis	
Platelets	6.1 ×10 ⁴ /μL	ALT	60 U/L	Qualitative	
Coagulation system		LDH	635 U/L	pH	7
PT-INR	1.11	ALP	171 U/L	Specific gravity	
APTT	50.6 seconds	CK	472 U/L	Protein	2+
Fibrinogen	282.1 mg/dL	Glucose	214 g/dL	Occult blood	2+
FDP	9.3 μg/mL	HbA1c	7.9 %	Nitrite	(-)
D-dimers	3.31 μg/mL	CRP	1.15 mg/dL	White blood cells	(-)

PT-INR: prothrombin time-international normalized ratio, APTT: activated partial thromboplastin time, FDP: fibrin/fibrinogen degradation products, BUN: blood urea nitrogen, AST: aspartate aminotransferase, ALT: alanine aminotransferase, LDH: lactate dehydrogenase, ALP: alkaline phosphatase, CK: creatine kinase, HbA1c: hemoglobin A1c, CRP: C-reactive protein, sIL-2R: soluble interleukin-2 receptor

out definite infiltration suggestive of pneumonia on chest radiography.

Although methylprednisolone at 125 mg/day and ceftriaxone at 2 g/day were started on an outpatient basis, she was admitted to the hospital because of liver dysfunction (aspartate aminotransferase, 79 U/L; alanine aminotransferase, 48 U/L) and thrombocytopenia ($7.9 \times 10^4/\mu\text{L}$) on the sixth day of illness. Despite these treatments at the hospital, she developed severe watery diarrhea and delirium and began engaging in dangerous actions, such as climbing over the bedrail. Therefore, she was transferred to Saga University Hospital on day 7.

On admission, her consciousness level was slightly somnolent, body temperature was 36.4°C, heart rate was 74 beats/min, blood pressure was 108/63 mmHg, respiratory rate was 23/min, and oxygen saturation was 98% with 2 L/min of oxygen delivered via a nasal cannula. Despite the presence of wheezing in both upper lung fields, a physical examination revealed no findings suggestive of heart failure, such as jugular venous distention, edema, or cardiac murmur. An exceedingly small eschar of 3 mm in diameter was found on her anterior chest. The laboratory findings on admission are shown in Table. The patient had a white blood cell count of $3.8 \times 10^3/\mu\text{L}$ (band form, 20.5%), C-reactive protein level of 1.15 mg/dL, and thrombocytopenia of $61,000/\mu\text{L}$. Her respiratory rate of >20/min and white blood cell count of $<4.0 \times 10^3/\mu\text{L}$ indicated the presence of systemic inflammatory response syndrome (6), and she was diagnosed with disseminated intravascular coagulation (DIC) with a score of 4 according to the Japanese Association for Acute Medicine DIC scoring system (7). She also had hypoalbuminemia (albumin, 2.9 g/dL), hepatic dysfunction (aspartate aminotransferase 117 U/L; alanine aminotransferase, 60 U/L), and hyponatremia (sodium, 133 mEq/L). Mycoplasma and chlamydia pneumonia antibodies, urinary antigens of pneumococcus and legionella, and β-D-glucan after starting

the administration of steroids were all negative. A urinalysis showed hematuria and proteinuria without urine leukocytes or nitrite. An arterial blood gas analysis with the administration of 2 L/min of oxygen showed a pH of 7.409, carbon dioxide partial pressure (PCO₂) of 25.6, partial pressure oxygen (PO₂) of 92.8, P/F ratio of 331, and HCO₃⁻ of 15.9, suggesting the presence of type I respiratory failure. Blood culture was negative. Although sputum culture showed an extremely small amount of *Candida* with α-streptococcus and very low numbers of neutrophils, we determined these to have no diagnostic significance as the cause of her pneumonia. Chest radiography and chest computed tomography showed symmetric pale ground-glass opacities (GGOs) in the bilateral upper lung fields, bronchial dilatation, and emphysematous changes (Fig. 1). Echocardiography revealed an ejection fraction of 77% and a left ventricular end-systolic dimension of 30 mm with no valvular disease. Because the patient had no abnormalities suggesting heart failure, the cause of dyspnea was considered to be noncardiogenic pulmonary edema (NCPE).

On day 11, SFTSV was detected in blood and eschar specimens by polymerase chain reaction. In addition, hemophagocytosis by neutrophils and macrophages was detected in bone marrow aspiration samples taken on the same day. Based on these findings, the patient was diagnosed with SFTS complicated by NCPE, DIC, and hemophagocytic syndrome. The minocycline that had been administered to treat possible tick-transmitted rickettsial diseases was stopped. The platelet count, C-reactive protein level, and liver function started to improve on day 12, and the GGOs in the bilateral upper lung fields disappeared (Fig. 2). Because her general condition had improved, she was transferred to the initial hospital for further recuperation on day 20.

Her symptoms and signs subsequently disappeared completely. She has visited her family doctor at the outpatient

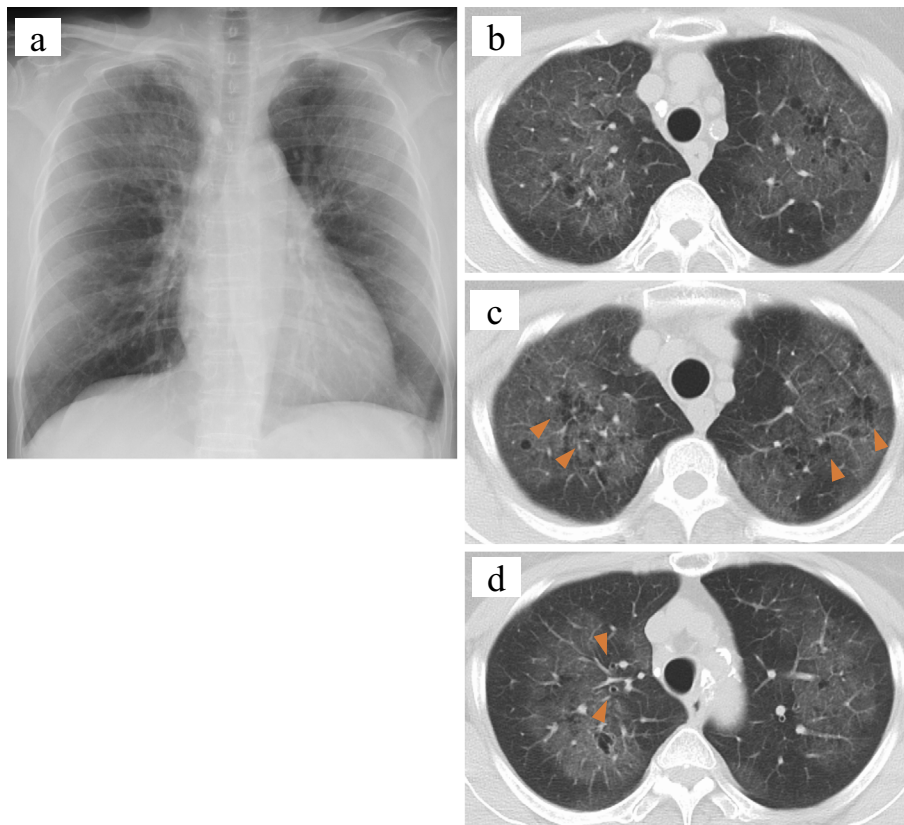


Figure 1. Chest imaging findings on admission. (a) A chest radiograph shows symmetric pale ground-glass opacities (GGOs) in the bilateral upper lung fields. Chest computed tomography also shows (b) GGOs in the bilateral upper lung fields and (c) emphysematous changes (arrowheads) with (d) bronchial dilatation (arrowheads).

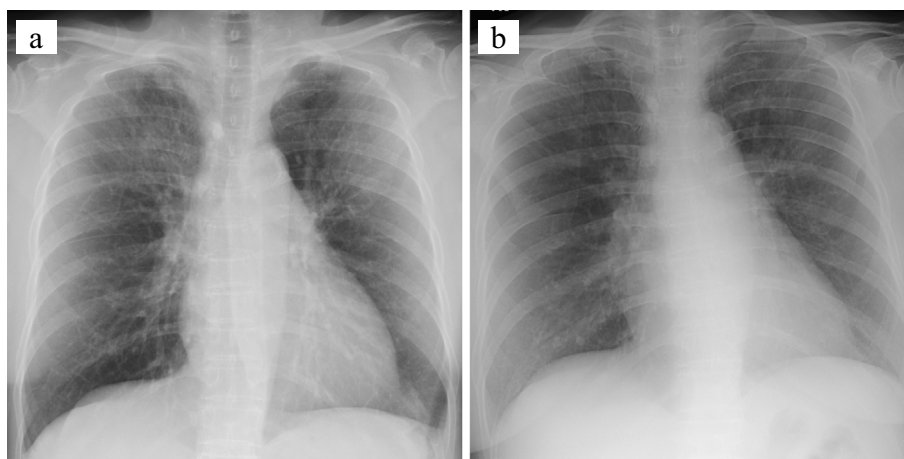


Figure 2. Changes in chest radiographic findings. (a) On admission (7 days after onset), ground-glass opacities (GGOs) were present in the bilateral upper lung fields. (b) On day 12, these GGOs had disappeared in parallel with the improvement in the patient's general condition.

clinic of the hospital for more than a year due to her chronic obstructive pulmonary disease (COPD) without any recurrence of symptoms or signs of SFTS. Although we regrettably could not check for the presence of SFTSV in the blood of her domestic dog or determine the precise extension of SFTSV in her neighborhood, we have not detected any incidence of SFTS among her local family members or

neighbors, including her husband.

Discussion

This is the first case report of SFTS with dyspnea, wheezing, and a high fever as the earliest manifestations. The complete clinical features of SFTS are unclear because it is

a rather newly discovered disease entity, being first reported in China in 2011 (1). Although many symptoms and signs may reportedly develop during the disease course, such as a fever (90-99%), fatigue (83-93%), vomiting (29-77%), diarrhea (46-71%), abdominal pain (38-55%), myalgia (17-71%), and lymphadenopathy (40-55%), a fever and digestive symptoms, such as vomiting and diarrhea, are the most frequent first manifestations (8, 9). With respect to respiratory manifestations that appear during the course of the disease, coughing (24-29%), sputum production (24%) and dyspnea (15%) have been reported (2, 10). However, to our knowledge, no reported case of SFTS has started with dyspnea and wheezing. Although it is certainly rare for SFTS to start with these symptoms and signs, it is important to recognize them as possible initial manifestations of this serious and potentially fatal disease.

SFTS were reported to induce lung lesions in 33.7% cases, of which GGOs accounted for 36.4% (10). The causal conditions producing GGOs were considered to be viral pneumonia, bacterial pneumonia, atypical pneumonia, acute respiratory distress syndrome, and fungal infection (10, 11). Although both NCPE and viral pneumonia could have been the causative conditions of the dyspnea and wheezing in our case, we considered NCPE the more likely cause. The etiology of pulmonary edema is classified into cardiogenic pulmonary edema (CPE) and NCPE (12). The mechanism underlying CPE is acute elevation of either the hydrostatic pressure or pulmonary capillary pressure, which occurs with the depression of the cardiac function. In contrast, the mechanism underlying NCPE is increased pulmonary capillary permeability (12). In NCPE, chest imaging studies usually show bilateral diffuse infiltrates or alveolar filling patterns without cardiac dilatation or pleural effusion, which are caused by diffuse alveolar damage which may be identified on pathological examinations (13). Although chest computed tomography in the present case revealed GGOs around the bilateral upper lung fields and hilar areas, findings that are not typical of NCPE, the distributions of the GGOs were consistent with NCPE. These rather atypical imaging findings are considered to be due to the complication of severe chronic obstructive pulmonary disease. In addition, echocardiography revealed no findings of cardiac depression. While NCPE can be caused by many conditions, such as severe pneumonia, sepsis, acute kidney injury, severe trauma, near-drowning, and post-transfusion (12, 13), the etiology in our case was considered to be SFTSV infection.

The other possible etiology of the respiratory manifestations and imaging findings in our case is viral pneumonia. Two pathogenic mechanisms of viral pneumonia are possible: either a respiratory tract infection or bloodstream infection (viremia) attributed to a causative virus (14). The only 2 cases of viral pneumonia caused by SFTSV involve patients who developed respiratory tract infections via the aerosol route from other patients with respiratory tract infection induced by SFTSV; of note, those patients developed a cough and sore throat, which are not typical symptoms of

SFTS. Imaging studies have shown findings consistent with lobular pneumonia. These patients' conditions were cured using only conservative treatments without specific antiviral medications (5). In contrast, our patient had a typical type of SFTS, not SFTSV infection via the respiratory tract; therefore, viremia was present. In addition, no reports have described tick-transmitted viral pneumonia in patients with SFTS (14). Because viral pneumonia associated with viremia sometimes results in the development of diffuse, generalized GGOs (14), which is compatible with the imaging findings of our case, we cannot completely rule out a possible diagnosis of viral pneumonia in our patient.

Conclusion

We herein report the first case of SFTS with dyspnea and wheezing as the initial manifestations, followed by a high fever. Because SFTS can have a fatal outcome, the diagnosis should not be ruled out based on these rare onsets.

The authors state that they have no Conflict of Interest (COI).

References

1. Yu XJ, Liang MF, Zhang SY, et al. Fever with thrombocytopenia associated with a novel bunyavirus in China. *N Engl J Med* **364**: 1523-1532, 2011.
2. Liu Q, He B, Huang SY, Wei F, Zhu XQ. Severe fever with thrombocytopenia syndrome, an emerging tick-borne zoonosis. *Lancet Infect Dis* **14**: 763-772, 2014.
3. Ding F, Zhang W, Wang L, et al. Epidemiologic features of severe fever with thrombocytopenia syndrome in China, 2011-2012. *Clin Infect Dis* **56**: 1682-1683, 2013.
4. Hu JL, Bao CJ, Qi X, et al. Clinical and epidemiological characteristics on 20 cases of SFTSV infection. *Chin J Zoonoses* **28**: 302-305, 2012 (in Chinese, Abstract in English).
5. Zhu Y, Wu H, Gao J, et al. Two confirmed cases of severe fever with thrombocytopenia syndrome with pneumonia: implication for a family cluster in East China. *BMC Infect Dis* **17**: 537, 2017.
6. Rhodes A, Evans LE, Alhazzani W, et al. Surviving sepsis campaign: international guidelines for management of sepsis and septic shock: 2016. *Intensive Care Med* **43**: 304-377, 2017.
7. Gando S, Saitoh D, Ogura H, et al. Natural history of disseminated intravascular coagulation diagnosed based on the newly established diagnostic criteria for critically ill patients: results of a multicenter, prospective survey. *Crit Care Med* **36**: 145-150, 2008.
8. Guo CT, Lu QB, Ding SJ, et al. Epidemiological and clinical characteristics of severe fever with thrombocytopenia syndrome (SFTS) in China: an integrated data analysis. *Epidemiol Infect* **144**: 1345-1354, 2016.
9. Kato H, Yamagishi T, Shimada T, et al. Epidemiological and clinical features of severe fever with thrombocytopenia syndrome in Japan, 2013-2014. *PLoS One* **11**: e0165207, 2016.
10. Deng B, Zhou B, Zhang S, et al. Clinical features and factors associated with severity and fatality among patients with severe fever with thrombocytopenia syndrome bunyavirus infection in Northeast China. *PLoS One* **8**: e80802, 2013.
11. Hiraki T, Yoshimitsu M, Suzuki T, et al. Two autopsy cases of severe fever with thrombocytopenia syndrome (SFTS) in Japan: a pathognomonic histological feature and unique complication of SFTS. *Pathol Int* **64**: 569-575, 2014.
12. Ware LB, Matthay MA. The acute respiratory distress syndrome. *N Engl J Med* **342**: 1334-1349, 2000.

13. Sureka B, Bansal K, Arora A. Pulmonary edema- cardiogenic or noncardiogenic? J Family Med Prim Care **4**: 290, 2015.
14. Freeman AM, Leigh Jr TR. Pneumonia, viral. StatPearls [Internet]. StatPearls Publishing 2018.

The Internal Medicine is an Open Access journal distributed under the Creative Commons Attribution-NonCommercial-NoDerivatives 4.0 International License. To view the details of this license, please visit (<https://creativecommons.org/licenses/by-nc-nd/4.0/>).

© 2019 The Japanese Society of Internal Medicine
Intern Med 58: 2731-2735, 2019