

MR Enterography in Crohn's Disease: Comparison of Contrast Imaging with Diffusion-weighted Imaging and a special Form of Color Coding

MR-Enterografie bei Morbus Crohn: Vergleich der Kontrastbildgebung mit diffusionsgewichteter Bildgebung und einer besonderen Form der Farbcodierung



Authors

Maja Jakob¹, Maik Backes², Christian Schaefer³, Joerg Albert³, Angela Geissler²

Affiliations

- 1 Molecular Oncology, Robert Bosch Hospital, Stuttgart, Germany
- 2 Radiology, Robert Bosch Hospital, Stuttgart, Germany
- 3 Gastroenterology, Robert Bosch Hospital, Stuttgart, Germany

Key words

MR enterography, MR-diffusion/perfusion, inflammation bowel, color coding, MaRIA Score

received 11.06.2021

accepted 16.03.2022

published online 15.06.2022

Bibliography

Fortschr Röntgenstr 2022; 194: 1119–1131

DOI 10.1055/a-1826-0049

ISSN 1438-9029


© 2022. The Author(s).

This is an open access article published by Thieme under the terms of the Creative Commons Attribution-NonDerivative-NonCommercial License, permitting copying and reproduction so long as the original work is given appropriate credit. Contents may not be used for commercial purposes, or adapted, remixed, transformed or built upon. (<https://creativecommons.org/licenses/by-nc-nd/4.0/>)

Georg Thieme Verlag KG, Rüdigerstraße 14,
70469 Stuttgart, Germany

Correspondence

Frau Prof. Angela Geissler
Department of Radiology, Robert Bosch Hospital,
Auerbachstr. 110, 70376 Stuttgart, Germany
Tel.: +49/7 11/81 01 34 36
Fax: +49/7 11/81 01 37 76
Angela.Geissler@rbk.de

 Supplementary material is available under:
<https://doi.org/10.1055/a-1826-0049>

ABSTRACT

Purpose We compared contrast-enhanced MR enterography with diffusion-weighted sequences to evaluate the validity of diffusion-weighted sequences for activity assessment in Crohn's disease compared to endoscopy. In addition, we investigated a new color-coded image post-processing technique in comparison with standard sequences and endoscopy.

Materials and Methods Included were 197 MR enterographies (2015–2017) performed by using standardized examination protocols. The intestine was divided into 7 segments, which were compared separately. The accuracy of the MR examinations with regard to disease activity was validated using the Seo and MaRIA score and endoscopy findings. In addition, the image data were post-processed using a color-coded evaluation method (DCE tool on OsiriX).

Results The comparison between contrast-enhanced and diffusion-weighted sequences showed a highly significant correlation for all bowel sections with a mean Spearman correlation coefficient of 0.876 (0.809–0.928). The color-coded image post-processing showed a sensitivity of 83.2% and a specificity of 70.5% in comparison with the MaRIA score. In comparison to endoscopy, a sensitivity of 81.3% and a specificity of 70.5%. In comparison with endoscopy, the MaRIA score showed a sensitivity of 80.2% and a specificity of 84.0% at a cut-off of 7. The visual score according to Seo showed a sensitivity of 85.7% with a specificity of 77.0% in the contrast-weighted examination and a sensitivity of 87.9% and a specificity of 71.8% for diffusion weighted images.

Conclusion Diffusion-weighted sequences are as good as contrast-weighted sequences for assessing inflammatory activity in Crohn's disease. Contrast is often helpful for assessing complications, but this was not the purpose of this study. Visual imaging using color-coded data sets was similarly good at detecting inflammation.

Key points:

- MR enterography is possible without contrast using diffusion-weighted imaging with comparable high informative value.

- Inflammatory activity in MR correlates sufficiently well with endoscopy
- The MaRIA and Seo scores are comparable in their validity.
- The colored representation of inflamed bowel sections is a promising technique.

Citation Format

- Jakob M, Backes M, Schaefer C et al. MR Enterography in Crohn's Disease: Comparison of Contrast Imaging with Diffusion-weighted Imaging and a special Form of Color Coding. *Fortschr Röntgenstr* 2022; 194: 1119–1131

ZUSAMMENFASSUNG

Ziel Vergleich der entzündlichen Aktivität verschiedener Darmabschnitte in der kontrastmittelgestützten MR-Enterografie mit diffusionsgewichteten Sequenzen und dem endoskopischen Befund. Eine neue farbcodierte Bildnachverarbeitung wurde im Vergleich zu den Standardsequenzen und der Endoskopie untersucht.

Material und Methoden Eingeschlossen wurden 197 MR-Enterografien aus den Jahren 2015–2017. Der Darm wurde in 7 Segmente unterteilt, die separat verglichen wurden. Die Treffsicherheit der MR-Untersuchungen bezüglich entzündlicher Darmwandveränderungen wurde mittels Endoskopie sowie Seo- und MaRIA-Scores validiert. Zusätzlich wurden die

Bilddaten mithilfe eines farbcodierten Auswerteverfahrens (DCE-Tool auf OsiriX) nachverarbeitet.

Ergebnisse Der Vergleich zwischen kontrastgestützten und diffusionsgewichteten Sequenzen ergab für alle Darmabschnitte eine hochsignifikante Korrelation mit einem mittleren Korrelationskoeffizienten nach Spearman von 0,876 (0,809–0,928). Die farbcodierte Bildnachverarbeitung zeigte im Vergleich mit dem MaRIA-Score eine Sensitivität von 83,2% und eine Spezifität von 70,5%. Im Vergleich zur Endoskopie fand sich eine Sensitivität von 81,3% und eine Spezifität von 70,5%. Der MaRIA-Score zeigte im Vergleich mit der Endoskopie beim Cut-Off von 7 eine Sensitivität von 80,2% bei einer Spezifität von 84,0%. Der visuelle Score nach Seo zeigte bei der kontrastgestützten Untersuchung eine Sensitivität 85,7% bei einer Spezifität von 77,0%, bei der diffusionsgewichteten Sequenz eine Sensitivität von 87,9% und einer Spezifität von 71,8%.

Schlussfolgerung Diffusionsgewichtete Sequenzen sind zur Beurteilung der Entzündungsaktivität bei Morbus Crohn ebenso gut geeignet wie kontrastgestützte Sequenzen. Zur Beurteilung von Komplikationen ist eine Kontrastmittelgabe oft hilfreich. Die Darstellung mittels farbcodierter Datensätze konnte Entzündungen ähnlich gut nachweisen und könnte die Befunddemonstration in der interdisziplinären Zusammenarbeit verbessern helfen.

Introduction

Magnetic resonance enterography has replaced small bowel double-contrast radiographic imaging for detection and assessment of disease activity in Crohn's disease [1–3]. For the detection of ileitis terminalis, MR enterography examination has comparable accuracy to ileocolonoscopy or capsule endoscopy [4, 5]. Endoscopic procedures achieve a higher sensitivity than MR enterography or computed tomography only in the detection of inflammatory changes of the upper small intestine [6].

The value of diffusion-weighted MR enterography compared with contrast-enhanced MR enterography has not been conclusively established [7, 8]; consequently optimal sequence selection and patient preparation, as well as comparison to endoscopic findings, is the subject of current research [9–11].

Patients with Crohn's disease usually need to be examined several times during their lives using cross-sectional imaging, preferably MRI due to the absence of radiation. However, the gadolinium-containing MRI contrast agent used for this purpose today may accumulate in body tissues [12, 13].

Furthermore, because the clinical relevance of these gadolinium deposits is currently unclear and contrast application represents a potentially eliminable cost factor, the aim of this study was to statistically compare diffusion-weighted (DWI) MR enterography and contrast-enhanced MR enterography with each other and with endoscopic findings.

We also investigated whether semiquantitative evaluation and integrated color-coded display of contrast-enhanced MR sequen-

ces could be used to facilitate assessment of disease activity. Integrated, color-coded display of contrast agent dynamics enables easier demonstration and discussion of findings in interdisciplinary exchange.

Materials and Methods

Patient Cohort

The Ethics committee of the University of Tübingen has informed us that no ethics vote is required for this retrospective study. The study was conducted in compliance with the Declaration of Helsinki.

The study population of this retrospective study included 197 patients with previously known or newly diagnosed Crohn's disease who underwent a complete MR enterography examination (including contrast-enhanced and diffusion-weighted sequences) between July 1, 2015 and December 31, 2017, at the Robert Bosch Hospital in Stuttgart, Germany, and who also underwent an endoscopic examination of the bowel within ± 30 days.

All MR enterography examinations were performed on a 1.5 Tesla MRI (Siemens Aera). The study included 197 MR examinations performed on 177 patients. Of these, 88 were women aged 17–76 years (mean 40.1) and 90 were men aged 17–75 years (mean 39.7 years) with 0 to 46 years of disease since initial diagnosis (mean 13.2 years). The jejunum, ileum, terminal ileum, ascending colon, transverse colon, descending colon, and sigmoid colon sections were assessed separately for each patient. Exami-

▶ **Table 1** MR enterography sequence overview.

Sequence name	Description	Orientation	TR [ms]	TE [ms]	Slice thickness (mm)	Distance factor [%]	No. of slices	Flip angle
T1_fl2d_tra_mbh	T1-weighted	Transverse	131	4	6	20	30	70°
T2_haste_tra_mbh	T2-weighted	Transverse	1000	107	6	20	30	180°
T2_haste_tim_cor_mbh	T2-weighted Fat saturation	Coronary	1000	94	6	20	28	180°
T2_trufi_cor_bh	Evidence of adhesions	Coronary	3.21	1.61	6	20	28	70°
Angio_3D_cor_bh 4 runs*	Sequences with i. v. contrast agent	Coronary	3.29	1.12	1.2	20	104	25°
T1_vibe_fs_cor	Thin-layered	Coronary	3.3	1.26	1.3	20	120	11°
T1_fl2d_fs_tra_mbh	Late venous phase	Transverse	122	2.34	6	20	30	80°
ep2d_diff_spair_b0_800_tra	Diffusion-weighted	Transverse	8200	75	6	20	30	According to b-value

TE = echo time; TR = repetition time; i. v. = intravenous.

* A total of 4 runs, the first native, the following 3 after intravenous contrast administration, each with 60 s interval.

nations included only those sections of bowel that were still present and sufficiently distended for diagnostic purposes and could be assessed.

Of all 177 patients studied, 54 % (n = 96) had undergone previous bowel surgery in the context of the underlying disease.

MR imaging revealed bowel stenosis in 37 % (n = 66) of examinations, abscesses were found in 12 % (n = 21), and fistulas were present (interenteric or perianal) in 25 % (n = 44).

MR Enterography

After oral administration of contrast with 1000 ml of 2.5% mannitol solution mixed with 5 g of hydroxyethylcellulose, the examination was performed after intravenous administration of butylscopolamide (20 mg per 30 kg body weight) and the MR contrast agent gadotriol (0.2 ml per kg body weight). All study patients well tolerated both the orally and intravenously administered contrast agent.

Examination Sequences

▶ **Table 1** shows the MRI sequences used in the study.

Image Evaluation

MaRIA score

As described by Rimola et al. [14], each bowel section was evaluated separately.

The MaRIA score was calculated using the following formula [14]:

(MaRIA(S) = 1.5 * wall thickness + 0.02 * RCE + 5 * edema + 10 * ulceration)

where $RCE = \frac{(WSI_{postgadolinium} - WSI_{pregadolinium})}{WSI_{postgadolinium}} \times 100 \times \frac{(SD_{noisepregadolinium})}{(SD_{noisepostgadolinium})}$

According to the study by Rimola et al. [14], acute inflammation is assumed from a value of MaRIA ≥ 7; we also used this value as a cut-off value for the diagnosis of acute inflammation.

Seo score

A score was developed by Seo et al. (called “Seo score” in this paper see ▶ **Table 2**), which allowed comparison of diffusion-weighted (DWI) and contrast-enhanced MR sequences in Crohn’s disease [15]. The Seo score is the closest to routine clinical evaluation of MR images and is one of the few scoring systems available for the assessment of DWI sequences.

Image post-processing (generation of integrated color-coded perfusion maps)

The plug-in “DCE Tool” developed by Kyung Sung was used for the DICOM Viewer OsiriX and enables the processing and evaluation of dynamic, contrast-enhanced sequences [16]. Originally programmed for cerebral applications, we first used the software to assess chronic inflammatory bowel disease.

The plug-in offers different options to create parametric maps; in the present work the colored representation of the integral

► **Table 2** Overview of Seo score parameters [15].

Parameter	Score = 0	Score = 1	Score = 2	Score = 3
Wall thickness in mm	1–3	>3–5	>5–7	>7
Mural signal intensity in T2-weighted images	Equivalent to healthy bowel wall	Slight increase in signal intensity: bowel wall appears dark gray in fat-saturated images.	Moderate increase in signal intensity, in which the bowel wall appears as bright gray in fat-saturated images.	Strong increase in signal intensity: Bowel wall contains areas of high signal intensity, approaching that of the luminal content.
Perimural signal intensity in T2-weighted images	Equivalent to normal mesentery	Increased signal of mesentery, but no free fluid	Free fluid (≤ 2 mm)	Free fluid (> 2 mm)
Signal amplification in T1-weighted images (DCE only)	Equivalent to healthy bowel wall	Slight signal enhancement of the intestinal wall compared to the healthy one, but significantly weaker than nearby vascular structures.	Moderate increase in the signal intensity of the bowel wall, slightly lower than in nearby vascular structures.	Strong signal enhancement: Bowel wall signal intensity approaches that of nearby vascular structures.
Signal intensity in diffusion-weighted imaging (DWI)	No increased diffusion restriction	Increased DWI signal intensity, similar to but lower than that of lymph nodes.	Elevated DWI signal intensity indistinguishable from that of lymph nodes.	Increased DWI signal intensity, which is higher than that of the lymph nodes and spleen.

DCE = dynamic contrast enhancement, this parameter is only used for the Seo score including contrast-enhanced imaging (Seo DCE).

DWI = diffusion weighted imaging, this parameter is only used for the Seo score including diffusion-weighted imaging (Seo DWI).

The sum of the values determined per parameter results in the Seo score of the corresponding intestinal segment. The first four values are relevant for the DCE Seo score, the first three values and the fifth value for the DWI Seo score.

value (the “area under the curve” parameter) was used. This is described in greater detail in the attached appendix. In this case the “jet” color scale was employed (see ► **Fig. 1**).

The evaluation was performed with the DCE tool after subtracting the native sequences from the contrast-enhanced sequences (reduction of the color noise of the parametric evaluation) (► **Fig. 16**). The integrated color parameter maps were output for visual findings with a color scale width of 5% to 50%. This resulted in thoroughly improved visualization of severely inflamed intestinal section segments. ► **Fig. 1** shows a typical semiquantitative representation of an inflamed intestinal section with small severely inflamed areas.

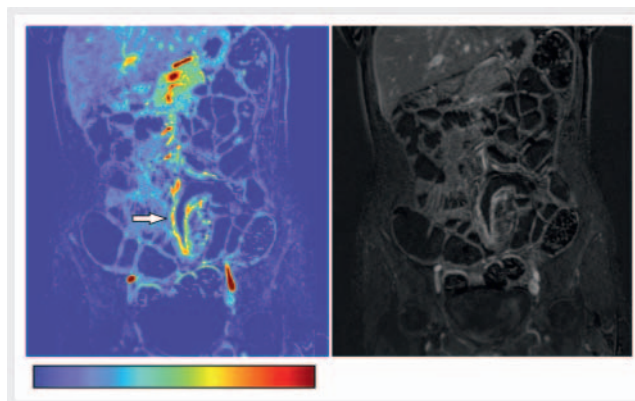
Evaluation of integrated parametric perfusion maps

ROI determined an integral value in a representative section of the intestinal wall. An ROI was placed in the aorta of all patients as an external reference. The highest value measured in one patient was referenced to all other measured intestinal sections to ensure comparability of integral values.

Endoscopic examination

For comparison all endoscopic examinations performed in the period of ± 30 days relative to MRI were used.

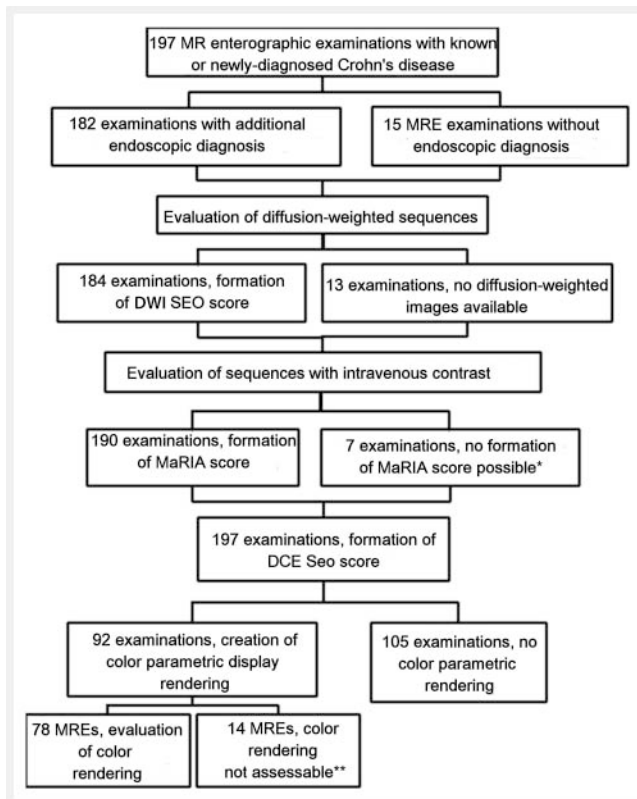
In all, 169 colonoscopies were performed. The study included 137 examinations of the terminal and an additional 10 examinations down to the preterminal ileum. Push enteroscopy of the small intestine was performed in 12 patients.



► **Fig. 1** Contrast-enhanced image and parametric representation of the “area under the curve” with image subtraction. Below the colour gradient of the “Jet” colour scale.

A total of 525 intestinal segments were evaluated endoscopically, including: 162 small intestinal segments (including 142 terminal ileum) and 363 large intestinal segments.

A modified SES-CD (simple endoscopic score for Crohn’s disease) was used based on the pathological changes mentioned in the findings [17]. To achieve better comparability of the endoscopy results, we classified the intestinal sections as either unremarkable (score 0) or inflamed (score 1), independent of the severity of inflammation subjectively documented by the examiner.



► **Fig. 2** Overview of the evaluation. * Absence of the native angio sequence; therefore no calculation of the MaRIA score possible. In another 2 cases, only the transverse colon could not be assessed, as this section of the intestine was outside the selected FOV. ** In 10 cases, one of the 4 required sequences (native or post-KM) was missing, whereby it was not possible to determine whether these were not measured or were lost during transfer to the archive; in 2 cases, the movement artefacts were too strong and the image overlay could not be evaluated; in 2 cases, the position of the FOV was changed during the angio images and an overlay or calculation of the parametric map was not possible.

Image evaluation

All image data were evaluated in triplicate at 4-week intervals by a physician trained in this procedure. In the third run, the color parametric display was created. The procedure of the standardized evaluation can be seen in ► **Fig. 2**.

Statistics

All recorded parameters and results were analyzed using the statistical software SPSS, IBM Statistics, version 20.0.0.

The values of the two Seo scores were plotted against each other in a scatterplot and presented in subtraction histograms (► **Fig. 3–9**).

Evaluation of intestinal segments by Seo score was correlated using Spearman's rank correlation (► **Table 3**).

In addition, the different evaluation methods of MR enterography using receiver operating characteristic curves (ROC curves) versus endoscopic results were presented, possible cut-off values and their sensitivity and specificity were shown, and the area

under the curve is determined, which is another criterion for the discriminatory power of the various diagnostic methods.

Results

Comparison of Seo scores (DWI vs. contrast)

The scatterplots in ► **Fig. 3–9** visually indicate a good correlation between diffusion-weighted and contrast-enhanced MRI with respect to the inflammatory expression of the intestinal segments, with a score 12 corresponding to the most severe inflammatory expression of an intestinal segment.

A statistical comparison of diffusion-weighted and contrast-assisted MRI shows a significant Spearman's correlation for each intestinal segment, see ► **Table 3**. The jejunum showed a correlation coefficient of 0.854, the ileum 0.822, and the terminal ileum 0.928. For the colon, the value for the descending colon is 0.809, for the transverse colon 0.892, for the descending colon 0.913, and for the sigmoid colon likewise 0.913. The p-value for all intestinal segments is < 0.05.

Comparison of MaRIA score versus Seo score

These two scoring systems do not differ significantly in their accuracy. There were 284 positive, 427 negative and 87 absent values. ► **Fig. 10** shows the receiver operating characteristic curve (hereafter ROC curve) with the corresponding evaluation.

Endoscopy Evaluation

In a total of 798 intestinal segments examined by MR enterography, a corresponding endoscopic finding was identified in 551 images. Of the missing 247 segments, 169 intestinal segments could not be reached endoscopically, in 17 a stenosis could not be passed, in 10 there was too much contamination, and in 51 segments endoscopy could not be performed because of poor patient preparation.

A total of 229 positive, i. e. inflamed, and 322 inflammation-free intestinal sections were evident.

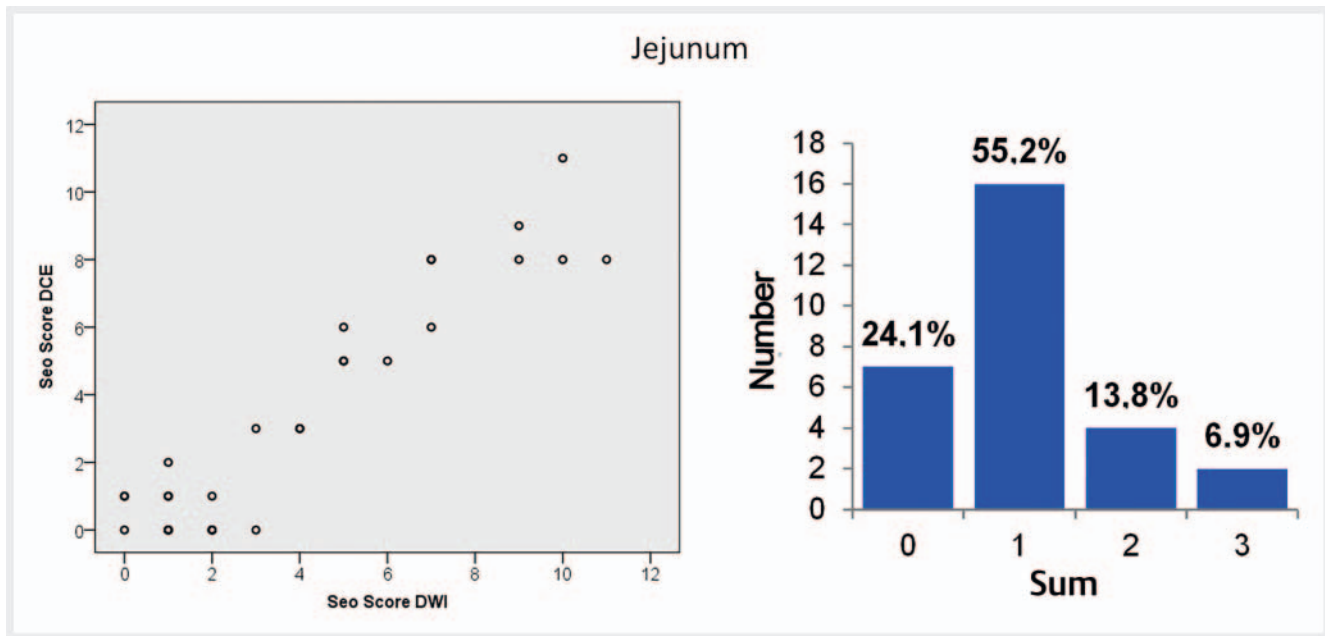
Comparison of Seo score (contrast) versus endoscopy

In this observation, there were 227 positive (inflamed segments), 322 negative (non-inflamed segments) and 249 missing values (non-existent/non-evaluable segments).

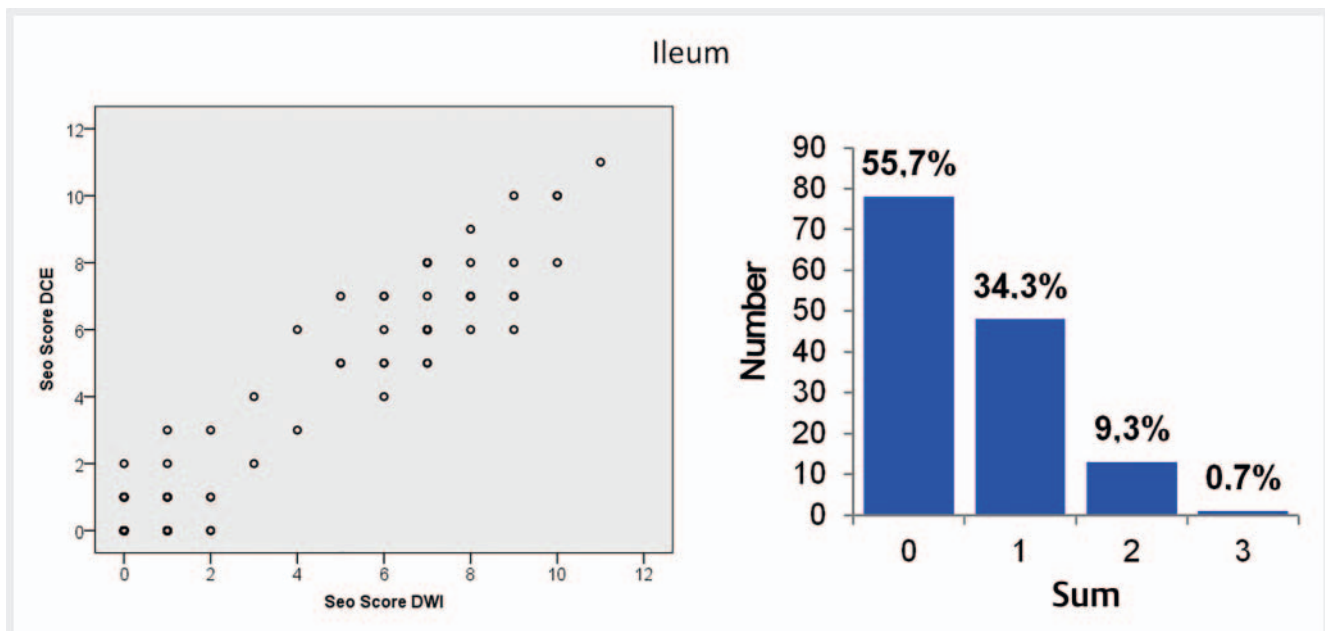
A comparison of the endoscopically obtained findings with the contrast-enhanced MR images showed a good correlation (► **Fig. 11**). The area under the curve is 0.883 with a confidence interval of 0.853–0.912. Considering possible cut-off values with the corresponding values of sensitivity and specificity, the best ratio between sensitivity and specificity is found with a cut-off value of 3.5 (sensitivity 85.7%, specificity 77.0%).

Comparison of Seo score (DWI) versus endoscopy

In this observation, there were 218 positive (inflamed segments), 298 negative (non-inflamed segments) and 282 missing values (non-existent/non-evaluable segments). Taking into consideration the ROC curve in ► **Fig. 12** and the calculated area under the



► **Fig. 3** Scatterplot and histogram of the evaluation for the intestinal segment of the jejunum. Seo DCE = Seo score including contrast-enhanced imaging. Seo DWI = Seo score including diffusion-weighted imaging.



► **Fig. 4** Scatterplot and histogram of the evaluation for the intestinal segment of the ileum. Seo DCE = Seo score including contrast-enhanced imaging. Seo DWI = Seo score including diffusion-weighted imaging.

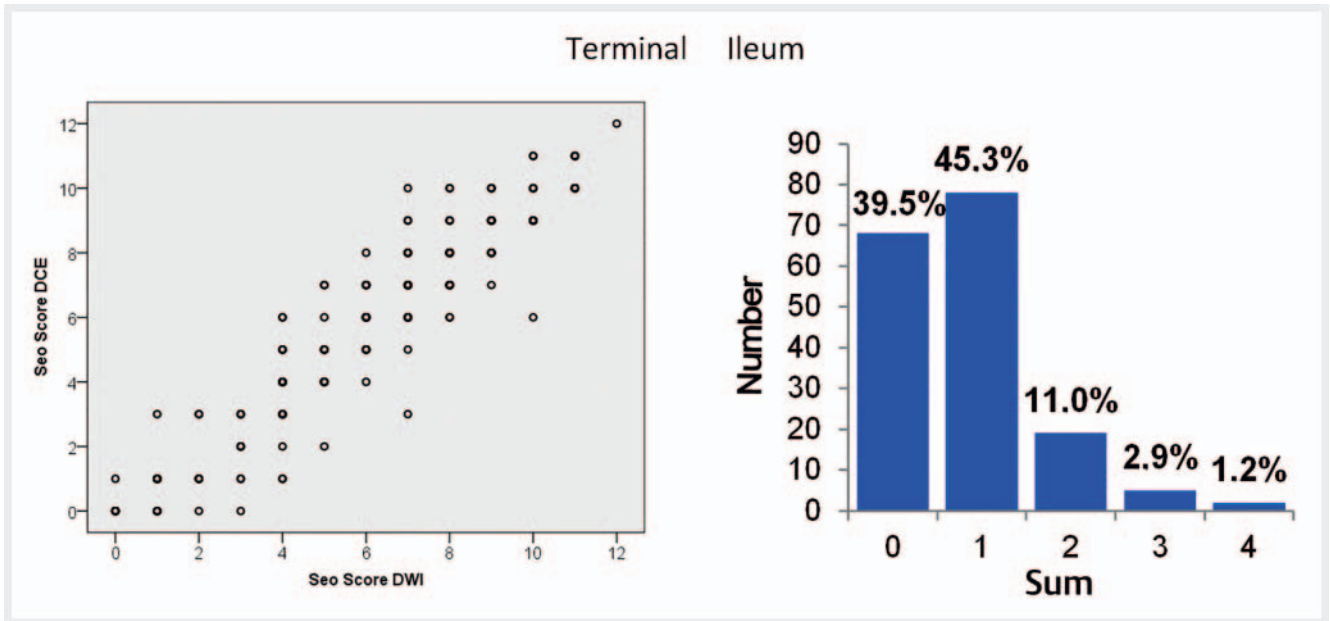
curve results in a value of 0.871 with a confidence interval of 0.839–0.902. A cut-off value of 3.5 results in a sensitivity of 87.9% and a specificity of 71.8%. The optimal cut-off values are identical for contrast- and diffusion-weighted imaging.

► **Fig. 13** shows an interesting case in which diffusion-weighted imaging shows a contrary finding to endoscopy.

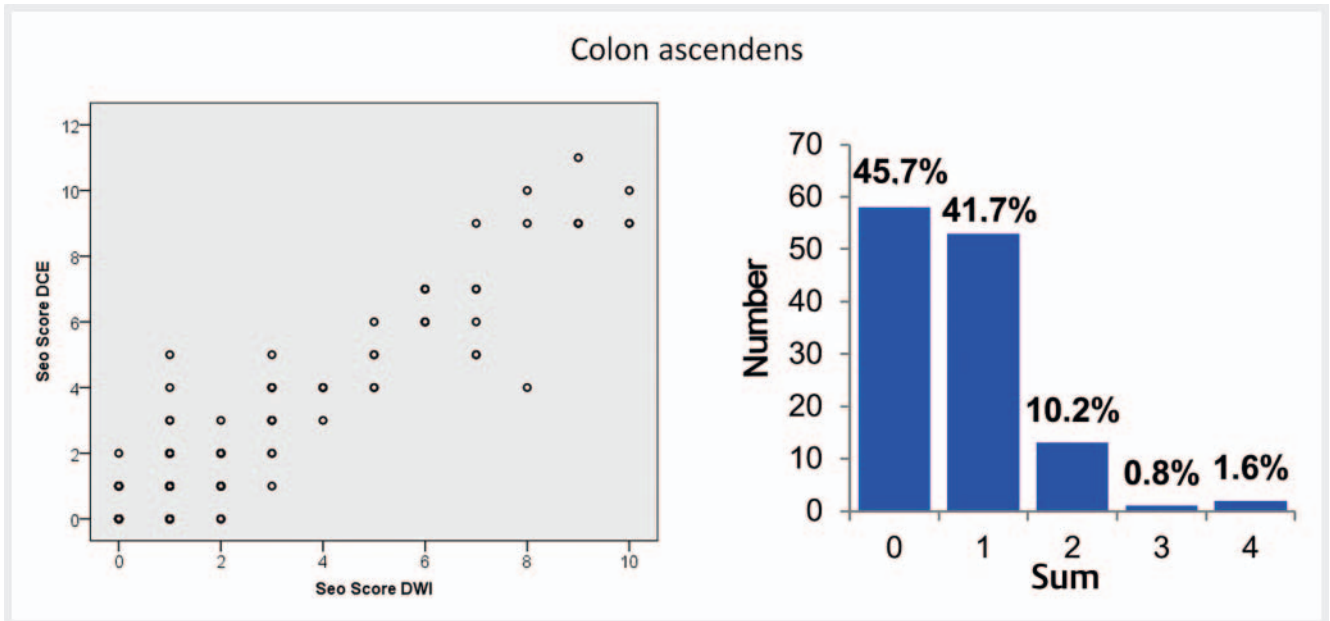
Comparison of MaRIA score versus endoscopy

A comparison with the result of the Seo score shows 215 positive (inflamed segments), 313 negative (non-inflamed segments) and 270 missing values (non-existent/non-evaluable segments).

This results in an area under the curve of 0.871 (► **Fig. 14**) with a confidence interval of 0.839–0.904.



► **Fig. 5** Scatterplot and histogram of the evaluation for the intestinal segment of the terminal ileum. Seo DCE = Seo score including contrast-enhanced imaging. Seo DWI = Seo score including diffusion-weighted imaging.



► **Fig. 6** Scatterplot and histogram of the evaluation for the intestinal segment of the ascending colon. Seo DCE = Seo score including contrast-enhanced imaging. Seo DWI = Seo score including diffusion-weighted imaging.

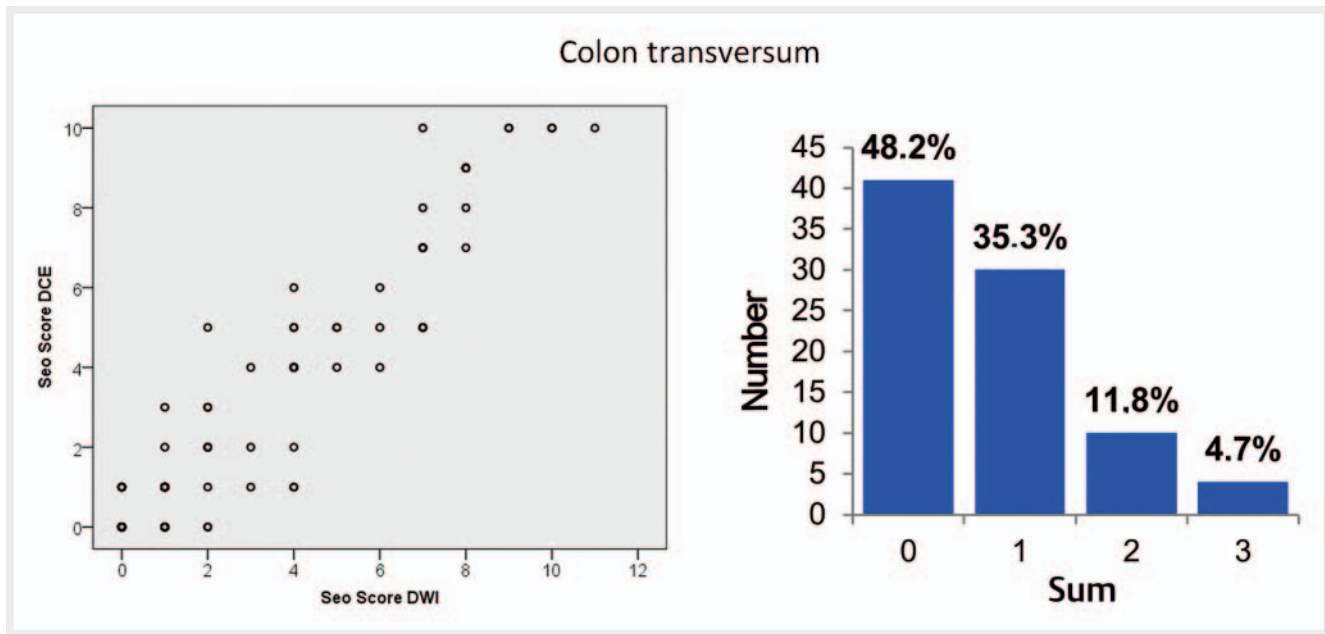
The literature [14] suggests a cut-off value of 7 for a detected inflammation. A cut-off value of 7.0 results in a sensitivity of 80.2% and a specificity of 84.0%.

ROC correlation of color integral value with MaRIA score

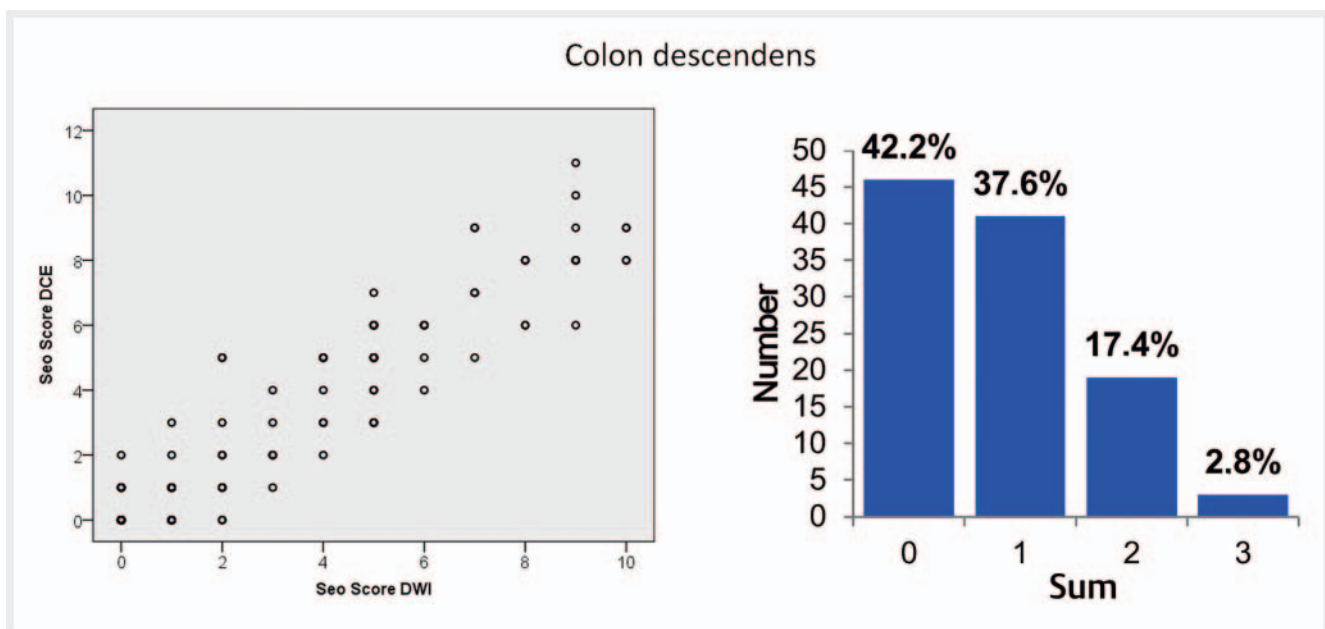
Comparison of the integrated contrast-enhanced color-coded score with the MaRIA score showed good agreement. We defined evaluation-specific cut-off values in order to optimize sensitivity

and specificity. Since sensitivity in the presence of known chronic bowel disease is more important for clinical course assessment, the cut-off was chosen with this in mind.

The area under the curve is 0.84 with a confidence interval of 0.795–0.888. A cut-off value of 21 245 results in a sensitivity of 83.2% and a specificity of 70.5%. With a cut-off value of 27 569, the specificity is 85.0% with a significant loss of sensitivity (70.6%).



► **Fig. 7** Scatterplot and histogram of the evaluation for the intestinal segment of the transverse colon. Seo DCE = Seo score including contrast-enhanced imaging. Seo DWI = Seo score including diffusion-weighted imaging.



► **Fig. 8** Scatterplot and histogram of the evaluation for the intestinal segment of the descending colon. Seo DCE = Seo score including contrast-enhanced imaging. Seo DWI = Seo score including diffusion-weighted imaging.

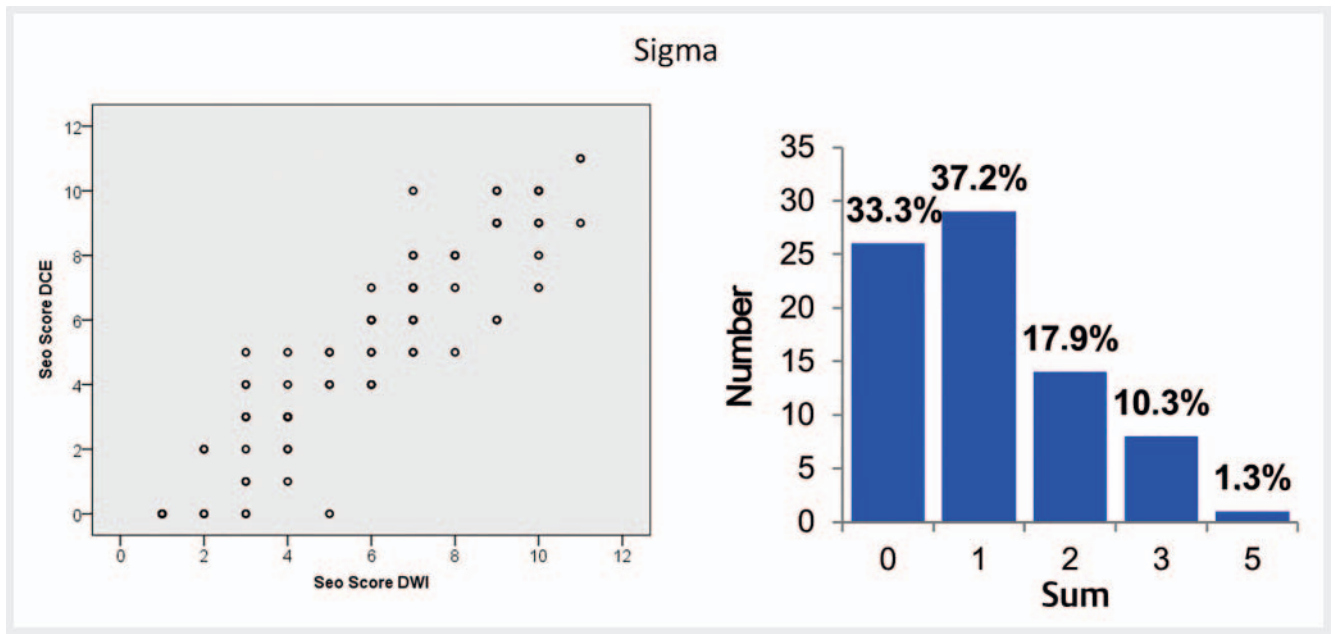
ROC correlation of color integral value with endoscopy

There is a good correlation between the color-coded images and the endoscopy findings. The area under the curve is 0.82 with a confidence interval of 0.76–0.88. A cut-off value of 22 760 results in a sensitivity of 81.3% and a specificity of 70.5%. ► **Fig. 15** shows the corresponding ROC curve.

Summary of the most important test results

Looking at the different evaluations of diffusion-weighted and contrast-enhanced imaging, we can summarize that the two do not differ significantly with respect to the assessment of the presence of inflammation of intestinal segments.

If this question alone is the issue, it is therefore possible to dispense with intravenous contrast agent application during MRI.



► **Fig. 9** Scatterplot and histogram of the evaluation for the intestinal segment of the sigma. Seo DCE = Seo score including contrast-enhanced imaging. Seo DWI = Seo score including diffusion-weighted imaging.

The method developed for this study for semiquantitative, color-parametric imaging of intestinal wall inflammation shows good sensitivity and specificity compared with the established MaRIA score and endoscopic examinations, even with few dynamic measurement time points.

Discussion

Comparison of MR scores versus endoscopy

Seo et al. [15] previously compared contrast-enhanced assisted with diffusion-weighted MR imaging. Averaged over all intestinal sections, a good correlation of 0.937 was found. However, the study was performed at 3 Tesla and mainly examined the terminal ileum.

In our study, we found a correlation coefficient of 0.854 in the jejunum, 0.822 for the ileum, and 0.928 for the terminal ileum; thus, our results are comparable to Seo's working group. Likewise, Cansu's study [7] demonstrated good agreement between DWI and contrast-enhanced MRI. The specificity was somewhat higher than in our study (97.9%). However, the examination was performed at 3 Tesla and only involved the colon and terminal ileum [7].

The MaRIA score described by Rimola [14] was developed for comparison with endoscopic findings and correlates well with them. For the MaRIA score, the specificity in our study was 84% and sensitivity was 80%. With a cut-off of 7, our data were slightly worse than in the publication by Rimola (sensitivity 88%, specificity 82%) [14].

In our retrospective evaluation of endoscopy findings, we used a modified SES-CD score to achieve greater consistency of data [17]. In addition to colonoscopies, we also included both double

balloon and capsule endoscopies for comparison, whereas in the other studies only the terminal ileum was included in the analysis. If only the terminal ileum from our study data is used for the evaluation, our results correspond approximately to the published results mentioned. Ulcerations are often difficult to detect at 1.5 Tesla, so we may have underestimated the severity of inflammation in this case. However, 1.5 Tesla devices continue to be widely used and reflect well the capabilities used in clinical practice.

We used the MaRIA score for comparison with Seo, as it showed the highest accuracy [18, 19].

In a review article by Minordi et al. [20], a comparison of the different studies demonstrated a range of sensitivity compared to endoscopy between 87% and 64% and a specificity of 85%–81% similar to our study.

Comparatively, the specificity of DWI MRI in our study was 72%, the sensitivity was about 88%; for contrast-enhanced MRI the specificity was 77% and sensitivity was 86%. Integrated contrast-enhanced color-coded evaluation showed a specificity of 71% and a sensitivity of 81%.

Despite its less than ideal sensitivity and specificity, MR enterography is a valid method in clinical routine for the diagnosis and progress assessment of inflammatory bowel changes due to the complete visualization of the intestinal tract and lack of invasiveness, especially if the work of Lee et al. [21] is included. In this study evidence of inflammatory change on MRI was even associated with a worse prognosis despite unremarkable endoscopy [21].

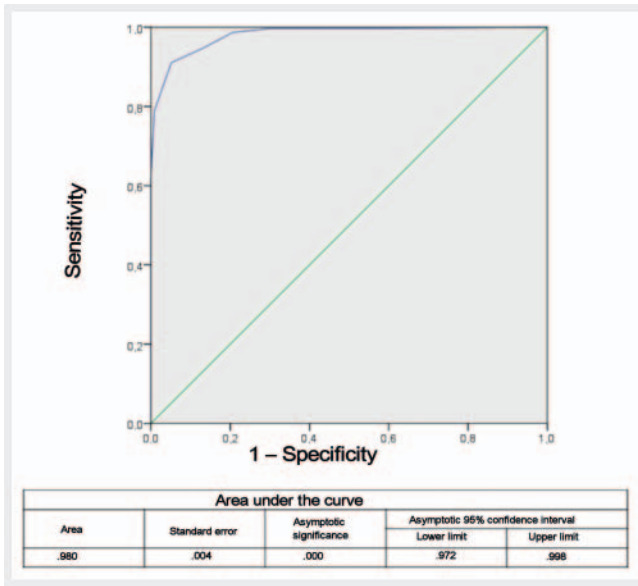
For the follow-up assessment of inflammatory bowel wall lesions, our study shows that omission of contrast agent administration is possible without significant loss of sensitivity. The detection of abscesses is also possible in a synopsis of all acquired native

► **Table 3** Correlations of individual intestinal sections.

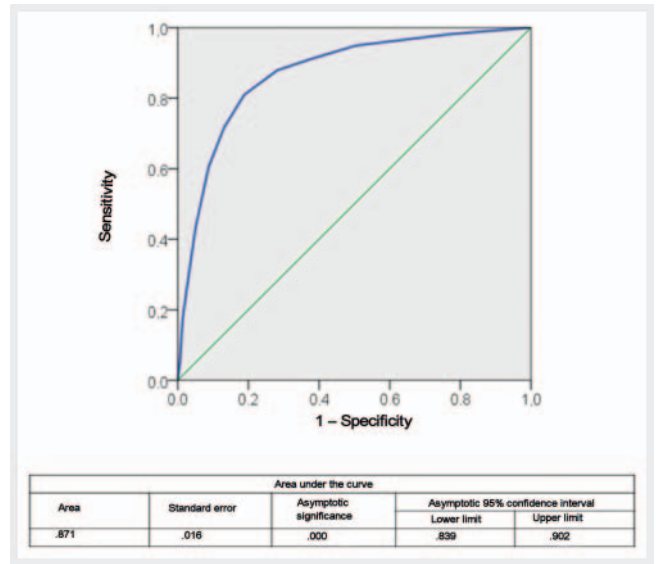
Jejunum			DCE Seo score	DWI Seo score
Spearman's Rho	DCE Seo score	Correlation coefficient	1	0.854**
		Sig. (2-tailed)	.	.000
		N	33	29
	DWI Seo score	Correlation coefficient	0.854**	1
		Sig. (2-tailed)	.000	.
		N	29	29
Ileum			DCE Seo score	DWI Seo score
Spearman's Rho	DCE Seo score	Correlation coefficient	1.000	0.822**
		Sig. (2-tailed)	.	.000
		N	151	140
	DWI Seo score	Correlation coefficient	0.822**	1.000
		Sig. (2-tailed)	.000	.
		N	140	140
Terminal ileum			DCE Seo score	DWI Seo score
Spearman's Rho	DCE Seo score	Correlation coefficient	1.000	0.928**
		Sig. (2-tailed)	.	.000
		N	184	172
	DWI Seo score	Correlation coefficient	0.928**	1.000
		Sig. (2-tailed)	.000	.
		N	172	172
Transverse colon			DCE Seo score	DWI Seo score
Spearman's Rho	DCE Seo score	Correlation coefficient	1.000	0.892**
		Sig. (2-tailed)	.	.000
		N	93	85
	DWI Seo score	Correlation coefficient	0.892**	1.000
		Sig. (2-tailed)	.000	.
		N	85	87
Descending colon			DCE Seo score	DWI Seo score
Spearman's Rho	DCE Seo score	Correlation coefficient	1.000	0.913**
		Sig. (2-tailed)	.	.000
		N	118	109
	DWI Seo score	Correlation coefficient	0.913**	1.000
		Sig. (2-tailed)	.000	.
		N	109	109
Sigmoid			DCE Seo score	DWI Seo score
Spearman's Rho	DCE Seo score	Correlation coefficient	1.000	0.913**
		Sig. (2-tailed)	.	.000
		N	80	78
	DWI Seo score	Correlation coefficient	0.913**	1.000
		Sig. (2-tailed)	.000	.
		N	78	78

** . Correlation is significant at 0.01 (2-tailed).

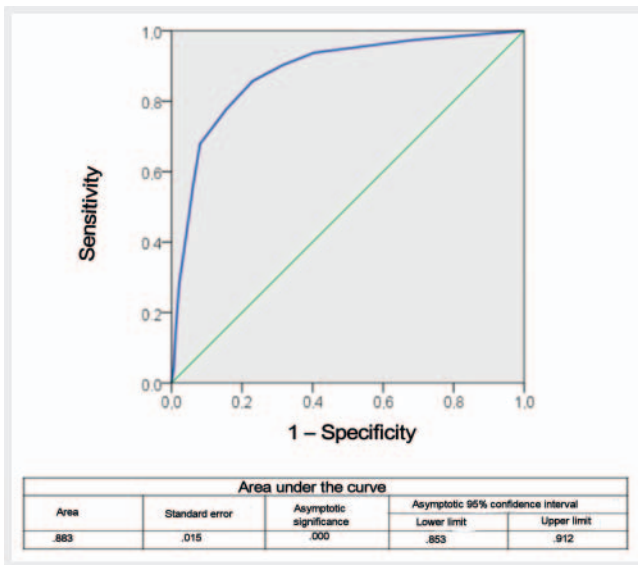
N = number; Sig. = significance; DCE Seo score = calculated Seo score including contrast-enhanced images; DWI Seo score = calculated Seo score including diffusion-weighted images.



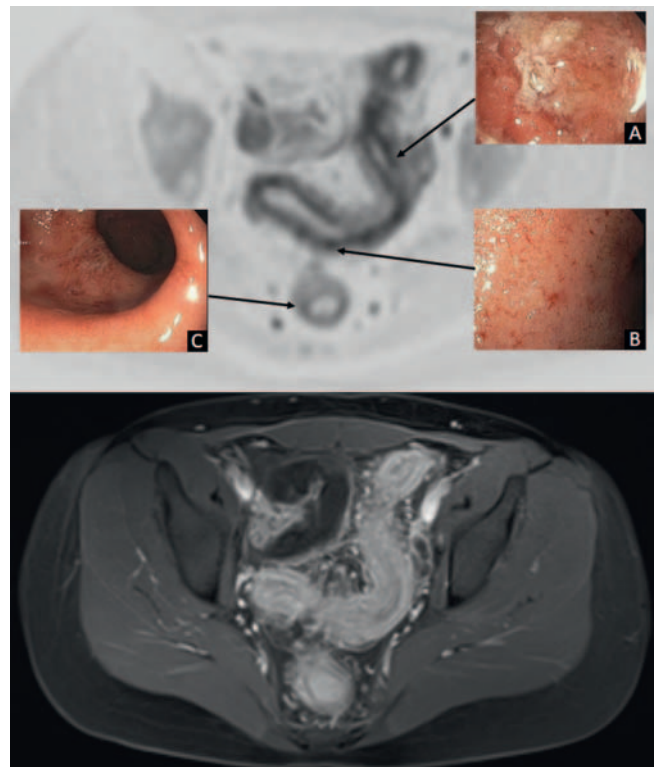
► Fig. 10 Area under the curve ROC value: Seo score DCE vs. MaRIA.



► Fig. 12 ROC curve: Seo DWI vs. endoscopy.



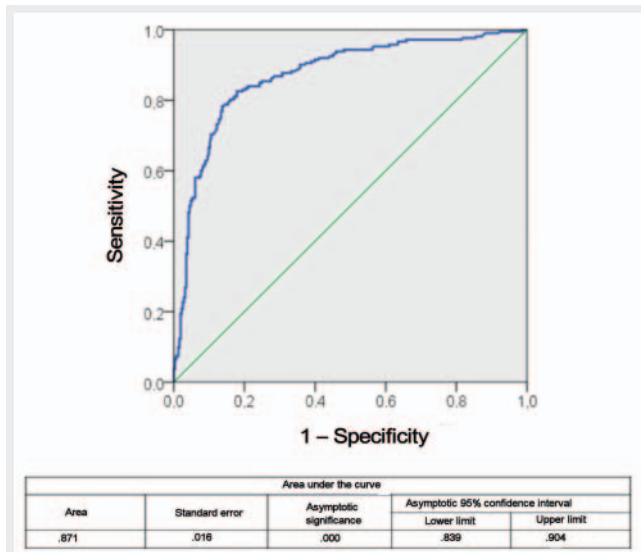
► Fig. 11 ROC curve: Seo score DCE vs. endoscopy.



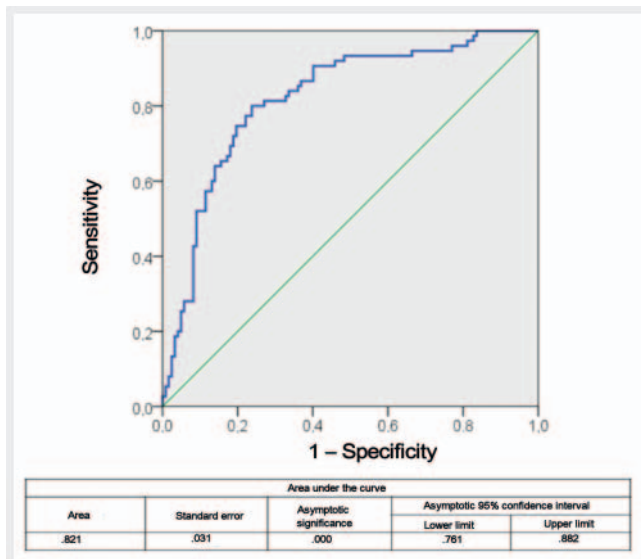
► Fig. 13 Crohn's colitis in a 23-year-old female patient: comparison of endoscopy vs. diffusion imaging: A. proximal sigmoid, B. distal sigmoid, C. rectum. In A and B, clear evidence of inflammation in both procedures, in localisation C endoscopically relatively bland appearance compared to the clearly recognisable transmural inflammation in the diffusion image. The contrast-enhanced image shows the massive inflammation and, more impressively, a small abscess.

MRI sequences together with diffusion-weighted imaging, but was not the subject of the study.

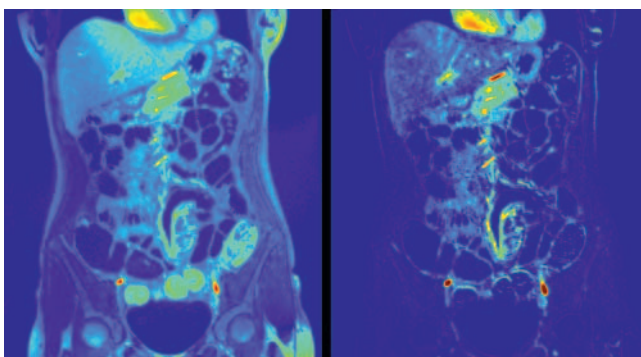
In order to simplify the rapid visual evaluation of the MRI studies, we examined the value of a color representation using a color integral for the semi-quantitative assessment of the inflammatory activity. To our knowledge, we were the first to develop and employ this color parametric display for the evaluation of inflammatory bowel disease. It showed good sensitivity and specificity compared to the already established MaRIA score and also compared to endoscopic examinations. The investigators described the detection of pathological changes as easier. However, this means an increased amount of effort due to the currently necessary manual processing of the MRI datasets. Colored



► Fig. 14 ROC curve: MaRIA score vs. endoscopy.



► Fig. 15 ROC curve: colour integral vs. endoscopy.



► Fig. 16 Left side: Parametric representation of the “area under the curve” without image subtraction. Right side: Parametric representation of the same structures after image subtraction.

representation of inflammatory changes could certainly be simplified with the help of AI algorithms and would be advantageous for the progression assessment and presentation of inflammatory changes and their severity in everyday clinical practice.

CLINICAL RELEVANCE OF THE STUDY

- We were able to demonstrate a good correlation between contrast-enhanced and DWI MRI sequences for inflammatory changes in Crohn’s disease.
- Contrast-free DWI MRI is particularly suitable for progress assessments.
- The established MaRIA and Seo scores correlate well with endoscopy.
- The Seo score is easier to use in clinical routine since it offers a visual classification.
- The integrated, contrast-enhanced, color-coded evaluation of the MRI studies, which we used for the first time, showed a good correlation with the established methods and is a promising new method for the semi-quantitative evaluation of MR enterographies.

Conflict of Interest

The authors declare that they have no conflict of interest.

Literatur

- [1] Griffin N, Grant LA, Anderson S et al. Small bowel MR enterography: problem solving in Crohn’s disease. *Insights Imaging* 2012; 3: 251–263. doi:10.1007/s13244-012-0154-3
- [2] Albert JG, Martiny F, Krummnerl A et al. Diagnosis of small bowel Crohn’s disease: a prospective comparison of capsule endoscopy with magnetic resonance imaging and fluoroscopic enteroclysis. *Gut* 2005; 54: 1721–1727. doi:10.1136/gut.2005.069427
- [3] Schreyer AGLD, Koletzko S, Hoffmann JC et al. Aktualisierte S3-Leitlinie zur Diagnostik des M. Crohn – Radiologische Untersuchungstechniken. *RöFo* 2010; 182 (2): 116–121
- [4] Friedrich C, Fajfar A, Pawlik M et al. Magnetic resonance enterography with and without biphasic contrast agent enema compared to conventional ileocolonoscopy in patients with Crohn’s disease. *Inflamm Bowel Dis* 2012; 18: 1842–1848. doi:10.1002/ibd.22843
- [5] Golder SK, Schreyer AG, Endlicher E et al. Comparison of capsule endoscopy and magnetic resonance (MR) enteroclysis in suspected small bowel disease. *Int J Colorectal Dis* 2006; 21: 97–104. doi:10.1007/s00384-005-0755-0
- [6] Jensen MD, Nathan T, Rafaelsen SR et al. Diagnostic accuracy of capsule endoscopy for small bowel Crohn’s disease is superior to that of MR enterography or CT enterography. *Clin Gastroenterol Hepatol* 2011; 9: 124–129. doi:10.1016/j.cgh.2010.10.019
- [7] Cansu A, Bekircavusoglu S, Oguz S et al. Can diffusion weighted imaging be used as an alternative to contrast-enhanced imaging on magnetic resonance enterography for the assessment of active inflammation in Crohn disease? *Medicine (Baltimore)* 2020; 99: e19202. doi:10.1097/MD.00000000000019202
- [8] Soydan L, Demir AA, Ozer S et al. Can MR Enterography and Diffusion-Weighted Imaging Predict Disease Activity Assessed by Simple Endoscopic Score for Crohn’s Disease? *J Belg Soc Radiol* 2019; 103: 10. doi:10.5334/jbsr.1521

- [9] Kim KJ, Lee Y, Park SH et al. Diffusion-weighted MR enterography for evaluating Crohn's disease: how does it add diagnostically to conventional MR enterography? *Inflamm Bowel Dis* 2015; 21: 101–109. doi:10.1097/MIB.0000000000000222
- [10] Stanescu-Siegmund N, Nimsch Y, Wunderlich AP et al. Quantification of inflammatory activity in patients with Crohn's disease using diffusion weighted imaging (DWI) in MR enteroclysis and MR enterography. *Acta Radiol* 2017; 58: 264–271. doi:10.1177/0284185116648503
- [11] Chatterji M, Fidler JL, Taylor SA et al. State of the Art MR Enterography Technique. *Top Magn Reson Imaging* 2021; 30: 3–11. doi:10.1097/RMR.0000000000000263
- [12] Kanda T, Fukusato T, Matsuda M et al. Gadolinium-based Contrast Agent Accumulates in the Brain Even in Subjects without Severe Renal Dysfunction: Evaluation of Autopsy Brain Specimens with Inductively Coupled Plasma Mass Spectroscopy. *Radiology* 2015; 276: 228–232. doi:10.1148/radiol.2015142690
- [13] Sardanelli F, Cozzi A, Trimboli RM et al. Gadolinium Retention and Breast MRI Screening: More Harm Than Good? *Am J Roentgenol* 2020; 214: 324–327. doi:10.2214/Am J Roentgenol.19.21988
- [14] Rimola J, Ordas I, Rodriguez S et al. Magnetic resonance imaging for evaluation of Crohn's disease: validation of parameters of severity and quantitative index of activity. *Inflamm Bowel Dis* 2011; 17: 1759–1768. doi:10.1002/ibd.21551
- [15] Seo N, Park SH, Kim KJ et al. MR Enterography for the Evaluation of Small-Bowel Inflammation in Crohn Disease by Using Diffusion-weighted Imaging without Intravenous Contrast Material: A Prospective Noninferiority Study. *Radiology* 2016; 278: 762–772. doi:10.1148/radiol.2015150809
- [16] University of California, Los Angeles/Kyung Sung. Im Internet (Stand: 28.12.2021): http://kyungs.bol.ucla.edu/software/DCE_tool/DCE_tool.html
- [17] Daperno M, D'Haens G, Van Assche G et al. Development and validation of a new, simplified endoscopic activity score for Crohn's disease: the SES-CD. *Gastrointest Endosc* 2004; 60: 505–512. doi:10.1016/s0016-5107(04)01878-4
- [18] Rimola J, Alvarez-Cofino A, Perez-Jeldres T et al. Comparison of three magnetic resonance enterography indices for grading activity in Crohn's disease. *J Gastroenterol* 2017; 52: 585–593. doi:10.1007/s00535-016-1253-6
- [19] Tielbeek JA, Makanyanga JC, Bipat S et al. Grading Crohn disease activity with MRI: interobserver variability of MRI features, MRI scoring of severity, and correlation with Crohn disease endoscopic index of severity. *Am J Roentgenol* 2013; 201: 1220–1228. doi:10.2214/Am J Roentgenol.12.10341
- [20] Minordi LM, Larosa L, Papa A et al. Assessment of Crohn's Disease Activity: Magnetic Resonance Enterography in Comparison with Clinical and Endoscopic Evaluations. *J Gastrointest Liver Dis* 2019; 28: 213–224. doi:10.15403/jgld-183
- [21] Lee JH, Park YE, Seo N et al. Magnetic resonance enterography predicts the prognosis of Crohn's disease. *Intest Res* 2018; 16: 445–457. doi:10.5217/ir.2018.16.3.445

ERRATUM

Erratum to Jakob M, Backes M, Schaefer C et al. MR Enterography in Crohn's Disease: Comparison of Contrast Imaging with Diffusion-weighted Imaging and a special Form of Color Coding. *Fortschr Röntgenstr* 2022; DOI 10.1055/a-1826-0049

The first sentence of the figure legend of figure 1 was changed on 27.09.2022. Correct: Contrast-enhanced image and parametric representation of the "area under the curve" with image subtraction.