

A Case Report of a Prenatally Missed Mowat-Wilson Syndrome With Isolated Corpus Callosum Agenesis

Nesrin Şenbil, MD¹, Zeynep Arslan, MD², Derya Beyza Sayın Kocakap, MD³, and Yasemin Bilgili, MD⁴

Abstract

Mowat–Wilson syndrome (MWS) is an autosomal dominant genetic disorder caused by *ZEB2* gene mutations, manifesting with unique facial characteristics, moderate to severe intellectual problems, and congenital malformations as Hirschsprung disease, genital and ophthalmological anomalies, and congenital cardiac anomalies. Herein, a case of 1-year-old boy with isolated agenesis of corpus callosum (IACC) in the prenatal period is presented. He was admitted postnatally with Hirschsprung disease (HSCR), hypertelorism, uplifted earlobes, deeply set eyes, frontal bossing, oval-shaped nasal tip, “M” shaped upper lip, opened mouth and prominent chin, and developmental delay. Hence, MWS was primarily considered and confirmed by the *ZEB2* gene mutation analysis. His karyotype was normal. He had a history of having a prenatally terminated brother with similar features. Antenatally detected IACC should prompt a detailed investigation including karyotype and microarray; even if they are normal then whole exome sequencing (WES) should be done.

Keywords

developmental delay, disability, fMRI, genetics, seizures

Received November 10, 2020. Received revised January 21, 2021. Accepted for publication February 26, 2021.

Mowat–Wilson syndrome (MWS; OMIM #235730) is an autosomal dominant disorder and manifests with a distinct facial appearance, moderate-to-severe intellectual disability (ID), motor retardation and epilepsy, and variable congenital malformations including HSCR, congenital heart defects, genitourinary anomalies, eye defects, and functional and structural central nervous system defects.¹ MWS is characterized by heterozygous mutations or deletions of the zinc finger E-box-binding homeobox 2 (*ZEB2*) gene located on chromosome 2q22.3.² To date, more than 300 individuals and 170 pathogenic *ZEB2* mutations have been described, most of which are de novo large deletions or mutations leading to premature stop codons affecting protein function.³

We report a 1-year-old boy with IACC in the prenatal period. He presented postnatally with HSCR, facial dysmorphism, and developmental delay. Thus, MWS was suspected and later confirmed by a *ZEB2* gene mutation analysis.

Case

The patient was born with C/S at 38 weeks of gestation with a birth weight of 3820 g; was the 3rd alive child of a 35-year-old

mother in her 4th pregnancy. His mother’s second pregnancy was a male with agenesis of corpus callosum (ACC), congenital heart disease and absence of nasal bone which were detected on ultrasound at 24th week. The pregnancy had been terminated without genetic tests or autopsy. The patient’s antenatal ultrasonographic investigation showed an IACC at 18 weeks of gestation but fetal MRI was not performed and amniocentesis revealed 46, XY karyotype. He had not defecated for the first

¹ Department of pediatric neurology, Kırıkkale University Faculty of Medicine, Kırıkkale, Turkey

² Department of pediatrics, Kırıkkale University Faculty of Medicine, Kırıkkale, Turkey

³ Department of Genetics, Kırıkkale University Faculty of Medicine, Kırıkkale, Turkey

⁴ Department of Radiology, Kırıkkale University Faculty of Medicine, Kırıkkale, Turkey

Corresponding Author:

Zeynep Arslan, Department of Pediatrics, Kırıkkale University Faculty of Medicine Hospital, Kırıkkale 71100, Turkey.

Email: zarlan697@gmail.com



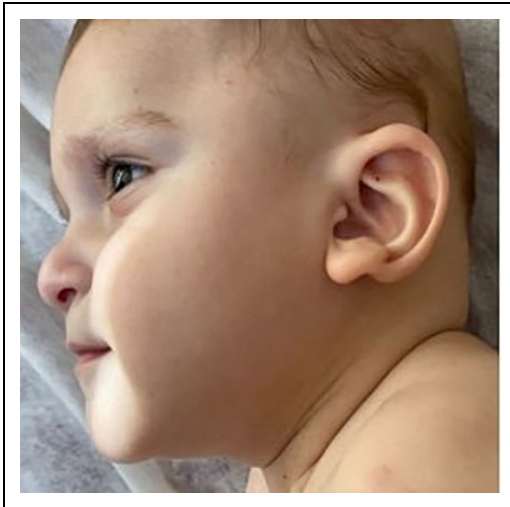


Figure 1. Ears had uplifted lobes with a central depression, frontal bossing, short neck.

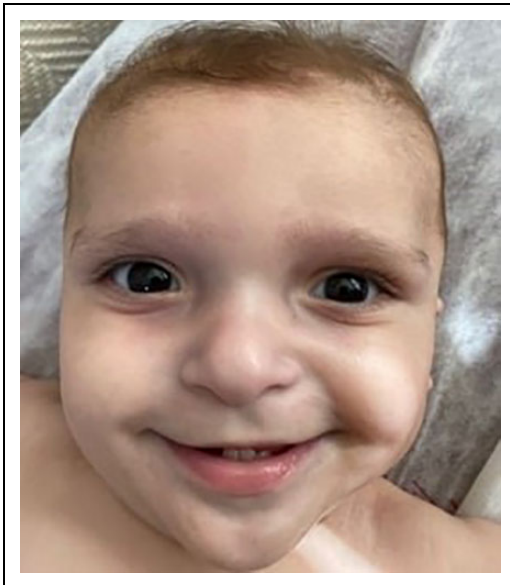


Figure 2. Hypertelorism, telecanthus, deep-set eyes, infraorbital fold, long lashes, broad eyebrows with a medial flare, a wide nasal bridge with prominent and rounded nasal tip, low-hanging columella, open-mouthed smiling expression, thin upper lip, prominent chin.

three days of life; he defecated a large amount of stool after rectal stimulation. The patient underwent laparotomy for intestinal biopsies and diagnosed with HSCR and ileostomy was opened.

He presented to our clinic when he was one year old with fever for two days. His weight was 8.4 kg (3 rd percentile); height 74 cm (3 rd percentile); and head circumference 46 cm (25th percentile). Hypertelorism, uplifted earlobes with a central depression, frontal bossing, telecanthus, deeply set eyes, infraorbital fold, long lashes, broad eyebrows with a medial flare, a wide nasal bridge with prominent and rounded nasal tip, low-hanging columella, open-mouth expression, thin “M”

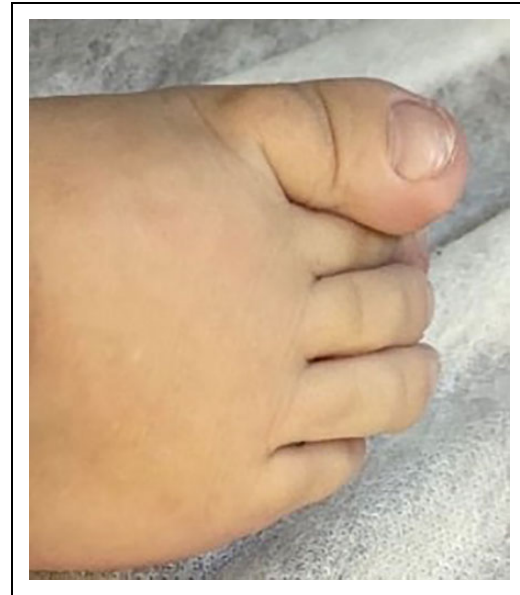


Figure 3. Overlapping toes.

shaped upper lip, prominent chin, short neck, wide-spaced nipples, overlapping toes, and pes planus were noted (Figure 1–3). Abdominal examination showed no guarding or rebound tenderness; he had orange-colored liquid stool in an ileostomy bag. He had eye contact, social smile, and stereotypic hand movements, speaking indistinguishable three words. Traction response was poor, and he was hypotonic on vertical suspension. He could not sit unassisted. Deep tendon reflexes were normal; bilaterally plantar reflexes were extensor; sustained Achilles clonus was noted. At admission, urinalysis showed pyuria. Acute pyelonephritis was diagnosed. Urinary ultrasound and voiding cystourethrogram showed grade 3 hydronephrosis affecting the right ureter. Cranial magnetic resonance imaging (MRI) demonstrated enlargement of the third and lateral ventricles, the occipital and temporal horns. There was a bilateral incomplete hippocampal inversion, enlargement of thalamus, nucleus caudate, and ACC (Figure 4–6). A heterozygous “class 2” c.646dupT (p.Cys216LeufsTer23) mutation on exon 6 of ZEB2 (zinc finger E-box binding homeobox 2) gene was detected by a mutation surveyor program, and the diagnosis of MWS was made. At 16 months, he presented with fever due to pneumonia and generalized seizure for 5 minutes. His EEG showed no epileptic discharge but an immature parietooccipital rhythm for his age. Valproic acid was initiated. The patient is still on follow-up for developmental delay, renal, and gastrointestinal problems.

Discussion

Facial dysmorphism, ACC, HSCR, and neuromotor developmental delay hinted to the diagnosis of MWS which was confirmed by mutation analysis. Facial features as hypertelorism, uplifted earlobes, deeply set eyes, frontal bossing, oval-shaped nasal tip, “M” shaped upper lip, opened mouth,

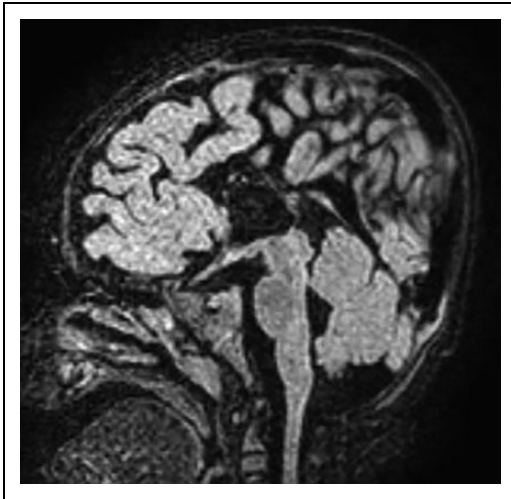


Figure 4. Complete agenesis of the corpus callosum on sagittal T2 weighted 3D images.

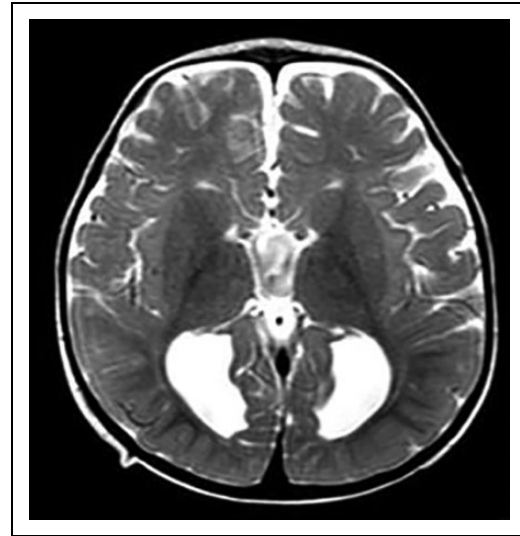


Figure 6. Enlargement of occipital horns on an axial T2 weighted image.

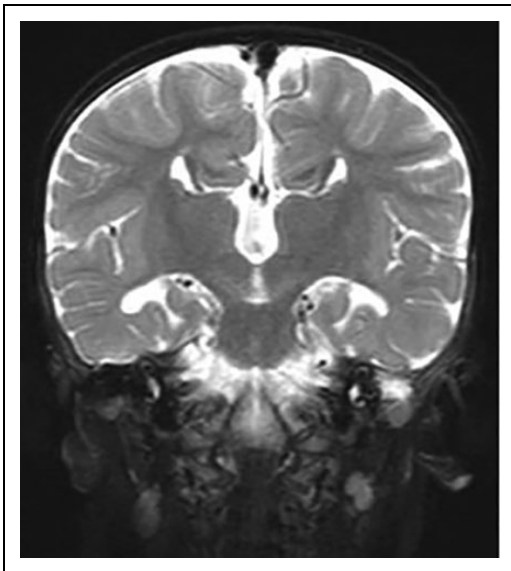


Figure 5. Bilateral incomplete hippocampal inversion on a coronal T2 weighted image.

and prominent chin were concordant with previous descriptions. A child with developmental delay, atypical facial features (uplifted earlobes, rounded nasal tip, prominent columella, medially broad eyebrows, prominent chin, an open-mouthed smiling expression), cardiac or genitourinary anomalies, and febrile seizures should prompt investigations for MWS.⁴⁻⁶ All patients reported to date have had moderate to severe mental retardation, with ethnicity influencing the phenotype.³ Our case had global developmental delay, prominent motor retardation, and febrile seizures. Urogenital abnormalities and HSCR have been reported in 61.25% and 30.6% of patients, respectively.⁴ The most common neuro-radiological phenotypes are corpus callosum (79.6%) and the hippocampal abnormalities (77.8%).⁷

Our patient was diagnosed with IACC by prenatal ultrasonography. HSCR was not detected as intestinal biopsy was not performed. If fetal MRI had been performed, other cranial anomalies-hippocampal abnormality- might have been detected and that further genetic workup might have been done.

ACC may be related to multiple diseases and affect fetal prognosis. Palmer and Mowat indicated in their review that 20-35% of the ACC have an identifiable monogenic cause. They subdivided genetic syndromes with ACC in 6 groups: syndromes with craniofacial dysmorphism (including MWS), with neuroanatomical/neurological features, with prominent ocular phenotype, metabolic conditions, ciliopathy spectrum conditions and other.⁸ A study which prospectively evaluated IACC patients showed that 65% of patients had normal school intelligence level, 29% had mild learning disabilities and 6% had severe intellectual disability. One of the two patients from severe intellectual disability group was diagnosed as MWS.⁹ A meta-analysis on postnatal outcomes of antenatally detected IACC showed that 4.8% of patients had chromosomal anomalies, 4.4% motor retardation, 10.9% epilepsy, and 15.1% cognitive retardation.¹⁰

Identifying the underlying cause of ACC is essential for appropriate management and genetic counseling. Even if the standard karyotype is normal, aCGH may detect a genetic abnormality. Antenatal imaging is most of the time not enough to distinguish other possible anomalies, and it will not be possible to ascertain that if ACC is truly isolated or not using imaging alone.¹⁰ Therefore, while consulting a patient, prenatal aCGH should be offered; if the latter results normal, WES should be considered.¹¹ Gosso et al.¹² suggested that WES is the first line diagnosis for MWS compared to traditional genetic tests.

In our case, a mutation analysis revealed a heterozygote c.646dupT (p. Cys216LeufsTer23) change in the ZEB2 gene. To our knowledge, this change has not been reported previously

and is considered to be novel. c.646dupT(p.Cys216LeufsTer23) mutation is in the zinc finger C2H2 -1 domain of the ZEB2 gene (<https://www.uniprot.org/uniprot/O60315>). As the C2H2 motif is critical for transcription factors to bind DNA, we can hypothesize that this mutation disrupts many DNA-DNA interactions and cause gene expression changes causing MWS. The largest cohort of MWS with 87 cases of molecularly confirmed MWS was reported by Ivanovski et al. They attempted to build a genotype-phenotype correlation, but only a few clinical features (such as medial flaring, broad nasal bridge, open mouth, etc.) showed differences between full- gene deletion and absence of protein/defective protein groups. Also, they noted that more heart defects were observed in patients with complete gene deletion.⁶

It is difficult to establish a genotype-phenotype correlation in MWS due to the limited number of cases and the lack of functional data. Alleles carrying ZEB2 intragenic mutations produce transcripts undergoing non-sense mediated mRNA decay or short and nonfunctional transcripts. It is considered that mutations disrupting protein function have a greater impact on phenotype. Patients with nonsense mutations in the ZEB2 gene have been described with milder features of MWS; similarly, in Ivanovski's cohort, the least severely affected patients had mutations that disrupt only a small portion of the protein.

In conclusion, when IACC is detected on antenatal ultrasound, further investigations should be considered; fetal MRI should be performed, and even if karyotype and microarray results are normal, WES should be kept in mind. Prenatal diagnosis of MWS recurrence is strongly suggested by abnormal ultrasound findings such as ACC, but mutation analysis is necessary for confirmation. This stresses the importance of molecular confirmation of MWS in probands when parents consider having more children and wish to receive an accurate prenatal diagnosis.

Declaration of Conflicting Interests

The author(s) declared no potential conflicts of interest with respect to the research, authorship, and/or publication of this article.

Funding

The author(s) received no financial support for the research, authorship, and/or publication of this article.

Ethical Approval

No ethical committee approval was necessary for this case report.

References

1. Mowat DR, Croaker GD, Cass DT, et al. Hirschsprung disease, microcephaly, mental retardation, and characteristic facial features: delineation of a new syndrome and identification of a locus at chromosome 2q22-q23. *J Med Genet.* 1998;35(8): 617-623.
2. Zweier C, Albrecht B, Mitulla B, et al. "Mowat-Wilson" syndrome with and without Hirschsprung disease is a distinct, recognizable multiple congenital anomalies-mental retardation syndrome caused by mutations in the zinc finger homeo box 1B gene. *Am J Med Genet.* 2002;108(3):177-181.
3. Ho S, Luk HM, Chung BH, Fung JL, Mak HH, Lo IF. Mowat-Wilson syndrome in a Chinese population: a case series. *Am J Med Genet A.* 2020;182(6):1336-1341.
4. Ivanovski I, Djuric O, Caraffi SG, et al. Phenotype and genotype of 87 patients with Mowat-Wilson syndrome and recommendations for care. *Genet Med.* 2018;20(9):965-975.
5. Garavelli L, Zollino M, Mainardi PC, et al. Mowat-Wilson syndrome: facial phenotype changing with age: study of 19 Italian patients and review of the literature. *Am J Med Genet A.* 2009; 149(3):417-426.
6. Seo SE, Kim SH, Lee ST, et al. Mowat-Wilson syndrome presenting with fever-associated seizures. *Epileptic Disord.* 2017; 19(4):481-485.
7. Garavelli L, Ivanovski I, Caraffi SG, et al. Neuroimaging findings in Mowat-Wilson syndrome: a study of 54 patients. *Genet Med.* 2017;19(6):691-700.
8. Palmer EE, Mowat D. Agenesis of the corpus callosum: a clinical approach to diagnosis. *Am J Med Genet C Semin Med Genet.* 2014;166C(2):184-197.
9. Des Portes V, Rolland A, Velazquez-Dominguez J, et al. "Outcome of isolated agenesis of the corpus callosum: A population-based prospective study." *Eur J Paediatr Neurol.* 2018;22(1):82-92.
10. D'Antonio F, Pagani G, Familiari A, et al. Outcomes associated with isolated agenesis of the corpus callosum: a meta-analysis. *Pediatrics.* 2016;138(3):e20160445.
11. De Wit MC, Boekhorst F, Mancini GM, et al. Advanced genomic testing may aid in counseling of isolated agenesis of the corpus callosum on prenatal ultrasound. *Prenat Diagn.* 2017;37(12): 1191-1197.
12. Gosso MF, Rohr C, Brun B, et al. Exome-first approach identified novel INDELs and gene deletions in Mowat-Wilson Syndrome patients. *Hum Genome Var.* 2018;5:21.