



# A randomized controlled experimental study comparing chitosan coated polypropylene mesh and Proceed™ mesh for abdominal wall defect closure



S.T. Jayanth<sup>a,\*,1</sup>, Anna Pulimood<sup>b</sup>, Deepak Abraham<sup>d</sup>, A. Rajaram<sup>c</sup>, M.J. Paul<sup>d</sup>, Aravindan Nair<sup>d</sup>

<sup>a</sup> Department of General Surgery, Christian Medical College, Vellore, India

<sup>b</sup> Department of Pathology, Christian Medical College, Vellore, India

<sup>c</sup> Department of Biophysics, Central Leather Research Institute, Chennai, India

<sup>d</sup> Department of Endocrine Surgery, Christian Medical College, Vellore, India

## HIGHLIGHTS

- Effective abdominal wall defect closure was achieved with minimal morbidity.
- Chitosan was found to be effective in reducing post surgical adhesions.
- Its efficacy was better at four weeks than at twelve weeks.
- It was found to be of equivalent potency when compared to the Proceed™ mesh.
- Currently available coating materials can reduce early adhesions, but not late adhesions.

## ARTICLE INFO

### Article history:

Received 29 March 2015

Received in revised form

15 September 2015

Accepted 1 October 2015

### Keywords:

Experimental study  
Abdominal wall defect  
Chitosan  
Adhesions

## ABSTRACT

**Background:** Abdominal wall defects and hernias are commonly repaired with synthetic or biological materials. Adhesions and recurrences are a common problem. A study was conducted to compare Chitosan coated polypropylene mesh and a polypropylene–polydioxanone composite with oxidized cellulose coating mesh (Proceed™) in repair of abdominal wall defect in a Rabbit hernia model.

**Methods:** A randomized controlled experimental study was done on twelve New Zealand white rabbits. A ventral abdominal defect was created in each of the rabbits. The rabbits were divided into two groups. In one group the defect was repaired with Chitosan coated polypropylene mesh and Proceed mesh™ in the other. The rabbits were operated in two phases. They were followed up at four weeks and twelve weeks respectively after which the rabbits were sacrificed. They were evaluated by open exploration and histopathological examination. Their efficacy in reducing adhesion and ability of remodeling and tissue integration were studied.

**Results:** There was no statistical significance in the area of adhesion, the force required to remove the adhesions, tissue integration and remodeling between Chitosan and Proceed™ group. Histological analysis revealed that the inflammatory response, fibrosis, material degradation and remodeling were similar in both the groups. There were no hernias, wound infection or dehiscence in any of the studied animals.

**Conclusion:** Chitosan coated polypropylene mesh was found to have similar efficacy to Proceed™ mesh. Chitosan coated polypropylene mesh, can act as an anti adhesive barrier when used in the repair of incisional hernias and abdominal wall defects.

© 2015 Published by Elsevier Ltd on behalf of IJS Publishing Group Limited. This is an open access article under the CC BY-NC-ND license (<http://creativecommons.org/licenses/by-nc-nd/4.0/>).

## 1. Introduction

Incisional hernias can occur after abdominal surgery and can cause serious complications. The use of prosthetic mesh in incisional hernia repair is the accepted current practice [1–3]. The

\* Corresponding author. Department of General Surgery, Christian Medical College, Vellore, TamilNadu, 632004, India.

E-mail address: [stjayanth2704@gmail.com](mailto:stjayanth2704@gmail.com) (S.T. Jayanth).

<sup>1</sup> The corresponding author is not a recipient of a research scholarship.

meshes are placed either extraperitoneally or intraperitoneally. Repair of the abdominal wall is done using autologous tissue (fascia grafts or tissue flaps), synthetic materials such as polypropylene mesh or biological materials such as human acellular dermal matrix (HADM) [4].

The complications associated with intraperitoneal mesh repair include adhesions and seroma formation. The areas of adhesion are at the sutures, mesh margins or tacks used in laparoscopic hernia repair [2,3,5,6]. Different materials have been used to prevent adhesions. They include coated meshes, composite meshes and anti adhesive barriers. A good composite mesh would combine excellent parietal surface tissue in-growth with minimal visceral surface adhesiveness [5,7]. The currently available composite meshes (Parietex composite™(Covidien), Composix™(Bard), Proceed™(Ethicon)) claim to possess these characteristics, but are very expensive in the Indian scenario.

Chitosan, a partially deacetylated form of chitin (obtained from sea shells) has been found to reduce adhesions and is of interest as a novel biomaterial coating [4,8,9]. It is hypothesized that coating the polypropylene mesh with Chitosan will reduce the adhesions and help in tissue remodeling while the Polypropylene component will allow tissue in-growth and contribute to the tensile strength. This forms the basis for the present study. It is already well known that polypropylene mesh produces severe adhesions [9–12] when placed intraperitoneally and hence not used separately as a control.

## 2. METHODS

A randomized, controlled experimental study was done on twelve New Zealand white rabbits. The approval was obtained from the Institutional review board and the animal ethics committee of our institution. The Rabbits were divided into two study groups by simple randomization technique by the principal investigator (by picking a sealed envelope which contained a label as group 1 or group 2) and were allotted to the following groups.

1. Polypropylene–polydioxanone composite with oxidized cellulose coating

(Proceed mesh™–Ethicon).

2. Chitosan coated Polypropylene mesh

### 2.1. Preparation of chitosan coated polypropylene mesh

Chitosan is prepared by the deacetylation of chitin which is obtained from sea shells. A 1% solution of chitosan was made in 10% acetic acid. This solution was filtered with polyester chitin to remove impurities and centrifuged at 5000 rpm to remove smaller particles. The supernatant was used to coat the polypropylene mesh. The obtained mesh was sterilized with gamma irradiation.

### 2.2. Experimental procedure

Feeding was withheld 12 h before the procedure. Intramuscular ketamine (35 mg/kg) and Xylazine (5 mg/kg) were used as inducing agents and the anesthesia was maintained with Intramuscular ketamine. A 2.5 × 2.5 cm defect was created by excising a portion of the rectus after incising the abdominal wall. The defect was closed with a 5 × 5 cm piece of either Proceed™ mesh, or Chitosan coated polypropylene mesh. The subcutaneous tissue was closed with 3–0 Vicryl suture. The skin incision was closed with subcuticular sutures using 3–0 monocryl. The Rabbits received Enrofloxacin and Meloxicam 0.5 mg/kg for five days postoperatively. Regular

evaluation of the rabbit's condition was done by the investigator assisted by the animal house keeper who was unaware of the randomization.

An overdose of Ketamine 100 mg/kg was given and following which the rabbits were sacrificed. Three animals in each group were sacrificed and examined at 4 weeks. The remaining animals were sacrificed and examined at 12 weeks. The abdominal wall was excised using a U-shaped incision well away from the mesh repair.

## I Macroscopic evaluation

Macroscopic scoring of adhesion formation and tissue integration was carried out.

The findings were recorded by an investigator who was unaware of the randomization.

### 1) Assessment of Adhesions:

Adhesions were assessed qualitatively and semiquantitatively by the adhesion scoring and the modified diamond scale used in prior experimental studies [7]. Photographs were taken, and the type, amount and extent of adhesions were scored in a blinded fashion by independent observers.

- a. Adhesion grading by resistance to lysis (Refer Table 1).

The strength of the adhesions was evaluated by its resistance to removal by using the following scoring system.

- b. Assessment of area of adhesion coverage on the mesh surface:

The adhesion coverage area was quantified by assigning a percentage to the area occupied by adhesions per unit total visible implant area. After describing the adhesions in vivo, the abdominal wall was completely excised and the areas of mesh that were free of adhesions were marked with red ink. All adhesions were then excised sharply, resulting in a topographic map, with uninvolved mesh being marked with red ink and the involved areas being left unmarked. Each specimen was photographed with a digital camera, and the resulting images were analyzed by an independent and blinded observer. Adhesions to the prosthetic mesh were scored for extent (%) using the Modified Diamond Scale [7]. (Refer Table 2).

### 2) Tissue integration

In growth of the mesh into the abdominal wall was analyzed by whether a back end forceps can be inserted between the mesh and the abdominal wall as done in a previous experimental study [12]. Tissue in growth was scored as A (Integration of more than 70% of mesh surface), B (Integration of 50–70% of the mesh surface area) and C (Integration of less than 50% of the mesh surface area).

## II Histological analysis

Every specimen was evaluated by a pathologist who was blinded to the sample. It was fixed in a 10% buffered formaldehyde solution. After routine tissue processing, 5-mm sections were cut and stained with hematoxylin and eosin. Sections were studied with light microscopy. Lymphocytic infiltration, polymorphonuclear leukocyte infiltration, giant cells, capillary proliferation, and fibroblast proliferation were evaluated semi quantitatively, as negative (–) or positive (+), (++) , (+++). The parameters evaluated were: Inflammation, fibrosis, Material degradation, and remodeling.

Remodeling was characterized as:

**Table 1**  
Adhesion scoring.

Adhesion score	Characteristics
0	<b>Without adhesions</b>
1	<b>Flimsy adhesions:</b> Easily removed with blunt dissection and results in limited bleeding
2	<b>Intermediate adhesions:</b> removed with more aggressive blunt dissection or little sharp dissection, results in moderate bleeding and good plane of dissection present
3	<b>Firm adhesions:</b> Removed only with sharp dissection, bleeds heavily and no plane of dissection present.

**Table 2**  
Modified diamond scale.

Grade	Adhesion
0	0%
1	1–25%
2	25–50%
3	50–75%
4	>75%

**Table 3**  
Adhesion grading.

Chitosan group	Score
C1	2
C2	1
C3	1
C4	3
C5	1
C6	2
Proceed group	Score
P1	1
P2	2
P3	1
P4	1
P5	3
P6	1

- Unremodeled – if no degradation of the implant or cell infiltration occurred;
- Partially remodeled – if some degradation of the implant and deposition of new extracellular matrix occurred
- Fully remodeled – if there were no signs of the implant and only freshly deposited new extracellular matrix and cells were present.

### 2.3. Statistical analyses

All baseline variables were summarized using descriptive statistical methods. Mann–Whitney U test was used to analyze differences in adhesion grading, tissue integration and histological analysis. Fisher's exact test was used to analyze difference in percentage of mesh covered with adhesions. A  $p$  value  $<0.05$  was considered to be statistically significant.

## 3. RESULTS

### I. Macroscopic analysis

#### 1) Assessment of adhesions

Four weeks after the repair the gross appearances of hernia defects were compared. Mesh repair sites in both the groups were intact but had adhesions involving the omentum, bowel and liver. (Refer Fig. 1).

At the end of 12 weeks, both the chitosan coated polypropylene mesh and Proceed mesh repair sites showed visible implant with minimal degradation and remodeling. But the meshes were well integrated into the tissues.

#### a. Adhesion grading by resistance to lysis

When the two groups were compared for resistance to lysis of the adhesions there was no significant difference between chitosan coated polypropylene mesh and the Proceed™ mesh (Grade 1 and grade 3),  $P$  value – 0.99 and 0.65. (Refer Table 3).

#### b. The area of adhesions coverage on the mesh surface

Chitosan coated polypropylene mesh resulted in greater adhesion coverage area compared with Proceed mesh, but was not

statistically significant (Median percentage area of mesh (% PAM) covered with adhesions was 18% Vs 10%).  $P$  value – 0.08 (Fisher's exact test) (Refer Fig. 2, Tables 4 and 5).

#### 2) Tissue integration

The tissue integration appeared to be better in the Proceed group than in the Chitosan group though it was not statistically significant ( $p = 0.12$ ) (Refer Tables 6 and 7).

### II. Histological analysis

There was no statistically significant difference between any of the histopathological parameters of the two groups. The markers of inflammation (PMNL, LI/PS, CP, GC) and fibrosis (AF, COLLAGEN) were compared between the two groups and there was no statistically significant difference between them ( $p = 0.62$  and  $0.80$ ) (Refer to Figs. 3 and 4, Tables 8 and 9). There was partial remodeling and mesh degradation in all the rabbits under the study. All the histological sections revealed persistence of the implant fibers with surrounding fibrosis and minimal degradation of the fibers.

## 4. Complications

The skin healing in both the groups were excellent and there were no complications of wound infection, dehiscence or hernia at the end of twelve weeks. Six out of the twelve animals (two in the Chitosan group and four in the proceed group) developed pressure sores over the bony prominences of the limbs that were in constant contact with the metallic cage.

## 5. Discussion

Various materials have been added to polypropylene (composite meshes) to minimize its primary shortcoming of visceral adhesions. The study addressed the short-term reduction of adhesions and remodeling of a new biomaterial (Chitosan).

In this study, the investigator compared the barrier effects of

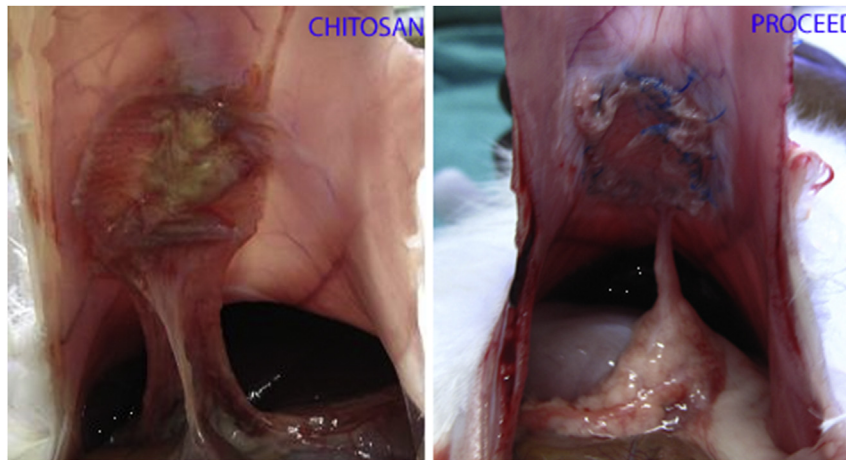


Fig. 1. Omental adhesions in the Chitosan and Proceed group.

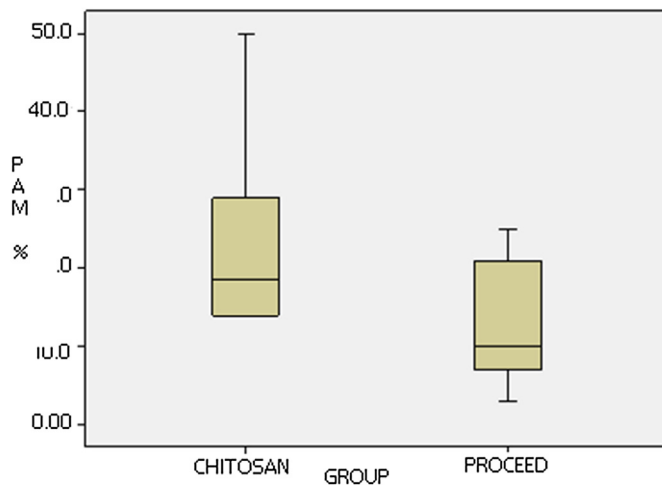


Fig. 2. Box plot showing percentage adhesion coverage of the mesh surface (PAM) in the Chitosan group and the Proceed group.

Table 4  
Area of adhesions – Chitosan group.

Rabbit no:	Area of adhesions	Score
C1	15%	1
C2	29%	2
C3	14%	1
C4	50.3%	3
C5	13.75%	1
C6	22%	1

Proceed™ mesh (Ethicon) and Chitosan coated Polypropylene mesh in experimentally created abdominal defect in rabbits. None of the rabbits in both groups were adhesion free.

At 4 weeks and 12 weeks the Proceed mesh and Chitosan coated Polypropylene mesh reduced the extent of adhesions. Majority of the adhesions were only omental. There was one rabbit in each group with dense adhesions involving the bowel. The median surface area involved by adhesions was greater in the Chitosan group compared to the Proceed group but this association was not statistically significant (p value – 0.08).

It was observed that in the Chitosan group, at 12 weeks the

Table 5  
Area of adhesions – Proceed group.

Rabbit no:	Area of adhesions	Score
P1	12%	1
P2	25%	1
P3	21%	1
P4	2.5%	1
P5	7.1%	1
P6	8.2%	1

rabbits had more dense adhesions and involved a larger surface area of the mesh when compared to the rabbits at 4 weeks. This could be attributed to the fact that the thin film of Chitosan that was coated on the mesh was absorbed and at 12 weeks more adhesions were formed. In terms of grading of adhesions there was no significant difference between the groups (p value – 0.65).

Chitosan acts as an anti-adhesive barrier and its efficacy in reducing intra-abdominal adhesions has been scarcely studied [4]. Paulo et al. [9] studied the barrier effect of Chitosan films associated with polypropylene meshes on adhesion formation experimentally induced in Wistar rats. They demonstrated a decrease in adhesions when Chitosan films were sutured over polypropylene meshes as compared to polypropylene meshes alone.

An experimental study by Thomas et al. [13] compared Chitosan coated polypropylene mesh with plain polypropylene mesh in incisionally created ventral hernia in rats. At a follow up of 12 weeks there were significantly fewer adhesions in the Chitosan coated mesh group when compared to the plain polypropylene mesh. But the mesh was extruded in all the rats. The reason attributed was the non-porous nature of the mesh. This study is done to overcome the problems of this mesh by making it porous and also by coating the individual fibers.

A study was conducted to investigate the feasibility of using silk fibroin and Chitosan blend (SFCS) scaffolds for ventral hernia repair in guinea pigs [4]. The investigator compared SFCS with biodegradable human acellular dermal matrix (HADM) and non-biodegradable polypropylene mesh by implanting each to repair an incisionally created ventral hernia in the abdominal wall using an inlay technique. At 4 weeks, both HADM and SFCS underwent remodeling by host tissue, but polypropylene mesh resulted in extensive bowel adhesions and scarring.

In a recent publication on coated meshes, Schreinemacher and colleagues [14] concluded that absorbable layers on the surface of

**Table 6**  
Chitosan group.

Rabbit no:	Tissue integration
C1	A
C2	B
C3	B
C4	A
C5	C
C6	B

**Table 7**  
Proceed™ group.

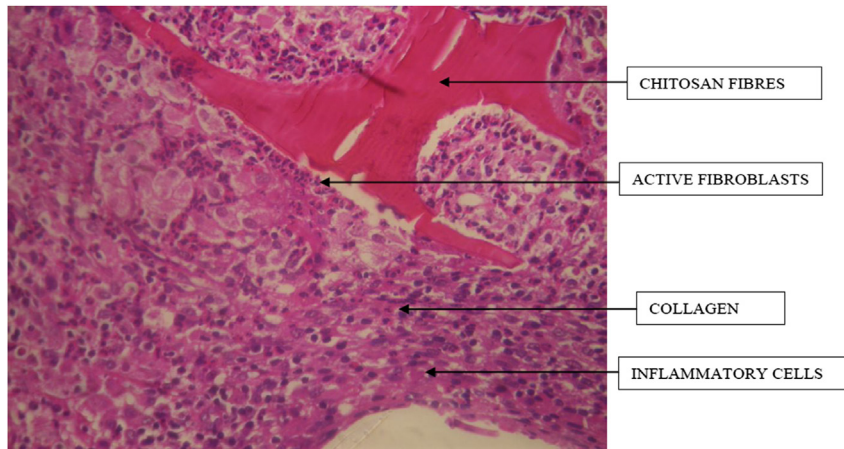
Rabbit no:	Tissue integration
P1	B
P2	A
P3	A
P4	B
P5	A
P6	A

deposition and remodeling of new extracellular matrix, and regeneration of the tissue with a gross appearance similar to that of the native abdominal wall musculofascia.

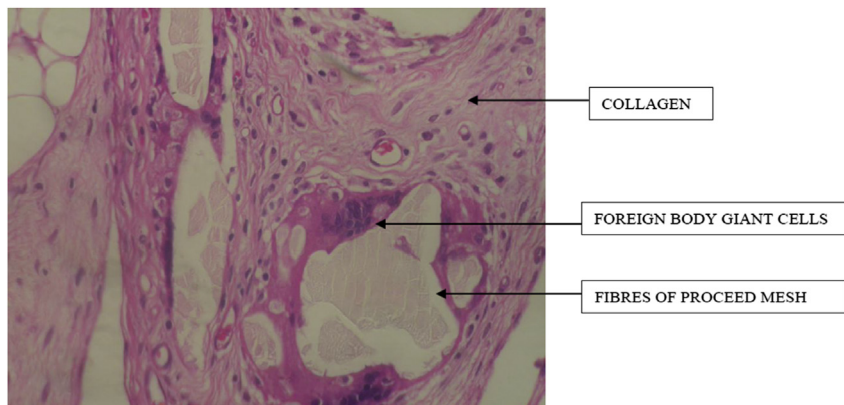
In both the groups the mesh was reasonably well integrated into the host tissue. There was partial remodeling of the mesh in all the animals studied. Despite the success of integration in small animals, clinical translation into humans will require further long-term studies. The skin healing in both the groups were excellent and there were no complications of wound infection, dehiscence or hernia at the end of 12 weeks.

## 6. Conclusions

Effective abdominal wall defect closures were achieved in rabbits with minimal peri-operative morbidity, no clinical implant infection, and no early recurrences. Chitosan was found to be effective in reducing post surgical adhesions. Its efficacy was better at four weeks than at twelve weeks. When compared with the Proceed™ mesh there was no statistical significance in the area of



**Fig. 3.** High magnification view of histologic section of musculofascial – implant (chitosan) interface showing chitosan fibres with surrounding inflammatory cells.



**Fig. 4.** High magnification view of histologic cross-section examination of musculofascial – implant interface showing Proceed™ mesh fibers with surrounding inflammatory cells.

the mesh were able to prevent adhesion formation at 7 days, but its effect is diminished at 30 days and adhesions to the mesh were substantial.

Both the Chitosan and the Proceed™ mesh supported good cellular infiltration, vascularization, scaffold biodegradation,

adhesion, force required to remove the adhesions, tissue integration and remodeling. Histological analysis revealed that the inflammatory response, fibrosis, material degradation and remodeling were similar in both the groups. Chitosan coated polypropylene mesh was found to be comparable to the Proceed™

**Table 8**  
Histological analysis – Chitosan group.

Rabbit no:	PMNL	FB	AF	CP	GC	LI/PS	Collagen/Fibrosis	Material degradation	Remodeling
C1	0	1+	1+	0	0	0	2+	–	Partial
C2	2+	3+	3+	2+	1+	3+	2+	+	Partial
C3	0	0	1+	1+	0	0	2+	NA	Partial
C4	0	1+	1+	3+	1+	1+	2+	NA	Partial
C5	3+	2+	1+	1+	1+	3+	3+	+	Partial
C6	1+	1+	3+	2+	0	1+	3+	+	Partial

**Table 9**  
Histological analysis – Proceed group.

Rabbit no:	PMNL	FB	AF	CP	GC	LI/PS	Collagen/Fibrosis	Material degradation	Remodeling
P1	0	3+	2+	1+	3+	1+	3+	+	Partial
P2	1+	1+	2+	1+	1+	1+	3+	+	Partial
P3	1+	2+	2+	3+	2+	2+	2+	+	Partial
P4	0	0	0	2+	0	0	1+	NA	Partial
P5	0	2+	1+	1+	1+	1+	2+	+	Partial
P6	2+	2+	3+	3+	2+	2+	3+	+	Partial

PMNL = polymorphonuclear leukocytes; FB = Foreign body reaction, AF + Active fibroblasts, CP = Capillary proliferation, GC = giant cell; LI/PS = lymphocyte infiltration/Plasma cells.

mesh in the outcomes assessed. However this is not confirmatory. This has to be interpreted with caution due to the small sample size. The result also reinforces the fact that currently available coating materials can reduce early adhesions, but not late adhesions. Modification of the chitosan coating and finding other innovative ways to help reduce late adhesions is a challenge. This can reduce operative complications due to adhesions significantly. Chitosan is an economic and potential alternative to the expensive composite meshes, especially in developing countries. This study

IRB approval No: 13/2009.

#### Sources of funding

Nil.

#### Author contribution

Responsibilities									
Author(s) name	Research and study design	Data collection & analysis	Laboratory analysis	Interpretation and conclusion	Preparation of manuscript	Review of manuscript	Guide and critical revision	Administration	Technical Support
Jayanth ST	Yes	Yes	–	Yes	Yes	–	–	–	–
Pulimood A	–	–	Yes	Yes	–	Yes	–	–	Yes
Rajaram A	Yes	–	–	–	–	–	–	–	Yes
Paul M J	–	–	–	Yes	–	Yes	Yes	Yes	Yes
Nair A	Yes	–	–	Yes	Yes	Yes	Yes	Yes	Yes

has given the authors encouraging results and the impetus to continue research in this field. Further long term studies are required to address the problem of late adhesions to lend credibility to the claims of chitosan coated meshes in reducing visceral adhesions.

#### Disclosure

STJ declares no conflict of interest. The other co-authors AP, AR, DA, MJP and AN declare no conflict of interest directly or indirectly related to the work. There was no grant or travel support from any external sources.

#### Ethical approval

The approval to conduct the study was obtained by the Institutional review board and ethics committee.

#### Conflicts of interest

No.

#### Guarantor

1. Aravindan Nair, MS, DNB, MNAMS, Professor, Department of Endocrine surgery, CMC Hospital, Vellore.

2. M J Paul, MS, Professor, Department of Endocrine surgery, CMC Hospital, Vellore.

#### Acknowledgements

The authors would like to thank the staff of the Central animal facility at our institution, for housing the rabbits and providing the resources to conduct the experiment. We are grateful to Mr. P of the biostatistics department for the statistical help offered.

## References

- [1] M. Moore, T. Bax, M. MacFarlane, M.S. McNevin, Outcomes of the fascial component separation technique with synthetic mesh reinforcement for repair of complex ventral incisional hernias in the morbidly obese, *Am. J. Surg.* 195 (5) (2008 May) 575–579 discussion 579.
- [2] R. Penttinen, J.M. Grönroos, Mesh repair of common abdominal hernias: a review on experimental and clinical studies, *Hernia* 12 (4) (2008 Aug) 337–344.
- [3] K. Cassar, A. Munro, Surgical treatment of incisional hernia, *Br. J. Surg.* 89 (5) (2002 May) 534–545.
- [4] A.S. Gobin, C.E. Butler, A.B. Mathur, Repair and regeneration of the abdominal wall musculofascial defect using silk fibroin-chitosan blend, *Tissue Eng.* 12 (12) (2006 Dec) 3383–3394.
- [5] A.N. Kingsnorth, M.K. Shahid, A.J. Valliattu, R.A. Hadden, C.S. Porter, Open onlay mesh repair for major abdominal wall hernias with selective use of components separation and fibrin sealant, *World J. Surg.* 32 (1) (2008 Jan) 26–30.
- [6] J. Lipman, D. Medalie, M.J. Rosen, Staged repair of massive incisional hernias with loss of abdominal domain: a novel approach, *Am. J. Surg.* 195 (1) (2008 Jan) 84–88.
- [7] B.P. Jacob, N.J. Hogle, E. Durak, T. Kim, D.L. Fowler, Tissue ingrowth and bowel adhesion formation in an animal comparative study: polypropylene versus proceed versus parietex composite, *Surg. Endosc.* 21 (4) (2007 Apr) 629–633.
- [8] L.R.D. Daroz, J.B. Lopes, L.A.O. Dallan, S.P. Campana-Filho, L.F.P. Moreira, N.A.G. Stolf, Prevention of postoperative pericardial adhesions using thermal sterile carboxymethyl chitosan, *Rev. Bras. Cir. Cardiovasc.* 23 (4) (2008 Dec) 480–487.
- [9] N.M. Paulo, M.S. De Brito e Silva, A.M. Moraes, A.P. Rodrigues, L.B. De Menezes, M.P. Miguel, et al., Use of chitosan membrane associated with polypropylene mesh to prevent peritoneal adhesion in rats, *J. Biomed. Mater. Res. Part B Appl. Biomater.* 91 (1) (2009 Oct) 221–227.
- [10] E. Dilege, H. Coskun, B. Gündüz, D. Sakiz, M. Mihmanli, Prevention of adhesion to prosthetic mesh in incisional ventral hernias: comparison of different barriers in an experimental model, *Eur. Surg. Res.* 38 (3) (2006) 358–364.
- [11] M. Van't Riet, P.J. De Vos van Steenwijk, F. Bonthuis, R.L. Marquet, E.W. Steyerberg, J. Jeekel, et al., Prevention of adhesion to prosthetic mesh: comparison of different barriers using an incisional hernia model, *Ann. Surg.* 237 (1) (2003 Jan) 123–128.
- [12] S. Gruber-Blum, A.H. Petter-Puchner, J. Brand, R.H. Fortelny, N. Walder, W. Oehlinger, et al., Comparison of three separate antiadhesive barriers for intraperitoneal onlay mesh hernia repair in an experimental model, *Br. J. Surg.* 98 (3) (2011 Mar) 442–449.
- [13] G.Z.N. Thomas, Chitosan coated marlex mesh: an experimental study in rats, *J. Indian Assoc. Pediatr. Surg.* 1 (3) (1996) 103–107.
- [14] M.H.F. Schreinemacher, P.J. Emans, M.J.J. Gijbels, J.-W.M. Greve, G.L. Beets, N.D. Bouvy, Degradation of mesh coatings and intraperitoneal adhesion formation in an experimental model, *Br. J. Surg.* 96 (3) (2009 Mar) 305–313.