



## Original article

# Balloon embedded stenting: A novel technique for percutaneous coronary intervention of bifurcation lesions, experience in Indian population



Desabandhu Vinayakumar<sup>a</sup>, Bijilesh Uppalaka<sup>b</sup>, Kailash Kumar Goyal<sup>a,\*</sup>, Anishkumar Nair<sup>a</sup>

<sup>a</sup> Department of Cardiology, Government Medical College, Kozhikode, Kerala, India

<sup>b</sup> Department of Cardiology, Government Medical College, Thrissur, Kerala, India

## ARTICLE INFO

## Article history:

Received 26 March 2017

Accepted 17 July 2017

Available online 21 July 2017

## Keywords:

Bifurcation lesions

Percutaneous coronary intervention

Balloon embedded stenting

## ABSTRACT

**Background:** Bifurcation lesions account for 15–20% of interventions carried out in a catheterization laboratory. Several techniques have been described for treating bifurcation lesions of which culotte and T-stenting and protrusion (TAP) are commonly used. Both these techniques involve recrossing the struts of primary stent, failing which the flow in second branch which can be impaired and lead to catastrophic events. In this study, we describe a novel balloon embedded stenting technique which can be incorporated with traditional culotte or TAP technique and facilitates conversion to bail out crush in case of such an event.

**Methods and results:** 28 patients who were treated with balloon embedded stenting for bifurcation lesions were included in the study. Angiographic and procedural success were achieved in all the patients. Primary stent could not be recrossed in 1 patient, who was successfully converted to bail out crush using the technique. There were no complications during the procedure. Mean fluoroscopy time and contrast volume was similar to that of conventional culotte and TAP.

**Conclusion:** The present study suggests that incorporation of balloon embedded stenting into traditional culotte or TAP technique is achievable and can facilitate conversion to bail out crush when required.

© 2017 Published by Elsevier B.V. on behalf of Cardiological Society of India. This is an open access article under the CC BY-NC-ND license (<http://creativecommons.org/licenses/by-nc-nd/4.0/>).

## 1. Introduction

A bifurcation lesion is defined as “a coronary artery narrowing occurring adjacent to, and/or involving, the origin of a significant side branch (SB). A significant SB is a branch, whose loss is of consequence to a particular patient (symptoms, location of ischemia, viability of the supplied myocardium, collateralizing vessel, left ventricular function).”<sup>1</sup> Bifurcation lesions account for 15–20% of interventions undertaken in a catheterization laboratory. The currently recommended strategy for bifurcation lesion is to use a single stent for main vessel and provisionally stent the side branch if there are suboptimal results in the side branch. However, approximately 35% of patients require crossover to two stent approach with this strategy.<sup>2</sup> Further there are many bifurcation

lesions which need an elective two stent strategy specially if the lesion involves left main coronary artery (LMCA). This underscores the need for an optimal, safe and effective two stent strategy for bifurcation lesions. Several two stent techniques like crush, culotte, T-stenting, T-stenting and protrusion (TAP stenting) and simultaneous kissing stenting (SKS) have been described, none of which have been proved to be superior over the other. Culotte and TAP technique are very often used and both of these require the primary stent to be recrossed which can be difficult sometimes. Failing to recross the wire through the struts of the first stent compromises the unstented branch and can be life threatening specially if it involves LMCA or proximal LAD artery. Recently few techniques have been developed which aim to increase the safety of this approach and enhance side branch protection.<sup>3,4</sup> We here in intend to describe a similar strategy in Indian population in which a wire with an embedded balloon in the unstented branch safeguards the eventuality of a failed culotte or TAP stenting and facilitates conversion to bail out crush.

\* Corresponding author at: Department of Cardiology, Super-specialty Block Government Medical College, Kozhikode, Kerala, 673008, India.  
E-mail address: [goyal31st@gmail.com](mailto:goyal31st@gmail.com) (K.K. Goyal).

## 2. Material and methods

A prospective, observational, non-blinded study in patients from a single tertiary referral cardiac centre. Patients with an indication for percutaneous coronary intervention (PCI) of a de-novo bifurcation lesion were screened. The study included 28 patients who underwent coronary angiogram in our institution and had bifurcation lesions suitable for culotte or TAP procedures between January 2016 to February 2017. Bifurcation lesions were classified according to Medina class. Culotte or TAP stenting technique was used depending on the operator's discretion. Angiographic success was defined as attainment of a residual diameter stenosis of 20% or less with TIMI 3 flow in both the main and side branches. Procedural success was defined as angiographic success without the occurrence of major complications (death, MI or CABG) before discharge. All patients provided written informed consent and the study was approved by the institutional Ethics Committee.

### Technique:-

A schematic diagram of the steps used in the technique is shown in Fig. 1. The steps include:-

1. Wiring of both the main branch and side branch (Fig. 2).
2. Predilatation of both the branches
3. Stenting of the angulated branch while the jailed wire with an embedded balloon was retained in the other branch. (Fig. 3)
4. Rewiring the unstented branch through the primary stent followed by strut dilatation (Fig. 4).
5. Following this, the jailed wire with embedded balloon was removed and Culotte or TAP stenting completed as the case was.
6. However, if the second branch could not be recrossed and flow was impaired, embedded balloon was used to crush the first stent and converted the technique into a bail out crush.
7. Final Kissing balloon dilatation was done in all the cases.

A balloon with the lowest profile ( $1 \times 5$  mm) was used in the first 8 cases, keeping in mind the possibility of the balloon getting stuck in the jailed wire. However with gaining experience and achieving success in the first 8 cases,  $1.5 \times 10$  mm balloon was used

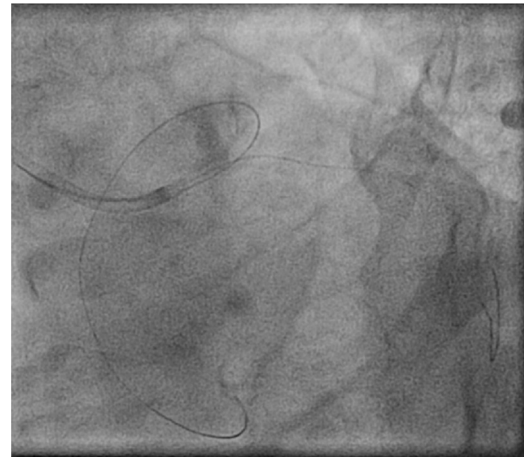


Fig. 2. Both the main and side branch are wired.

in the next 5 cases. In the last 15 cases, a  $2 \times 10$  mm balloon was used.

The embedded balloon was kept proximally at the stent in the first 7 cases so that it could help in the rapid conversion to bail out crush. In later cases, the embedded balloon was parked distally. Everolimus eluting stent (promus element, Boston Scientific) was used in all the cases as the first stent to be recrossed.

## 3. Results

Baseline clinical characteristics of the patients included in the study are shown in Table 1. 20 of the total 28 patients were males. Mean age of patients was 58.2 years. Risk factors included Diabetes Mellitus ( $n = 15$ ), hypertension ( $n = 20$ ), smokers ( $n = 16$ ), dyslipidemia ( $n = 23$ ) and positive family history of coronary artery disease (CAD) ( $n = 11$ ). History of an acute coronary syndrome (ACS) was present in 19 patients while the remaining 9 had a history of exertional angina grade II to III. Culotte stenting was done in 21 patients whereas TAP was done in 7 patients.

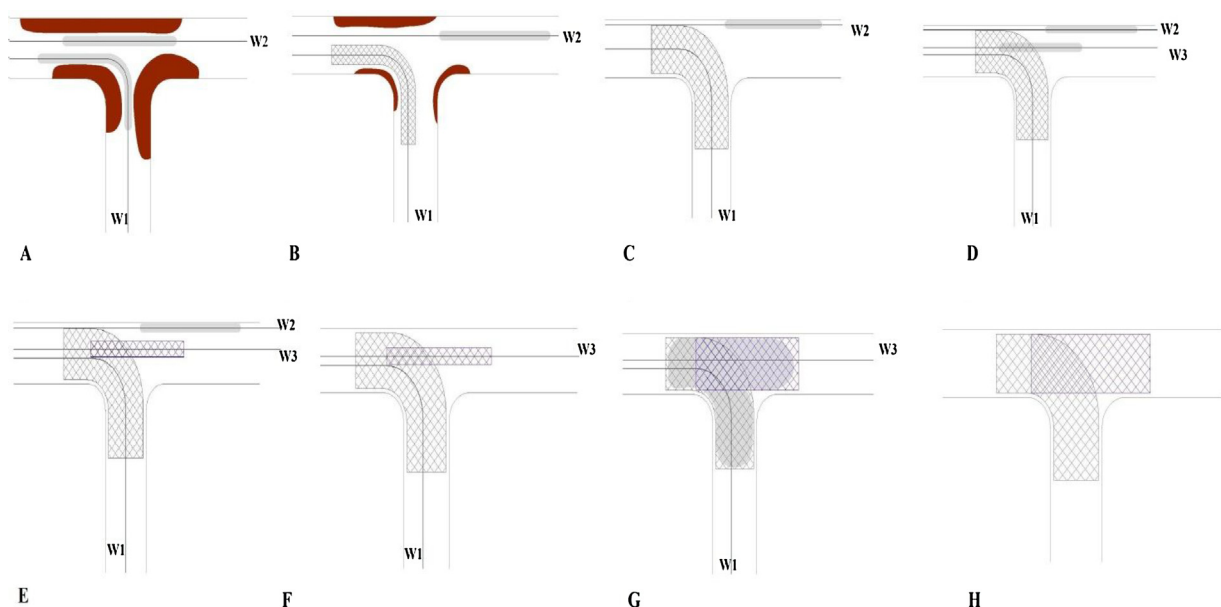
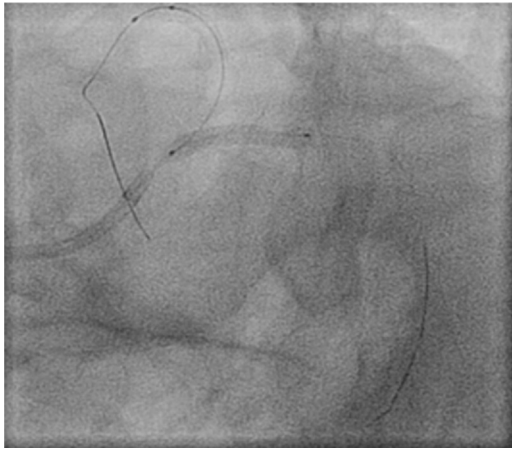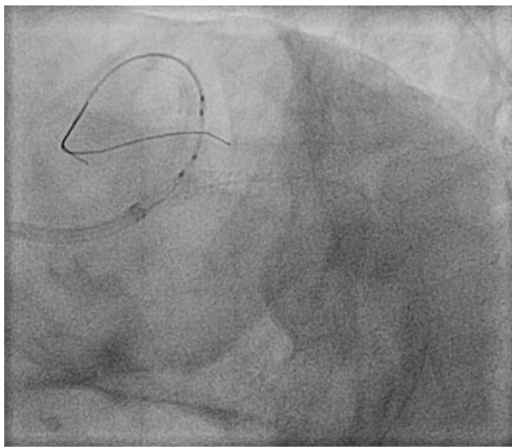


Fig. 1. Schematic diagram showing steps used in the technique. A- predilatation of both the branches. B,C- stenting of the angulated branch with the jailed wire and embedded balloon in the second branch. D- rewiring the second branch through the primary stent followed by strut dilatation. E- the second stent passed via the dilated struts. F- Jailed wire with embedded balloon was removed. G- second stent deployed and final kissing balloon dilatation done. H- final result.



**Fig. 3.** The angulated branch is stented while a jailed wire with an embedded balloon is retained in the other branch.



**Fig. 4.** The unstented branch is rewired through the primary stent.

**Table 1**

Baseline clinical characteristics (n = 28).

Age, years(mean)	58.2
Male	20(71.4)
Diabetes Mellitus	15(53.5)
Hypertension	20(71.4)
Smokers	16(57.1)
Family history of CAD	11(39.2)
Dyslipidemia	23(82.1)
History of ACS	19(67.8)

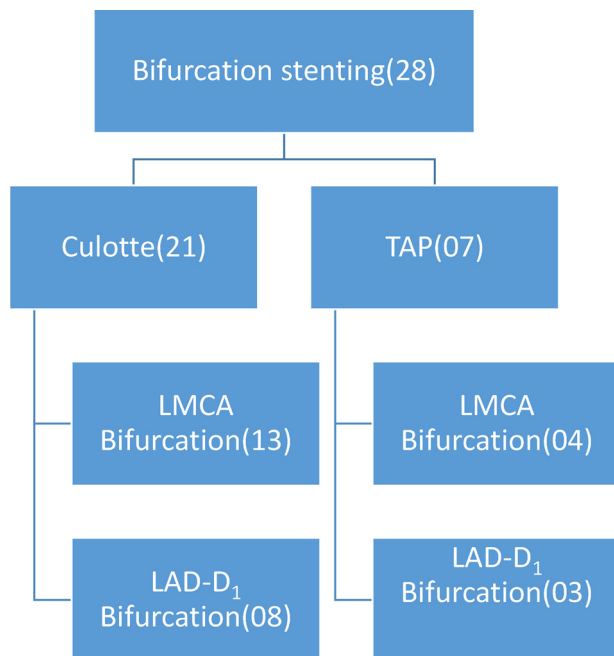
patient was successfully converted into bail out crush strategy using the embedded balloon and TIMI 3 flow was achieved in both the branches.

The mean procedural time was 93 min and mean fluoro time was 32 min which was comparable with the time taken for conventional culotte or TAP procedure done by the same operator. Angiographic and procedural success were achieved in all the patients. There were no in hospital cardiovascular events (MI, stent thrombosis, stroke) in any of the patients. All the patients were discharged on the second day.

#### 4. Discussion

Percutaneous coronary intervention (PCI) for bifurcation lesions still remains a challenge to the interventional cardiologist and is associated with low procedural success rate and high complication rates.<sup>5</sup> The incidence of stent thrombosis and target lesion revascularization (TLR) following an intervention for bifurcation lesion remains high compared to that for non bifurcation lesions.<sup>6,7</sup> Randomized studies have consistently demonstrated that a single-stent provisional strategy of stenting just the main branch (MB) has the best clinical outcomes compared to double-stent techniques. A significant number of patients however still require two stent strategy of which culotte and TAP are commonly used. In both these techniques, the second stent needs to be advanced through the side struts of an implanted stent which can be difficult and impossible sometimes thus compromising flow in the second branch. Crush technique although useful in avoiding side branch occlusion, has a higher side branch restenosis rate compared to that of culotte stenting.<sup>8</sup> Crush technique is also associated with a higher risk of malapposition than either the culotte or TAP technique<sup>9</sup> and final kissing balloon inflation is potentially difficult with crush technique because the wire and the balloon have to cross double layers of stent at the SB orifice. These all factors make crush technique a less preferable first choice for bifurcation stenting. A strategy is thus needed in which all patients requiring two stents can undergo culotte or TAP as the first choice with an option of converting to bail out crush technique in case culotte or TAP fails. Various new techniques have shown promise in improving the safety of side branch;<sup>10</sup> however, there no such studies in Indian population to our knowledge.

In this pilot study, we used a novel balloon embedded culotte or TAP stenting technique which aimed to facilitate the conversion of a failed culotte or TAP to a bailout crush strategy. The study showed that balloon embedded stenting offered a high procedural success rate with minimal complications. One patient with a failed culotte of LAD-D<sub>1</sub> bifurcation was successfully and rapidly converted to bail out crush technique with no complications. The amount of stent to be crushed however depends on the length of the first stent protruding in the parent vessel. So, while planning the technique, operators may predetermine the amount of protrusion of side branch stent into the parent vessel. The embedded balloon could be removed in all the patients with no balloon damage or entrapment



Rewiring of side branch through the stent was successful in 27 patients. However, in a patient with LAD-D<sub>1</sub> bifurcation lesion, wire could not be re crossed into the side branch via the stent. This

In previously described jailed balloon technique,<sup>3</sup> balloon per se was embedded in the stent struts. In our study, we embedded the balloon only in few patients while in other cases balloon shaft was embedded in the stent with the balloon parked distally in the vessel. The additional advantage provided by the distally parked balloon was that it acted as an anchor and helped in the recrossing the stent struts in difficult cases. This is highlighted by the fact that 27 out of 28 patients underwent successful culotte or TAP stenting. Further, in balloon cushioning technique described by Ku PM et al.,<sup>11</sup> a semiinflated balloon was used, whereas in our study we didn't use inflated balloon.

Advantages of the technique include

1. Ease of conversion to a bailout crush
2. Embedded balloon if parked distally can be used as an anchor to ensure guide support as well as to facilitate strut recrossing.
3. Serves as a life saving option in the event of failure to recross into the true lumen with flow limiting flaps, as the first wire is always in the true lumen thereby ensuring a true lumen access till the stent is successfully recrossed.
4. Additional fluoroscopic exposure or procedure time is not required.

## 5. Conclusion

Balloon embedded stenting is a novel technique which can be used for patients undergoing bifurcating stenting using two stents. This technique facilitates the rapid conversion of a failed culotte or TAP to a bail out crush as well as increases the probability of a successful culotte or TAP.

Possible risks associated with the technique

1. Difficulty in re crossing of true lumen which occurred in one case in current study and was converted to bail out crush.
2. Difficulty in retrieval of embedded balloon- none of the cases in this study.
3. Possible coronary artery perforation- none in our study.
4. Difficulty in re crossing the second stent- none in our study.

## Limitations of the study

1. The study was performed in a single centre and all the cases were done by the same operator.
2. This was an observational study to assess the feasibility and safety of the technique and hence have a small number. With gaining experience, we would like to incorporate other centres/operators and go for a controlled trial.
3. This study was planned as a prospective observational study. Hence, the control arm was not planned.

## References

1. Louvard Y, Thomas M, Dzavik V, et al. Classification of coronary artery bifurcation lesions and treatments: time for a consensus!. *Catheter Cardiovasc Interv.* 2008;71:175–183.
2. Ferenc M, Buettner HJ, Gick M, et al. Clinical outcome after percutaneous treatment of de novo coronary bifurcation lesions using first or second generation of drug-eluting stents. *Clin Res Cardiol.* 2016;105:230–238.
3. Burzotta F, Trani C, Sianos G. Jailed balloon protection: a new technique to avoid acute side-branch occlusion during provisional stenting of bifurcated lesions. Bench test report and first clinical experience. *EuroIntervention.* 2010;5:809–813.
4. Aminian A, Dolatabadi D, Lalmand J. Small balloon inflation over a jailed wire as a bailout technique in a case of abrupt side branch occlusion during provisional stenting. *J Invasive Cardiol.* 2010;22:449–452.
5. Al Suwaidi J, Berger PB, Rihal CS, et al. Immediate and long-term outcome of intracoronary stent implantation for true bifurcation lesions. *J Am Coll Cardiol.* 2000;35(4):929–936.
6. Stinis CT, Hu SP, Price MJ, et al. Three-year outcome of drug-eluting stent implantation for coronary artery bifurcation lesions. *Catheter Cardiovasc Interv.* 2010;75:309–314.
7. Iakovou I, Schmidt T, Bonizzoni E, et al. Incidence, predictors, and outcome of thrombosis after successful implantation of drug-eluting stents. *JAMA.* 2005;293:2126–2130.
8. Erglis A, Kumsars I, Niemelä M, Kervinen K, Maeng M. Randomized comparison of coronary bifurcation stenting with the crush versus the culotte technique using Sirolimus eluting stents: the Nordic Stent Technique Study. *Circ Cardiovasc Interv.* 2009;2:27–34.
9. Foin N, Alegria-Barrero E, Torii R, et al. Crush, culotte, tap: which 2-stent technique for treatment of true bifurcation lesions? *Circ J.* 2012;77:73–80.
10. Burzotta F, Trani C. Jailed balloon protection and rescue balloon jailing techniques set the field for safer bifurcation provisional stenting. *Int J Cardiol.* 2015;201(December) 376–7A.
11. Ku PM, Huang TY, Chen ZC, Woo M, Hung JS. Incorporation of a balloon-cushion stenting technique into the culotte stenting technique in left main Coronary artery bifurcation interventions. *J Clin Exp Cardiol.* 2013;4:230.