

## Peripheral nerve entrapments—rare causes of a common condition: case series

Laura Mendes de Barros<sup>a</sup> , Adilson Jose Manuel de Oliveira<sup>b,c</sup> ,  
Alan de Souza Santos<sup>a</sup> , Flávio Leão Lima<sup>a</sup> , Rodolfo Silva Valente<sup>d</sup> 

**How to cite:** Barros LM, de Oliveira AJM, Santos AS, Lima FL, Valente RS. Peripheral nerve entrapments—rare causes of a common condition: case series. *Autops Case Rep* [Internet]. 2020;10(2):e2020153. <https://doi.org/10.4322/acr.2020.153>

### ABSTRACT

Compressive syndromes of peripheral nerves both in the upper and lower limbs are part of daily clinical practice; however, the etiological diagnosis can be challenging and impact on the outcome of the patient. We report five cases with rare etiologies of nerve entrapments: one in the lower limb and four in the upper limbs with the final diagnosis made only during the operation. The patients evolved without post-operative complications and had good outcomes. This series includes the first report of sciatic compression by a lipoma in the popliteal fossa, two lipomas one with compression of infraclavicular brachial plexus and another with compressing the posterior interosseous nerve, and two reports of vascular lesions due to blunt traumas, which are also uncommon. This series adds to the literature more hypotheses of differential diagnoses in nerve entrapments, which is fundamental to surgical decisions and pre-operative planning—and perhaps most importantly prevents wrong diagnosis of idiopathic compressions, which would lead to a completely wrong approach and unfavorable outcomes.

### Keywords

Sciatic Neuropathy; Nerve Compression Syndromes, Ulnar Nerve; Radial Nerve; Aneurysm; Lipoma.

### INTRODUCTION

Nerve entrapment syndrome describes the mechanical irritation by which a specific peripheral nerve becomes locally injured in a vulnerable anatomic site, and it may be idiopathic or secondary. Secondary causes include fractures, tumors, synovial cysts, or vascular lesions.<sup>1</sup>

The entrapment symptoms depend on the affected nerve and the compression site. The decision for a surgical approach depends on the identification—or not—of the cause of the compression. In the case of

identification of a secondary lesion the approach is directed towards elimination of the causal agent.<sup>1</sup>

The usual progression of symptoms is initially only sensory and transient, then they become permanent, and finally a delay in treatment or lack of treatment can result in incapacitating motor deficits.<sup>1,2</sup>

Compression syndromes of the lower limbs are less frequent than in the upper limbs. When present, the most frequent lower limb symptoms are idiopathic compression of the fibular nerve at the head of the

<sup>a</sup> Hospital de Base do Distrito Federal, Department of Neurosurgery. Brasília, DF, Brazil.

<sup>b</sup> Universidade de São Paulo (USP), Hospital das Clínicas, Faculty of Medicine, Department of Neurosurgery. São Paulo, SP, Brazil.

<sup>c</sup> Clínica Girassol, Neurosurgery Service. Luanda, Angola.

<sup>d</sup> Radiolinea Centro de Imagens. Brasília, DF, Brazil.



fibula, or compression of the sciatic nerve in the gluteal or intra-pelvic region. On the other hand, compressions in the upper limb are more frequent and have a great variety of causes—some of which are very rare.<sup>3</sup>

Vascular lesions and lipomas are rarer causes of peripheral nerve entrapment, and there are very few case reports in the literature worldwide.<sup>3-6</sup>

We report five cases of rare causes of peripheral nerve entrapment. The first is a compression of the sciatic nerve at the popliteal fossa; the second is a compression of the medial cutaneous nerve of the forearm by a post-traumatic pseudoaneurysm; and the final three cases were caused by lipomas in different anatomic regions.

### Case 1

A 31-year-old male patient presented in the outpatient clinic with complaints of loss of muscle strength in his left leg, with a dropped foot, which was associated with neuropathic pain refractory to clinical treatment with 2 years of evolution.

Physical examination of the left lower limb was undertaken.

*Sensory examination:* Anesthesia on the lateral side of the leg, foot, third to fifth toes; hypoesthesia in

the remaining regions of the leg and foot; Tinel's sign positive 2 cm proximal to de popliteal fossa.

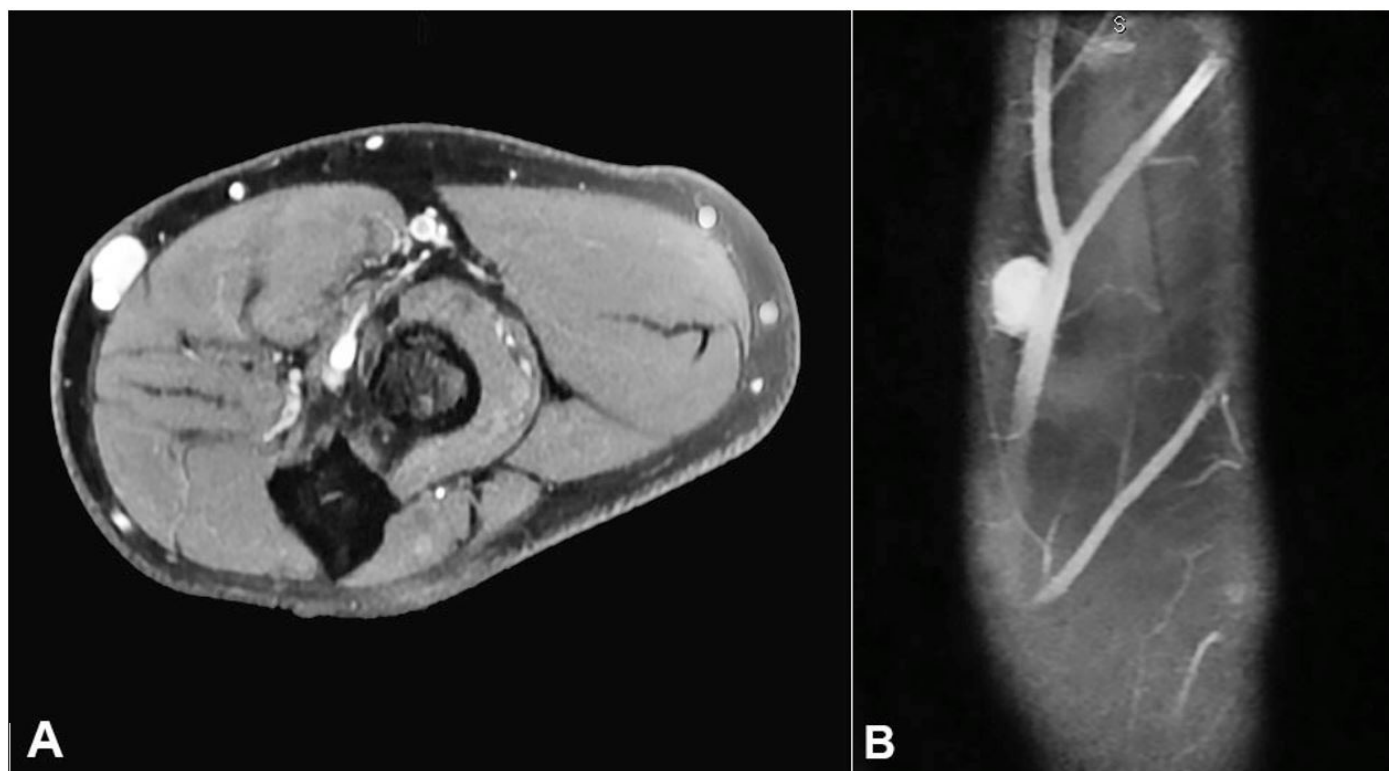
*Motor examination:* Motor strength grade 5 on the thigh and leg, on foot - grade 4 for dorsiflexion, eversion, plantar flexion and inversion, Calf atrophy was evident there were no other relevant findings.

*On Investigation:* Lumbar spine magnetic resonance imaging (MRI) had no relevant findings, but the left lower limb MRI revealed vascular alteration of the popliteal artery (Figure 1)

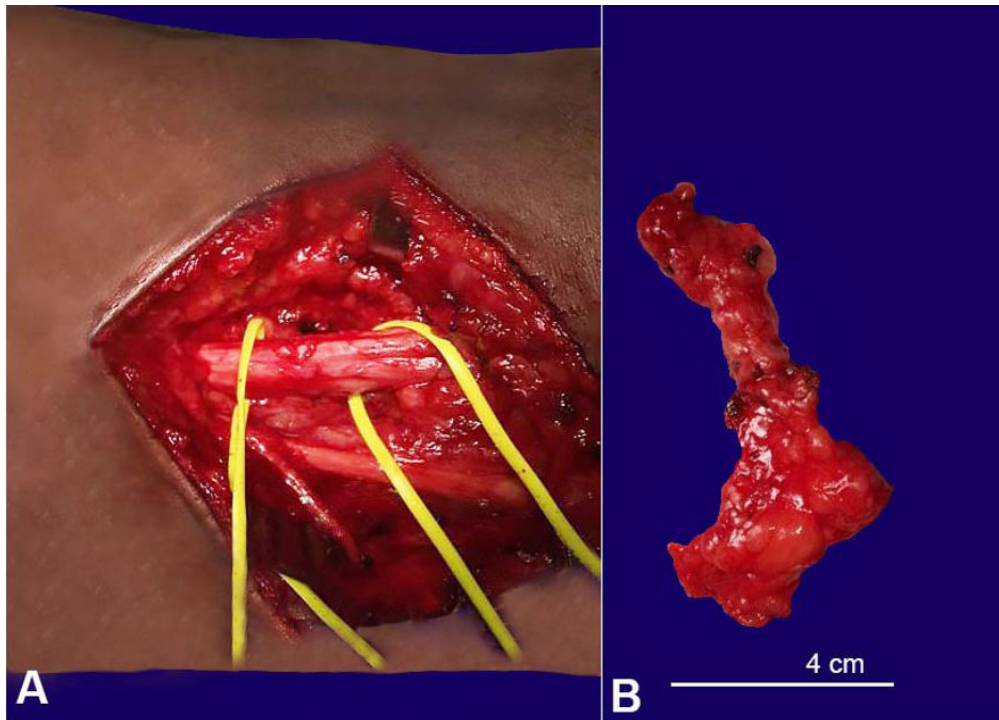
Electromyoneurography showed left sciatic nerve mononeuropathy involving tibial and common fibular divisions and signs of chronic reinnervation to a moderate degree. Also, there was injury before ramus to the femoral biceps muscle.

Surgical decompression was indicated due to motor strength loss and mainly the disabling neuropathic pain. During the intraoperative exploration of the popliteal fossa, a lipoma was found to be compressing the common tibial and fibular nerves (Figure 2) and a complete resection and external neurolysis were performed. The patient had no postoperative complications.

With 6 months of follow-up the patient's symptoms improved; at 1-year follow-up he became asymptomatic.



**Figure 1.** **A** – MRI of the left leg T1 Weighted image, after gadolinium injection, showing a saccular lesion in the popliteal artery topography; **B** – MR angiography reconstruction of popliteal artery showing the lesion.



**Figure 2.** **A** – Intraoperative view of the sciatic nerve, in the popliteal fossa after resection of the tumor; **B** – Gross view of the resected tumor (lipoma).

### Case 2

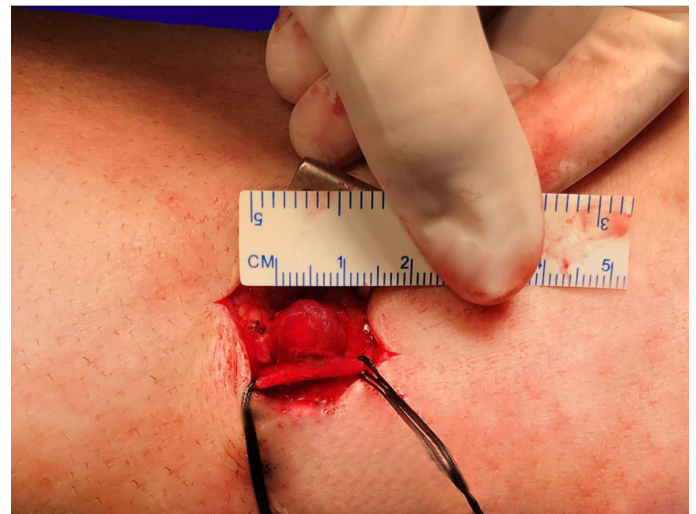A 51-year-old male patient presented at the outpatient clinic with complaints of a right forearm nodule with 10 years of evolution. Five years ago, he developed neuropathic pain (shock and burning).

Physical examination of the right upper limb revealed a palpable nodule in the proximal third of the anteromedial forearm, which was painful with local “shock.” The lesion was moveable and had a fibroelastic consistency, Tinel’s sign presented proximal to the nodule in the topography of the medial cutaneous nerve of the forearm. There were no other relevant findings.

*On Investigation:* Right upper limb MRI revealed an ovular lesion, which was well-circumscribed, adjacent to the arterial vascular branch with homogeneous contrast enhancement. Electromyoneurography showed a mononeuropathy of the right forearm cutaneous medial nerve.

A surgical approach was indicated due to the disabling neuropathic pain. In the intraoperative exploration of the forearm, a vascular lesion with compression of the medial cutaneous branch was found (Figure 3) and a complete resection was performed. The patient had no postoperative complications.

On the first post-operative day the patient’s symptoms improved and he remains asymptomatic at 1-year of follow-up.



**Figure 3.** Intraoperative view of the vascular lesion compressing the medial cutaneous branch that is isolated by the surgical treads.

### Case 3

A 36-year-old female patient presented to the outpatient clinic complaining of a right dropped hand after a traumatic injury 6 months before.

Physical examination revealed a Grade 2 motor strength for wrist extension, and finger and thumb extension Grade 0. There was no change in sensitivity. Tinel’s signal presented 1 cm distal to the lateral



epicondyle. There was a palpable mass in the cubital fossa. There were no other relevant findings

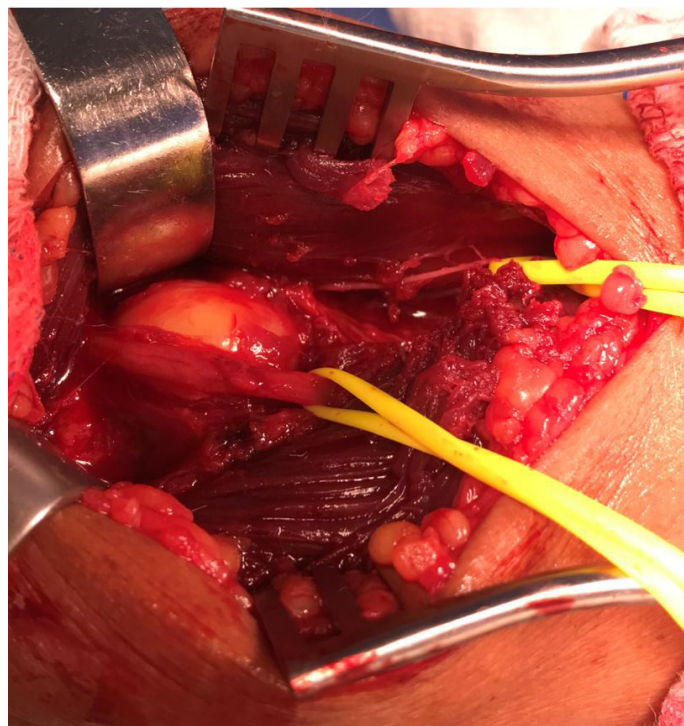*On Investigation:* Ultrasonography revealed an expansive lesion on the anterolateral face of the proximal third of the right forearm measuring 20 × 20 × 15 mm. This caused extrinsic compression of the radial and posterior interosseous nerve, which was thickened and heterogeneous, covering a 3 mm<sup>2</sup> area (contralateral 1 mm<sup>2</sup>) and shifting to the supinator belly. Electromyoneurography showed total axonal mononeuropathy at the right posterior interosseous nerve, which suggested axonotmesis.

A surgical approach was indicated due to the loss of muscular strength. Intraoperative exploration found a tumor compressing the posterior interosseous nerve (Figure 4), and a complete resection was performed. Histopathologic diagnosis revealed a lipoma. The patient had no postoperative complications.

There has not been enough follow-up time for a recovery evaluation.

#### Case 4

A 44-year-old female patient presented to the outpatient clinic with complaints of a nodule in the left forearm, with neuropathic pain in the fourth and



**Figure 4.** Intraoperative view the vascular lesion with close contact and compressing the medial cutaneous branch isolated by the yellow surgical tape.

fifth fingers over the last year, refractory to clinical treatment.

Physical examination revealed hypoesthesia in the ulnar nerve territory. There were no other relevant findings.

*On Investigation:* Ultrasonography showed an expansive lesion on the ulnar nerve topography in the forearm in continuity with the nerve, measuring 12 × 8 × 5 mm.

A surgical approach was indicated due to the neuropathic pain. The intraoperative exploration of the forearm revealed a vascular lesion (Figure 5), and a complete resection was performed.

The patient had no post-operative complications. The histologic diagnosis revealed a capillary hemangioma

At 1 week of follow-up the patient's symptoms had improved and she remains asymptomatic at 1-year follow-up.

#### Case 5

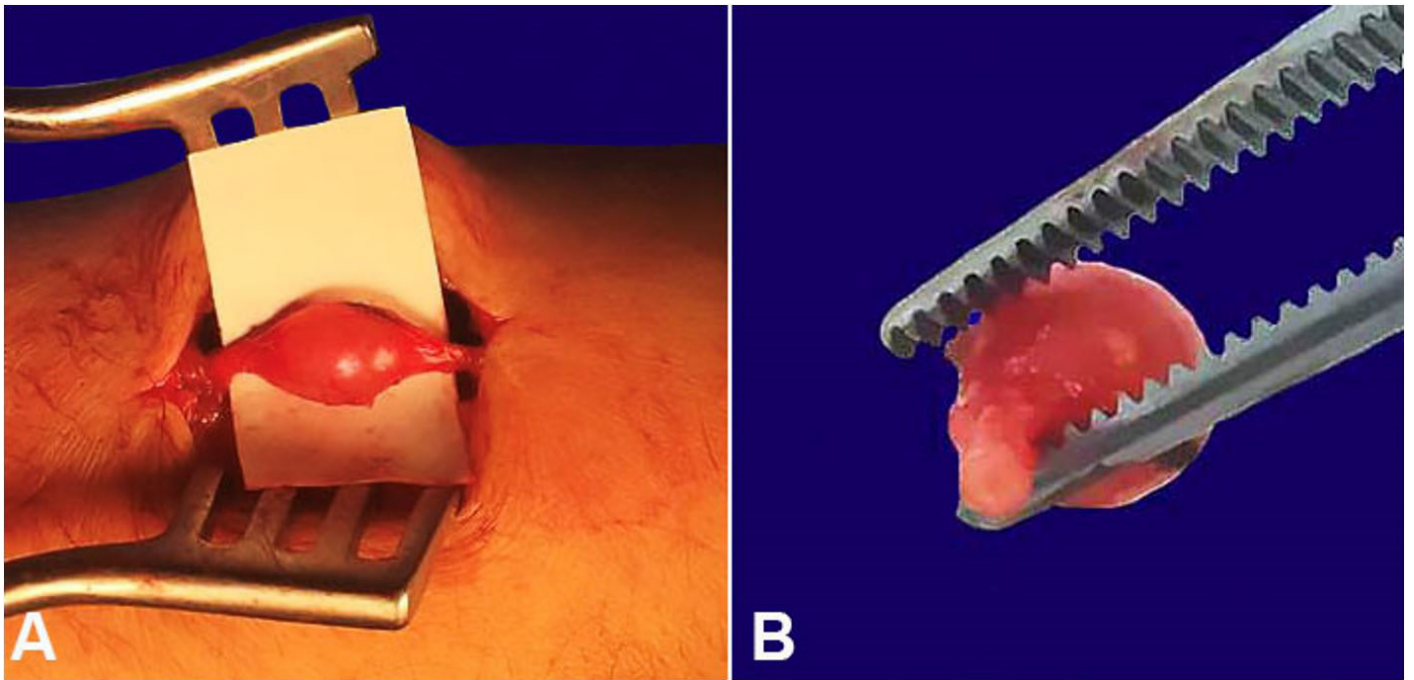
A 55-year-old female patient with a previous diagnosis of hypertension and diabetes, presented to the outpatient clinic with complaints of tumor in the right axillary region with progressive growth over 10 years. For the past year the patient has had disabling neuropathic pain.

Physical examination revealed motor strength Grade 4 to the forearm extension, wrist extension, and intrinsic hand. The sensory examination was normal, and there were no other relevant findings.

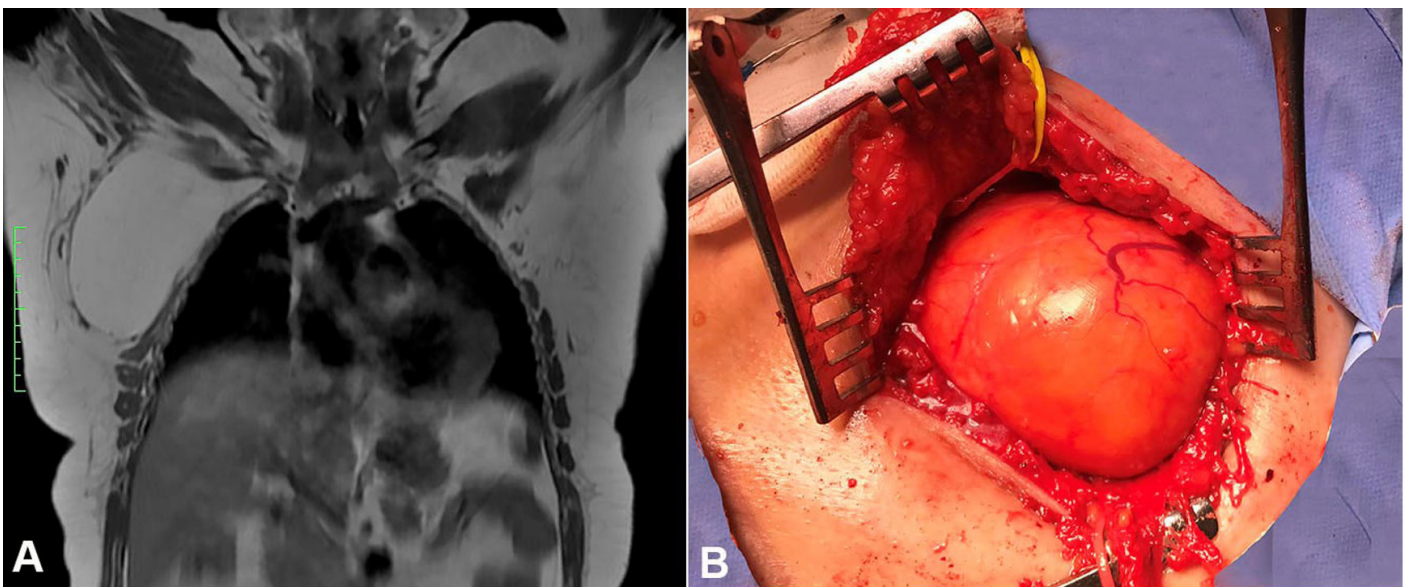
*On Investigation:* A right upper limb MRI showed a right axillary expansive lesion of 130 × 80 × 80 mm, displacing the right brachial plexus anteriorly and superiorly (Figure 6A).

A surgical resection was indicated due to the progressive worsening of motor strength. The intraoperative exploration revealed a lesion suggestive of lipoma (Figure 6B). A complete resection was performed, and the patient had no postoperative complications. The histologic diagnosis was an atypical lipoma.

At 1 month of follow-up the patient's symptoms had improved and she remains asymptomatic at 1-year follow-up.



**Figure 5.** **A** – intraoperative view of the vascular lesion in the forearm; **B** – capillary haemangioma.



**Figure 6.** **A** – Thoracic MRI showing a right axillary expansive lesion displacing the right brachial nervous plexus; **B** – Intraoperative view - right supraclavicular lipoma.

## DISCUSSION

Compressive syndromes of peripheral nerves are part of daily medical practice. Perhaps the first question is: idiopathic or secondary? Clinical history and complementary exams can rule out secondary causes, which, when not found, point to treatment with idiopathic compression.<sup>1</sup>

We reviewed the main databases and did not find any previous reports of compression of the sciatic nerve by lipoma in the popliteal fossa. We consider it

important to report these cases as a means of placing popliteal fossa lipoma as a differential diagnosis for compressive nerve syndromes. Other authors have already reported lipomas as a cause of compression of nerves and vascular structures.<sup>5,6</sup> We found two reports specifically relating to the popliteal fossa; however, they were of selective compression of the peroneal or tibial nerves<sup>7,8</sup> not the sciatic nerve. Other more cranial locations have been previously reported with sites of compression of the sciatic nerve by lipomas.<sup>9</sup>



Nerve compression by aneurysms has previously been described in the literature,<sup>10</sup> but our series adds two cases that call attention to the challenging diagnosis, which was only possible intraoperatively. Post-traumatic vascular lesions are difficult to treat, but when treatment becomes feasible they have a good evolution.

Ulnar nerve compression is one of the most frequent conditions, just behind carpal tunnel syndrome, with reports of some rare causes.<sup>11,12</sup> There are some reports of direct traumatic lesions;<sup>11</sup> however, in this case of ulnar compression it was due to an aneurysm and not direct traumatic injury as the most of cases. This is also a new finding in the literature to which we would like to draw the attention of the medical and academic community.

Radial nerve compression by pseudoaneurysm has previously been described,<sup>13-15</sup> but other authors report cases of arterial injury due to penetrating trauma. We want to draw attention in this case of radial nerve compression to the possibility of arterial injury even in blunt traumas.

These vascular lesions may have different degrees of complexity and require the surgeon's skills to choose the best vascular approach to the arterial ligation.<sup>10</sup> In our cases the intraoperative evaluation of the distal pulse to the connected artery allowed the decision to be made safely; however, it is not always that simple.

## CONCLUSION

This series of five cases has demonstrated a new finding (compression of the sciatic nerve in the popliteal fossa by lipoma) and two atypical presentations of relatively frequent compressive syndromes.

We believe that the most important clinical aspects of this series of cases are: (i) history of trauma (although blunt traumas may be related to vascular lesions); and (ii) the presence of a compressive syndrome with topography in the popliteal fossa should take into account lipomas as possible etiological agents.

All five patients signed the informed consent and the manuscript has the authorization of the institutional ethics committee.

## REFERENCES

1. Neal SL, Fields KB. Peripheral nerve entrapment and injury in the upper extremity. *Am Fam Physician*. 2010;81(2):147-55. PMID:20082510.

2. Nakano KK. The entrapment neuropathies. *Muscle Nerve*. 1978;1(4):264-79. <http://dx.doi.org/10.1002/mus.880010403>. PMID:750930.
3. Hirose CB, McGarvey WC. Peripheral nerve entrapments. *Foot Ankle Clin*. 2004;9(2):255-69. <http://dx.doi.org/10.1016/j.fcl.2004.02.001>. PMID:15165581.
4. Lubahn JD, Cermak MB. Uncommon nerve compression syndromes of the upper extremity. *J Am Acad Orthop Surg*. 1998;6(6):378-86. <http://dx.doi.org/10.5435/00124635-199811000-00006>. PMID:9826421.
5. Flores LP, Carneiro JZ. Peripheral nerve compression secondary to adjacent lipomas. *Surg Neurol*. 2007;67(3):258-62, discussion 262-3. <http://dx.doi.org/10.1016/j.surneu.2006.06.052>. PMID:17320633.
6. Kim DH, Midha R, Murovic JA, Spinner RJ, Teil R. Kline and Hudson's nerve injuries: operative results for major nerve injuries, entrapments and tumors. USA: Elsevier Health Sciences; 2007.
7. Resende LA, Silva MD, Kimaid PA, Schiavão V, Zanini MA, Faleiros AT. Compression of the peripheral branches of the sciatic nerve by lipoma. *Electromyogr Clin Neurophysiol*. 1997;37(4):251-5. PMID:9208220.
8. Midón Miguez J, Casteleiro Roca P, Martelo Villar F. Lipomas y compresión nerviosa. *Cir. Plást. Ibero-Latinoam*. 2010;36(1):49-56.
9. Botwin KP, Shah CP, Zak PJ. Sciatic neuropathy secondary to infiltrating intermuscular lipoma of the thigh. *Am J Phys Med Rehabil*. 2001;80(10):754-8. <http://dx.doi.org/10.1097/00002060-200110000-00009>. PMID:11562557.
10. Robbs JV, Naidoo KS. Nerve compression injuries due to traumatic false aneurysm. *Ann Surg*. 1984;200(1):80-2. <http://dx.doi.org/10.1097/00000658-198407000-00014>. PMID:6732331.
11. Kalisman M, Laborde K, Wolff TW. Ulnar nerve compression secondary to ulnar artery false aneurysm at the Guyon's canal. *J Hand Surg Am*. 1982;7(2):137-9. [http://dx.doi.org/10.1016/S0363-5023\(82\)80077-4](http://dx.doi.org/10.1016/S0363-5023(82)80077-4). PMID:7069168.
12. Oliveira AJM, Sterman H, Martins RS, Foroni LH, Siqueira MG. A rare cause of ulnar nerve entrapment at the elbow in a patient with leprosy. *Autops Case Rep*. 2019;9(3):e2019096. <http://dx.doi.org/10.4322/acr.2019.096>. PMID:31372358.
13. Rahimizadeh A. Unusual delayed radial nerve palsy caused by a traumatic aneurysm of a collateral radial artery: report of two cases. *Neurosurgery*. 1992;30(4):628-30. <http://dx.doi.org/10.1227/00006123-199204000-00028>. PMID:1584366.
14. Kassabian E, Coppin T, Combes M, Julia P, Fabiani JN. Radial nerve compression by a large cephalic vein aneurysm: case report. *J Vasc Surg*. 2003;38(3):617-9. [http://dx.doi.org/10.1016/S0741-5214\(03\)00290-8](http://dx.doi.org/10.1016/S0741-5214(03)00290-8). PMID:12947288.
15. Bagir M, Sayit E, Tanrivermis Sayit A. Pseudoaneurysm of the radial artery on the hand secondary to stabbing. *Ann Vasc Surg*. 2017;41:280.e7-10. <http://dx.doi.org/10.1016/j.avsg.2016.09.027>. PMID:28242403.

**Authors' contributions:** Barros LM, Santos AS and Lima FL were the surgeons of the cases and provide clinical information, intra operative photos and approved the final version. de Oliveira AJM wrote the manuscript, edited the pictures and approved the final version. Valente Rs Provided, analysed the radiological pictures and approved the final version.

**Conflict of interest:** None

**Financial support:** None

**Submitted on:** January 7<sup>th</sup>, 2020

**Accepted on:** January 30<sup>th</sup>, 2020

**Correspondence**

Adilson José Manuel de Oliveira  
Alameda Santos, 663 – Ap 34B – São Paulo/SP – Brazil  
CEP: 01419-001  
Phone: +55 (11) 99779-2709  
adilsonvalmont@gmail.com