



Successful endoscopic submucosal dissection for a tumor located completely within a colonic diverticulum after inversion of the diverticulum using a traction device

Takashi Muramoto, MD, PhD,¹ Ken Ohata, MD, PhD,¹ Ryoju Negishi, MD,¹ Yohei Minato, MD,¹ Nobuyuki Matsuhashi, MD, PhD²

A 59-year-old man was diagnosed as having a flat-elevated tumor measuring 10 mm in diameter in the colon; the tumor was completely located within a colonic diverticulum in the hepatic flexure (Fig. 1A to C). Based on endoscopic evaluation, we determined there was a good chance of obtaining curative resection by endoscopic means. In addition, because we made it possible to invert the diverticulum into the colonic lumen by traction with forceps, we scheduled endoscopic submucosal dissection (ESD) using a traction device with the patient under general anesthesia (Fig. 1D).

The entire procedure is presented in [Video 1](#) (available online at www.giejournal.org). After reconfirming that the diverticulum could be inverted into the lumen with forceps, the first endoclip, grasping a ring-thread made of dental floss,¹ was fixed on the mucosa in the diverticulum. Immediately afterward, a second endoclip was used to grasp the ring-thread and fix it to the opposite colonic wall. By insufflating with air, the lesion within the inverted diverticulum was pulled out of the diverticulum into the colonic lumen, establishing a good field of view for dissection (Fig. 2A). After local injection of hyaluronic

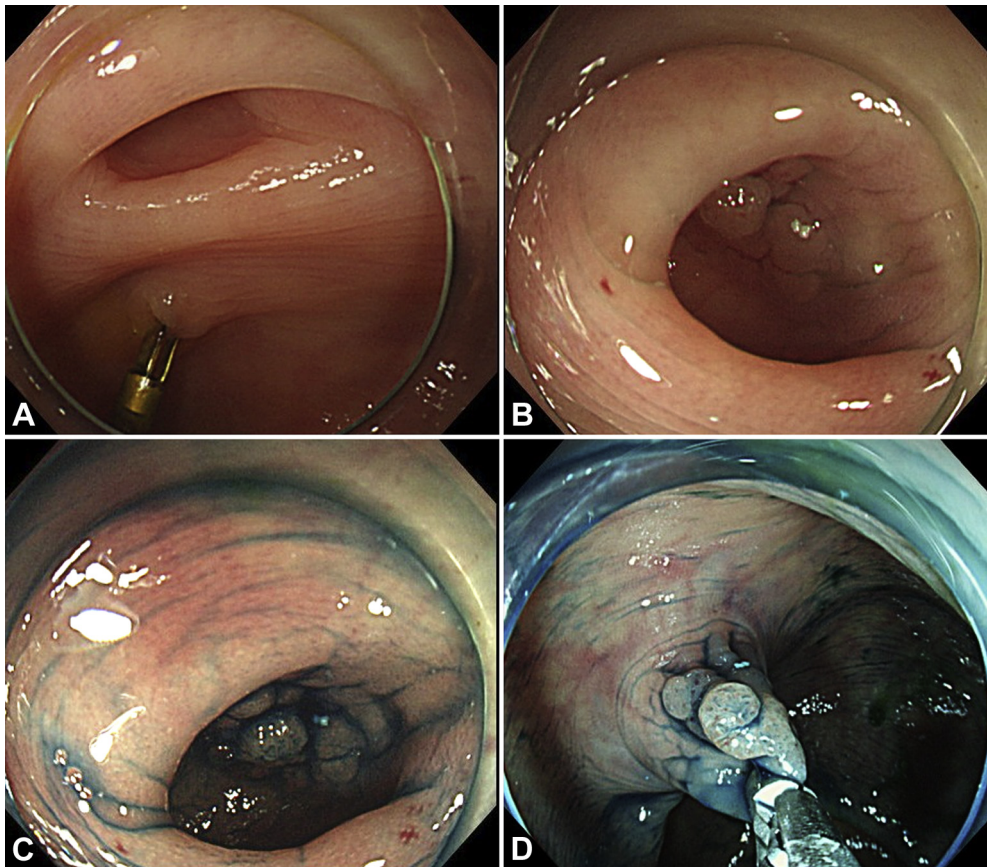


Figure 1. **A**, Colonoscopy revealed multiple diverticula in the hepatic flexure. **B and C**, The flat-elevated tumor located completely within the diverticulum. **D**, By using forceps for traction, the diverticulum containing the tumor could be completely inverted into the colonic lumen, clearly exposing the lesion.

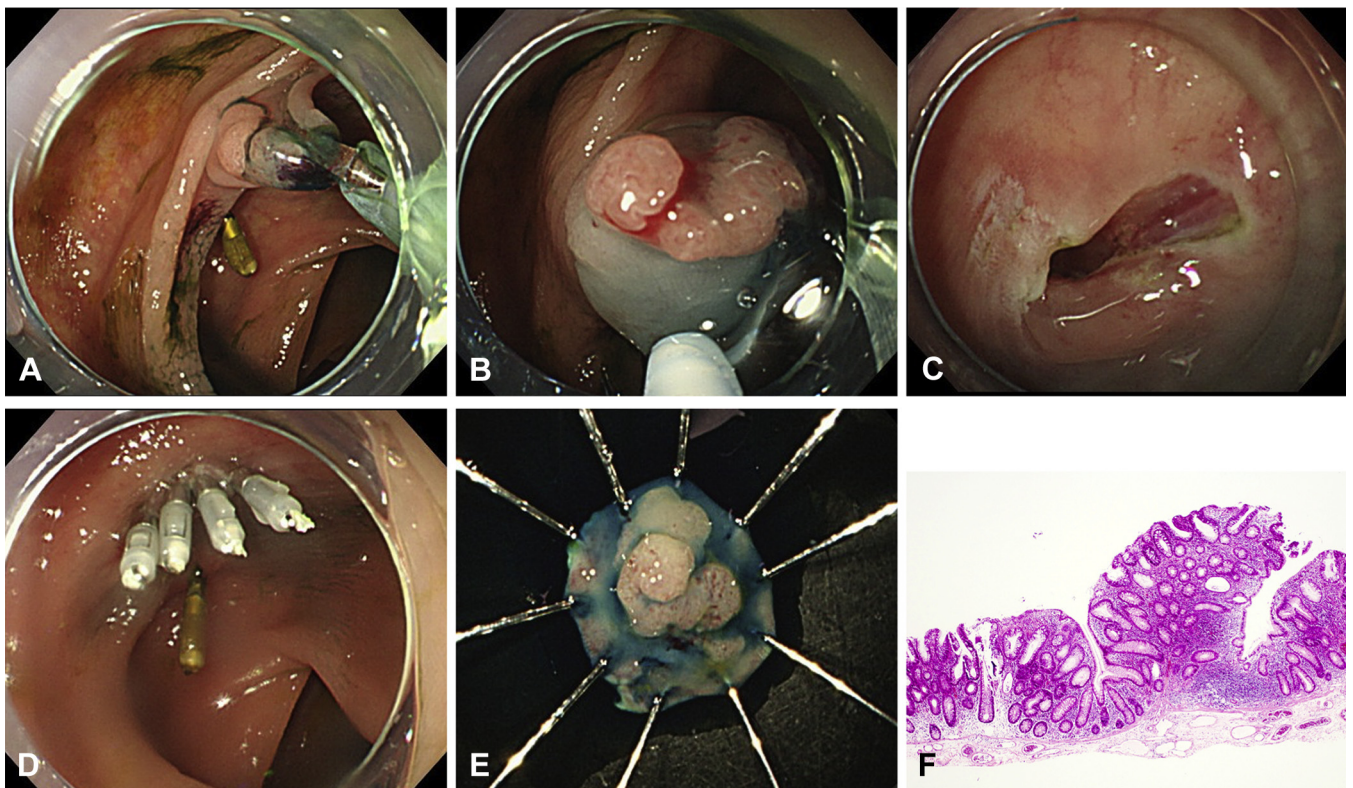


Figure 2. **A**, The tumor within the diverticulum was exposed by inverting the diverticulum containing the lesion into the colonic lumen using ring-thread traction. **B**, The inverted tumor was resected using a DualKnife. **C**, The wound after endoscopic submucosal dissection. **D**, The wound was completely closed with endoclips, along with the diverticulum. **E**, Resected specimen; en bloc resection was achieved. **F**, Histologic examination confirmed the diagnosis of low-grade adenoma.

acid, a circumferential incision and dissection were performed using a DualKnife (Olympus, Tokyo, Japan), and the lesion was promptly removed en bloc (Fig. 2B, C, and E). The wound was completely closed with endoclips, along with the diverticulum (Fig. 2D). The total procedure time was 10 minutes, and there were no adverse events. The patient was discharged 4 days after ESD, and there were no adverse events during the first 1 to 2 months as well. Histologic examination of the resected lesion revealed a low-grade adenoma, and curative resection had been achieved (Fig. 2F).

Safely performing ESD for lesions involving a diverticulum is technically very challenging, not least because of the high risk of perforation owing to the absence of a muscle layer in a diverticulum.^{2,3} In addition, it is difficult to recognize the dissection line in the deeper parts of a diverticulum, which often results in incomplete resection. Therefore, it is difficult to achieve en bloc resection of a lesion involving a colonic diverticulum by ESD without adverse events, unless performed by very highly skilled endoscopists; therefore, until recently, surgical treatment was the most commonly adopted treatment strategy for these lesions, even if the lesions would otherwise have been expected to be resectable endoscopically. However, in the present case, we used the traction technique first

to invert the diverticulum into the colonic lumen, which allowed a good field of view to be established for easy recognition of the dissection line. As a result, it was possible to remove even this lesion that was completely located within a diverticulum rapidly and safely.

Although there are some reports of ESD using a traction technique that was useful for these lesions, all were used during dissection.^{4,5} This is the first case in which ESD was performed after inversion of the entire diverticulum into the lumen using the traction technique.

As an alternative endoscopic treatment method, full-thickness resection using the Full-Thickness Resection Device (Ovesco Endoscopy GmbH, Tübingen, Germany) seems to be an effective option for the treatment of small lesions involving a diverticulum.^{6,7} However, this method is not only limited by the size of the lesion, but also by the risk of perforation associated with the use of the Full-Thickness Resection Device in patients with a diverticulum. In this regard, our technique is not only unlimited by the size of the lesion, it is also simple to use.

By first using a traction device to invert the diverticulum containing the lesion into the colonic lumen, the tumor completely located within the diverticula, for which endoscopic treatment is technically challenging, was successfully resected by ESD.

DISCLOSURE

All authors disclosed no financial relationships.

Abbreviation: ESD, endoscopic submucosal dissection.

REFERENCES

1. Mori H, Kobara H, Nishiyama N, et al. Novel effective and repeatedly available ring-thread counter traction for safer colorectal endoscopic submucosal dissection. *Surg Endosc* 2017;31:3040-7.
2. Muramoto T, Ohata K, Sakai E, et al. Endoscopic submucosal dissection for colorectal neoplasms in proximity or extending to a diverticulum. *Surg Endosc* 2021;35:3479-87.
3. Jimenez-Garcia VA, Yamada M, Ikematsu H, et al. Endoscopic submucosal dissection in management of colorectal tumors near or involving a diverticulum: a retrospective case series. *Endosc Int Open* 2019;7:E664-71.
4. Iwatsubo T, Uedo N, Yamasaki Y, et al. Traction-assisted colorectal endoscopic submucosal dissection by use of clip and line for a neoplasm involving colonic diverticulum. *VideoGIE* 2017;2:337-8.
5. Albouys J, Geyl S, Charissoux A, et al. Counter-traction using clips and rubber banding for endoscopic submucosal dissection of a laterally spreading tumor involving a diverticulum in the colon. *Endoscopy* 2019;51:E295-6.
6. Schmidt A, Bauerfeind P, Gubler C, et al. Endoscopic full-thickness resection in the colorectum with a novel over-the-scope device: first experience. *Endoscopy* 2015;47:719-25.
7. Boger P, Rahman I, Hu M, et al. Endoscopic full thickness resection in the colo-rectum: outcomes from the UK Registry. *Eur J Gastroenterol Hepatol* 2021;33:852-8.

Department of Gastrointestinal Endoscopy, NTT Medical Center Tokyo, Tokyo, Japan (1), Department of Gastroenterology, NTT Medical Center Tokyo, Tokyo, Japan (2).

Copyright © 2021 American Society for Gastrointestinal Endoscopy. Published by Elsevier Inc. This is an open access article under the CC BY-NC-ND license (<http://creativecommons.org/licenses/by-nc-nd/4.0/>).

<https://doi.org/10.1016/j.vgie.2021.09.005>

Facebook

Follow *VideoGIE* on Facebook to receive the latest news, updates, and article links. Visit <https://www.facebook.com/videogiejournal/> and keep checking back to view our most recent posts.