

# Mid-Term Outcomes of Single-Port versus Conventional Three-Port Video-Assisted Thoracoscopic Surgery for Primary Spontaneous Pneumothorax

Hanna Jung, M.D., Tak Hyuk Oh, M.D., Joon Yong Cho, M.D., Deok Heon Lee, M.D.

Department of Thoracic and Cardiovascular Surgery, Kyungpook National University Hospital,  
Kyungpook National University School of Medicine

**Background:** The benefits of video-assisted thoracoscopic surgery (VATS) have been demonstrated over the past decades; as a result, VATS has become the gold-standard treatment for primary spontaneous pneumothorax (PSP). Due to improvements in surgical technique and equipment, single-port VATS (s-VATS) is emerging as an alternative approach to conventional three-port VATS (t-VATS). The aim of this study was to evaluate s-VATS as a treatment for PSP by comparing operative outcomes and recurrence rates for s-VATS versus t-VATS. **Methods:** Between March 2013 and December 2015, VATS for PSP was performed in 146 patients in Kyungpook National University Hospital. We retrospectively reviewed the medical records of these patients. **Results:** The mean follow-up duration was 13.4±6.5 months in the s-VATS group and 28.7±3.9 months in the t-VATS group. Operative time ( $p<0.001$ ), the number of staples used for the operation ( $p=0.001$ ), duration of drainage ( $p=0.001$ ), and duration of the postoperative stay ( $p<0.001$ ) were significantly lower in the s-VATS group than in the t-VATS group. There was no difference in the overall recurrence-free survival rate between the s-VATS and t-VATS groups. **Conclusion:** No significant differences in operative outcomes and recurrence rates were found between s-VATS and t-VATS for PSP. Therefore, we cautiously suggest that s-VATS may be an appropriate alternative to t-VATS in the treatment of PSP.

*Key words:* 1. Video-assisted thoracic surgery  
2. Pneumothorax  
3. Recurrence

## Introduction

Since first introduced, the benefits of video-assisted thoracoscopic surgery (VATS) have been clearly demonstrated; as a result, VATS has become the gold-standard treatment for primary spontaneous pneumothorax (PSP), as it is a quick, safe, and effective procedure, with comparable recurrence to open thoracotomy [1]. Due to improvements in surgical technique and equipment, single-port VATS (s-VATS)

is emerging as an alternative approach to conventional three-port VATS (t-VATS) [2-4]. PSP is not a critical disease, but may become problematic due to recurrence. With the s-VATS approach, since all the instruments are manipulated through just one small hole, limitations in the visual field and surgical procedure are inevitable [5]. There are still doubts about the degree to which it is actually possible to fully explore the thoracic cavity to find blebs or bullae, and about whether this technique allows for the

Received: July 25, 2016, Revised: September 29, 2016, Accepted: October 17, 2016, Published online: June 5, 2017

Corresponding author: Deok Heon Lee, Department of Thoracic and Cardiovascular Surgery, Kyungpook National University Hospital, Kyungpook National University School of Medicine, 130 Dongdeok-ro, Jung-gu, Daegu 41944, Korea (Tel) 82-53-200-5665 (Fax) 82-53-426-4765 (E-mail) [ldhms@naver.com](mailto:ldhms@naver.com)

© The Korean Society for Thoracic and Cardiovascular Surgery. 2017. All right reserved.

© This is an open access article distributed under the terms of the Creative Commons Attribution Non-Commercial License (<http://creativecommons.org/licenses/by-nc/4.0>) which permits unrestricted non-commercial use, distribution, and reproduction in any medium, provided the original work is properly cited.

precise wedge resection of the targeted blebs or bullae. Thus, despite all the benefits of s-VATS, the most important point to consider is recurrence after s-VATS. The aim of this study was to evaluate s-VATS as a treatment for PSP by comparing operative outcomes and recurrence between s-VATS and t-VATS [6].

## Methods

### 1) Study population

Between March 2013 and December 2015, VATS for PSP was performed in 146 patients at Kyungpook National University Hospital. We retrospectively reviewed the medical records of these patients. One case was counted as a single operation on one side (right or left). A total of 165 cases of VATS for PSP were performed. Fifty-one patients underwent 54 t-VATS procedures between March 2013 and April 2014. In May 2014, s-VATS became the routine approach at our institution for treating PSP in cases requiring surgical access; 101 patients underwent 111 s-VATS procedures between May 2014 and December 2015.

The eligibility criteria for this study included ipsilateral recurrent pneumothorax, a previous history of contralateral pneumothorax, persistent air leakage for more than 3 days, visible blebs or a collapsed lung on radiologic examinations, and age under 30 years. The exclusion criteria were a history of any lung disease, a previous history of ipsilateral thoracic surgery, and two-port VATS and t-VATS cases performed after s-VATS was adopted. This study was approved by the institutional review board of Kyungpook National University Hospital (IRB no. 2016-04-013).

### 2) Surgical technique

The operations were all performed by a single surgeon. All patients scheduled for VATS underwent high-resolution computed tomography to locate bullae and blebs. All operations were performed with the patient in the lateral decubitus position under general anesthesia with a double-lumen endotracheal tube allowing one-lung ventilation.

PSP patients who required closed thoracostomy to relieve symptoms routinely had a 12F trocar catheter (Argyle, suture rib trocar catheter; Covidien, Mansfield, MA, USA) inserted through the fifth intercostal space (ICS) at the mid-axillary line to use as a single port

after lengthening the skin incision to 20 mm.

The s-VATS approach was performed with a 20-mm skin incision on the mid-axillary line of the fifth ICS. A 5-mm 30° video thoracoscope and roticulator endograsp (Covidien) were used. We also employed a wound protector (T-port; Yuwon Meditech, Wonju, Korea) to retract the soft tissue and intercostal muscle and to allow maximum exposure of the incision site. All instruments were then inserted through the single incision. In most cases, the thoracoscope was placed at the right side of the incision, although sometimes the orientation of the instruments along the incision was changed. We did not require a single-incision laparoscopic surgery port [5] or an additional invasive anchoring suture (tower crane technique) [7].

For the t-VATS approach, we used inverted triangle positioning. A 10-mm 30° video thoracoscope was inserted through the seventh ICS mid-axillary line. In addition, 10-mm working ports were inserted through the fifth ICS anterior axillary line and the sixth ICS posterior axillary line.

After inserting the thoracoscope, the entire lung was carefully inspected throughout the lobes, with particular attention paid to the apex and the superior segment of the lower lobe. When it was possible to identify definite blebs or bullae, complete wedge resection of these lesions was performed using an endoscopic stapler (Endo GIA articulating stapler; Covidien). We reinforced the stapler lines by covering them with absorbable cellulose mesh (Surgicel; Ethicon, Somerville, NJ, USA) with fibrin glue (Greenplast; Green Cross Corp., Yongin, Korea); we did not perform mechanical pleural abrasion. After bleeding control was performed, we placed a 20F or 24F thoracic catheter at the apex of the pleural space.

### 3) Postoperative management

Postoperative pain control started in the recovery room with intravenous patient-controlled analgesia. As soon as the patient arrived at their room, negative suction (−20 cm H<sub>2</sub>O) was applied. If no air leakage was present on postoperative day 1, we changed to natural water-sealed drainage [8]. The thoracic catheter was removed when air leakage was no longer present and when the lung was observed to expand well on plain chest films. Patients were discharged on the day of or after removal of the thoracic catheter.

**Table 1. Patient characteristics**

Variable	Single-port VATS (n=111)	Three-port VATS (n=54)	p-value
Age (yr)	17.9±2.7	19.4±3.3	0.005
Gender			0.093
Male	97 (87.4)	52 (96.3)	
Female	14 (12.6)	2 (3.7)	
Body mass index (kg/m <sup>2</sup> )	18.9±2.1	19.2±2.5	0.563
Laterality			0.870
Right	55 (49.5)	26 (48.1)	
Left	56 (50.5)	28 (51.9)	
Mean follow-up duration (mo)	14.4±7.6	27.3±5.8	<0.001

Values are presented as mean±standard deviation or number (%). VATS, video-assisted thoracoscopic surgery.

#### 4) Follow-up and recurrence

Patients were monitored at an outpatient clinic with plain chest films 1 or 2 weeks after discharge; no other routine follow-up appointments were scheduled. Patients in this study were interviewed by telephone to ask about their present symptoms and recurrence of pneumothorax after VATS. The follow-up period was defined as the time between the date of the operation and the date of the last outpatient clinic visit or last telephone interview.

Recurrence was defined as ipsilateral recurrence of PSP after VATS on plain chest films. In addition, recurrence requiring intervention [9] was defined as recurrence requiring treatment with closed thoracostomy or reoperation.

#### 5) Statistics

Differences between 2 continuous variables were expressed as mean±standard deviation and were assessed using the Student t-test. Categorical variables were expressed as numbers (percentages) and were assessed using the Fisher exact test and the Pearson chi-square test. Freedom from recurrence was defined as the duration from surgery to the recurrence of ipsilateral pneumothorax or the last follow-up. The recurrence rates were analyzed using the Kaplan-Meier method and were compared using the log-rank test. All statistical analyses were performed using IBM SPSS ver. 22.0 for Windows (IBM Corp., Armonk, NY, USA). A statistically significant difference was defined as a 2-sided p-value <0.05.

**Table 2. Operative outcomes**

Variable	Single-port VATS (n=111)	Three-port VATS (n=54)	p-value
Operative time (min)	30.7±9.1	51.4±18.0	<0.001
No. of wedge resections	1.3±0.5	1.4±0.5	0.672
No. of staples	2.4±0.9	3.0±1.1	0.001
Drainage (day)	1.6±1.0	2.7±2.2	0.001
Postoperative stay (day)	2.3±1.3	3.6±2.4	<0.001

Values are presented as mean±standard deviation. VATS, video-assisted thoracoscopic surgery.

**Table 3. Recurrence**

Variable	Single-port VATS (n=111)	Three-port VATS (n=54)	p-value
Overall recurrence	14 (12.6)	8 (14.8)	0.808
Intervention <sup>a)</sup>	8 (7.2)	7 (13.0)	0.255

Values are presented as number (%). VATS, video-assisted thoracoscopic surgery. <sup>a)</sup>Recurrence requiring intervention.

## Results

### 1) Patient characteristics

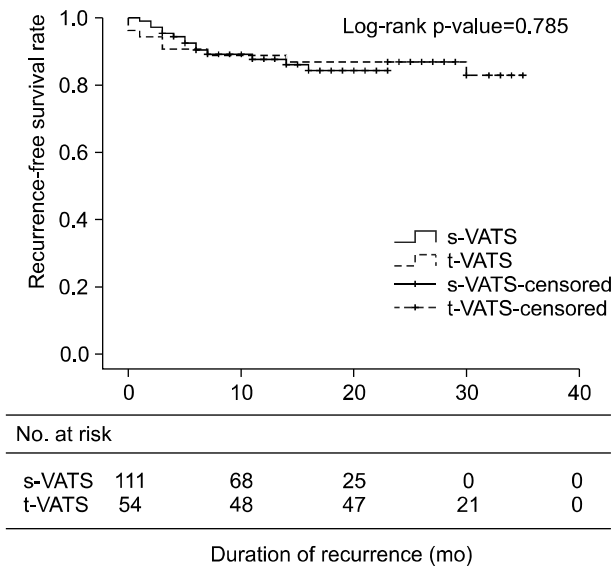
Patient characteristics are listed in Table 1. There were 111 cases of s-VATS and 54 cases of t-VATS; the mean age for each group was 17.9±2.7 years and 19.4±3.3 years, respectively. No statistically significant differences between the 2 groups were found according to gender, body mass index, or laterality of pneumothorax [10]. The mean follow-up duration was 13.4±6.5 months in the s-VATS group and 28.7±3.9 months in the t-VATS group.

### 2) Operations

The operative results are compared in Table 2. Operative time (p<0.001), the number of staplers used for the operation (p<0.001), duration of drainage (p<0.001), and the duration of the postoperative stay (p<0.001) were significantly lower in the s-VATS group than in the t-VATS group, although the number of wedge resections (p=0.672) was not significantly different between the 2 groups [8]. No surgical morbidity or 30-day hospital mortality was seen in either group.

### 3) Recurrence

The incidence of recurrence is shown in Table 3.

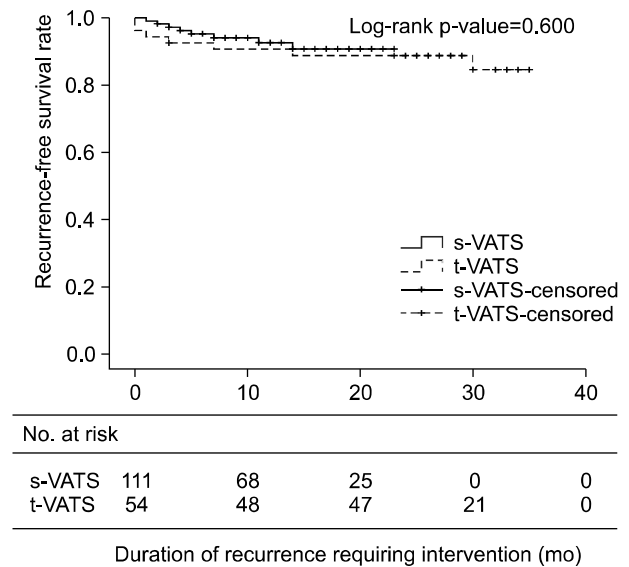


**Fig. 1.** Kaplan-Meier curves for recurrence-free survival. There was no difference in overall recurrence-free survival rates between single-port and three-port VATS. The 6-month freedom from recurrence rate was 90.4% for single-port VATS and 90.7% for three-port VATS. The rate of 1-year freedom from recurrence was 87.9% for single-port VATS and 88.9% for three-port VATS. VATS, video-assisted thoracoscopic surgery.

Recurrence occurred in 14 patients (12.6%) in the s-VATS group and 7 patients (13.0%) in the t-VATS group. Further intervention was required in 8 patients (7.2%) and 6 patients (11.1%) in the s-VATS and t-VATS groups during the follow-up period, respectively. Fig. 1 and Fig. 2 show the Kaplan-Meier curves for recurrence-free survival. Overall recurrence and recurrence requiring intervention were not significantly different between the 2 groups.

## Discussion

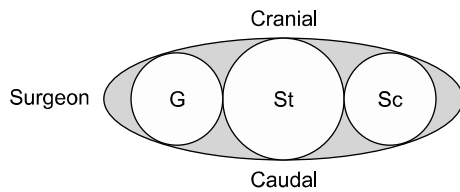
There is currently no good consensus on the best treatment for PSP. The first treatment of choice is conservative management, such as observation, oxygen inhalation, needle aspiration, or closed thoracostomy, according to the patient's symptoms. PSP is not a critical disease, but can become problematic due to its significant recurrence rate, with an average rate of 30% within 6 months to 2 years. As PSP recurrence happens more frequently, it becomes more difficult to stop the air leak with conservative management. VATS has many clear advantages, such as less postoperative pain, a shorter hospital stay, an



**Fig. 2.** Kaplan-Meier curves for recurrence requiring intervention-free survival. There was no difference in recurrence requiring intervention-free survival rates between single-port and three-port VATS. The 6-month freedom from recurrence rate was 95.3% for single-port VATS and 92.6% for three-port VATS. The rate of 1-year freedom from recurrence was 92.6% for single-port VATS and 90.7% for three-port VATS. VATS, video-assisted thoracoscopic surgery.

attenuated postoperative inflammatory response, and better cosmetic outcomes; surgeons now regard VATS as the gold-standard management technique not only for PSP, but also for other thoracic conditions, such as pleural disease and interstitial lung disease [1].

VATS for patients with spontaneous pneumothorax was first reported by Levi et al. [11] in 1990 [5]. The development of the thoracoscope, which allows for a panoramic view of the hemithorax, the availability of special endoscopic instruments, patients' concerns for better cosmetic outcomes with less pain, and surgeons' steady efforts have led to the so-called 'single-port era' [1]. Rocco et al. [12] first reported an s-VATS pulmonary wedge resection in 2004 [5]. Many other papers have described other ways of performing s-VATS with early outcomes. Kang et al. reported early outcomes of s-VATS for PSP and discussed the difficulty of whole lung exploration and obtaining an optimal angle for stapling the lung [10]. Chong et al. [7] used vicryl sutures to anchor the lung (the tower crane technique), and Yang et al. adopted a single-incision laparoscopic surgery port



**Fig. 3.** Illustration showing the order of the instruments used for the procedure. The Sc is moved on the very right side, the G is on the very left side, and the St is inserted through the middle of the incision, regardless of the laterality of the primary spontaneous pneumothorax. G, gasper; Sc, scope; St, stapler.

[5] to maximize the ICS. Based on this learning curve, we inserted all instruments through a single incision site and applied a wound protector to the 20-mm skin incision. Regardless of the laterality of the PSP, the surgeon stood on the right side of the patient. After performing whole lung exploration, the scope was moved to the far right side, the gasper to the far left side, and the stapler was inserted through the middle of the incision to perform wedge resection. Fig. 3 illustrates the order of the instruments at the incision site.

In the literature on s-VATS for PSP, most previous papers have focused on describing reduced pain and less paresthesia with better cosmetic effects, which are now widely accepted as outcomes of s-VATS. However, the most important point in treating PSP is to minimize recurrence.

When adopting s-VATS in our institution, our first concern was the difficulty of whole lung exploration and our second concern was the possibility of stapling at the exact locations of the bullae and blebs. Although we located the bullae and blebs with high-resolution computed tomography, they may not be visible with s-VATS, which could result in recurrence after surgery. However, as seen in Table 2, our concerns were unfounded. The number of wedge resections showed no statistically significant difference between the 2 groups. However, the number of the staples used for the operation was higher in the t-VATS group; we assume that the convenience of stapler access through multiple ports resulted in more staplers used for wedge resections. In t-VATS, we used the most optimal port for the wedge resection. In s-VATS, we had no choice but to use the single port. Before attempting s-VATS for PSP in our institution, we simply thought we would use fewer staplers in t-VATS since we approached

through the optimal site. However, in practical experience, in s-VATS, we used the stapler with more precise aiming since we only had a single port. On the contrary, in t-VATS, we expended less effort in aiming because we could easily access other ports. As a result, we may presume that surgeons tended to invest more effort into accuracy and efficiency for wedge resections in s-VATS. Additionally, we expected that s-VATS would have a longer operative time because all the instruments were inserted through a single incision site. We had a short learning curve (approximately 10 cases) to establish the surgical technique and a pattern of harmonious cooperation with the surgical assistant. As shown in Table 2, s-VATS had a significantly shorter operative time. In t-VATS, we created 3 port sites, closed 2 port sites, and left 1 for the chest tube. In s-VATS, we created a single port site and left it open for the chest tube. As stated above, the number of wedge resections showed no statistically significant difference between the 2 groups. After the learning curve, the operative time depended on creating and closing the port sites. The operative time can also be prolonged if bleeding control is needed at the port site, which is more likely with t-VATS.

In this study, we focused on operative outcomes and the recurrence of pneumothorax to determine whether s-VATS could be applied as a first-line surgical treatment for PSP. This study was a retrospective review, and there was a period during which t-VATS and s-VATS overlapped. Subsequently, since s-VATS was our default technique, difficult cases may have been treated with t-VATS, while easier cases may have been treated with s-VATS. To avoid this possibility of selection bias, we excluded t-VATS performed after adopting the s-VATS approach.

Because s-VATS was adopted recently, the t-VATS group had a longer follow-up duration. Thus, a simple parallel comparison of recurrence rates between t-VATS and s-VATS is meaningless. Fig. 1 shows the Kaplan-Meier curves for recurrence-free survival. Even though the 1-year rates of recurrence and recurrence requiring intervention in the 2 groups were not significantly different, longer follow-up needs to be performed.

In conclusion, when s-VATS was compared with t-VATS for PSP, no significant differences were found in operative outcomes or recurrence. Thus, we cau-

tiously suggest that s-VATS could be an appropriate alternative for t-VATS in the treatment of PSP. To confirm the clinical efficiency of s-VATS for PSP, a prospective randomized controlled trial with a longer follow-up duration is required. Moreover, advancements in s-VATS instruments and the accumulation of further surgical experience will also lead to the wider application of s-VATS.

This study has several limitations. First, this study was a retrospective analysis. Second, its statistical power may be weak because the number of subgroups was small and the follow-up duration was relatively short. Third, as s-VATS was performed more recently than t-VATS, the follow-up duration between the groups was inevitably significantly different, and the follow-up duration for s-VATS might be too short for a secure conclusion to be reached.

### Conflict of interest

No potential conflicts of interest relevant to this article are reported.

### Acknowledgments

This study was supported by a Grant of the Samsung Vein Clinic Network (Daejeon, Anyang, Cheongju, Cheonan; Fund no. KTCS04-068).

### References

1. Ng CS, Lee TW, Wan S, Yim AP. *Video assisted thoracic surgery in the management of spontaneous pneumothorax: the current status*. Postgrad Med J 2006;82:179-85.
2. Ng CS. *Single-port thoracic surgery: a new direction*. Korean J Thorac Cardiovasc Surg 2014;47:327-32.
3. Salati M, Brunelli A, Xiume F, et al. *Uniportal video-assisted thoracic surgery for primary spontaneous pneumothorax: clinical and economic analysis in comparison to the traditional approach*. Interact Cardiovasc Thorac Surg 2008;7:63-6.
4. Jutley RS, Khalil MW, Rocco G. *Uniportal vs standard three-port VATS technique for spontaneous pneumothorax: comparison of post-operative pain and residual paraesthesia*. Eur J Cardiothorac Surg 2005;28:43-6.
5. Yang HC, Cho S, Jheon S. *Single-incision thoracoscopic surgery for primary spontaneous pneumothorax using the SILS port compared with conventional three-port surgery*. Surg Endosc 2013;27:139-45.
6. Wiwanitkit V. *Single-port video-assisted thoracic surgery for primary spontaneous pneumothorax*. Korean J Thorac Cardiovasc Surg 2015;48:155.
7. Chong Y, Cho HJ, Kang SK, et al. *Outcomes of the tower crane technique with a 15-mm trocar in primary spontaneous pneumothorax*. Korean J Thorac Cardiovasc Surg 2016;49:80-4.
8. Kim MS, Yang HC, Bae MK, Cho S, Kim K, Jheon S. *Single-port video-assisted thoracic surgery for secondary spontaneous pneumothorax: preliminary results*. Korean J Thorac Cardiovasc Surg 2015;48:387-92.
9. Lee S, Kim HR, Cho S, et al. *Staple line coverage after bullectomy for primary spontaneous pneumothorax: a randomized trial*. Ann Thorac Surg 2014;98:2005-11.
10. Kang DK, Min HK, Jun HJ, Hwang YH, Kang MK. *Early outcomes of single-port video-assisted thoracic surgery for primary spontaneous pneumothorax*. Korean J Thorac Cardiovasc Surg 2014;47:384-8.
11. Levi JF, Kleinmann P, Riquet M, Debesses B. *Percutaneous parietal pleurectomy for recurrent spontaneous pneumothorax*. Lancet 1990;336:1577-8.
12. Rocco G, Martin-Ucar A, Passera E. *Uniportal VATS wedge pulmonary resections*. Ann Thorac Surg 2004;77:726-8.