

Custom-made Hydroxyapatite Cranioplasty: Radiological and Histological Evidence of Bone-Biomaterial Osteointegration in Five Patients

Abstract

Custom-made cranial implants facilitate the surgical reconstruction of destructive pathologies of the skull or extensive demolitive skull surgery. Customized cranioplasty allows for an immediate restoration of the functional integrity of the cranial defect (*restitutio ad integrum*), with excellent functional and esthetic outcome and a quick, safe, and simple procedure. In this context, bioceramics like hydroxyapatite (HA) claim high biocompatibility and bone-binding capability. The osteoconductive properties of the HA have been reported in animal models and humans. The purpose of this study is to demonstrate with radiological and histological examination and how HA prosthesis may integrate after their implantation showing data related to five patients that needed primary HA cranial reconstruction with secondary removal after few years. The histological examination showed neo-formed lamellar/trabecular bone tissue fragments accompanied by the amorphous reticular tissue (HA prosthesis) revealing diffuse ossification sites in all included cases.

Keywords: Cranioplasty, custom made, hydroxyapatite, osteointegration

Introduction

Cranial reconstruction or cranioplasty is a complex and very important surgical procedure aimed to restore the integrity of the skull after bone flap removal.^[1-3] The use of autologous graft as well as alloplastic or combined materials is suitable for cranial defects reconstruction caused by traumas, vascular diseases, congenital malformations, and tumors. Alloplastic materials are usually preferred in case of complex cranial reconstructions, revision surgery for infection, tumor relapse, or autologous bone reabsorption.^[3-7]

High-quality synthetic materials and custom-made implants are progressively chosen in an increasing number of cases. Custom-made cranial implants, for instance, may facilitate the surgical reconstruction of the skull with less morbidity and faster patient recovery.^[8]

Graft integration is one of the main goals of cranial reconstruction, and biomimetic materials with porous or trabecular structure can allow osteoconduction, with promotion of osteoblastic migration across the prosthesis, as shown *in vitro* studies.^[9]

Among alloplastic materials, bioceramics such as microporous and macroporous hydroxyapatite (HA) have been extensively used as a bone-graft substitute because the crystalline phase of HA is similar to the mineral bone component.

HA is a biocompatible material and the high porosity of its structure promotes cell homing colonization and proliferation, resulting in new bone formation and device integration *in vitro*.^[9]

The osteoconductive properties of the HA have been investigated also in animal models, but only a few cases of histological analysis have been reported on humans.^[9-11]

We retrospectively analyzed the data related to five patients who underwent HA cranial reconstruction with secondary prosthesis removal after a few years. The implants were removed for tumor relapse (in three patients) or for infection (one patient). In one case, a bone-graft interface biopsy was performed. Each sample was subsequently microscopically analyzed with the primary aim to define the diagnosis of tumor relapse or infection, but at the same time, it was possible to show the bone tissue growth inside the prosthesis.

How to cite this article: Bruno Z, Angelo N, Riccardo S, Nicola Z, Stefano P, Camillo PP, et al. Custom-made hydroxyapatite cranioplasty: Radiological and histological evidence of bone-biomaterial osteointegration in five patients. *Asian J Neurosurg* 2020;15:198-203.

Submission: 09-07-2019 **Accepted:** 23-12-2019
Published: 25-02-2020

Zanotti Bruno,
Nataloni Angelo¹,
Spaggiari Riccardo²,
Zingaretti Nicola³,
Pizzolitto Stefano⁴,
Parodi Pier
Camillo³, Nicolosi
Federico⁵, Morselli
Carlotta⁶

Department of Neuroscience,
"C. Poma" Hospital, Mantova,

¹Department of Clinic,
FinCeramica Faenza, RA,

²Department of Neurosurgery,
Humanitas University, Pieve

Emanuele, ³Department of
Neurosurgery, Neurocenter,

IRCCS Humanitas Clinical
and Research Hospital,

Rozzano, MI, ³Department of
Medical Science, Clinic of

Plastic and Reconstructive
Surgery, Academic Hospital

of Udine, University of Udine,

⁴Department of Pathology,
Santa Maria della Misericordia

University Hospital Udine,
Udine, ⁶Department of

Neuroscience, Sapienza
University of Rome, Rome, Italy

Address for correspondence:

Dr. Morselli Carlotta,

Department of Neuroscience,

Sapienza University of Rome,

Viale dell'Università 30, Rome,
Italy.

E-mail: cmorselli822@gmail.

com

Access this article online

Website: www.asianjns.org

DOI: 10.4103/ajns.AJNS_208_19

Quick Response Code:



This is an open access journal, and articles are distributed under the terms of the Creative Commons Attribution-NonCommercial-ShareAlike 4.0 License, which allows others to remix, tweak, and build upon the work non-commercially, as long as appropriate credit is given and the new creations are licensed under the identical terms.

For reprints contact: reprints@medknow.com

Patients' history

A review of existing clinical data with patient identifiers removed was performed. Our Institutional Ethics Committee approved the study design. Written informed consent was obtained from all the patients in the study or from their legal guardian.

Clinical, radiological, and histopathological data of all patients were retrospectively collected.

Each patient underwent HA cranial reconstruction after skull infiltrating meningioma excision (three patients), traumatic brain injury (one patient), and Aplasia cutis congenita with thecal involvement (one patient).

Each patient received custom-made porous HA device. The chemical composition of each prosthesis was $Ca^{10}(PO_4)^6(OH)^2-Ca/P$ di 1.67. A layer of synthetic dura mater was applied under each implant during the reconstruction procedure.

Each patient received regular follow-up visits with radiological investigations (computed tomography [CT] scan or magnetic resonance imaging [MRI]) when necessary.

The prosthesis has been removed for tumor recurrence (three patients) or for infection (1 case). In one case, the prosthesis was not removed, and a biopsy on bone-graft interface was performed for the development of a suspect neoformed irregularity (scar retraction). Prosthesis was removed after a mean of 59.4 months from implant surgery.

A CT scan with bone window was performed in each patient. A sample of HA prosthesis were histologically analyzed, and the possible evidence of fusion or osteointegration have been researched.

The biopsy was performed at the peripheral margins of the cranioplasty in two of the patients and in three patients at 3–7 cm from the margins' periphery.

No signs of metabolic diseases or allergies were collected in each patient. No medical therapies that could have interacted with the histological tests were used. No stem cell preparations, growth factors, or platelets had been used in the tests.

Relevant data regarding the five selected case studies are shown in Table 1.

Radiological examination

A CT scan with the bone window was performed in each patient. Any signs of bone-implant interface fusion or integration were collected.

Standard acquisition features include helical acquisition, 280 mA, 120 kV, step 0.9 pipe speed 0.8 and dose-length product (DLP) of about 800 mGy cm. The CT images were cut with a thickness of 0.6 mm, aiming at generating a multiplanar reconstruction.

The Hounsfield unit scale was employed to define the ossification degree of the implant in each patient. The perimeter's continuity between bone and cranioplasty was evaluated using the bone window within a WL 300–350 and WW 1500–2000 range.

Histological analysis

Each sample has been fixed it in 10% buffered formalin, and then, it was decalcified. Decalcification procedure was conducted by placing the specimen in the proper amount of decalcifying solution, which was composed of formic acid (99%) diluted in distilled water until 6% of final concentration and hydrochloric acid (37%) diluted in distilled water until 4.8% of final concentration and buffered with sodium citrate. The solution was changed on a regular basis (pH 7.5) over the following 50 days period after which the decalcification process could be considered complete.

Formalin-fixed paraffin-embedded tissue blocks were prepared, and sections were sliced on 4 μ m of thickness and stained with hematoxylin and eosin (H and E) for routine histopathological examination.

Cases results description

Between 2004 and 2015, five patients (four males and one female; average age: 60 years old) with custom-made porous HA cranioplasty devices were explanted and underwent a surgical prosthesis sample examination after an average period of 59.4 months. All the examined cranioplasties came across as large >100 cm².

The CT scan with bone window performed at the last FU showed a continuous perimeter in the bone-cranioplasty interface in all cases. The following histological examination showed neoformed lamellar/trabecular bone tissue fragments that, accompanied by amorphous reticular tissue, revealed diffuse ossification sites in all cases.

Illustrative case

A 65-year-old male patient underwent one-stage cranial demolition reconstruction for an atypical left frontotemporoparietal meningioma with skull infiltration. A custom-made prosthesis of HA (252.34 cm²) was implanted. A histopathological sampling of the lesion revealed an atypical meningotheial meningioma with a diffuse dural invasion. Proliferation index (Mib-1/Ki67): 8%.

One and 4 years after surgery, the patient received CyberKnife radiosurgery because of a relapse of the lesion on the same site.

Eighty-five months after the first treatment, MRI showed tumor progression into the residual temporal bone.

Despite preoperative CT scan showed the signs of bone-prosthesis fusion, a second surgery with HAP implant removal was required.

Table 1: Clinical, preoperative and postoperative data of the 5 include patients

Patient	Age (years)	Sex	First diagnosis	Comorbidity	Medical therapy	Site of cranioplasty	Area (cm ²)	Dural repair	Other treatments	Time of biopsy (months)	Second surgery	Biopsy	Histological examination
1	65	Male	Meningioma WHO II	Epilepsy	AEDs	None	252.34	Synthetic Lyodura®	CyberKnife+RT85	RT85	Meningioma relapse	6 cm from the edge of the cranioplasty	Amorphous matrix that presented a lamellar structure with neofomed bone lamellar tissue and meningiomatous neoplastic tissue
2	60	Male	Meningioma WHO III	None	None	None	235.62	Synthetic Tissudura®	Gamma Knife	48	Meningioma relapse	7 cm from the edge of the cranioplasty	Neofomed bone lamellar tissue integrated within amorphous prosthetic lamellar material
3	55	Male	Posttraumatic bone defect	Epilepsy Hypertension	AEDs	None	2.02	Synthetic (not specified)	-	43	Cicatricial retraction	1 cm from the edge of the cranioplasty	Fibrous and sclerotic tissue Irregular island of the lamellar bone was integrated within amorphous prosthetic alveolar-lamellar material
4	11	Male	Bone aplasia and cutaneous -cranio lacunae	Psychomotor retardation	None	None	159.50	Synthetic (not specified)	-	13	Prosthesis infection	0.5 cm from the edge of the cranioplasty	Neofomed trabecular bone tissue integrated within amorphous prosthetic alveolar-lamellar material
5	45	Female	Meningioma WHO III	None	None	None	291.73	Synthetic Duraform®	Gamma Knife	109	Meningioma relapse and fluid collection	3 cm from the edge of the cranioplasty	Irregular neofomed bony lamellae within an amorphous lamellar material and meningiomatous neoplastic tissue

Clinical, preoperative and postoperative data of the presented patients. AEDs – Anti-epileptic drugs; RT – : Radiotherapy

Intraoperative macroscopical implant showed signs of bone adhesion and fusion near the edges.

Histological examination showed an amorphous matrix containing a lamellar structure with neoformed bone lamellar tissue and meningiomatous neoplastic tissue [Figure 1 – H and E, $\times 10$].

Seven years after the first surgery, the patient underwent stereotactic radiosurgery due to a new meningioma relapse with 7 Gy/die fractions and up to 21 Gy total. During the clinical course of the treatment, the patient developed epilepsy with focal seizure.

Discussion

HA implants have demonstrated their ability to recolonize the bone in cranial and maxillofacial reconstruction.^[12]

Among alloplastic materials, macroporous hydroxyapatite is characterized by the presence of micro, macro, and interconnecting pores, mimicking the structure of the living bone.

Custom-made high porosity HA prosthesis implants are characterized by the pores of various size (ranges from 5 to 600 μm) aimed to promote osteoconductivity with osteoblastic migration across the prosthesis and bone formation with consequent osteointegration.^[13]

This peculiar property allows the new bone to grow not only on the surface of the scaffold but also within its internal structure, thus improving the biomechanical properties of the implant.^[14]

Although these properties have been studied *in vitro*, only a few cases of histological osteointegration between the prosthesis and autologous bone were observed in humans.^[8,10]

Experiments in animals^[11] and the clinical results of some human explants^[10] have revealed that osteoblast migration to the scaffold occurs 4–8 months after the implant, with a good perimetric osteointegration.

At microscopical examination, Frassanito *et al.* showed evidence of a neo-formed bone that was still lacking a lamellar organization.^[15]

In all of our described five cases, the histological examination of the prosthesis-bone interface showed fibrous and sclerotic tissue, calcium aggregates, and amorphous material, surrounded by a sclerotic shell of lamellar material.

In our patients, probably because of the long duration between reconstruction surgery and prosthesis removal (more than 1 year), lamellar organization was observed in each sample.

Although some authors described a prevalent HA integration at the proximity of the bone/implant interface,^[10,16] other authors showed that osteointegration can also occur at a certain distance from the edges of the prosthesis in HA.^[17] In three patients of the present series, the sample was taken at 3 and 7 cm away from the margins. In these samples away from interface bone implant, island of lamellar bone integrated with amorphous alveolar-lamellar material was noted. Therefore, osteointegration can also occur at a certain distance from the edges.

With the purpose to show HA implants osteointegration, the histological specimen should be prepared avoiding decalcification because an energetic decalcification of the samples can remove the HA.^[9] In choosing the optimal method required to diagnose tumor relapse or infectious disease, each sample of our patients was instead decalcified.

Even if HA crystals can be dissolved out during decalcification process, in our population, we obtained a good demonstration and evidence of HA integration, observing that the planar/lamellar scaffold of the prostheses remains negative, and therefore, visible.

Surrounding tissues with their biological properties may play an important role to achieve osteointegration. It has been described the presence of new bone formation in the inner surface of HA cranial prosthesis, where it was in contact with the autologous dura mater.^[18] The new bone

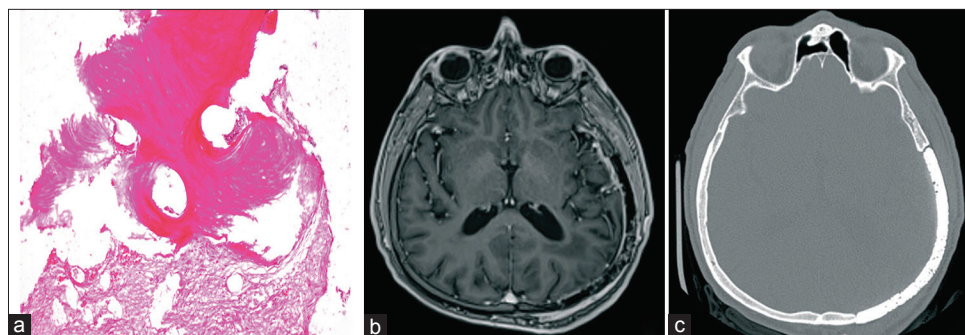


Figure 1: (a) Picture of histological examination, after decalcification of the sample showing the presence of bone tissue integrated within the prosthesis. Amorphous matrix that presented a lamellar structure with neoformed bone lamellar tissue and meningiomatous neoplastic tissue. (b) Preoperative magnetic resonance imaging with contrast enhancement showing the progression of the meningioma with bone invasion. (c) Preoperative computed tomography scan in bone window showing peripheral osteointegration

formation was described both at the margins of the HA plate (in direct contact with the skull) that in noncontact areas such as the HA plate vault and inside the pores.^[18]

In 2016, Ono *et al.*^[19] observed new bone formation *in vivo* after cranioplasty in two patients. Histological findings displayed the evidence of new bone formation not only on the margin of the implant, in direct contact with the skull, but also noncontact areas such as the implant vault or inside the pores away from the surrounding tissues.

In our series, a layer of synthetic dura mater was applied under each HA prosthesis. Therefore, the observation of osteoinduction distant from the edges does not depend only on osteoconductive proprieties of the dura layer.

According to the related literature, as histological examination is not always possible, the CT scan with bone-viewing windows is a primary diagnostic tool for the evaluation of the osteointegration between the HA and the surrounding bone.^[20,21]

In a recent comparative study by Moles *et al.*, which examined autologous and HA custom-made prosthesis in 100 patients, the authors reported that 51% of custom-bone HA prosthesis presented no signs of bone fusion at CT scan.^[20]

In our study, the use of CT scan with bone viewing helped to show the level of osteointegration between the HAP and the surrounding bone.

Nevertheless, this technique has been criticized, particularly in regard to the changes in the visibility of the prosthesis/bone continuity, including even small variations in bone window range. As we previously mentioned, the simplest and most widespread means of evaluation of an implant osteointegration is cranial CT scan with bone windows. One of the limitations of this technique is that even a slight variation of the viewing windows may change the perception of the osteointegration degree. Therefore, it is actually the histological examination procedure that proves to be decisive in this regard (when its execution is possible, of course).^[22]

Conclusions

In recent years and according to related literature, macroporous custom-bone HA prosthesis has shown good clinical results in cranial and craniofacial reconstruction. The osteoconductive properties of the HA have been reported both in animal models and humans. The CT scan with bone-viewing window and the histological examination of our sample had demonstrated that osteointegration occurs between the prosthesis and the surrounding bone and in areas located far from the prosthesis' margins. Variations in bone window range or the presence of infection or fluid collection can limit the sensibility of the radiological procedure.

Therefore, histological evaluation is decisive to confirm the activation of osteointegration process, but it is not always possible.

In the event that a sample of implanted HA has to be analyzed, it is important to carefully consider the primary reason that leads to biopsy. The possibility to demonstrate device osteointegration represents only a resource to obtain additional information on its biocompatibility and biomechanical properties.

Moreover, we obtain an optimal resolution of the bone/biomaterials interface, even if the decalcification technique was adopted.

Autologous surrounding tissues like autologous dura mater may improve osteoinduction process. When its integrity is lack, the use of a substitute of synthetic dura mater ensures adequate biomechanical protection of the brain without osteointegration process inhibition.

Declaration of patient consent

The authors certify that they have obtained all appropriate patient consent forms. In the form the patient(s) has/have given his/her/their consent for his/her/their images and other clinical information to be reported in the journal. The patients understand that their names and initials will not be published and due efforts will be made to conceal their identity, but anonymity cannot be guaranteed.

Financial support and sponsorship

Nil.

Conflicts of interest

There are no conflicts of interest.

References

1. Stefani R, Esposito G, Zanotti B, Iaccarino C, Fontanella MM, Servadei F. Use of "custom made" porous hydroxyapatite implants for cranioplasty: Postoperative analysis of complications in 1549 patients. *Surg Neurol Int* 2013;4:12.
2. Servadei F, Iaccarino C. The therapeutic cranioplasty still needs an ideal material and surgical timing. *World Neurosurg* 2015;83:133-5.
3. Honeybul S, Ho KM, Gillett GR. Reconsidering the role of decompressive craniectomy for neurological emergencies. *J Crit Care* 2017;39:185-9.
4. Goiato MC, Pesqueira AA, Ramos da Silva C, Gennari Filho H, Micheline Dos Santos D. Patient satisfaction with maxillofacial prosthesis. Literature review. *J Plast Reconstr Aesthet Surg* 2009;62:175-80.
5. Zanotti B, Zingaretti N, Verlicchi A, Robiony M, Alfieri A, Parodi PC. Cranioplasty: Review of materials. *J Craniofac Surg* 2016;27:2061-72.
6. Moreira-Gonzalez A, Jackson IT, Miyawaki T, Barakat K, DiNick V. Clinical outcome in cranioplasty: Critical review in long-term follow-up. *J Craniofac Surg* 2003;14:144-53.
7. Schoekler B, Trummer M. Prediction parameters of bone flap resorption following cranioplasty with autologous bone. *Clin Neurol Neurosurg* 2014;120:64-7.

8. Frassanito P, De Bonis P, Mattogno PP, Mangiola A, Novello M, Brinchi D, *et al.* The fate of a macroporous hydroxyapatite cranioplasty four years after implantation: Macroscopical and microscopical findings in a case of recurrent atypical meningioma. *Clin Neurol Neurosurg* 2013;115:1496-8.
9. Fricia M, Passanisi M, Salamanna F, Parrilli A, Giavaresi G, Fini M. Osteointegration in custom-made porous hydroxyapatite cranial implants: From reconstructive surgery to regenerative medicine. *World Neurosurg* 2015;84:591.e11-6.
10. Messina G, Dones I, Nataloni A, Franzini A. Histologically demonstrated skull bone integration in a hydroxyapatite prosthesis in a human. *Acta Neurochir (Wien)* 2011;153:1717-8.
11. Kon E, Muraglia A, Corsi A, Bianco P, Marcacci M, Martin I, *et al.* Autologous bone marrow stromal cells loaded onto porous hydroxyapatite ceramic accelerate bone repair in critical-size defects of sheep long bones. *J Biomed Mater Res* 2000;49:328-37.
12. Sahoo NK, Mohan N, Tomar K, Bhat S. Classification of the residual cranial defects and selection of reconstruction materials. *J Craniofac Surg* 2017;28:1694-701.
13. Rawlings CE 3rd. Modern bone substitutes with emphasis on calcium phosphate ceramics and osteoinductors. *Neurosurgery* 1993;33:935-8.
14. Affi AM, Gordon CR, Pryor LS, Sweeney W, Papay FA, Zins JE. Calcium phosphate cements in skull reconstruction: A meta-analysis. *Plast Reconstr Surg* 2010;126:1300-9.
15. Frassanito P, Tamburrini G, Massimi L, Di Rocco C, Nataloni A, Fabbri G, *et al.* Post-marketing surveillance of custom bone service implanted in children under 7 years old. *Acta Neurochir (Wien)* 2015;157:115-21.
16. Hardy H, Tollard E, Derrey S, Delcampe P, Péron JM, Fréger P, *et al.* Clinical and ossification outcome of custom-made hydroxyapatite prothese for large skull defect. *Neurochirurgie* 2012;58:25-9.
17. Brie J, Chartier T, Chaput C, Delage C, Pradeau B, Caire F, *et al.* A new custom made bioceramic implant for the repair of large and complex craniofacial bone defects. *J Craniomaxillofac Surg* 2013;41:403-7.
18. Okii N, Nishimura S, Kurisu K, Takeshima Y, Uozumi T. *In vivo* histological changes occurring in hydroxyapatite cranial reconstruction--case report. *Neurol Med Chir (Tokyo)* 2001;41:100-4.
19. Ono H, Sase T, Tanaka Y, Takasuna H. Histological assessment of porous custom-made hydroxyapatite implants 6 months and 2.5 years after cranioplasty. *Surg Neurol Int* 2017;8:8.
20. Moles A, Heudes PM, Amelot A, Cristini J, Salaud C, Roualdes V, *et al.* Long-term follow-up comparative study of hydroxyapatite and autologous cranioplasties: Complications, cosmetic results, osseointegration. *World Neurosurg* 2018;111:e395-402.
21. Staffa G, Nataloni A, Compagnone C, Servadei F. Custom made cranioplasty prostheses in porous hydroxy-apatite using 3D design techniques: 7 years experience in 25 patients. *Acta Neurochir (Wien)* 2007;149:161-70.
22. Zanotti B, Verlicchi A, Robiony M, Parodi PC. Surgical calvarial demolition and reconstruction: Procedure, implants and results. In: Zanotti B, Verlicchi A, Parodi PC, editors. *Cranial Demolition and Reconstruction. Cranioplasty in One Step*. New Magazine Edizioni. Trento: Topics in Medicine; 2010.