

Rapid aneurysm growth after transarterial chemoembolization

Kirsten Dansey, BS,^a Mathew Wooster, MD,^b Alexis Powell, MD,^b Eduardo Rodriguez, MD,^b Bruce Zwiebel, MD,^c and Murray Shames, MD,^b *Tampa, Fla*

Chemotherapy has been anecdotally related to aneurysm growth, but no correlation has been noted to date for localized transarterial chemoembolization. We present the case of a 64-year-old man with clearly documented accelerated aortic and iliac artery aneurysm dilation after two rounds of transarterial chemoembolization for hepatocellular carcinoma. Given the large size with rapid growth of his aneurysms and inability to be listed for transplant consideration before repair, he was offered endovascular repair and was successfully treated. (*J Vasc Surg Cases* 2015;1:65-7.)

Anecdotal reports have demonstrated an association between chemotherapy and accelerated aneurysmal growth.^{1,2} However, such a report has not been noted related to transarterial chemoembolization (TACE). Localized TACE therapy requires significantly lower doses of the chemotherapeutic agent, theoretically reducing the systemic effects. We report the first clearly documented case of significant, rapid aneurysmal dilatation after TACE. The patient consented to publication.

CASE REPORT

A 64-year-old Caucasian man was referred to our clinic for evaluation of aortoiliac aneurysmal disease identified during workup for a liver transplant. The patient's medical history was significant for hepatocellular carcinoma (HCC) secondary to hepatitis C, portal hypertension, chronic obstructive pulmonary disease, and a resolved hepatitis B infection. He received treatment with ribavirin and interferon for hepatitis C, resulting in an undetectable viral load for 11 months leading up to his presentation. Of note, he had no prior or family history of aneurysmal diseases or vasculitides.

On initial magnetic resonance imaging during the HCC workup, a noninflammatory infrarenal aneurysm measuring 3.9 cm was identified in November 2013, with a right common iliac artery (RCIA) aneurysm measuring 3.3 cm and a left common iliac artery (LCIA) measuring 2.3 cm (Fig 1).

Three rounds of TACE were performed over the course of 5 months while the patient was being evaluated for liver transplantation. During round one (March 2014), doxorubicin (50 mg)

with QuadraSphere Microspheres Merit Medical Systems Inc, South Jordan, Utah) was delivered through the right hepatic artery. Follow-up magnetic resonance imaging in April 2014 demonstrated rapid growth of the aneurysms, with the infrarenal aorta measuring 4.1 cm, the RCIA measuring 3.6 cm, and the LCIA measuring 2.8 cm (Fig 2).

During round two of TACE, doxorubicin (50 mg), lipiodol (1 mL), and LC Beads (AngioDynamics, Queensbury, NY) were administered to the right hepatic lobe. Computed tomography angiography imaging in June 2014 revealed progressive aneurysmal dilatation, with measurements of the infrarenal aorta at 4.8 cm, RCIA at 4.3 cm, and the LCIA at 3.3 cm (Fig 3).

The patient was offered endovascular repair of the aneurysm given the significant growth, the size of the aneurysm, and the transplant committee's decision to exclude the patient for liver transplantation secondary to the aneurysms. After his third TACE procedure using lipiodol (10 mL) as the sole agent, the patient elected to undergo an endovascular repair.

Off-label techniques, as previously described, were used to perform successful exclusion of the aneurysm, with bilateral hypogastric artery preservation, and he was discharged home on postoperative day 2 without incident.^{3,4}

DISCUSSION

This is the first documented case of accelerated CIA aneurysm growth after TACE treatment. TACE is an accepted treatment for unresectable HCC.⁵⁻⁷ The procedure involves gaining access to the hepatic arteries for targeted chemotherapy, theoretically allowing much lower doses of chemotherapeutic agents to be used with little to no systemic influence of the drug. Hepatic artery aneurysms developing after TACE have been reported, hypothesized to form secondary to trauma to vessels during the procedure or as a side effect of the chemotherapy itself, but no known literature has documented iliac aneurysmal growth rates after TACE.^{8,9}

Although the growth rate of CIA aneurysms is debated, the maximum reported growth rate in the literature is defined as 0.32 cm/y.^{10,11} Our patient presented with significantly greater growth. The RCIA and LCIA grew 1.0 cm during a period of just 7 months, and 0.7 cm and

From the Morsani College of Medicine,^a and the Departments of Vascular and Endovascular Surgery^b and Radiology,^c University of South Florida. Author conflict of interest: M.S. is a speaker for Medtronic and Gore.

Reprint requests: Kirsten Dansey, BS, 2 Tampa General Circle, Tampa, FL 33606 (e-mail: kdansey@health.usf.edu).

The editors and reviewers of this article have no relevant financial relationships to disclose per the Journal policy that requires reviewers to decline review of any manuscript for which they may have a conflict of interest.

2352-667X

Copyright © 2015 The Authors. Published by Elsevier Inc. on behalf of the Society for Vascular Surgery. This is an open access article under the CC BY-NC-ND license (<http://creativecommons.org/licenses/by-nc-nd/4.0/>).

<http://dx.doi.org/10.1016/j.jvsc.2014.12.003>

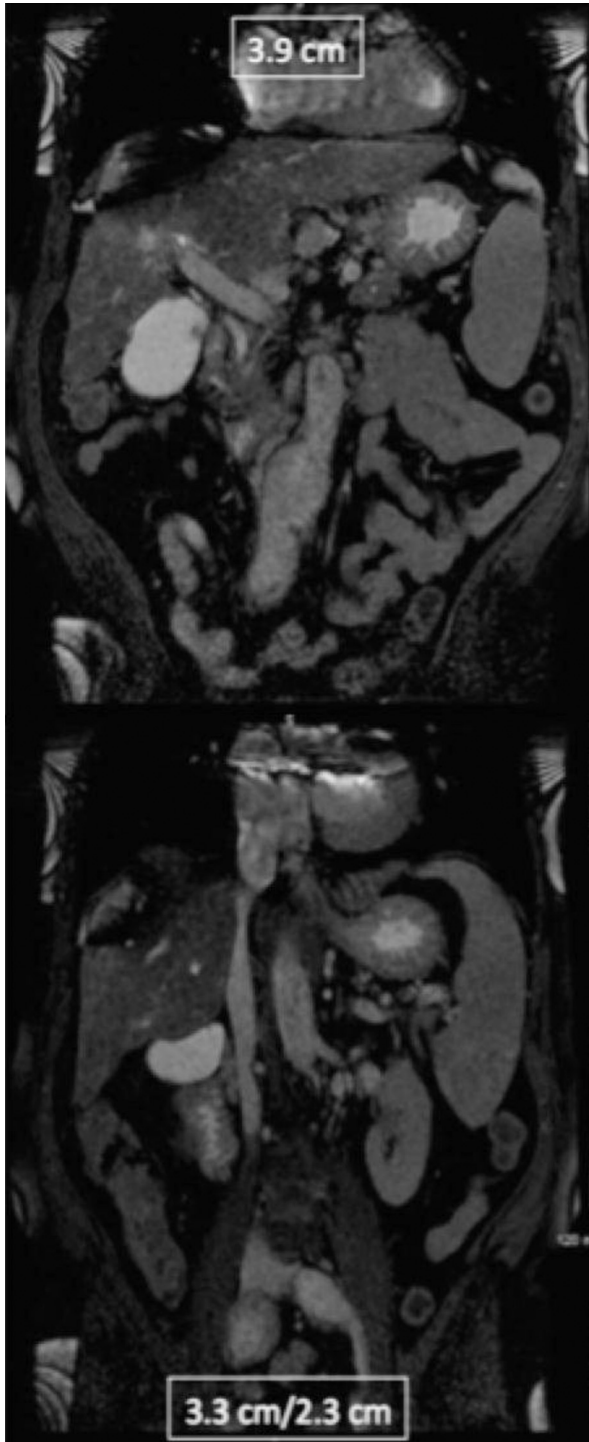


Fig 1. Magnetic resonance imaging of the abdomen and pelvis, November 2013.

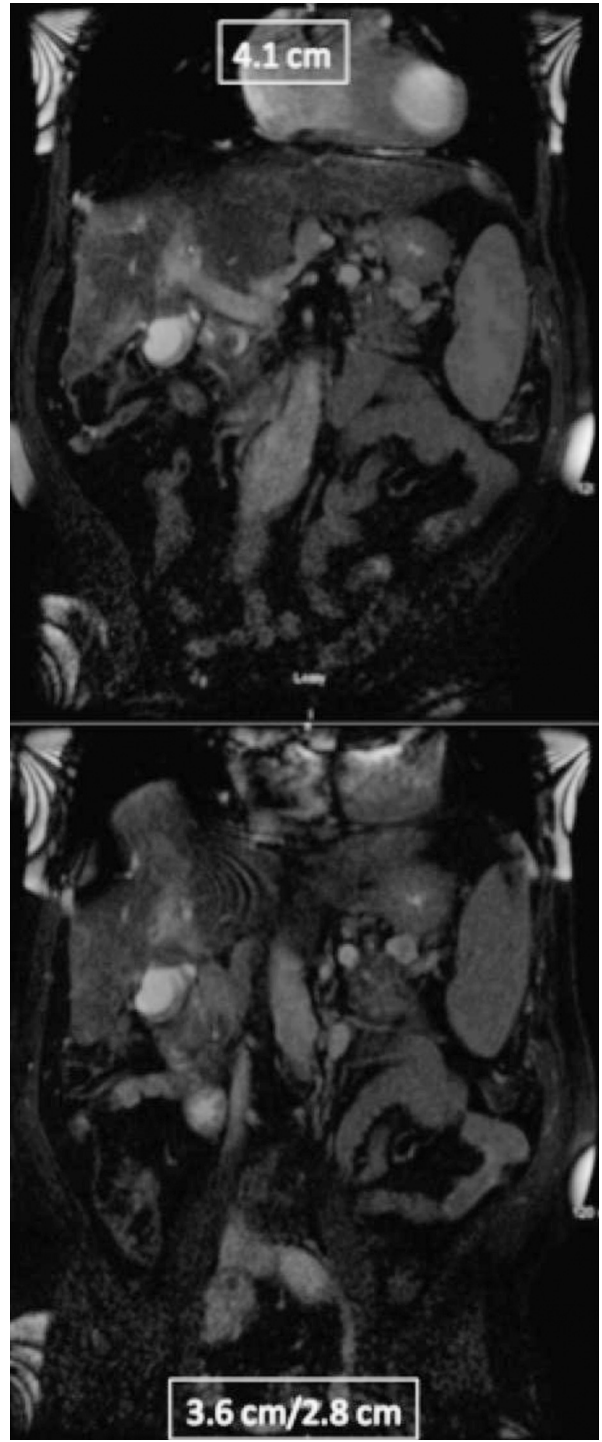


Fig 2. Magnetic resonance imaging abdomen and pelvis, April 2014.

0.5 cm, respectively, in just 1 month after two rounds of TACE. Aneurysmal disease as a result of chemotherapy is debated, with a recent report demonstrating no association between aortic aneurysm growth and chemotherapy.¹²

CONCLUSIONS

Despite this study, there remains a broadly held concern regarding the effects of these cytotoxic agents

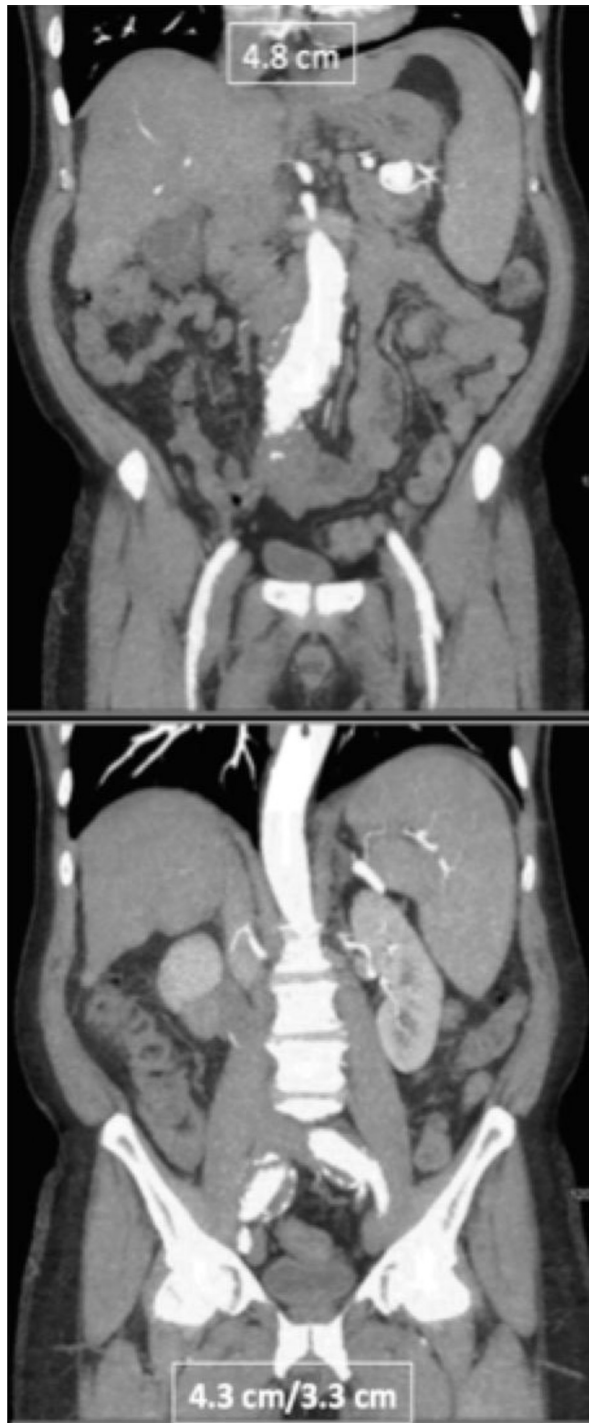

Fig 3. Computed tomography angiography of the abdomen and pelvis, June 2014.

often prompting aneurysm repair at an earlier time than would otherwise be considered. There is no prevailing explanation for aneurysmal growth with chemotherapy use; however, some have questioned altered generation of DNA, collagen and elastin, release of inflammatory markers, and disturbance in smooth muscle proliferation.¹² In theory, TACE is a localized treatment and should not have systemic effects, as are believed to be seen with other cytotoxic treatments, but this first documented incidence indicates a need for further review and awareness.

REFERENCES

1. Zanow J, Leistner Y, Ludewig S, Rauchfuss F, Settmacher U. Unusual course of an abdominal aortic aneurysm in a patient treated with chemotherapy for gastric cancer. *J Vasc Surg* 2012;55:841-3.
2. Palm SJ, Russwurm GP, Chang D, Rozenblit AM, Ohki T, Veith FJ. Acute enlargement and subsequent rupture of an abdominal aortic aneurysm in a patient receiving chemotherapy for pancreatic carcinoma. *J Vasc Surg* 2000;32:197-200.
3. Minion DJ, Xenos E, Sorial E, Saha S, Edeand ED. The trifurcated endograft technique for hypogastric preservation during endovascular aneurysm repair. *J Vasc Surg* 2008;47:658-61.
4. Cuff R, Banegas S, Mansour A, Chambers C, Wong P, Slaikeu J. Endovascular repair of bilateral common iliac artery aneurysms following open abdominal aortic aneurysm repair with preservation of both hypogastric arteries using commercially available stent grafts. *J Vasc Surg* 2014;59:516-9.
5. Camma C, Schepis F, Orlando A, Albanese M, Shahied L, Trevisani F, et al. Transarterial chemoembolization for unresectable hepatocellular carcinoma: meta-analysis of randomized controlled trials. *Radiology* 2002;224:47-54.
6. Llovet JM, Real MI, Montana X, Planas R, Coll S, Aponte J, et al. Arterial embolisation or chemoembolisation versus symptomatic treatment in patients with unresectable hepatocellular carcinoma: a randomised controlled trial. *Lancet* 2002;359:1734-9.
7. Jelic S, Sotiropoulos GC, Group EGW. Hepatocellular carcinoma: ESMO clinical practice guidelines for diagnosis, treatment and follow-up. *Ann Oncol* 2010;21(Suppl 5):v59-64.
8. Sueyoshi E, Hayashida T, Sakamoto I, Uetani M. Vascular complications of hepatic artery after transcatheter arterial chemoembolization in patients with hepatocellular carcinoma. *AJR Am J Roentgenol* 2010;195:245-51.
9. Sakamoto I, Aso N, Nagaoki K, Matsuoka Y, Uetani M, Ashizawa K, et al. Complications associated with transcatheter arterial embolization for hepatic tumors. *Radiographics* 1998;18:605-19.
10. Huang Y, Glociczki P, Duncan AA, Kalra M, Hoskin TL, Oderich GS, et al. Common iliac artery aneurysm: expansion rate and results of open surgical and endovascular repair. *J Vasc Surg* 2008;47:1203-10; discussion: 1210-1.
11. Santilli SM, Wernsing SE, Lee ES. Expansion rates and outcomes for iliac artery aneurysms. *J Vasc Surg* 2000;31:114-21.
12. Martin ZL, Mastracci TM, Greenberg RK, Morales JP, Bena J. The effect of chemotherapy for malignancy on the natural history of aortic aneurysm. *J Vasc Surg* 2015;61:50-7.

Submitted Oct 27, 2014; accepted Dec 22, 2014.