

# Surgical Repair of Aortocaval Fistula Presenting with Cardiogenic Shock

In Ha Kim, M.D.<sup>1</sup>, Ho-Ki Min, M.D.<sup>1</sup>, Ji Yong Kim, M.D.<sup>1</sup>, Dong-Kie Kim, M.D.<sup>2</sup>,  
Do Kyun Kang, M.D.<sup>1</sup>, Hee Jae Jun, M.D.<sup>1</sup>, Youn-Ho Hwang, M.D.<sup>1</sup>

<sup>1</sup>Department of Thoracic and Cardiovascular Surgery and <sup>2</sup>Division of Cardiology, Department of Internal Medicine, Inje University Haeundae Paik Hospital, Inje University College of Medicine

Aortocaval fistula (ACF) occurs in <1% of all abdominal aortic aneurysms (AAAs), and in 3% to 7% of all ruptured AAAs. The triad of clinical findings of AAA with ACF are abdominal pain, abdominal machinery bruit, and a pulsating abdominal mass. Other findings include pelvic venous hypertension (hematuria, oliguria, scrotal edema), lower-limb edema with or without arterial insufficiency or venous thrombus, shock, congestive heart failure, and cardiac arrest. Surgery is the main treatment modality. We report successful surgical treatment in a patient with a ruptured AAA with ACF who presented with cardiogenic shock.

**Key words:** 1. Abdominal aortic aneurysm  
2. Arteriovenous fistula  
3. Cardiogenic shock

## Case report

A 50-year-old man without any underlying disease was transferred to Haeundae Paik Hospital for abdominal pain and palpitations. His vital signs were unremarkable except for tachycardia, with a heart rate of around 120 bpm. A huge pulsating abdominal mass was present on physical examination. Laboratory tests were within the normal range, except for elevated cardiac enzymes and renal function test findings (creatinine kinase-MB, 4.9 ng/mL; troponin I, 0.30 ng/mL; serum creatinine, 1.61 mg/dL). An electrocardiogram showed sinus tachycardia without ST-segment changes. Contrast-enhanced abdominal computed tomography (CT) revealed an infrarenal abdominal aortic aneurysm (AAA) measuring 9×8 cm with a posterior wall defect, as well as communication between the aorta and the inferior vena cava

(IVC) just above the iliac bifurcation (Fig. 1). Moreover, early enhancement of the IVC and hepatic vein was found, suggesting an aortocaval fistula (ACF). Abdominal pain and palpitation continued throughout the examinations. Sudden changes in the color of the lower extremities and cardiac arrest occurred after the radiologic tests. Immediate cardiopulmonary resuscitation was performed and the patient recovered after 5 minutes. Without further evaluation, an emergency operation was performed.

The central venous pressure after general anesthesia was 23 mm Hg. After median laparotomy, there was no hematoma in the retroperitoneal space, but there was a hematoma around the aorta, which was interpreted as a sign of rupture. The abdominal aorta, IVC, and both common iliac arteries and veins were exposed and clamped. A vertical incision was then made in the abdominal aorta. The organized

Received: March 16, 2018, Revised: September 2, 2018, Accepted: September 4, 2018, Published online: December 5, 2018

Corresponding author: Ho-Ki Min, Department of Thoracic and Cardiovascular Surgery, Inje University Haeundae Paik Hospital, Inje University College of Medicine, 875 Haeun-daero, Haeundae-gu, Busan 48108, Korea  
(Tel) 82-51-797-3135 (Fax) 82-51-797-3135 (E-mail) [minhoki@naver.com](mailto:minhoki@naver.com)

© The Korean Society for Thoracic and Cardiovascular Surgery. 2018. All right reserved.

© This is an open access article distributed under the terms of the Creative Commons Attribution Non-Commercial License (<http://creativecommons.org/licenses/by-nc/4.0>) which permits unrestricted non-commercial use, distribution, and reproduction in any medium, provided the original work is properly cited.

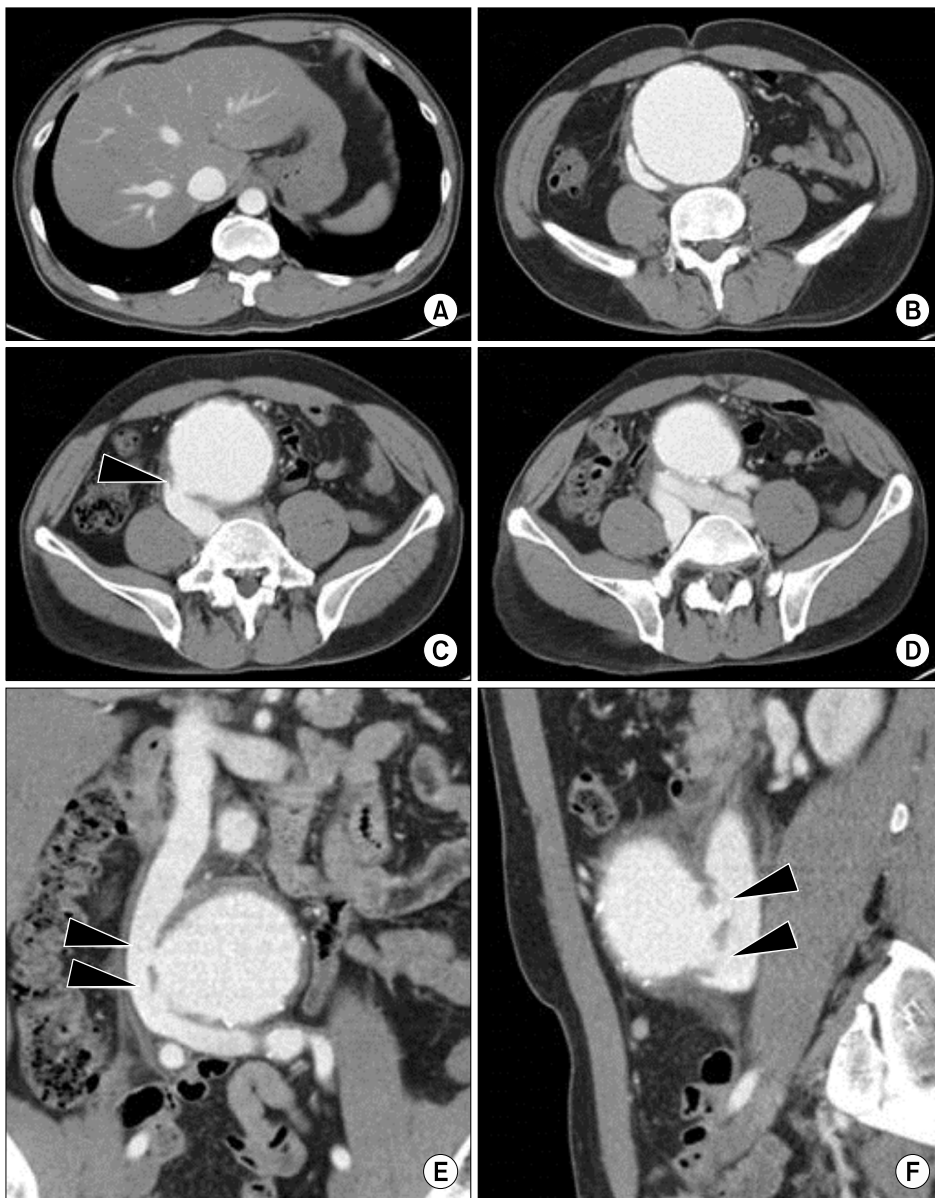


Fig. 1. Contrast-enhanced abdominal computed tomography shows the abdominal aorta and its relation to the IVC. (A) Early enhancement of the hepatic vein and the IVC in the arterial phase is observed. (B) The IVC is collapsed because of the abdominal aortic aneurysm with a maximum diameter of 9 cm. (C, E, F) A wall defect and fistulous communication (arrowheads) between the aorta and the IVC are revealed on the axial plane, coronal plane, and sagittal plane, respectively. (D) Early enhancement and dilatation of both common iliac veins are revealed. IVC, inferior vena cava.

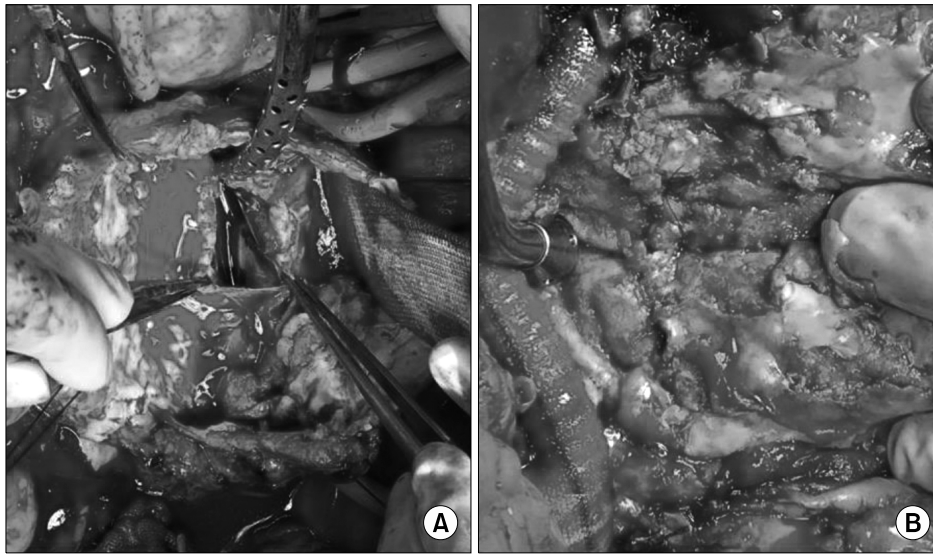
thrombus was gently removed and the collateral artery was obliterated. The entrance of the fistula between the posterior wall of the aorta and the IVC was revealed (Fig. 2). The fistula was 4–5 cm long, and there was no dissection of the IVC and no thrombus in the fistula. When declamping of the IVC was performed, massive venous bleeding was observed from the fistula, as expected. The fistula was directly closed within the aortic lumen by a 4-0 polypropylene continuous running suture. The abdominal aorta was replaced with a prosthetic bifurcated graft (Intergard, 16×8×50 mm; Maquet Cardiovascular,

Wayne, NJ, USA). The patient's postoperative course was uneventful, and hepatic function and renal function recovered immediately after surgery. He was discharged on postoperative day 10 without complications.

IRB was exempted. Written informed consents were obtained.

### Discussion

ACF is spontaneous in 80% of cases, and it occurs in <1% of all AAAs and 3% to 7% of all ruptured AAAs [1,2]. ACF was first reported by Syme in 1831,



**Fig. 2.** (A) After opening the aneurysmal sac and removing the organized thrombus, the aorticocaval fistula between the aorta and the IVC was revealed. The defect was located between the posterolateral wall of the aorta and the IVC and its size was approximately 4-5 cm in length. Dark deoxygenated blood was observed in the fistula. (B) Direct suture closure was performed to repair the aorticocaval fistula. IVC, inferior vena cava.

and the first successful repair was performed by DeBakey and his colleagues in 1954 [3]. The hemodynamics of ACF are derived from the diversion of blood flow from the high-resistance arterial circulation to the low-resistance venous circulation through the fistula. It causes a decrease in total peripheral resistance and an increase in venous pressure and preload, which results in an increase in heart rate, stroke volume, and cardiac output. If this situation continues, heart failure can occur. Shock or cardiac arrest can occur, as in our case, if this process occurs suddenly because of rupture without compensation. Furthermore, elevated renal venous pressure causes a reduction in renal arterial perfusion pressure and activation of the renin-angiotensin-aldosterone system. This results in intravascular volume expansion and exacerbates congestive heart failure [3]. It has been reported that 35% of patients with ACF developed congestive heart failure [2]. Unstable hemodynamics, such as shock and cardiac arrest, may be observed in decompensated patients with a large amount of shunt through the fistula. Furthermore, rupture of the AAA can accelerate the decompensation, as in our case. Lower-extremity and pelvic venous hypertension are also consequences of ACF [3].

These hemodynamic changes cause various clinical symptoms and signs. The triad of clinical findings of AAA with ACF are abdominal or lower back pain, abdominal machinery bruit, and a pulsating abdominal

mass. Other findings include pelvic venous hypertension (hematuria, oliguria, scrotal edema), lower-extremity edema with or without arterial insufficiency or venous thrombus, shock, and congestive heart failure [1-6]. In a previous study, symptoms were found in most patients, but only 17% of the patients had all components of the classic triad of clinical findings. [4]. In addition, about half of the patients had no classical symptoms [2]. Elevated central venous pressure is also observed, but it sometimes may be within the normal range or even low [3].

A precise preoperative diagnosis can be possible if the classic findings are observed, but if these findings are absent or the situation is urgent, the diagnosis may be ambiguous. Contrast-enhanced CT is the gold standard for the diagnosis of AAA [1]. It allows the visualization of several distinctive features of AAA with an ACF. A large aneurysm more than 8 cm, pelvic venous dilatation, and an early enhancement of the IVC or hepatic vein in the arterial phase of contrast-enhanced CT are observed in most AAA patients with an ACF [5]. In addition, wall defects between the aorta and the venous system can be revealed. Other imaging modalities include duplex ultrasonography, angiography, and magnetic resonance angiography [1,3].

In this case, abdominal auscultation was omitted and abdominal bruit was not confirmed, but the other members of the triad of classical clinical findings were observed. In addition, tachycardia, renal and

hepatic insufficiency, elevated central venous pressure, color change and edema in the lower extremities, and shock were consistent with ACF. Fortunately, in this patient, an accurate diagnosis was possible with abdominal CT, enabling a precise surgical plan to be established.

Most AAA patients with ACF require immediate surgical treatment. The most important aspect of ACF repair is proper control of venous bleeding from the fistula [3]. In order to accomplish this objective, direct manual compression of the areas proximal and distal to the IVC or the insertion of a ballooning catheter into the IVC can be performed [1,3,4]. Surgical methods to close the caval defect include direct suture closure within the aortic lumen or patch closure [1]. Depending on the size and type of AAA, and the location of the ACF, a tubular or bifurcated graft replacement can be performed to repair the aorta. In this case, successful repair was possible by clamping of the IVC and both iliac veins, followed by direct closure of the 4- to 5-cm-long fistula with concomitant bifurcated replacement of the aorta.

Reports have described using autotransfusion for massive bleeding [1,3,6]. Our operation was performed with red blood cell transfusion (5 pints) without autotransfusion.

When performing surgery for this condition, aortic cross-clamping should be performed gradually. Sudden clamping can instantaneously reduce the preload, causing arrhythmia or cardiac arrest [1]. In addition, the aorta should be carefully manipulated because migration of a thrombus or organized material through the fistula may cause pulmonary thromboembolism [1-3]

According to several reports, the surgical mortality rate varies from 16% to 66% [3,6], depending on age, underlying diseases, acute blood loss, coagulopathy, and the degree of organ failure. An accurate preoperative diagnosis is an important factor affecting the surgical mortality rate. It is known that surgical mortality decreases when an accurate preoperative diagnosis is made [2,3]. Recently, reports have described the use of endovascular techniques,

which have the advantages of being less invasive and involving less bleeding. However, complications such as type II endoleaks have been reported [7,8].

AAA with ACF is an uncommon condition that can be fatal. Making an accurate preoperative diagnosis significantly influences the likelihood of successful treatment. Treatment modalities include surgical repair and endovascular techniques. When hemodynamic instability is observed, an emergency operation should be performed. We report this case of a successful operation for AAA with ACF.

### Conflict of interest

No potential conflict of interest relevant to this article was reported.

### References

1. Nakazawa S, Mohara J, Takahashi T, Koike N, Takeyoshi I. *Aortocaval fistula associated with ruptured abdominal aortic aneurysm*. *Ann Vasc Surg* 2014;28:1793.
2. Maeda H, Umezawa H, Goshima M, et al. *Surgery for ruptured abdominal aortic aneurysm with an aortocaval and iliac vein fistula*. *Surg Today* 2007;37:445-8.
3. Davidovic L, Dragas M, Cvetkovic S, Kostic D, Cinara I, Banzic I. *Twenty years of experience in the treatment of spontaneous aorto-venous fistulas in a developing country*. *World J Surg* 2011;35:1829-34.
4. Davis PM, Gloviczki P, Cherry KJ Jr, et al. *Aorto-caval and ilio-iliac arteriovenous fistulae*. *Am J Surg* 1998;176:115-8.
5. Pevec WC, Lee ES, Lamba R. *Symptomatic, acute aortocaval fistula complicating an infrarenal aortic aneurysm*. *J Vasc Surg* 2010;51:475.
6. Cinara IS, Davidovic LB, Kostic DM, Cvetkovic SD, Jakovljevic NS, Koncar IB. *Aorto-caval fistulas: a review of eighteen years experience*. *Acta Chir Belg* 2005;105:616-20.
7. Akwei S, Altaf N, Tennant W, MacSweeney S, Braithwaite B. *Emergency endovascular repair of aortocaval fistula: a single center experience*. *Vasc Endovascular Surg* 2011;45:442-6.
8. Silveira PG, Cunha JR, Lima GB, Franklin RN, Bortoluzzi CT, Galego Gdo N. *Endovascular treatment of ruptured abdominal aortic aneurysm with aortocaval fistula based on aortic and inferior vena cava stent-graft placement*. *Ann Vasc Surg* 2014;28:1933.