

Neochordameter: A New Technology in Mitral Valve Repair

Alireza Alizadeh-Ghavidel¹, Niloofar Samiei¹, Hoda Javadikasgari^{1,*}, Kamiar Bashirpour²

¹Heart Valve Disease Research Center, Rajaie Cardiovascular Medical and Research Center, Iran University of Medical Sciences, Tehran, IR Iran

²Mechanical Engineering Departments, Amirkabir University of Technology, Tehran, IR Iran

*Corresponding author: Hoda Javadikasgari, Heart Valve Disease Research Center, Rajaie Cardiovascular Medical and Research Center, Vali-Asr Ave, Niayesh Blvd, Tehran, IR Iran. Tel: +98-9112244604, E-mail: Hoda.Javadi.K@gmail.com

Received: May 11, 2013; Revised: June 02, 2013; Accepted: June 10, 2013

Background: Mitral valve repair has shown superior results compared to mitral valve replacement in patients with mitral valve prolapse. Using premeasured neochordae (the loop technique) has been proposed for both anterior and posterior leaflet repairs. However, there are two major problems that are usually experienced using this method. One is deciding the length of the neo-chordae, and the other is tying the knot at the intended length.

Objectives: This study introduced a new technology in mitral valve repair that reduces the complexity of making neo-chordae loops, especially in minimally invasive surgeries.

Patients and Methods: Neochordameter is a new device which utilizes preoperative transthoracic echocardiography to determine the exact length of required neochordae and enable surgeons to make neochordae loops before starting the cardiopulmonary bypass. In this study, we applied this technique in mitral valve repair of three patients.

Results: Two of these patients were male and the other one was female. All of them had severe mitral regurgitation requiring anterior leaflet repair. Total eight neochordae loops were used in these patients. No change in the length of neochordae was required after saline test and all of these patients had none or trivial mitral regurgitation by intraoperative and follow up transesophageal echocardiography. No complication was seen in six-month follow up.

Conclusions: The ability of this technology in developing premeasured neo-chordae loops with accurate sizes and not needing the post-implantation length adjustment which is efficient in reducing the complexity of both minimally invasive and conventional surgeries are the issues which is going to be regarded.

Keywords: Artificial Chordae; Mitral Valve Annuloplasty; Prolapse

1. Background

Mitral valve prolapse is a common cardiac disease. Mitral valve repair (MVR) provided excellent midterm and long-term results and is considered the gold standard therapy for the patients with severe regurgitation (1). Using premeasured neo-chordae (the loop technique) has been proposed for both anterior and posterior leaflet repairs. However, there are two major problems that are usually experienced using this method. One is deciding the length of the neo-chordae, and the other is tying the knot at the intended length (2). In this study, we proposed a novel technique to address these issues.

2. Objectives

This study introduced a new technology in mitral valve repair that reduces the complexity of making neo-chordae loops, especially in minimally invasive surgeries.

3. Patients and Methods

Neochordameter is a new device for making neo-chordae loops before starting the cardiopulmonary bypass. This device is setup using preoperative transthoracic echocardiography (TTE) views. We used TTE instead of transesophageal echocardiography (TEE) since left ventricular foreshortening is more serious in TEE rather than in TTE (3, 4). Anterior/posterior, medial/lateral, and base to apex views provide the best images for determining the exact geometry of each patient's left ventricular apparatus. Two-chamber view (medial/lateral view) provides the distance between the tip of each papillary muscle and the coaptation point (Figure 1). Four-chamber view provides the anterior distance between the tip of anterolateral papillary muscle and the coaptation point (Figure 2). Apical long axis provides the posterior distance between the tip of posteromedial papillary muscle and the coaptation point (Figure 3). Neochordameter is setup using these distances.

Implication for health policy/practice/research/medical education:

This study introduced a new technology in mitral valve repair that reduces the complexity of making neo-chordae loops, especially in minimally invasive surgeries.

Copyright © 2013, Rajaie Cardiovascular Medical and Research Center, Iran University of Medical Sciences, Tehran, Iran; Published by Kowsar Corp. This is an open-access article distributed under the terms of the Creative Commons Attribution License (<http://creativecommons.org/licenses/by/3.0>), which permits unrestricted use, distribution, and reproduction in any medium, provided the original work is properly cited.

A semi-lunar blade is designed in this device which models the free edge of anterior and posterior mitral valve leaflets (Figure 4 A). Several grooves are defined at each four millimeter distance on each free edge. They model the suture position on the free edge of patient's mitral valve leaflets. A clamp (Figure 4 B) is designed for keeping the pledgete (considered the tip of the papillary muscle). The position of the clamp related to the center of semi-lunar blade can be changed (considered the coaptation point) based on the TTE measurements and enable the device to model the left ventricular geometry for each patient. This technique was applied for three patients who were candidate for MVR. The protocol of this study was approved by the Local Ethics Committee and a written informed consent was obtained from all patients. Neochordameter was set for each patient based on his/her individual preoperative TTE. Neochordae loops were made before starting cardiopulmonary bypass with regard to the position of prolapsed scallop in preoperative TTE. Saline test and intraoperative transesophageal echocardiography (TEE) were used to evaluate this technique. Ring annuloplasty was done for all patients.

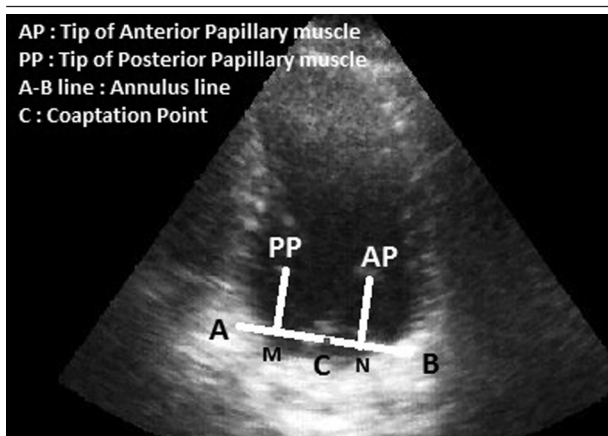


Figure 1. Two-Chamber View in Transthoracic Echocardiography

C-M and C-N lines demonstrate the distance between coaptation point and the tip of posteromedial and anterolateral papillary muscle, respectively.

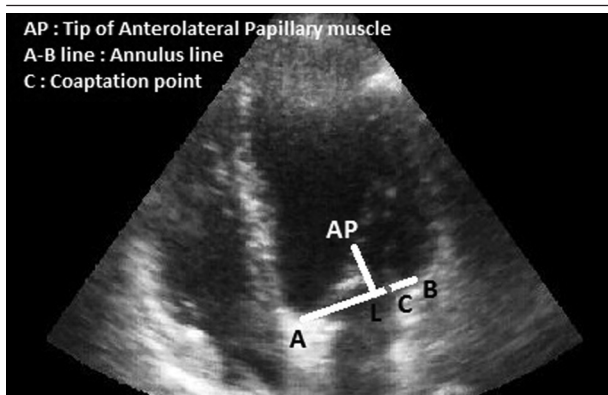


Figure 2. Four-Chamber View in Transthoracic Echocardiography

C-L line demonstrates the anterior distance between coaptation point and the tip of anterolateral papillary muscle.

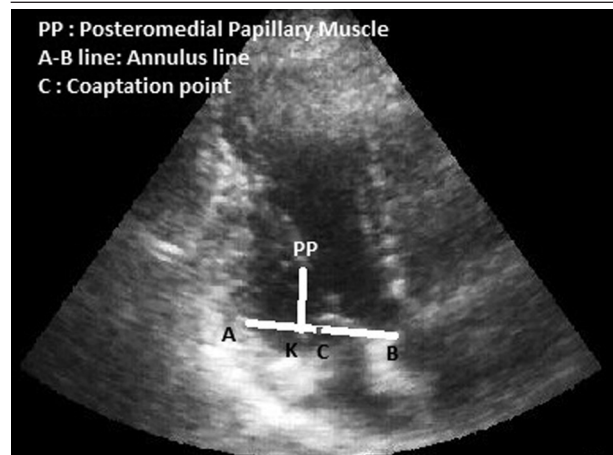


Figure 3. Apical Long Axis View in Transthoracic Echocardiography

C-K line demonstrates the posterior distance between coaptation point and posteromedial papillary muscle.

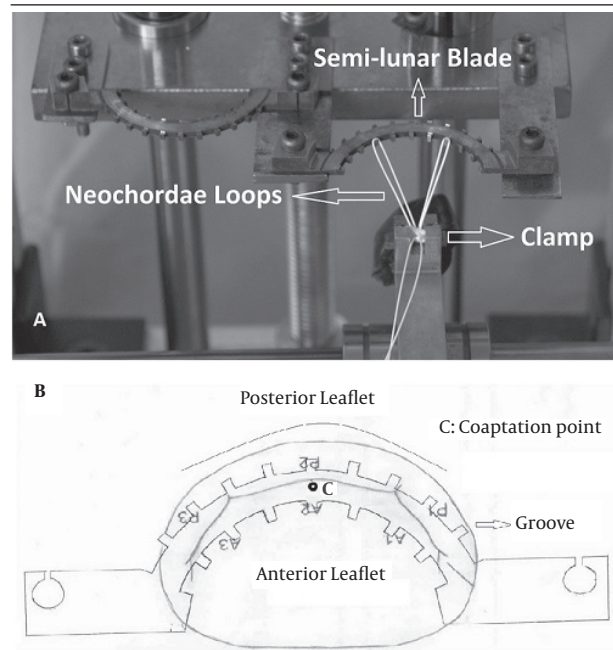


Figure 4. Neochordameter Elements

4. Results

Three patients enrolled in the preliminary phase of this study. Two of these patients were male and the other one was female. All of them had severe mitral regurgitation requiring anterior leaflet repair. Total eight neochordae loops were used. Table 1 shows their pre and postoperative results. No change in the length of neochordae loops or any additional suture or modification were required

after saline test. Intraoperative and follow-up TEE showed or trivial regurgitation or nothing. No complication was seen in three months follow-up.

5. Discussion

Using neo-chordae for mitral valve repair has been favored by several surgeons from the first introduction (5-7). Since then, several methods have been proposed to facilitate estimating the length of required neo-chordae. These methods can be divided into two major categories. First one is determining the length of neochordae during operation and the second one is using preoperative echocardiography to find the length. However, all of these methods have shown some drawbacks including: measuring the length of neochordae in non-physiological state, the need for post-implantation length adjustment, and technical deficiencies for applying in minimally invasive and robotic surgeries. Matsui employed a new device consisting of two metallic tubes with a circular, hook shaped distal tip (8) Prêtre et al. (9) used an approach through the aortic valve for an anterior and posterior leaflet prolapse. They used saline test to examine adjustment of neo-chordal length. Tam et al. used a caliper during the surgery to measure the length of neochordae (10). Gilli-

nov improved their methods and measured the length of neochordae with a caliper and made the loops around it (11). All of these mentioned methods are just applicable during surgery while the surgeon has not excellent view over the position of papillary muscles. Moreover, all of these methods require post-implantation length adjustment which further increases cardiopulmonary bypass time. Mandegar et al. used preoperative transesophageal echocardiography to estimate the distance between posterior papillary muscle and the free edge of the leaflet (12). Doi et al. used a combination of preoperative echocardiography and intraoperative measurements to estimate the length of neochordae (2). Recently, Matsui et al. used a new technique which needs only 12-French transparent plastic tube (13). Although these methods reduce the problem of intraoperative length measurement, both need post-implantation length adjustment. Our proposed technique has several advantages. All steps of this method including TTE and making the loops of neo-chorda are performed preoperatively in a physiological state. Therefore, this would decrease the cardiopulmonary bypass time and increase the accuracy of length measurements. Furthermore, this ability would develop this technology for minimally invasive and robotic mitral valve repair.

Table 1. Patients' Characteristics

Preoperative variables	Patient 1	Patient 2	Patient 3
Age, y	36	35	67
Gender	Male	Male	Female
Body Mass Index	26.84	26.64	30
LVEF ^a (%)	60	60	55
End Systolic Volume, mL	48	85	53
End Diastolic Volume, mL	80	204	150
Left Atrial size, mm	33	60	40
IVRT ^a	65	70	60
IVRT/(QE - QE')	13	14	12
E/E'	8.5	15	10.5
Postoperative variables			
Ring size, mm	32	32	32
LVEF (%)	55	50	50
LVOT gradient, mmHg	4	4.2	5.7
Coaptation length, mm	6	6	6
TMVG, mmHg	4.6	4.2	2.26
Number of neochordae	3	3	2

^a Abbreviations: E, early ventricular filling velocity; E', peak diastolic velocity of the septal mitral annulus; LVEF, left ventricular ejection fraction; LVEF, isovolumic relaxation time; QE, the time interval from Q in the ECG to the onset of E; QE', the time interval from Q to the onset of E'; TMVG, trans mitral valve gradient

Acknowledgements

We are indebted to Golrokh Bateni for her help in our study.

Authors' Contribution

Study concept and design: Ghavidel, Samiei, Javadikasgari, and Bashirpour. Drafting manuscript: Ghavidel, Samiei, and Javadikasgari, Bashirpour. Critical revision of the manuscript for important intellectual content: Ghavidel, Samiei, Javadikasgari, and Bashirpour. Statistical analysis: Javadikasgari.

Financial Disclosure

There is no financial disclosure.

Funding Support

There is no funding support.

References

1. Suri RM, Schaff HV, Dearani JA, Sundt TM, 3rd, Daly RC, Mullany CJ, et al. Survival advantage and improved durability of mitral repair for leaflet prolapse subsets in the current era. *Ann Thorac Surg.* 2006;**82**(3):819-26.
2. Doi A, Iida H, Sunazawa T. Intracardiac calipers for artificial chordae replacement in mitral valve repair. *Ann Thorac Surg.* 2009;**87**(1):326-8.
3. Colombo PC, Municino A, Brofferio A, Kholdarova L, Nanna M, Ilterci A, et al. Cross-sectional multiplane transesophageal echocardiographic measurements: comparison with standard transthoracic values obtained in the same setting. *Echocardiography.* 2002;**19**(5):383-90.
4. Hozumi T, Shakudo M, Shah PM. Quantitation of left ventricular volumes and ejection fraction by biplane transesophageal echocardiography. *Am J Cardiol.* 1993;**72**(3):356-9.
5. David TE, Armstrong S, Sun Z. Replacement of chordae tendinae with Gore-Tex sutures: a ten-year experience. *J Heart Valve Dis.* 1996;**5**(4):352-5.
6. Morita S, Yasui H, Harasawa Y, Tomita Y, Tominaga R. Extensive use of artificial chordae for repairing diffuse mitral valve prolapse. *Ann Thorac Surg.* 1996;**62**(3):878-80.
7. Zussa C, Frater RW, Polesel E, Galloni M, Valfre C. Artificial mitral valve chordae: experimental and clinical experience. *Ann Thorac Surg.* 1990;**50**(3):367-73.
8. Matsui Y, Fukada Y, Naito Y, Sasaki S, Yasuda K. A new device for ensuring the correct length of artificial chordae in mitral valvuloplasty. *Ann Thorac Surg.* 2005;**79**(3):1064-5.
9. Pretre R, Khatchatourov G, Kadner A, Genoni M. Application and adjustment of artificial chordae to the mitral valve using an approach through the aortic valve. *Ann Thorac Surg.* 2006;**82**(2):761-2.
10. Tam R, Joshi P, Konstantinov IE. A simple method of preparing artificial chordae for mitral valve repair. *J Thorac Cardiovasc Surg.* 2006;**132**(6):1486-7.
11. Gillinov AM, Banbury MK. Pre-measured artificial chordae for mitral valve repair. *Ann Thorac Surg.* 2007;**84**(6):2127-9.
12. Mandegar MH, Yousefina MA, Roshanali F. Preoperative determination of artificial chordae length. *Ann Thorac Surg.* 2007;**84**(2):680-2.
13. Matsui Y, Kubota S, Sugiki H, Wakasa S, Ooka T, Tachibana T, et al. Measured tube technique for ensuring the correct length of slippery artificial chordae in mitral valvuloplasty. *Ann Thorac Surg.* 2011;**92**(3):1132-4.