




Diagnosis and Management of Apical Fenestrations Associated with Endodontic Diseases: A Literature Review

 Jasmine WONG,  Angeline Hui Cheng LEE,  Chengfei ZHANG

ABSTRACT

Apical fenestration describes a window-like opening of the alveolar bone that involves the root apex of the associated tooth. Mucosal fenestration is a similar defect of the overlying mucosa and, when presented with a concomitant apical fenestration, may expose the root apex to the oral environment. A fenestration may arise from physiological and pathological processes. Although its presence does not necessitate treatment per se, these lesions have significant clinical implications when associated with endodontic diseases. Apical fenestrations associated with endodontic infections are relatively uncommon and can easily be overlooked or misdiagnosed. A thorough understanding of these lesions is key for timely diagnosis and successful management. The aim of this study was to review the epidemiology, aetiological factors, characteristics, management methods and potential outcomes of apical fenestrations associated with endodontic diseases. A search of online databases for relevant studies was conducted. With the inclusion of hand searched articles, 20 articles, consisting of case reports and series, were identified, and the key characteristics of each case were summarised. Apical fenestrations were found to be most commonly associated with maxillary teeth and almost always occur on the buccal aspect of the alveolar bone. Clinicians may consider the possibility of an apical fenestration with concurrent endodontic pathology when patients present with non-healing sinus tracts, exposed tooth apices and/or persistent pain after endodontic treatment, particularly on palpation and mastication. Clinical signs and symptoms can vary, hence cone-beam computed tomography is an important tool for diagnosis. The management involves surgically restoring a favourable anatomical configuration of the root apex in relation to the alveolar bony housing and may be combined with guided tissue regeneration and/or grafting procedures. Sloughing, reopening and infection are potential complications. The literature on apical fenestrations associated with endodontic diseases is limited, thus further research is needed to develop evidence-based guidelines for the diagnosis and management of these lesions.

Keywords: Apical fenestration, endodontics, mucosal fenestration, periradicular surgery, persistent pain

HIGHLIGHTS

- Apical fenestrations can be associated with endodontic diseases, and may be a cause for persistent pain after endodontic treatment.
- Diagnosis and appropriate management of the apical fenestration is important for successful endodontic treatment.
- The clinical presentation of apical fenestrations may vary, hence CBCT investigation is advised when the presence of these lesions is suspected.
- Management often requires apical surgery and root-end resection with or without adjunctive GTR and/or grafting procedures.

INTRODUCTION

Fenestration describes a defect or a window-like opening at the cortical plate of the alveolar bone, which can develop from physiological or pathological processes (1). When involving the apical region of a root, it is referred to as an apical fenestration. A concomitant mucosal fenestration can result in the exposure of the root tip to the oral environment. A fenestration differs from a dehiscence as the latter always compromises the marginal bone, although both can involve the root apex (2). Apical fenestrations have been associat-

ed with several risk factors including past traumatic injuries, periodontal disease, buccally inclined roots, occlusal trauma, orthodontic treatment, thinness of the overlying alveolar bone and endodontic pathosis (3-9). When associated with endodontic diseases, such as apical periodontitis, fenestrations may be a result of pathological processes, including periradicular inflammation and resorption of the bony cortical plate (2, 5). In the event an apical fenestration and endodontic pa-

Please cite this article as: Wong J, Lee AHC, Zhang C. Diagnosis and Management of Apical Fenestrations Associated with Endodontic. *Eur Endod J* 2021; 6: 25-33

From the Department of Restorative Dental Sciences (J.W., A.H.C.L., C.Z.)
✉ zhangcf@hku.hk Faculty of Dentistry, The University of Hong Kong, Hong Kong

Received 28 August 2020,
Accepted 12 November 2020

Published online: 05 February 2021
DOI 10.14744/eej.2020.51422

This work is licensed under a Creative Commons Attribution-NonCommercial 4.0 International License.



thology occurs concurrently, timely diagnosis and appropriate management are of particular significance to successful endodontic treatment (10).

Patients presenting with apical fenestrations associated with endodontic infections may experience signs and symptoms such as pain on mastication and digital pressure (3), the presence of an abscess (10) and noticeable gingival defects (11). Apical fenestrations may be a cause for persistent pain following endodontic therapy (3). Conversely, patients can also be asymptomatic (2). Apical fenestrations may not always present with mucosal fenestrations (12, 13). But when mucosal fenestrations are involved, suppuration from the defect (14) and inflammation of the collar with plaque accumulation (4) may also be found. Due to the variable clinical presentations, diagnosis is often challenging, and further investigations, such as cone-beam computed tomography (CBCT), may be necessary (12, 13, 15).

Following non-surgical treatment of the endodontic infection, apical surgery with root-end resection is often needed to restore a more favourable relationship between the root apex and overlying alveolar bone (16). When there is a concurrent mucosal fenestration, various treatment options that have been suggested include primary closure (2), guided tissue regeneration (GTR) (17) and the use of mucosal grafts (10). In fact, much variation exists in the surgical management of these lesions. Because apical fenestrations are infrequently reported in the literature, there are currently no guidelines on their diagnosis and management.

The aim of this study was to review the existing literature on apical fenestrations, including mucosal fenestrations involving the root apex, associated with endodontic diseases, and to provide an overview of the epidemiology, aetiological factors, clinical and radiographic characteristics, histological features, management methods and outcomes.

MATERIALS AND METHODS

The electronic databases Scopus, PubMed and Ovid MEDLINE were searched using the following key words and their combinations: endodontic treatment, surgical endodontics, periradicular surgery, apical surgery, persistent apical periodontitis, mucosal fenestration, apical fenestration, gingival fenestration, root fenestration and gingivo-osseous pathologic fenestration. After identifying the articles to be included in this review, the references of those papers were then hand searched for other relevant studies.

Articles that were clinical studies or case reports of apical fenestrations, including mucosal fenestrations involving the root apex, associated with endodontic diseases were included. Other inclusion criteria included studies involving human subjects and permanent dentition. Articles of fenestrations solely related to non-endodontic conditions, such as those associated with orthodontic and periodontal conditions, were excluded.

Data from case reports were extracted either directly from statements included the main text/tables or inferred from

the clinical information, radiographs and clinical photos. Data regarding the patient demographics, tooth type, chief complaint, history of trauma, endodontic status, radiographic features, presence of mucosal fenestration, type of bony defect, treatment methods and review period were summarised and frequency statistics were calculated.

RESULTS

With the aforementioned search strategy, the articles were obtained and then screened using the inclusion criteria by title, abstract, accessibility and finally full texts, resulting in 17 articles. With the addition of hand searched articles, a total of 20 were identified for this literature review. Hand searched articles concerning epidemiology and prevalence of fenestrations were also included in this literature review.

From the 20 articles, 30 cases were identified, with one tooth per case. Two of those cases did not meet our criteria for inclusion. One of the 3 cases reported in Jhaveri et al. (4) was excluded because the osseous defect did not involve the apical portion of the root and was not associated with any endodontic pathology. One of the 2 cases reported by Bains et al. (14) was excluded because the osseous defect did not involve the apical portion of the root. Subsequently, the remaining 28 cases were all included in this literature review. The key findings of the included case reports have been summarised in Table 1.

Amongst the cases reported, the majority were related to maxillary teeth, most commonly the central incisors, as reported in 6 cases (21.4%), followed by maxillary first premolars, maxillary lateral incisors and mandibular central incisors, all of which had 5 cases each (17.9%). There were 4 cases of maxillary first molars (14.3%) and 3 of maxillary canines (10.7%). Prevalence was highest in persons between the ages of 31 and 40 (28.6%) and least common in those over 60 (3.6%). Prevalence was similar between males and females, with 14 (50.0%) and 11 (39.0%) cases respectively. Three of the cases did not state the patients' gender. History of trauma was associated with 10 teeth (35.7%). Teeth were either previously endodontically treated, i.e. 11 (39.3%) or presented with pulp necrosis i.e. 17 (60.7%). Twenty-four teeth presented with a concomitant mucosal fenestration (85.7%), whilst the remaining had no soft tissue defects.

Apical surgery was performed for all cases with or without prior non-surgical root canal (re)treatment, except for 1 as reported by Gandhi et al. (17) where a flap was raised to gain access to the apical region, and degranulation and root debridement was performed with no reported root-end resection. Surgical intervention revealed that 9 out of the 24 teeth with mucosal fenestrations involving the root apex were associated with bony dehiscences (37.5%). Six of the fenestrations were managed by primary closure, without grafting or regenerative methods (21.4%), and 1 was allowed to heal by secondary intention (3.6%). The management of the remaining majority (75.0%) involved the placement of membranes, bone grafts and/or mucogingival grafts. The reported follow up period ranged between 3 months and 160 months, although some authors did not specify the exact time period. Seven teeth (25.0%) reported a relapse of the fenestration and/or infec-

TABLE 1. Summary of the case reports included in this literature review

Case No.	Author (year)	Age	Sex	Tooth	Chief complaint	Trauma	Endodontic status	Radiographic features	Mucosal fenestration	Bony defect	Endodontic treatment	Fenestration management	Follow up
1	Agarwal (2010)	18	M	21	Root exposure from gums	Yes	Pulp necrosis	Open apex	Yes	Dehiscence	RCT; apical surgery	Bone graft	1 yr
2	Bains et al. (2015)	20	----	11	Pus discharge, fracture	Yes	Pulp necrosis	Immature apex, midroot radiolucency	No	Fenestration [#]	RCT; apical surgery (MTA)	HAP bone graft, PRF membrane	1 yr
3	Boucher et al. (2000)	45	F	14	Pain after endodontic treatment	No	Previous RCT	Overextension of root filling; DB root fenestration [^]	No	Fenestration	Apical surgery	Primary closure	1 yr
4	Chen et al. (2009)	30	M	12	Abscess	No	Pulp necrosis	Immature apex, apical radiolucency	Yes	Fenestration	RCT; apical surgery (Super EBA)	DFDBA, connective tissue graft	1 yr
5		30	M	14	Root tip exposure	No	Previous RCT	Apical radiolucency	Yes	Fenestration	Apical surgery (Super EBA)	Connective tissue graft	1 yr
6	Dawes and Barnes (1983)	24	M	16	Exposed root apices	No	Pulp necrosis	No root canal fillings, furcal radiolucency	Yes	Fenestration (DB root), dehiscence (MB root)	RCT; Apical surgery (amalgam)	Primary closure	9 mos*
7	Furusawa et al. (2012)	55	F	13	Persistent pain	No	Previous RCT	Apical fenestration [^]	No	Fenestration	Apical surgery	----	2 yrs
8	Gandi et al. (2013)	24	M	11	Itchy gum	Yes	Pulp necrosis	Apical radiolucency	Yes	Fenestration [#]	RCT; apical surgery (GIC)	Bioactive glass bone graft, collagen membrane	3 mos
9		34	----	12	Trauma	Yes	Pulp necrosis	Apical radiolucency	Yes	Dehiscence [#]	RCT	Bone graft	3 mos
10	Jafri et al. (2019)	19	M	41	Gingival defect	Yes	Previous RCT	Diffuse radiolucency	Yes	Dehiscence [#]	Retreatment; apical surgery	TCP bone graft, collagen membrane	>7 days
11	Jhaveri et al. (2010)	24	M	16	Pain	No	Pulp necrosis radiolucency at	Apical	Yes	Fenestration surgery (GIC)	RCT; apical surgery	CTG	1 yr
12		20	M	31	Fenestration	Yes	Pulp necrosis	MB root Diffuse radiolucency, widened PDL	Yes	Dehiscence	RCT; apical surgery (GIC)	CTG	8 mos
13	Ju et al. (2004)	43	F	14	Abscess	No	Pulp necrosis	Apical radiolucency	Yes	Fenestration	RCT; apical surgery (amalgam)	Modified lateral pedicle flap	1 yr*
14	Lin et al. (2015)	36	M	14	Fenestration	No	Previous RCT	Apical radiolucency	Yes	Dehiscence	Retreatment; apical surgery (super EBA)	DFDBA, absorbable copolymer membrane	72 mos

TABLE 1. Cont.

Case No.	Author (year)	Age	Sex	Tooth	Chief complaint	Trauma	Endodontic status	Radiographic features	Mucosal fenestration	Bony defect	Endodontic treatment	Fenestration management	Follow up
15		26	M	31	Fenestration	No	Pulp necrosis	Apical radiolucency	Yes	Dehiscence	RCT; apical surgery (super EBA)	DFDBA, TR membrane, CTG	72 mos
16		34	F	26	Fenestration	No	Pulp necrosis	Apical radiolucency	Yes	Fenestration	RCT; apical surgery (super EBA)	DFDBA, TR membrane, CTG	160 mos
17		50	F	13	Fenestration	No	Previous RCT	Apical radiolucency	Yes	Fenestration	Retreatment; apical surgery (super EBA)	DFDBA, GTAM; CTG (2 nd surgery)	113 mos*
18		34	F	22	Fenestration	Yes	Pulp necrosis	Apical radiolucency	Yes	Fenestration surgery	RCT; apical membrane; (super EBA)	DFDBA, TR mos*	107
19	Nimigean and Nimigean (2013)	14	F	14	Aesthetic concerns	No	Pulp necrosis	Apical fenestration [^]	Yes	Fenestration	RCT; apical surgery	Bovine bone graft, collagen membrane	6 mos
20	Pasqualini et al. (2012)	32	F	26	Diffuse pain with sporadic intense episodes	No	Previous RCT	MB root overfilling; MB root apical fenestration [^]	No	Fenestration	Apical surgery (MTA)	Primary closure	1 yr
21	Rawlinson (1984)	41	M	41	Abscess	No	Previous RCT	Diffuse radiolucency	Yes	Fenestration	Retreatment; apical surgery	Healing by secondary intention	8 mos*
22	Ricucci et al. (2018)	35	F	2	Gingival defect	No	Pulp necrosis	Apical radiolucency; apical fenestration [^]	Yes	Fenestration	RCT; apical surgery (MTA)	Primary closure, collagen wound dressing	1 yr
23		52	M	21	Discoloration	Yes	Pulp necrosis	Diffuse radiolucency; apical fenestration [^]	Yes	Fenestration	RCT; apical surgery (MTA)	Primary closure	1 yr
24	Sharma et al. (2015)	34	F	12	Exposed root	No	Previous RCT	Inadequate RCT, lateral mid-root radiolucency	Yes	Dehiscence	Retreatment (MTA); apical surgery	TCP-HAP bone graft, collagen membrane	6 mos
25	Singh et al. (2012)	20	F	21	Discoloured teeth	Yes	Pulp necrosis	Apical radiolucency	Yes	Fenestration	RCT; apical surgery	Bioactive glass bone graft, free gingival graft (2 nd surgery)	6 mos* (from 2 nd surgery)
26	Travassos et al. (2015)	35	---	23	Gingival defect	No	Previous RCT	Apical radiolucency	Yes	Dehiscence	Apical surgery	Bovine bone graft, bovine membrane, CTG (2 nd surgery)	180 days*

TABLE 1. Cont.

Case No.	Author (year)	Age	Sex	Tooth	Chief complaint	Trauma	Endodontic status	Radiographic features	Mucosal fenestration	Bony defect	Endodontic treatment	Fenestration management	Follow up
27	Tseng et al. (1995)	57	M	31	Mucosal defect	No	Pulp necrosis	Apical radiolucency	Yes	Fenestration	RCT; apical surgery (amalgam)	DFDBA, GTAM	6 mos
28	Yang et al. (1996)	62	M	11	Sinus tract	Yes	Previous RCT	Apical radiolucency, distal external inflammatory resorption	Yes	Fenestration	Retreatment; apical surgery (amalgam)	Primary closure	6 mos

----: Unspecified, RCT: Root canal treatment; A: Diagnosed by 3D imaging. *: Bone sounding performed, DB: Distobuccal, MB: Mesio Buccal, MTA: Mineral trioxide aggregate, GIC: Glass ionomer cement, super-EBA: Super-ethoxy benzoic acid, HAP: Hydroxyapatite, PRF: Platelet rich fibrin, DFDBA: Demineralised freeze-dried bone allograft, TCP-HAP: β -tricalcium phosphate with hydroxyapatite, CTG: Connective tissue graft, GTAM: Gore-Tex augmentation membrane, TR: Titanium reinforced, mos: Months, yr: Year, *: Outcome associated with complications.

tions, whilst 4 (14.3%) required resurgery. All the cases reported eventual clinical healing.

DISCUSSION

Terminology

The American Association of Endodontists defines fenestration as a defect or opening present on the alveolar plate that may expose part of the root, commonly located on the buccal or facial aspect of the alveolar bone (1). Other similar terms include gingivo-osseous pathologic fenestration (18), gingival fenestration (4) and root fenestration (3). Similarly, mucosal fenestration refers to a window-like defect of the overlying mucosa, often exposing the underlying root surface. The term apical fenestration indicates the involvement of the root apex and the apical position of the defect along the root. Dehiscence is defined as a vertical, narrow defect present on the alveolar plate, and is also commonly found on the buccal or facial aspect of the alveolar bone (1). These conditions are overlapping in that mucosal fenestrations involving the root apex are often associated with apical fenestrations, however surgical exploration may occasionally reveal a bony dehiscence when the pathological processes have progressed to involve the marginal bone (4, 19, 20).

Epidemiology

Because of the paucity of literature in relation to apical fenestrations, this section will cover the prevalence of fenestrations regardless of the position along the root. The prevalence of fenestrations reported from examination of dry cadaver human skulls is 4.3% to 16.9% (6-8, 21-24). The mean diameter of these lesions was reported to be 1.85 mm in the mandible and 2.86 mm in the maxilla (7). The location of the fenestration along the root was most commonly reported to occur at the apical third (5, 8). Advancements in technology have paved the way for three-dimensional imaging, allowing identification of bony changes in living humans. Using CBCT, Pan et al. (15) reported that the prevalence of fenestrations was 3.4% for a Chinese subpopulation. Another study using CBCT to investigate the periapical defects of previously endodontically treated teeth revealed apical fenestrations in 10% of patients (25). In general, the epidemiological results reported from cadaveric studies may not be a realistic representation of the prevalence of fenestration defects diagnosed clinically. This may be due to the physical damage or degradation of the skulls resulting in a higher prevalence of fenestrations in cadavers, hence CBCT imaging could offer a more accurate representation (15). Combined mucosal and apical fenestrations appear to be an even rarer occurrence, owing to the scarcity of related clinical reports. To our knowledge, there is currently no published data regarding the clinical prevalence of these lesions.

Aetiology

Apical fenestrations may arise from physiological and pathological processes. They can also be considered as an anatomical variation where the bone overlying a root apex is naturally deficient (3, 26). Aetiological factors include periodontal disease, endodontic pathosis, orthodontic treatment, trauma, attrition and traumatic occlusion (6, 7, 9, 27, 28). In the absence of disease, these localised alveolar defects are often symp-

tom-free, and their presence does not necessitate any clinical intervention (9, 15). However, if the root apex, or apices, communicates with the oral cavity via a concomitant mucosal fenestration, this may predispose the tooth to endodontic infection and complicate treatment due to the likelihood of microbial irritants from the oral environment entering the root canal system via the apical foramina and the potential for biofilm formation on the exposed roots (16). Hence, when associated with endodontic pathosis, the presence of an apical fenestration can have significant implications on diagnosis and treatment planning (10, 28).

Apical fenestrations can be implicated in primary endodontic infections as well as endodontic treatment failure (10, 16). Periradicular inflammation and bone resorption are the likely causes for breakdown of the alveolar bone overlying the root apex (29). This may lead to the situation in which the overlying alveolar bone, and subsequently mucosa, no longer encases the root tip, particularly in individuals with anatomical predispositions. Iatrogenic damage to the periradicular tissues from over-instrumentation and overfilling could contribute to the pathological development of apical fenestrations (3, 13). Pre-existing apical fenestrations may also be exacerbated by apical endodontic pathology and treatment (3), albeit it is not possible to determine whether the fenestration existed before the endodontic pathology or if the inflammatory processes lead to it (16).

The development and presence of apical fenestrations have been associated with several risk factors. Anatomical variations, such as thinness of alveolar bone and mucosa and buccally malpositioned teeth are commonly reported risk factors for developing fenestrations (2, 9, 10). Almost all apical fenestrations occur on the buccal aspect of the alveolar bone (9). The majority of these lesions are associated with maxillary teeth, particularly maxillary first molars which are most often reported with having the highest prevalence of fenestrations (5, 8, 9, 21-24). Other commonly associated teeth include maxillary canines (7, 23), maxillary first premolars (15) and mandibular lateral incisors (21, 22). The existing epidemiological evidence appears to contradict the findings of this study which suggests that clinical case reports of apical fenestrations associated with endodontic pathologies are most commonly related to maxillary central incisors followed by maxillary first premolars, maxillary lateral incisors and mandibular central incisors. This may be attributed to the fact that the majority of epidemiological evidence has been gathered from cadaveric studies, which, as previously mentioned, may not be an accurate representation of the clinical prevalence of apical fenestrations associated with endodontic diseases. There is no clear association between gender and the development or presence of apical fenestrations, with most studies having found no significant difference between the prevalence in males and females (15). Older individuals tend to show a lower prevalence than their younger counterparts, which could be attributed to the former having suffered greater loss of teeth due to dental diseases (5, 15). Variations in the prevalence of apical fenestrations have also been noted between different subpopulations, which could be attributed to ethnic differences in dento-alveolar anatomy (9).

Clinical characteristics

Patients with apical fenestrations associated with endodontic pathologies may present with various complaints, signs and symptoms. These include traumatic dental injuries (14, 17), aesthetic concerns (16, 28), gingival defects or discomfort (11, 16, 17, 20) and pain, especially on palpation and mastication (3, 12, 13). Patients may develop a habit of rubbing the area of discomfort, which could exacerbate their symptoms (3). Persistent pain following root canal treatment has been attributed to the presence of an apical fenestration, therefore it has been suggested that when a discernible cause cannot be identified for the persistent symptoms, an apical fenestration should be considered as a possible aetiological factor (12, 13). Boucher et al. (3) suggested that during occlusal or digital pressure, movement of teeth with any over-filled or extended material may irritate the periodontal tissues at the fenestration, thus leading to persistent pain after endodontic treatment. One study reported a case of atypical facial pain after endodontic treatment with an over-filled root canal (13). On the other hand, there are several reports of patients that presented without any symptoms at all (2, 17, 30).

Clinical examination may reveal a concomitant mucosal fenestration. When present, it can harbour plaque, food debris and calculus and the subsequent inflammation can act as a secondary aetiological factor (2, 11, 16, 17, 31). Purulent discharge from the mucosal defect and tenderness to palpation of the buccal mucosa overlying the root apex may be present (3, 14, 32). It is also likely that an apical fenestration may not be associated with a concurrent mucosal fenestration (3, 12-14). In these instances, further investigations such as bone sounding (11, 14, 17) and CBCT imaging (12, 13) can be useful.

Radiographic appearance

Radiographic investigation of apical fenestrations with concurrent endodontic diseases often reveals an apical radiolucency which is indicative of inflammatory and bone resorption processes that may have contributed to the development of these defects (17, 11, 4, 32, 16, 20, 31). Previously endodontically treated teeth may present with overfilled canals, a possible contributing factor to the pathogenesis (3, 13). However, some cases may not present with periapical lesions when viewed using only conventional intra-oral radiographs, particularly if there is only mild bone resorption (13, 25). Furthermore, as fenestrations are often situated on the buccal aspect of the alveolar bone, they are difficult to detect with intra-oral radiographs, which only show a two-dimensional representation of the anatomical structures. The American Association of Endodontists and American Academy of Oral and Maxillofacial Radiology 2015 joint statement on the use of CBCT in Endodontics also states that the use of CBCT should be considered when patients present with nonspecific or contradicting clinical signs and/or symptoms (33). Therefore, CBCT imaging has been advocated to facilitate the diagnosis of apical fenestrations, evaluate the extent of the lesion and the position of the root apex in relation to the overlying alveolar bone, and for the purposes of pre-surgical planning (12, 13, 15).

Histological features

Histological studies on apical fenestrations associated with endodontic infections are relatively scarce. A histological report identified chronic inflammatory tissue associated with a mucosal fenestration exposing the root apices of an endodontically infected upper right first molar (2). Ricucci et al. (16) further explored the histological features of apical fenestrations and found chronic inflammatory cells with fibrous connective tissue in the presence of heavy bacterial biofilm structures. An accumulation of bacterial biofilms was also found at the apical foramen and amongst fractured and detached cementum, whilst resorption of the cementum was also detected in some areas (16).

Management

Eliminating and controlling the impetus of infection is important for the successful management of these lesions (16). Primary or secondary non-surgical root canal treatment is first needed to disinfect and seal the root canal system, whilst subsequent surgical treatment by root-end resection coupled with root debridement of the exposed surface is often necessary to manage an apical fenestration with concurrent endodontic pathosis (2, 10, 20, 32). In general, the main goal of surgical treatment in this context is to produce a favourable anatomical configuration and environment for healing by removing contaminated and inflamed periradicular tissues as well as adjusting any prominent root apices so that they lie within the alveolar bony housing (2, 4). Furthermore, surgical intervention can seal the mucosal opening and prevent further influx of microbial irritants into the root canal system from the oral environment.

Various methods have been employed to manage apical fenestrations as well as mucosal fenestrations that involve the root apex. These include GTR (11, 17, 28, 34), mucogingival graft techniques (32, 35), and flap replacement with primary closure, with or without supplemental wound dressings (2, 13, 16, 31). Flap replacement with primary closure provides a simple method of managing the mucosal defect. The epithelium lined collar of a mucosal fenestration may be excised prior to flap replacement and suturing in order to improve epithelial attachment (2, 3, 11, 26, 31). When primary closure would result in excessive wound tension, GTR and other grafting procedures have been suggested (11, 17, 28, 34). GTR has shown beneficial effects in regard to bony ingrowth and connective tissue attachment for communicating endodontic and periodontal lesions (36-39). However, any exposure of the membrane to the oral environment could pose a risk of secondary infection (4). Other reports have suggested the use of mucogingival grafting techniques, such as the lateral pedicle and free gingival graft, with or without simultaneous GTR (32, 35). One report allowed the fenestration to heal via secondary intention, however it resulted in infection of the surgical wound and soft tissue defect (26). It has been suggested that predictable mucosal closure is crucial for successful healing and this can be aided by soft tissue manipulation, regardless of whether it is achieved by flap replacement or mucogingival grafts (34). A clinical case demonstrating the surgical management of mucosal fenestrations involving the root apices of 12 and 22 is presented in (Fig. 1).

One case reported by Gandi et al. (17) was not managed by root-end resection. Instead, after non-surgical root canal treatment, open flap debridement and degranulation up to the root apex were carried out followed by grafting procedures with no reported apicectomy. This could suggest the extent of root-end resection depends on the degree of anatomical malpositioning and, given there is no significant protrusion of the root apex out of the alveolar bone, it may be possible to manage apical and mucosal fenestrations that involve the apical region without considerable removal of the root apex. Other articles reported attempts to promote spontaneous closure of the mucosal defect by non-surgical debridement of the exposed root surface, oral hygiene reinforcement and the use antiseptic mouth wash (11, 17). Although these methods may have led to a reduction in inflammation of the mucosal collar, they apparently did not lead to the resolution of the soft tissue defect. Possible factors contributing to the failure of these conservative methods include extensive bacterial biofilms and irregular cementum layer detachments with subsequent infection of the underlying surfaces and apical foramina (16).

Outcome

In this literature review, all of the cases reported eventual healing of the fenestrations with radiographic evidence of bony infill. Sloughing or a depression at the site of the defect was observed in some cases (2, 26, 31, 40). Several articles reported complications, such as the persistence or reopening of the fenestration, and infection (2, 20, 26, 32, 34). Subsequent management could include careful root debridement and oral hygiene instructions to facilitate healing by secondary intention (26) and resurgery (35). In order to avoid the reopening of the wound, it has been recommended that primary closure via flap repositioning should generally only be used when there is no mucosal fenestration or when it is only minor defect (34). For larger defects, primary closure may lead to excessive wound tension and given that the bony support and blood supply is often compromised, mucogingival grafts may need to be employed to achieve predictable healing and wound closure (34).

CONCLUSION

In conclusion, apical fenestrations associated with endodontic diseases are uncommonly reported, yet they nonetheless have significant clinical implications. Diagnosis based solely on the clinical presentation may be challenging, particularly when there is no concomitant mucosal fenestration. The current literature suggests the associated signs and symptoms may vary widely. Whilst some patients with this condition may be completely asymptomatic, others may experience persistent pain following endodontic therapy. CBCT imaging serves as a useful diagnostic tool. Successful management depends on adequate control of root canal infection as well as restoring a favourable anatomical configuration of the root apex in relation to the surrounding alveolar bone. More research is still needed to formulate evidence-based recommendations on the diagnosis and treatment of apical fenestrations associated with endodontic diseases.

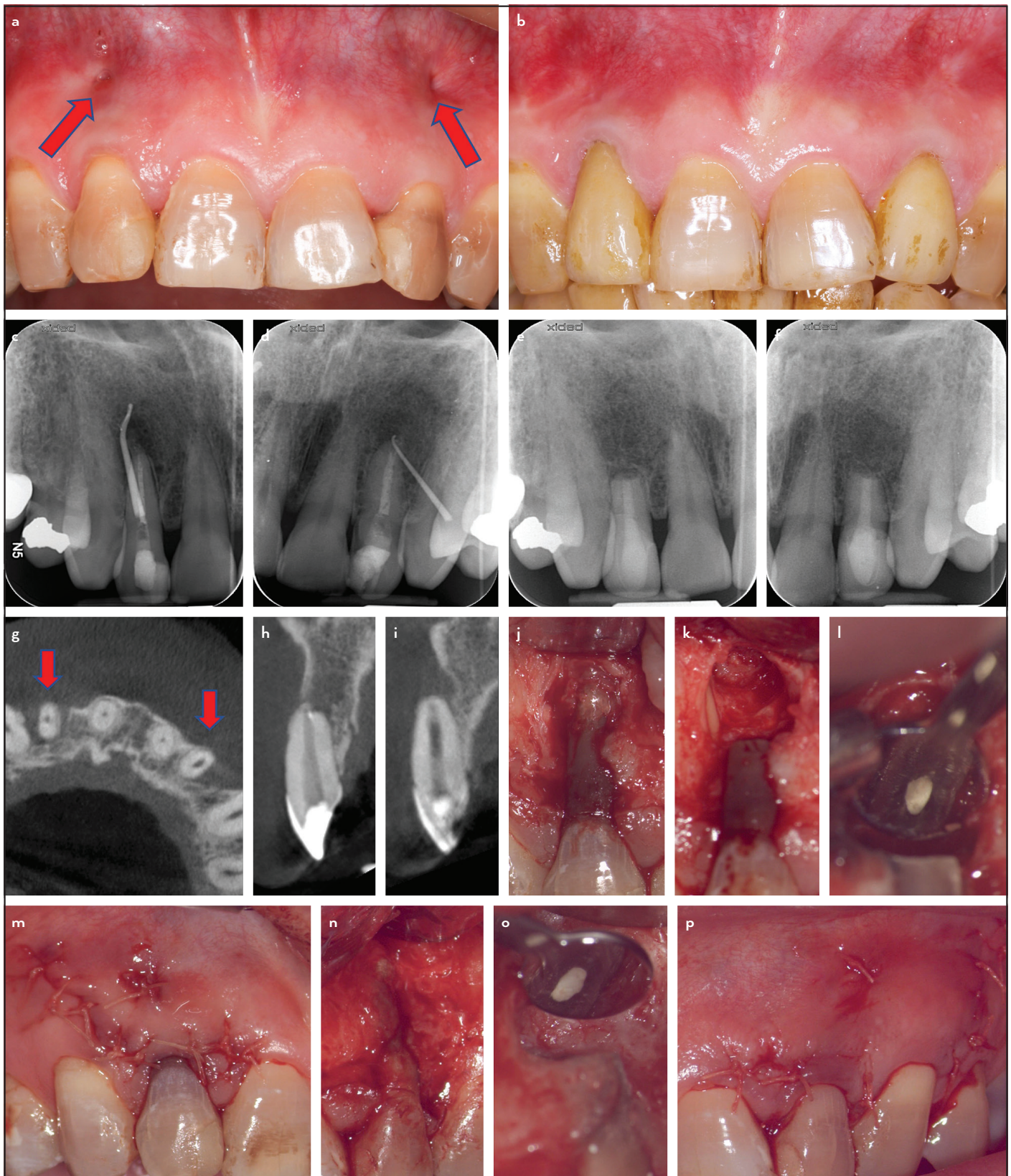


Figure 1. Grading (a) pre-operative clinical photo of 12 and 22 with buccal mucosal fenestrations; (b) 18-month post-operative clinical photo showing complete healing of the 12 and 22 mucosal fenestrations; (c) and (d) gutta-percha tracing of the fenestrations to the 12 and 22 apical region respectively, both had been filled with intra-canal medicament; (e) and (f) 18-month post-operative radiographs with evidence of bony infill after apical surgery of 12 and 22 respectively; (g) CBCT axial view showing 22 more labially positioned in the arch; (h) and (i) CBCT sagittal view of 12 and 22 respectively showing bony dehiscences involving the root apex; (j) 12 buccal dehiscence involving the root apex was revealed after raising surgical flap, followed by (k) root-end resection, (l) MTA obturation, placement of collagen membrane and (m) primary closure with sutures; (n) 22 buccal dehiscence involving the root apex was similarly revealed after raising flap, followed by (o) MTA obturation after root-end resection, placement of collagen membrane and (p) primary closure with sutures.

Disclosures

Conflict of interest: The authors deny any conflicts of interest related to this study.

Peer-review: Externally peer-reviewed.

Financial Disclosure: The authors declare that this study has received no financial support.

Authorship contributions: Concept – C.Z.; Design – J.W.; Supervision – C.Z., A.H.C.L.; Funding - None; Materials - None; Data collection &/or processing – J.W.; Analysis and/or interpretation – A.H.C.L., J.W.; Literature search – J.W.; Writing – J.W.; Critical Review – A.H.C.L., C.Z.

REFERENCES

- American Association of Endodontists. Glossary of endodontic terms. 10th ed. Available at: <https://www.aae.org/specialty/clinical-resources/glossary-endodontic-terms/>. Accessed Jul 21, 2020.
- Sawes WL, Barnes IE. The surgical treatment of fenestrated buccal roots of an upper molar—a case report. *Int Endod J* 1983; 16(2):82–6.
- Boucher Y, Sobel M, Sauveur G. Persistent pain related to root canal filling and apical fenestration: a case report. *J Endod* 2000; 26(4):242–4.
- Jhaveri HM, Amberkar S, Galav L, Deshmukh VL, Aggarwal S. Management of mucosal fenestrations by interdisciplinary approach: a report of three cases. *J Endod* 2010; 36(1):164–8.
- Nimigeon VR, Nimigeon V, Bencze MA, Dimcevic-Poesina N, Cergan R, Moraru S. Alveolar bone dehiscences and fenestrations: an anatomical study and review. *Rom J Morphol Embryol* 2009; 50(3):391–7.
- Stahl SS, Cantor M, Zwig E. Fenestrations of the labial alveolar plate in human skulls. *Periodontics* 1963; 1(3):99–102.
- Jorgić-Srdjak K, Plancak D, Bosnjak A, Azinović Z. Incidence and distribution of dehiscences and fenestrations on human skulls. *Coll Antropol* 1998; 22 Suppl:111–6.
- Edel A. Alveolar bone fenestrations and dehiscences in dry Bedouin jaws. *J Clin Periodontol* 1981; 8(6):491–9.
- Rupprecht RD, Horning GM, Nicoll BK, Cohen ME. Prevalence of dehiscences and fenestrations in modern American skulls. *J Periodontol* 2001; 72(6):722–9.
- Chen G, Fang CT, Tong C. The management of mucosal fenestration: a report of two cases. *Int Endod J* 2009; 42(2):156–64.
- Jafri Z, Sultan N, Ahmad N, Daing A. An infrequent clinical case of mucosal fenestration: Treated with an interdisciplinary approach and regenerative therapy. *J Indian Soc Periodontol* 2019; 23(2):168–71.
- Furusawa M, Hayakawa H, Ida A, Ichinohe T. A case of apical fenestration misdiagnosed as persistent apical periodontitis. *Bull Tokyo Dent Coll* 2012; 53(1):23–6.
- Pasqualini D, Scotti N, Ambrogio P, Alovisi M, Berutti E. Atypical facial pain related to apical fenestration and overfilling. *Int Endod J* 2012; 45(7):670–7.
- Bains R, Bains V, Gupta S, Mishra P, Loomba K. Management of dehiscence and fenestration alveolar defects around incisors using platelet-rich fibrin: report of two cases. *J Interdiscip Dent* 2015; 5(2).
- Pan HY, Yang H, Zhang R, Yang YM, Wang H, Hu T, et al. Use of cone-beam computed tomography to evaluate the prevalence of root fenestration in a Chinese subpopulation. *Int Endod J* 2014; 47(1):10–9.
- Ricucci D, Siqueira JF Jr, Loghin S, Grosso A, Valois EM, Leal ASM. Management and histobacteriological findings of mucosal fenestration: a report of 2 cases. *J Endod* 2018; 44(10):1583–92.
- Gandi P, Anumala N, Reddy A, Chandra RV. A regenerative approach towards mucosal fenestration closure. *BMJ Case Rep* 2013; 2013:bcr2013009604.
- Serrano J. Gingivo-osseous pathologic fenestration. *Oral Surg Oral Med Oral Pathol* 1971; 32(5):697–700.
- Sharma S, Srivastava D, Sood V, Yadav P. Endodontic and periodontal management of a severely affected maxillary lateral incisor having combined mucosal fenestration and palatogingival groove. *J Indian Soc Periodontol* 2015; 19(3):348–51.
- Travassos R, Soares B, Bhandi SH, Silva MB, Bandéca MC, Mouchrek JC Jr, et al. Multidisciplinary treatment of a fenestration-type defect. *J Contemp Dent Pract* 2015; 16(4):329–34.
- Abdelmalek RG, Bissada NF. Incidence and distribution of alveolar bony dehiscence and fenestration in dry human Egyptian jaws. *J Periodontol* 1973; 44(9):586–8.
- Davies RM, Downer MC, Hull PS, Lennon MA. Alveolar defects in human skulls. *J Clin Periodontol* 1974; 1(2):107–11.
- Larato DC. Alveolar plate fenestrations and dehiscences of the human skull. *Oral Surg Oral Med Oral Pathol* 1970; 29(6):816–9.
- Urbani G, Lombardo G, Filippini P, Nocini FP. Dehiscence and fenestration: study of distribution and incidence in a homogeneous population model. [Article in Italian]. *Stomatol Mediterr* 1991; 11(2):113–8.
- Yoshioka T, Kikuchi I, Adorno CG, Suda H. Periapical bone defects of root filled teeth with persistent lesions evaluated by cone-beam computed tomography. *Int Endod J* 2011; 44(3):245–52.
- Rawlinson A. Treatment of a labial fenestration of a lower incisor tooth apex. *Br Dent J* 1984; 156(12):448–9.
- Tamse A. Vertical root fractures in endodontically treated teeth: diagnostic signs and clinical management. *Endod Top* 2006; 13(1):84–94.
- Nimigeon VR, Nimigeon V. Combined mucosal and alveolar fenestration: a clinical report and literature review. *Rom J Morphol Embryol* 2013; 54(2):437–41.
- Abbott PV. Classification, diagnosis and clinical manifestations of apical periodontitis. *Endod Top* 2004; 8(1):36–54.
- Agarwal V. Fenestration and dehiscence in a non vital tooth - a case report. *J Clin Diagn Res* 2010; 4(4):2971–3.
- Yang ZP. Treatment of labial fenestration of maxillary central incisor. *Endod Dent Traumatol* 1996; 12(2):104–8.
- Ju YR, Tsai AH, Wu YJ, Pan WL. Surgical intervention of mucosal fenestration in a maxillary premolar: a case report. *Quintessence Int* 2004; 35(2):125–8.
- Special committee to revise the joint AAE/AAOMR position statement on use of CBCT in endodontics. AAE and AAOMR joint position statement: use of cone beam computed tomography in endodontics 2015 update. *Oral Surg Oral Med Oral Pathol Oral Radiol* 2015; 120(4):508–12.
- Lin YC, Lee YY, Ho YC, Hsieh YC, Lai YL, Lee SY. Treatment of large apical lesions with mucosal fenestration: a clinical study with long-term evaluation. *J Endod* 2015; 41(4):563–7.
- Singh S, Panwar M, Arora V. Management of mucosal fenestration by multidisciplinary approach: A rare case report. *Med J Armed Forces India* 2013; 69(1):86–9.
- Dietrich T, Zunker P, Dietrich D, Bernimoulin JP. Periapical and periodontal healing after osseous grafting and guided tissue regeneration treatment of apicomarginal defects in periradicular surgery: results after 12 months. *Oral Surg Oral Med Oral Pathol Oral Radiol Endod* 2003; 95(4):474–82.
- Lin L, Chen MY, Ricucci D, Rosenberg PA. Guided tissue regeneration in periapical surgery. *J Endod* 2010; 36(4):618–25.
- Rankow HJ, Krasner PR. Endodontic applications of guided tissue regeneration in endodontic surgery. *Oral Health* 1996; 86(12):33–5, 37–40, 43.
- Tsesis I, Rosen E, Tamse A, Taschieri S, Del Fabbro M. Effect of guided tissue regeneration on the outcome of surgical endodontic treatment: a systematic review and meta-analysis. *J Endod* 2011; 37(8):1039–45.
- Tseng CC, Chen YH, Huang CC, Bowers GM. Correction of a large periradicular lesion and mucosal defect using combined endodontic and periodontal therapy: a case report. *Int J Periodontics Restorative Dent* 1995; 15(4):377–83.