

Lumbar pedicle screw fixation with cortical bone trajectory: A review from anatomical and biomechanical standpoints

Keitaro Matsukawa¹⁾ and Yoshiyuki Yato²⁾

1) Department of Orthopaedic Surgery, Self Defense Force Central Hospital, Tokyo, Japan

2) Department of Orthopaedic Surgery, National Hospital Organization, Murayama Medical Center, Musashimurayama, Tokyo, Japan

Abstract:

Over the past few decades, many attempts to enhance the integrity of the bone-screw interface have been made to prevent pedicle screw failure and to achieve a better clinical outcome when treating a variety of spinal disorders. Cortical bone trajectory (CBT) has been developed as an alternative to the traditional lumbar pedicle screw trajectory. Contrary to the traditional trajectory, which follows the anatomical axis of the pedicle from a lateral starting point, CBT starts at the lateral part of the pars interarticularis and follows a mediolateral and caudocranial screw path through the pedicle. By markedly altering the screw path, CBT has the advantage of achieving a higher level of thread contact with the cortical bone from the dorsal entry point to the vertebral body. Biomechanical studies demonstrated the superior anchoring ability of CBT over the traditional trajectory, even with a shorter and smaller CBT screw. Furthermore, screw insertion from a more medial and caudal starting point requires less exposure and minimizes the procedure-related morbidity, such as reducing damage to the paraspinous muscles, avoiding iatrogenic injury to the cranial facet joint, and maintaining neurovascular supply to the fused segment. Thus, the features of CBT, which enhance screw fixation with limited surgical exposure, have attracted the interest of surgeons as a new minimally invasive method for spinal fusion.

The purpose of this study was: 1) to identify the features of the CBT technique by reviewing previous anatomical and biomechanical literature, and 2) to describe its clinical application with a focus on the indications, limitations, surgical technique, and clinical evidence.

Keywords:

Cortical bone trajectory, Fixation strength, Lumbar pedicle screw, Minimally invasive surgery, Insertional technique, Adjacent segment disease

Spine Surg Relat Res 2017; 1(4): 164-173
dx.doi.org/10.22603/ssrr.1.2017-0006

Introduction

The pedicle screw fixation system has been accepted as the gold standard technique for spinal fusion because of its anchoring ability. However, problems of screw loosening, which can result in a loss of fixation and nonunion have not been resolved, particularly in patients with osteoporotic bone¹⁾. The fixation strength of pedicle screws in vertebral bone depends on three major factors: the vertebral geometry and bone quality, design and mechanical properties of the pedicle screw, and the screw insertional technique²⁾. One strategy for enhancing screw fixation is modification of the screw path before screw insertion, including the pilot and

tapping holes. Biomechanical studies demonstrated that a pilot hole size smaller than the core diameter of the screw and an under-size-tapping smaller than the outer diameter of the planned screw improve the fixation strength of pedicle screws^{3,4)}. Another strategy influencing screw fixation is alteration of the transpedicular screw path from the conventional screw path. Several authors reported that screw insertion vertically without convergence from a medialized starting point led to a greater pullout strength^{5,6)}. Considering regional variation and heterogeneous bone properties within the vertebra, the amount of denser bone contact contributes to the differences in bone-screw interface stability.

More markedly, Santoni and Hynes et al. proposed corti-

Corresponding author: Keitaro Matsukawa, keitaro197897@hotmail.com

Received: January 26, 2017, Accepted: March 6, 2017

Copyright © 2017 The Japanese Society for Spine Surgery and Related Research

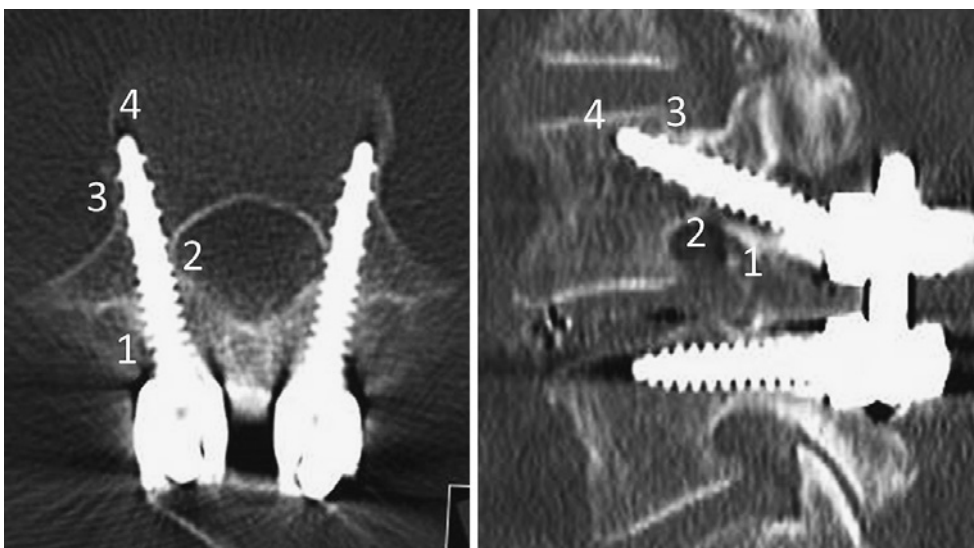


Figure 1. 4-point cortical contact of CBT.

Axial (left) and sagittal (right) CT slices along the axis of CBT screws. CBT can achieve a 4-point cortical contact between the dorsal lamina (1), inferomedial pedicle wall (2), anterolateral pedicle wall (3), and lateral curvature of the vertebral endplate (4).

cal bone trajectory (CBT) to increase purchase with a greater density bone⁷. CBT starts at the lateral part of the pars interarticularis and follows a mediolateral and caudo-cranial path through the pedicle. While traditional trajectory (TT) screws are inserted along the anatomical axis of the pedicle and rely on their stability mainly with cancellous bone in the pedicle and vertebral body⁸, CBT screws can maximize the contact between the screw thread and cortical bone within the complex structure of the vertebra by altering the screw trajectory in novel fashion⁹. Because cortical bone is less affected by the osteoporotic process than cancellous bone, the CBT technique has the possibility to reduce the incidence of screw loosening and subsequent fusion failure in osteoporotic patients. Additionally, screw insertion from a more medial and caudal starting point requires less exposure and minimizes the procedure-related morbidity: 1) it reduces paraspinal muscles dissection and retraction¹⁰, 2) it lessens iatrogenic injury to the mobile superior facet joint adjacent to the fused segment¹¹, and 3) it maintains neurovascular supply to the fused segment, such as the posteromedial branch of the nerve root passing near the mammillary process¹².

The purpose of this study was to review the anatomical and biomechanical characteristics of CBT and to describe its clinical application, including indications, limitations, surgical techniques, and clinical evidence.

Anatomical characteristics

CBT has the anatomical advantage of achieving a markedly increased thread contact with the cortical bone by setting a medial starting point and following a craniolateral direction. CT analyses demonstrated that Hounsfield units along CBT, even with shorter and smaller bone paths, were

four times higher than those along TT¹³, and this tendency was prominent with increasing generation¹⁴. Theoretically, CBT can achieve a 4-point cortical contact between the dorsal starting point, inferomedial pedicle wall, anterolateral pedicle wall, and lateral curvature of the vertebral endplate (Fig. 1)¹⁵. Among those, the starting point of the pars interarticularis is the anatomically densest lesion within the vertebral elements^{9,16,17}, and acts as a key component in the fixation of CBT¹⁸. In other words, the selection of the optimal starting point is the crucial factor for an improved bony purchase.

The original technique by Hynes proposed that the starting point was the junction of the center of the superior articular process and 1-2 mm inferior relative to the inferior border of the transverse process¹⁹. From a morphometric analysis of CBT, this point was typically close to the inferomedial border of the pedicle and corresponded to the 5 o'clock orientation in the left pedicle and the 7 o'clock orientation in the right pedicle (Fig. 2)¹⁵. This locational relationship between the starting point and pedicle was introduced as the "pedicle map"¹⁵, and is beneficial in deciding on the optimal starting point under the limited surgical exposure of the anatomical landmarks, especially for patients with severe degenerative change or cases requiring reoperation. The lateral pars is an identifiable structure and is less influenced by degenerative change;²⁰ therefore, it can be a good bony reference for the insertional location in the operative field²¹. The distance between the starting point and lateral margin of the pars gradually increased from L1 to L5 (L1: 0.8 mm, L2: 1.5 mm, L3: 2.0 mm, L4: 3.3 mm, L5: 4.7 mm) according to a previous morphometric study¹⁵.

As for the insertional direction, the trajectory moves from 5 (7) o'clock to 11 (1) o'clock orientation in the left (right) pedicle. CT analysis revealed that the direction was univer-

sally the same angle (cranial angle: 25-26°, lateral angle: 8-9°) regardless of lumbar spinal levels, which were widely different in their pedicular angulation and anatomic shape (Fig. 3)¹⁵⁾. Zhang et al. also conducted a morphometric measurement of CBT and demonstrated relatively similar results (cranial angle: 23-27°, lateral angle: 9-16°)²²⁾. Compar-

ing both results, the cranial angle was relatively consistent, and the disparity in the lateral angle might have been derived from differences in the location of the starting point and reviewed patient population, such as the sex and age.

Biomechanical characteristics

Fixation strength of CBT screw

Santoni et al. first reported the superiority of CBT screws in osteoporotic cadaveric lumbar spines⁷⁾. In their report, CBT screws (average 4.5-mm diameter and 29-mm length) demonstrated a 30% greater uniaxial pullout strength and equivalent strength against toggle loading as compared to TT screws (average 6.5-mm diameter and 51-mm length) (Table 1). More practically replicating a mechanism of pedicle screw loosening, Baluch et al. compared the fixation strength of CBT screws (average 4.5-mm diameter and 32-mm length) with that of TT screws (average 6.5-mm diameter and 45-mm length) under cyclic loads perpendicular to the screw axis, and demonstrated the superior resistance of CBT screws²³⁾. Another study also evaluated the mechanical behavior of CBT screws *in vivo* by measuring insertional torque²⁴⁾. The mean maximum insertional torque of CBT screws (5.5-mm diameter and 30- to 35-mm length) was 71% higher than that of TT screws (6.5- to 7.5-mm diameter

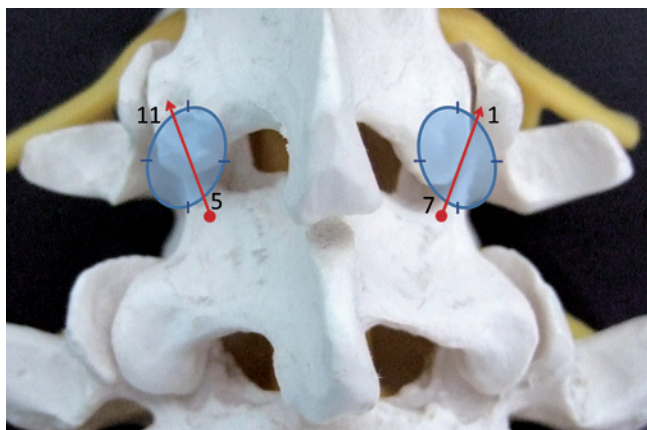


Figure 2. The starting point of CBT. In the left pedicle, CBT starts at the 5 o'clock orientation and moves to 11 o'clock orientation using the clock face. In the right pedicle, CBT starts at the 7 o'clock orientation and moves to the 1 o'clock orientation.

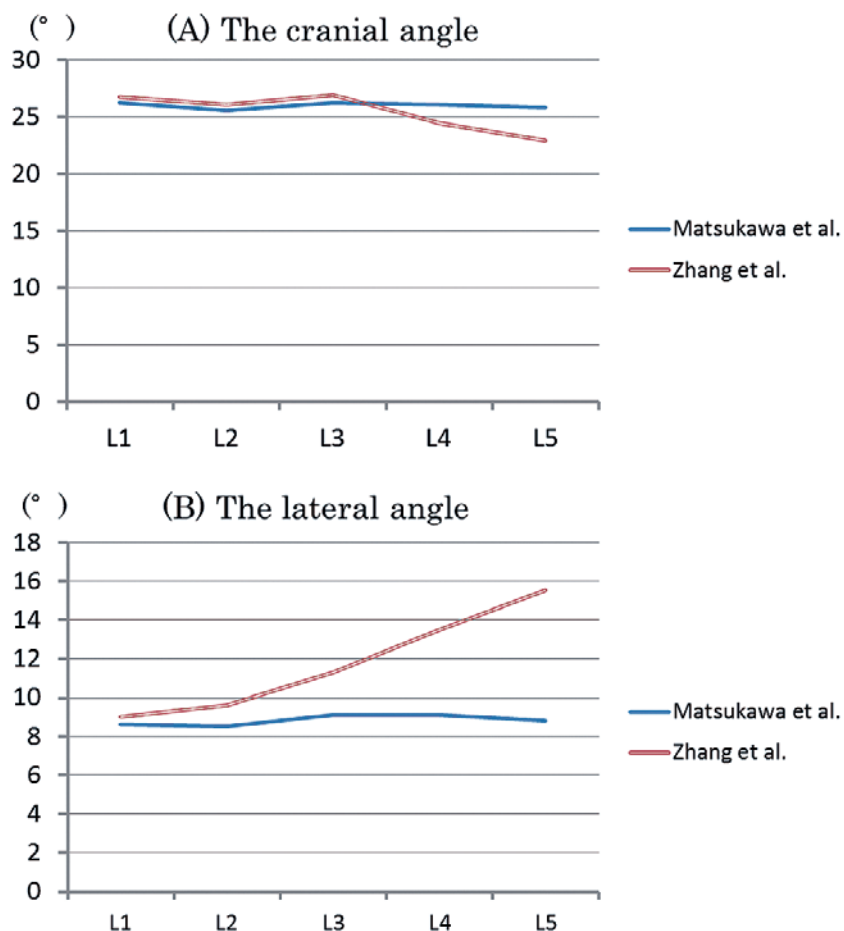


Figure 3. The insertional direction of CBT.

Table 1. Summary of the Comparative Biomechanical Studies between CBT and TT.

Author and year	Screw size of CBT	Screw size of TT	Mode	Results
Santoni et al. 2009 ⁷⁾	ϕ 4.5×29 mm	ϕ 6.5×51 mm	POS	CBT>TT
			Toggle	CBT=TT
Baluch et al. 2014 ²³⁾	ϕ 4.5×32 mm	ϕ 6.5×45 mm	Cyclic toggle	CBT>TT
Matsukawa et al. 2014 ²⁴⁾	ϕ 5.5×30-35 mm	ϕ 6.5-7.5×40 mm	Insertional torque	CBT>TT
Matsukawa et al. 2015 ²⁵⁾	ϕ 5.5×35 mm	ϕ 6.5×40 mm	POS (FEM)	CBT>TT
			Toggle (FEM)	CBT>TT
Wray et al. 2015 ²⁶⁾	ϕ 5.2-5.3×28-31 mm	ϕ 6.1-6.3×40-45 mm	POS	CBT=TT
			Toggle	CBT=TT
Akpolat et al. 2016 ²⁷⁾	ϕ 4.5×25 mm	ϕ 6.5×55 mm	Cyclic toggle	CBT<TT

CBT: cortical bone trajectory, TT: traditional trajectory, POS: pullout strength, and FEM: finite element method.

and 40-mm length). According to a finite element study, CBT screws (5.5-mm diameter and 35-mm length) demonstrated a 26% higher pullout strength, 28% greater resistance to cephalocaudal loading, and 140% greater resistance to mediolateral loading than TT screws (6.5-mm diameter and 40-mm length)²⁵⁾.

Contrary to these results, Wray et al. concluded in a cadaveric biomechanical study that there were no significant differences between CBT screws (5.2- to 5.3-mm diameter and 28- to 31-mm length) and TT screws (6.1- to 6.3-mm diameter and 40- to 45-mm length) in terms of the pullout strength and toggle resistance²⁶⁾. Akpolat et al. also demonstrated that CBT screws (4.5-mm diameter and 25-mm length) had a lower fatigue performance compared with TT screws (6.5-mm diameter and 55-mm length) in low-quality bone²⁷⁾. In their report, because CBT screws were inserted about 5 mm shallower than the full screw length to avoid screw head impingement against the dorsal lamina, a screw length of 25 mm was considered too short to resist loads perpendicular to the screw axis, even though screws had sufficient contact with the cortical bone.

Theoretically, the level of load applied to the vertebra is equal whether screws are inserted via TT or CBT; however, CBT screws, which are shorter and smaller than TT screws, have less surface area available within bone. In other words, mechanical stresses on the bone-screw interface per unit area using CBT are markedly higher than those using TT. Once CBT screw loosening has occurred, these higher stresses can cause the micro-motion of the screw and induce the acceleration of bone encroachment around the screw. To reduce the risk of screw loosening, a previous biomechanical study suggested that longer screws can improve the vertebral load distribution and decrease the mechanical stress on the bone-screw interface²⁸⁾.

Fixation strength of CBT construct

Although the CBT screw itself can provide greater mechanical performance, some biomechanical studies suggested that the spinal construct using CBT provided less rigid fixation against lateral bending and axial rotation loadings. Perez-Orribo et al. compared the biomechanical stability of one segmental screw-rod construct between TT and CBT us-

ing nondestructive flexibility tests on cadaveric lumbar spines²⁹⁾. No significant differences were observed during any kind of loading; however, the TT construct was significantly stiffer than the CBT construct during lateral bending and axial rotation under the condition of intact disc or transforaminal lumbar interbody support. Another biomechanical study using the finite element method revealed that the CBT paired-screw construct showed 51% higher vertebral fixation strength on flexion loading and 35% higher on extension, but 20% lower vertebral fixation strength on lateral bending and 37% lower on axial rotation, when compared with the TT construct²⁵⁾. Because these tendencies were invariably observed regardless of the bone density, the disadvantages of CBT, such as a divergent trajectory and short lever arm from the median axis, could be associated with these drawbacks.

To improve the vertebral stability against lateral bending and axial rotation, the following two points are advocated: 1) to enhance each screw's anchoring ability within a construct as much as possible by selecting the optimal screw trajectory and screw size^{18,28)}, and 2) to take countermeasures against torsional motion for the screw-rod construct by preservation of the facet joint³⁰⁾, large interbody grafting to reconstruct anterior column support³¹⁾, and the addition of a crosslink connector³²⁾.

Indications and limitations

The CBT technique is indicated for almost all lumbar spinal disorders without spondylolysis and severe spinal deformity, particularly in the lower lumbar spine. The anatomic characteristics of the lower spine, such as the deep-seated screw entry point, large volume of paraspinal muscles, and larger medialized pedicle axis from a more lateral entry point, necessitate extensive muscle dissection and retraction to insert a pedicle screw in a convergent direction compared with those of the upper spine. In contrast, CBT screws can be implanted with less muscle dissection in a divergent direction (Fig. 4). These findings become more notable in the case of obese patients with a deep surgical corridor. From a biomechanical point of view, the pedicle diameter of the lower spine is large and involves difficulty in optimal thread contact with subcortical bone of the pedicle³³⁾,

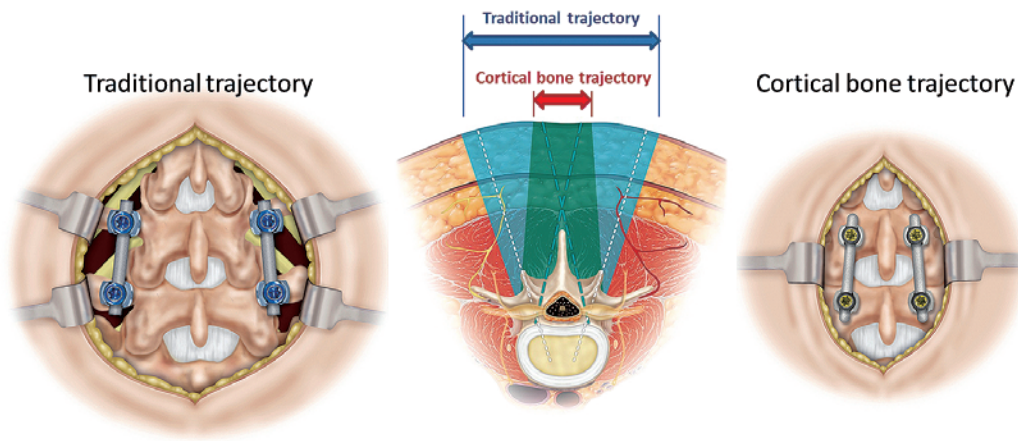


Figure 4. Comparison in the surgical exposure between traditional trajectory and cortical bone trajectory.

CBT screws can be implanted with less muscle dissection in a divergent direction compared with TT screws in a convergent direction (used with permission from Medtronic Inc. (Memphis, TN, USA)).

which is the most critical part of fixation for TT screws. In contrast, CBT screws can achieve rigid fixation, regardless of the pedicle size, by increasing engagement with the denser bone. For the reasons mentioned above, the most appropriate indication is short segmental fusion for lower lumbar pathologies; however, it can also be adapted for long segment fusion³⁴⁻³⁶. Care should be taken when placing screws in the upper spine because of a narrow pars and small pedicle¹⁵, associated with the potential risk of pars and pedicle fractures.

Another indication is as a salvage technique. Increasing the diameter and length of screws is a conventional recovery technique in cases of fixation failure after TT screw placement. Since CBT follows a widely different screw path from the traditional anatomical transpedicular trajectory, it can be an option for a compromised screw path, such as screw misplacement, screw loosening, and pseudoarthrosis. Supporting this, one biomechanical cadaveric study comparing the fixation of CBT and TT screws used for revision at the same pedicle found that CBT and TT screws each retain adequate construct stability³⁷.

On the other hand, surgeons should note some contraindications. One is spondylolytic vertebra, similarly including a pars defect secondary to a wide bony decompression, because spondylolytic vertebra lack cortical regions of the posterior element on which CBT screws rely for most of their stability^{9,16,17}. In terms of the fixation strength of CBT screws in spondylolytic vertebra, compared with that in normal vertebra, Ninomiya et al. reported a 50% lower insertional torque³⁸, and a finite element study demonstrated a 20% lower pullout strength and 30-40% lower vertebral fixation strength³⁹.

Another contraindication is severe spinal deformity with horizontal vertebral rotation. As aforementioned in the section on biomechanical characteristics, CBT is divergent and involves a short trajectory, and fails to traverse sufficiently deep enough through the instantaneous axis of rotation;

therefore, the screws cannot deliver enough rotational force to the anterior column to derotate the vertebral body.

Surgical technique

Biomechanical ideal trajectory

The following three points are essential for CBT to achieve better fixation and clinical results: 1) maximization of the thread contact with the cortical bone, 2) screw placement sufficiently deep into the vertebral body to enhance the holding power and effectively distribute the axial load, 3) avoidance of impingement with the adjacent cranial facet joint. A previous biomechanical study recommended the ideal trajectory as follows: 1) screw insertion from a caudal point, 2) cortical bone contact within the lamina, 3) passing the inferior border of the pedicle, 4) toward the posterior third to the posterior half of the superior vertebral endplate, and 5) following a 25-30° cranially and 10° laterally directed path (Fig. 5A, B)¹⁸. Contrary to the original CBT technique reported by Santoni et al. using 25-30-mm length screws⁷, the ideal trajectory extends deeper into the vertebral column using 35-40-mm length screws (Fig. 5C)¹⁸. Special attention should be paid to this narrow bony channel; therefore, the use of intraoperative image guidance is useful for achieving the correct trajectory and reducing the risk of neural injury by the inferomedial pedicle wall breach. Although the CBT technique may require more radiation exposure than the TT technique during screw placement, CBT screws can be inserted accurately and safely with sufficiently short fluoroscopic time (less than five seconds per screw).

Surgical procedure

A midline incision is made at the affected level in a prone position. The paraspinal muscles are dissected and retracted to the point exposing the lateral borders of the pars interarticularis, preserving the supra/interspinous ligaments, and

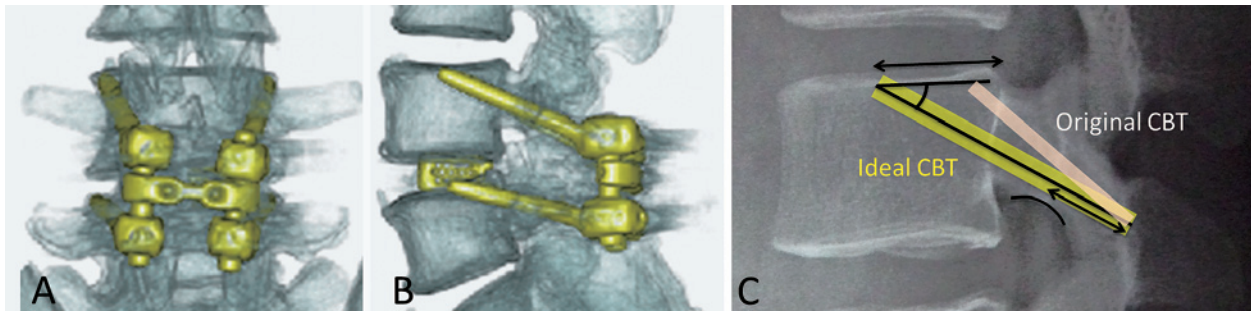


Figure 5. Illustrations demonstrating the ideal trajectory.

The ideal CBT starts at a caudal point of the pars interarticularis, follows a 25-30° cranially and 10° laterally-directed path through the inferior border of the pedicle, and ends up at the posterior third to the posterior half of the superior vertebral endplate (A, B). Contrary to the original CBT, the ideal CBT extends deeper into the vertebral column (C).

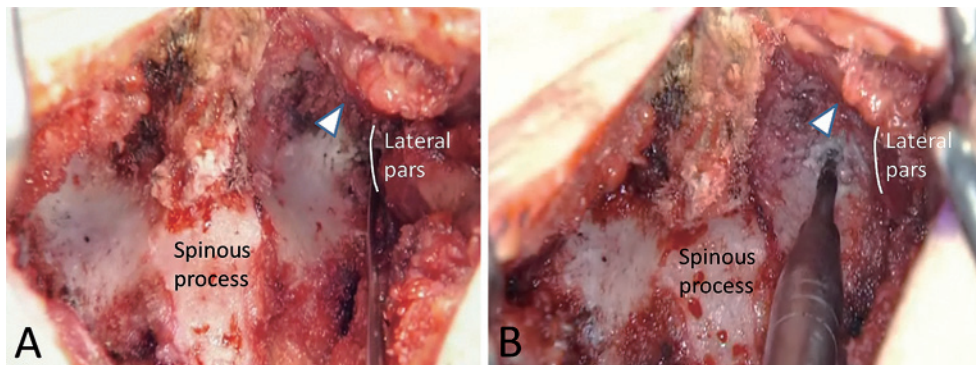


Figure 6. Creation of the starting point.

A, Exposure of lateral borders of the pars interarticularis preserving the superior adjacent facet joint (arrowhead)

B, Creation of the starting points using a 2-mm high-speed round burr

avoiding the exposure of facet joints adjacent to the fused segment. The spinous process is partially resected to achieve the appropriate lateral angulation for the trajectory.

Screw hole creation is preferred before the decompression procedure to achieve an ideal trajectory and avoid excessive bone resection. After direct visualization of the pars interarticularis (Fig. 6A), small divots (four divots for one segmental fusion) at the starting point are made using a 2-mm high-speed round burr drill under true anteroposterior fluoroscopic guidance (Fig. 6B). These points correspond to a 5 or 7 o'clock orientation in the pedicle. Since the spur formation and hypertrophy of the cranial facet joint can overhang to the pars interarticularis in cases with severe facet degeneration, selection of lower entry point, as much as possible, is desirable to avoid damage to the adjacent mobile segment¹¹. Following this, the screw paths are made under true lateral fluoroscopic guidance to be directed 25-30° cranially along the inferior border of the pedicle toward the posterior third to posterior half of the superior endplate, using the burr and a straight probe (Fig. 7). The starting point is at the laminar slope as it inclines cranially; thus, surgeons should prevent slippage toward the cranial side during the procedure, which may induce unintentional cranial facet joint violation by the screws¹¹. Because the starting points are lo-

cated around the medial border of the pedicle, a lateral angle of 10° is sufficient to avoid the risk of central neural injury. Special care should also be taken to check the trajectory and not breach the inferomedial border of the pedicle, which is close to the exiting nerve root. A desirable screw path length is 30-35 mm, not penetrating the superior endplate or lateral wall of the vertebral body. Bi-cortical fixation is not preferred to avoid potential injury to the superior adjacent intervertebral disk and the lumbar plexus traversing the lateral vertebral body. Following confirmation of the correctness of the screw path by palpation with a pedicle sounder, short L-shaped wires are placed to mark the screw paths (Fig. 8).

Posterior decompression should be performed before screw insertion because a medial position of the screw head will interfere with appropriate decompression and interbody work. During the decompression procedure, it is important to preserve a safe distance of at least 5 mm between the previously created pilot hole and margin of bony resection to avoid pars fracture, which leads to immediate fixation failure (Fig. 9). Then, two interbody cages with an autograft are placed as anteriorly as possible to withstand axial loading.

The screw paths are tapped line to line relative to the di-

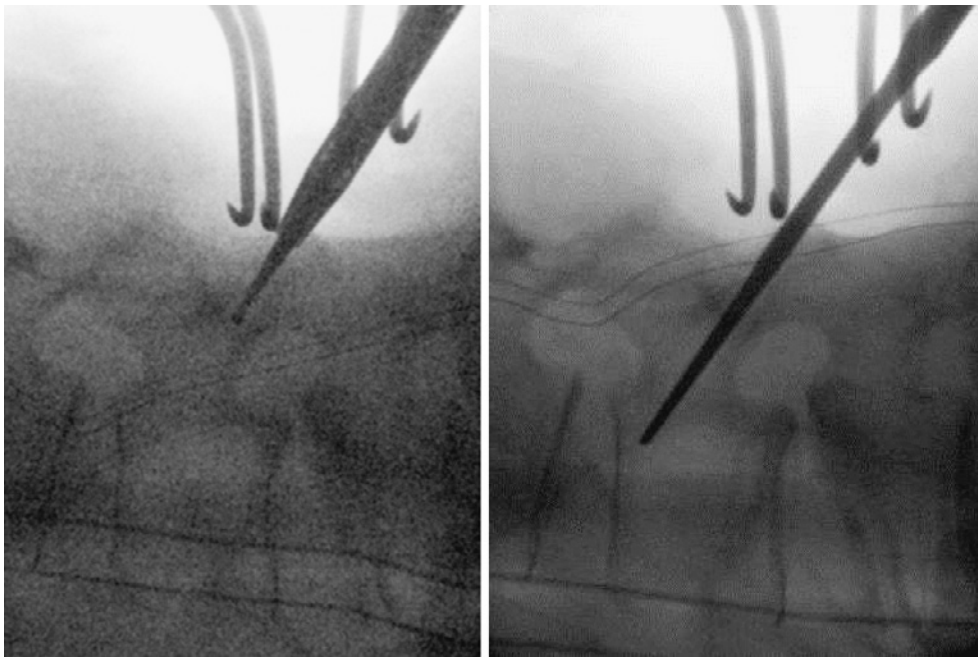


Figure 7. Creation of the screw path.

The Screw path is made under lateral fluoroscopic guidance toward the posterior third to posterior half of the superior endplate, using the burr (left) and a straight probe (right).

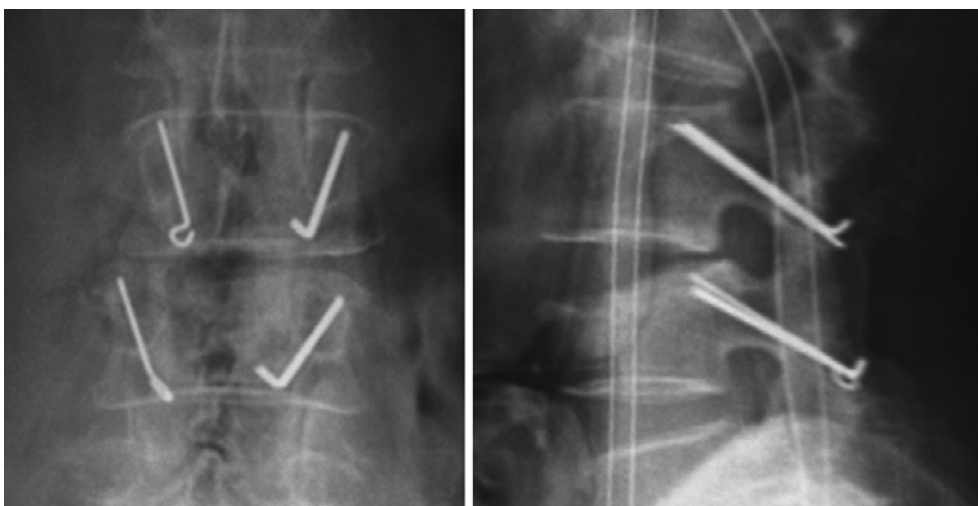


Figure 8. Short L-shaped markers on the anteroposterior view (left) and lateral view (right).

ameter of the planned screw to prevent cortical fissures at the pars/pedicle during screw insertion. The screw length is determined by the measured path length plus 5 mm, because the screw is inserted at a depth not to impinge the screw head on the dorsal lamina in order to avoid both cranial facet joint violation and the “hubbing” phenomenon^{11,40,41}. The standard screw size was 5.5 mm in diameter (4.5 mm for the upper lumbar vertebra) and 35-40 mm in length. Needless to say, the saddle position of the screw head decided the rod placement; thus, the use of screws with a polyaxial head is necessary (Fig. 10A)⁴¹.

Lastly, rods are connected to the screw heads under compression force between the screws to fix in lordotic alignment. Surgeons usually have to use a fixed-type crosslink

connector, not a variable-type connector, due to the short distance between two bilateral rods. Care should be taken to place the bilateral rods in parallel positions for easier connection (Fig. 10B).

Recent clinical evidence

Radiological prospect

Pedicle screw loosening is caused when the loading weight overwhelms the fixation strength at the bone-screw interface. Several authors have reported a lower incidence of screw loosening of CBT due to the reliable purchase of cortical bone⁴²⁻⁴⁴, although other studies have reported opposite

results^{45,46}. Because multiple factors, such as the pathology, bone quality, screw size, screw trajectory, strength of anterior column support, and fusion procedure, are related to the occurrence of screw loosening, these results should be interpreted with caution. A further study is needed to completely elucidate this topic.

For successful clinical results, the screw-rod construct must maintain stability until bony arthrodesis is appropriately achieved. Lee et al. first reported a prospective comparative study between the CBT and TT technique on per-

forming the single-level posterior lumbar interbody fusion (PLIF) procedure⁴³. There was no significant difference in the bony fusion rate during a one-year follow-up (CBT vs. TT: 92 vs. 87%). Kasukawa et al. also showed that the fusion rate using the CBT technique (91%) was not significantly different when compared with that using the TT technique via the Wiltse approach (83%) or percutaneous approach (100%)⁴⁷. These studies demonstrated satisfactory results; however, the sample size was small and various kinds of lumbar pathologies were included. More precisely, Sakaura et al. conducted a retrospective comparative study of 177 patients who underwent PLIF for degenerative lumbar spondylolisthesis (95 patients by the CBT technique vs. 82 controls by the TT technique) during a 3-year postoperative follow-up⁴⁸. The fusion rate with the CBT technique was lower than that with the TT technique, although the difference was not significant (CBT vs. TT: 88 vs. 96%). The authors suggested that micromotion during torsional loading might lead to the lower fusion rate associated with the CBT technique, and proposed the use of a transverse connector to increase spinal construct stiffness.

In addition, the capacity of vertebral slip reduction is another concern for surgeons to manage patients with degenerative lumbar spondylolisthesis. CBT screws have to be inserted after interbody work; therefore, the correction procedure involving the anteroposterior directional force is performed in the setting of previously placed interbody cages. As a consequence, some friction must occur between the vertebral endplate and interbody cage surface, and this inhibits transmission of the corrective force on lifting the slipped vertebra. In spite of this adverse effect on the surgical procedure, Mori et al. reported excellent radiologic outcomes with a 2-year-follow-up. The mean preoperative %slip (23%) was significantly reduced immediately after surgery (2.7%), and the reduction was maintained well until

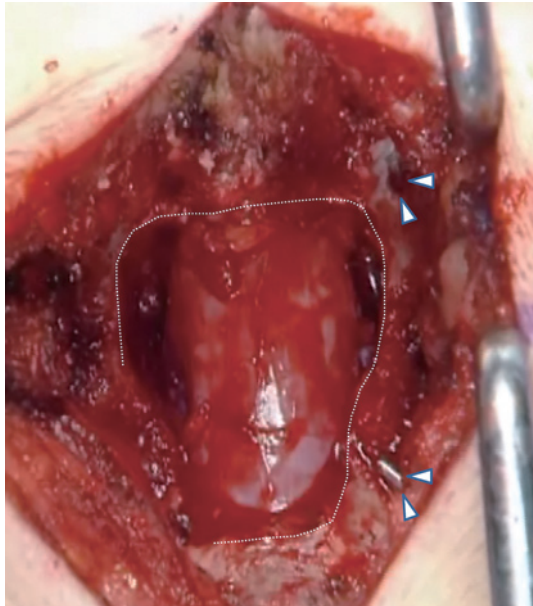


Figure 9. Screw hole and the bony margin. A safe distance of at least 5 mm between the created screw hole (arrow head) and margin of bony resection (interrupted curve) is mandatory to avoid pars fracture.

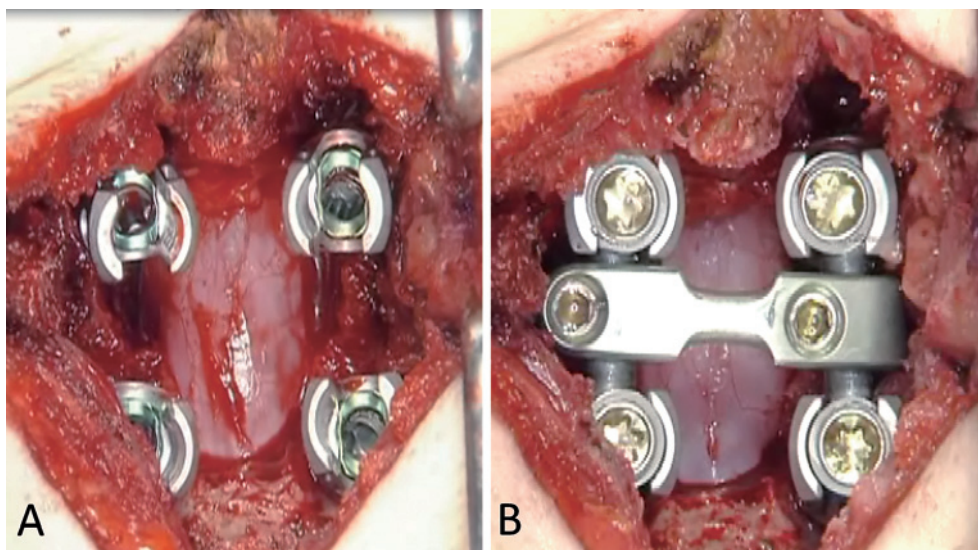


Figure 10. Screw placement and final construct.
A: Screw placement
B: Final construct with rods and a crosslink connector

the final follow-up (3.8%)⁴⁹⁾. Takata et al. reported a similar result in the treatment of L4 spondylolisthesis (preoperative %slip: 20%, postoperative %slip: 4/5%)⁵⁰⁾. These satisfactory outcomes may have been due to the advantage of the strong anteroposterior pullout resistance of CBT screws.

Clinical prospect

The advantage of the CBT technique is that spinal decompression, interbody fusion, and screw insertion are possible with only one limited midline approach, which is familiar to spinal surgeons. So, this technique has gained in popularity and facilitated reductions in approach-related soft tissue injury, the operative time, blood loss, perioperative complication rates, postoperative pain, and a shorter hospital stay^{10,42,43,47,51,52)}. More interestingly, a recent study showed a lower incidence of symptomatic adjacent segment disease (ASD) after PLIF using the CBT technique compared with that using the TT technique based on a three-year follow-up (CBT vs. TT: 3.2 vs. 11%, $p < 0.05$)⁴⁸⁾. Since the development of ASD is one of the major problems requiring additional surgical treatment, reduction in the incidence of ASD is a meaningful advantage using CBT. The CBT technique may become a standard fusion procedure not only to achieve better short-term clinical outcomes but also to prevent fusion disease in the future.

Conclusions

Many biomechanical and clinical studies demonstrated that the CBT technique can offer several benefits over the TT technique. This technique has been developed as an attractive alternative to the TT technique for lumbar spinal fusion in all patients; however, comparative clinical studies are still lacking. More studies should focus on long-term clinical and radiological outcomes to further elucidate the utility of the CBT technique.

Conflicts of Interest: The authors declare no conflicts of interest regarding this study.

References

- Hu SS. Internal fixation in the osteoporotic spine. *Spine*. 1997;22 (24 Suppl):S43-8.
- Cho W, Cho SK, Wu C. The biomechanics of pedicle screw-based instrumentation. *J Bone Joint Surg*. 2010;92(8):1061-5.
- Kuklo TR, Lehman RA. Effect of various tapping diameters on insertion of thoracic pedicle screws: a biomechanical analysis. *Spine*. 2003;28(18):2066-71.
- Silva P, Rosa RC, Shimano AC, et al. Effect of pilot hole on biomechanical and in vivo pedicle screw-bone interface. *Eur Spine J*. 2013;22(8):1829-36.
- Inceoglu S, Montgomery WH, Clair SS, et al. Pedicle screw insertion angle and pullout strength: Comparison of 2 proposed strategies. *J Neurosurg Spine*. 2011;14(5):670-6.
- Sterba W, Kim D-G, Fyhrie DP, et al. Biomechanical analysis of differing pedicle screw insertion angles. *Clin Biomech*. 2007;22 (4):385-91.
- Santoni BG, Hynes RA, McGilvary KC, et al. Cortical bone trajectory for lumbar pedicle screws. *Spine J*. 2009;9(5):366-73.
- Hirano T, Hasegawa K, Takahashi HE, et al. Structural characteristics of the pedicle and its role in screw stability. *Spine*. 1997;22 (21):2504-9.
- Matsukawa K, Yato Y, Hynes RA, et al. Comparison of pedicle screw fixation strength among different transpedicular trajectories: a finite element study. *Clin Spine Surg*. 2016; Epub ahead of print. DOI: 10.1097/BSD.0000000000000258
- Hung CW, Wu MF, Hong RT, et al. Comparison of multifidus muscle atrophy after posterior lumbar interbody fusion with conventional and cortical bone trajectory. *Clin Neurol Neurosurg*. 2016;145:41-5.
- Matsukawa K, Kato T, Yato Y, et al. Incidence and risk factors of adjacent cranial facet violation following pedicle screw insertion using cortical bone trajectory technique. *Spine*. 2016;41:E851-6.
- Regev GJ, Lee YP, Taylor WR, et al. Nerve injury to the posterior rami medial branch during the insertion of pedicle screws. *Spine*. 2009;34(11):1239-42.
- Kojima K, Asamoto S, Kobayashi Y, et al. Cortical bone trajectory and traditional trajectory—a radiological evaluation of screw-bone contact. *Acta Neurochir*. 2015;157(7):1173-8.
- Mai HT, Mitchell SM, Hashmi SZ, et al. Differences in bone mineral density of fixation points between lumbar cortical and traditional pedicle screws. *Spine J*. 2016;16(7):835-841.
- Matsukawa K, Yato Y, Nemoto O, et al. Morphometric measurement of cortical bone trajectory for lumbar pedicle screw insertion using computed tomography. *J Spinal Disord Tech*. 2013;26(6): E248-E53.
- Ivanov AA, Faizan A, Ebraheim NA, et al. The effect of removing the lateral part of the pars interarticularis on stress distribution at the neural arch in lumbar foraminal microdecompression at L3-L4 and L4-L5. *Spine*. 2007;32(22):2462-6.
- Weiner BK, Walker M, Wiley W, et al. The lateral buttress: an anatomic feature of the lumbar pars interarticularis. *Spine*. 2002; 27(17):E385-7.
- Matsukawa K, Taguchi E, Yato Y, et al. Evaluation of the fixation strength of pedicle screws using cortical bone trajectory: what is the ideal trajectory for optimal fixation? *Spine*. 2015;40(15):E873-8.
- Hynes RA: CD HORIZON LEGACY system cortical bone screw: surgical technique. Medtronic Sofamor Danek, Memphis TN USA, 2009, p.1-21.
- Su BW, Kim PD, Cha TD, et al. An anatomical study of the mid-lateral pars relative to the pedicle footprint in the lower lumbar spine. *Spine*. 2009;34(13):1355-62.
- Iwatsuki K, Yoshimine T, Ohnishi Y, et al. Isthmus-guided cortical bone trajectory for pedicle screw insertion. *Orthop Surg*. 2014;6 (3):244-8.
- Zhang H, Ajiboye RM, Shamie AN, et al. Morphometric measurement of the lumbosacral spine for minimally invasive cortical bone trajectory implant using computed tomography. *Eur Spine J*. 2016; 25(3):870-6.
- Baluch DA, Patel AA, Lullo B, et al. Effect of physiological loads on cortical and traditional pedicle screw fixation. *Spine*. 2014;39 (22):E1297-E302.
- Matsukawa K, Yato Y, Kato T, et al. In vivo analysis of insertional torque during pedicle screwing using cortical bone trajectory technique. *Spine*. 2014;39(4):E240-5.
- Matsukawa K, Yato Y, Imabayashi H, et al. Biomechanical evaluation of fixation strength of lumbar pedicle screw using cortical bone trajectory: a finite element study. *J Neurosurg Spine*. 2015;23

- (4):471-8.
26. Wray S, Mimran R, Vadapalli S, et al. Pedicle screw placement in the lumbar spine: effect of trajectory and screw design on acute biomechanical purchase. *J Neurosurg Spine* 2015;22(5):503-10.
 27. Akpolat YT, Inceoglu S, Kinne N, et al. Fatigue performance of cortical bone trajectory screw compared with standard trajectory pedicle screw. *Spine*. 2016;41(6):E335-41.
 28. Matsukawa K, Yato Y, Imabayashi H, et al. Biomechanical evaluation of fixation strength among different sizes of pedicle screws using the cortical bone trajectory: what is the ideal screw size for optimal fixation? *Acta Neurochir*. 2016;158(3):465-71.
 29. Perez-Orribo L, Kalb S, Reyes PM, et al. Biomechanics of lumbar cortical screw-rod fixation versus pedicle screw-rod fixation with and without interbody support. *Spine*. 2013;38(8):635-41.
 30. Abumi K, Panjabi M, Kramer KM, et al. Biomechanical evaluation of lumbar spinal stability after graded facetectomy. *Spine*. 1990;15(11):1142-7.
 31. Faizan A, Kiapour A, Kiapour AM, et al. Biomechanical analysis of various footprints of transforaminal lumbar interbody fusion devices. *J Spinal Disord Tech*. 2014;27(4):E118-27.
 32. Wahba GM, Bhatia N, Bui CNH, et al. Biomechanical evaluation of short-segment posterior instrumentation with and without crosslinks in a human cadaveric unstable thoracolumbar burst fracture model. *Spine*. 2010;35(3):278-85.
 33. Sansur CA, Caffes NM, Ibrahim DM, et al. Biomechanical fixation properties of cortical versus transpedicular screws in the osteoporotic lumbar spine: an in vitro human cadaveric model. *J Neurosurg Spine*. 2016;25(4):467-76.
 34. Matsukawa K, Yato Y, Hynes RA, et al. Cortical bone trajectory for thoracic pedicle screw: a technical note. *Clin Spine Surg*. 2016; Epub ahead of print. DOI: 10.1097/BSD.0000000000000130
 35. Matsukawa K, Yato Y, Kato T, et al. Cortical bone trajectory for lumbosacral fixation: penetrating S-1 endplate screw technique. *J Neurosurg Spine*. 2014;21(2):203-9.
 36. Xuan J, Zhang D, Jin HM, et al. Minimally invasive cortical bone trajectory screws placement via pedicle or pedicle rib unit in the lower thoracic spine: a cadaveric and radiographic study. *Eur Spine J*. 2016;25(12):4199-207.
 37. Calvert GC, Lawrence BD, Abtahi AM, et al. Cortical screws used to rescue failed lumbar pedicle screw construct: a biomechanical analysis. *J Neurosurg Spine*. 2015;22(2):166-72.
 38. Ninomiya K, Iwatsuki K, Ohnishi Y, et al. Significance of the pars interarticularis in the cortical bone trajectory screw technique: an in vivo insertional torque study. *Asian Spine J*. 2016;10(5):901-6.
 39. Matsukawa K, Yato Y, Imabayashi H, et al. Biomechanical evaluation of lumbar pedicle screws in spondylolytic vertebrae: comparison of fixation strength between the traditional trajectory and a cortical bone trajectory. *J Neurosurg Spine*. 2016;24(6):910-5.
 40. Paik H, Dmitriev AE, Lehman RA, et al. The biomechanical effect of pedicle screw hubbing on pullout resistance in the thoracic spine. *Spine J*. 2012;12(5):417-24.
 41. Cheng WK, Akpolat YT, Inceoglu S, et al. Pars and pedicle fracture and screw loosening associated with cortical bone trajectory: a case series and proposed mechanism through a cadaveric study. *Spine J*. 2016;16(2):E59-65.
 42. Chin KR, Pencle FJ, Coombs AV, et al. Clinical outcomes with midline cortical bone trajectory pedicle screws versus traditional pedicle screws in moving lumbar fusions from hospitals to outpatient surgery centers. *Clin Spine Surg*. 2016; Epub ahead of print. DOI: 10.1097/BSD.0000000000000436.
 43. Lee GW, Son JH, Ahn MW, et al. The comparison of pedicle screw and cortical screw in posterior lumbar interbody fusion: a prospective randomized noninferiority trial. *Spine J*. 2015;15(7):1519-26.
 44. Ninomiya K, Iwatsuki K, Ohnishi Y, et al. Clear-zone formation around screws in the early postoperative stages after posterior lumbar fusion using the cortical bone trajectory technique. *Asian Spine J*. 2015;9(6):884-8.
 45. Glennie RA, Dea N, Kwon BK, et al. Early clinical results with cortically based pedicle screw trajectory for fusion of the degenerative lumbar spine. *J Clin Neurosci*. 2015;22(6):972-5.
 46. Patel SS, Cheng WK, Danisa OA. Early complications after instrumentation of the lumbar spine using cortical bone trajectory technique. *J Clin Neurosci*. 2016;24:63-7.
 47. Kasukawa Y, Miyakoshi N, Hongo M, et al. Short-term results of transforaminal lumbar interbody fusion using pedicle screw with cortical bone trajectory compared with conventional trajectory. *Asian Spine J*. 2015;9(3):440-8.
 48. Sakaura H, Miwa T, Yamashita T, et al. Posterior lumbar interbody fusion with cortical bone trajectory screw fixation versus posterior lumbar interbody fusion using traditional pedicle screw fixation for degenerative lumbar spondylolisthesis: a comparative study. *J Neurosurg Spine*. 2016;25(5):591-5.
 49. Mori K, Nishizawa K, Nakamura A, et al. Short-term clinical result of cortical bone trajectory technique for the treatment of degenerative lumbar spondylolisthesis with more than 1-year follow-up. *Asian Spine J*. 2016;10(2):238-44.
 50. Takata Y, Matsuura T, Higashino K, et al. Hybrid technique of cortical bone trajectory and pedicle screwing for minimally invasive spine reconstruction surgery: a technical note. *J Med Invest*. 2014;61(3-4):388-92.
 51. Dabbous B, Brown D, Tsitlakidis A, et al. Clinical outcomes during the learning curve of MIDline Lumbar Fusion (MIDLF[®]) using the cortical bone trajectory. *Acta Neurochir*. 2016;158(7):1413-20.
 52. Khanna N, Deol G, Poulter G, et al. Medialized, muscle-splitting approach for posterior lumbar interbody fusion. *Spine*. 2016;41 (Suppl):S90-6.

Spine Surgery and Related Research is an Open Access article distributed under the Creative Commons Attribution - NonCommercial - NoDerivatives 4.0 International License. To view the details of this license, please visit (<https://creativecommons.org/licenses/by-nc-nd/4.0/>).