

Case report

Bellini duct carcinoma of the kidney masquerading as an iliac bone tumour in an adult Nigerian



Abdulkadir Ayo Salako¹, Tajudeen Adeniran Badmus¹, Innocent Ikem², Kayode Adelusola³, Ayodele Elkanah Orimolade², Martin Chukwudum Igbokwe^{1&}, Kelechi Mc'Clement Onuoha², Foluke Olanike Irabor³

¹Urology Unit, Department of Surgery, Obafemi Awolowo University Teaching Hospitals Complex, Ile-Ife, Nigeria, ²Department of Orthopaedics and Traumatology, Obafemi Awolowo University Teaching Hospitals Complex, Ile-Ife, Nigeria, ³Department of Morbid Anatomy, Obafemi Awolowo University Teaching Hospitals Complex, Ile-Ife, Nigeria

[&]Corresponding author: Martin Chukwudum Igbokwe, Urology Unit, Department of Surgery, Obafemi Awolowo University Teaching Hospitals Complex, Ile-Ife, Nigeria

Key words: Bellini duct carcinoma, iliac bone tumour, Ile-Ife, Nigeria

Received: 26/03/2017 - Accepted: 28/07/2017 - Published: 03/08/2017

Abstract

Bellini Duct Carcinoma (BDC) of the Kidney is a rare type of Renal Cell Carcinoma. It usually presents with features of local advancement or metastasis and rarely diagnosed incidentally. We present a case report of a young man who was found to have BDC of the Right Kidney following presentation with an iliac bone tumour. A 40 year old man presented to the Orthopaedic outpatient clinic on account of right sided pelvic pain and limping following a trivial fall at home. There was no antecedent history of loin pain, loin mass or haematuria. On evaluation, he was found to have a huge right iliac bone tumour invading the contiguous muscles. An incidental hypodense central ipsilateral renal mass with enlarged peri-hilar lymph nodes were found. He subsequently had right radical nephrectomy via a right sub-coastal approach and wide local excision of the Iliac bone tumour in two separate procedures. The resection margins were negative for tumour cells. Histology of the resected specimens were consistent with a metastatic right BDC of the kidney. He had a smooth post-operative recovery. One third of BDC of the kidney presents with metastasis. A high index of suspicion is required in order to diagnose BDC following such unusual presentations.

Pan African Medical Journal. 2017; 27:245 doi:10.11604/pamj.2017.27.245.12352

This article is available online at: <http://www.panafrican-med-journal.com/content/article/27/245/full/>

© Abdulkadir Ayo Salako et al. The Pan African Medical Journal - ISSN 1937-8688. This is an Open Access article distributed under the terms of the Creative Commons Attribution License (<http://creativecommons.org/licenses/by/2.0>), which permits unrestricted use, distribution, and reproduction in any medium, provided the original work is properly cited.

Introduction

Renal Cell Carcinoma (RCC) has also been called the "Internist's tumour" due to the myriad of ways it may present [1]. Bellini duct carcinoma (BDC) is a rare type of RCC accounting for less than 3% of Renal Carcinomas [2, 3]. In Nigeria, BDC has been reported as a slightly higher fraction of RCC (4%) by Tijani et al [4]. A 7-year retrospective review of RCC in our center between 2007 and 2014 during which a total of 51 cases of RCC were managed showed no case of BDC [5]. Forty percent (40%) of BDC are known to present with metastatic disease with 66% succumbing to the disease within 2 years of presentation, [6]. It has been found to be more common in men of African descent when compared with Caucasians [7]. The typical clinical presentation is similar to that of clear cell RCC though symptoms from metastatic disease or paraneoplastic syndromes at presentation have been described [8]. These features include gross hematuria, loin pain, loin mass and general weakness [5]. Unusual presentations reported in literature include acute renal failure and cervical lymphadenopathy (Kru Lin et al), multiple osteoblastic bone lesions (Nakamura et al) and meningeal carcinomatosis (Ohnishi et al) [2, 9, 10]. The diagnoses in these cases were not made till autopsy due to the bizzare presentations. We present in this report a 40 year old man with a rare metastatic BDC to the iliac bone managed by the Urology and Orthopaedic Units, Obafemi Awolowo University Teaching Hospital, Ile-Ife, Osun state, Nigeria.

Patient and observation

A 40-year-old man presented to the Orthopaedic out-patient clinic on account of a month history of right sided pelvic pain and a limp following a trivial fall at home. There was no preceding history of similar symptoms, haematuria, loin pain or loin mass. There was no weight loss. Initial clinical evaluation was unremarkable. An Abdominopelvic Contrast Computerized Tomography Scan (CT scan) revealed an expansile lytic mass in the right iliac bone, eroding it and invading the contiguous iliacus and gluteal muscles (Figure 1 A). It also showed a large hypodense mass in the central portion of the right kidney, adjacent to the renal hilum with peri-hilar lymph node enlargement (Figure 1 B). The renal vein and inferior vena cava were however not involved. There were no other areas of metastasis. Based on the above findings, a diagnosis of Right RCC (Clinical Stage T3, N1, M1 (Stage 4) was made. He was subsequently scheduled for right radical nephrectomy via a right subcoastal transperitoneal approach. Intra-operatively, we found a solid right renal mass which had invaded the Gerota's fascia in some areas measuring 7 by 8 centimeters. It was resected en bloc with adjoining peri-hilar lymph nodes (Figure 2). Following recuperation, he had wide local excision of the right pelvic mass along with the diseased iliac bone and iliacus muscle through a right Ilio-inguinal approach. Both specimen had negative resection margins. Histopathologic evaluation of the resected kidney specimen revealed proliferation of malignant epithelial cells forming tubules which are cystically dilated. The renal stroma was desmoplastic and infiltrated by some of these malignant cells. Tumour was confined to the gerota's fascia. The findings were consistent with a tubulocystic variant of BDC. Evaluation of the iliac bone specimen was in keeping with a metastasis from BDC of the kidney. The patient made a smooth post-operative recovery and is being planned for commencement of immunotherapy with Sunitinib (Figure 1, Figure 2, Figure 3, Figure 4).

Discussion

BDC of the kidney also known as collecting duct carcinoma of the Kidney is a rare type of RCC accounting for less than 3% of all cases of RCC and has a tendency for early metastasis and high mortality [2, 3]. Due to these peculiarities, BDC was recognised as a separate entity by the 1998 World Health Organisation (WHO) classification [11]. In our previous report on experience with management of RCC in Ile-Ife, there were no cases of histologically confirmed BDC in over 50 cases owing to its rarity. It is not surprising that the index patient is a 40-year-old male as BDC is commoner in males with a Male: Female ratio of 2:1 and occurs mostly within the age range of 40-71 years [3, 12]. The tumour is also frequently seen in the second and third decades of life, hence in younger patients than conventional RCC [2]. Bloem et al found that majority of bone tumours in patients older than 40 years were malignant [13]. Metastasis, multiple myeloma, chondrosarcoma, Ewing's tumour, osteosarcoma and fibrosarcoma were some of the more common histologic tumours found in this age group [13]. The index patient presented with right sided pelvic pain and a limp following a trivial fall and had none of the clinical triad of loin pain, loin mass or haematuria. This buttresses the fact that the clinical presentation of this tumour can mimic many other clinical conditions, hence requires a high index of suspicion in order to make the diagnosis. The index case displays the importance of thoroughly investigating all suspected metastatic bone tumours in order to establish their primary origin. Harbin et al discussed the role of imaging (CT scan) in making diagnosis of BDC even though there are no pathognomic features [8]. BDC is a pathologic diagnosis [14]. As was seen in the index case, presence of lesions in the medullary region, predominant formation of tubules, desmoplastic stromal reaction, cytologic, high grade malignant cells, infiltrative growth pattern and absence of other typical RCC subtypes strongly suggest BDC [14]. Radical nephrectomy is the surgery of choice for BDC due to the usual central (hilar) location of the tumour and the high propensity of the tumour to invade the collecting system [8]. Several chemotherapeutic and immunotherapeutic regimens have been used for adjuvant treatment in BDC with varying degrees of response. Oudard et al found a 26% remission rate in BDC following use of Gemcitabine + Cisplatin/Carboplatin combination while Tokuda et al in Japan found interferon (IFN) and interleukin-2 (IL-2) to be ineffective [6, 15]. Targetted therapy with sorafenib, sunitinib or temsirolimus seems to be promising [16]. The prognosis of this condition has remained very poor with a 3-year survival as low as 6% for patients with metastatic disease [17]. In our practice, we offer partial or radical nephrectomy to all patients with resectable RCC who can withstand the metabolic response from surgery. Adjuvant immunotherapy with the aforementioned agents are indicated in patients with recurrent or residual disease.

Conclusion

The presentation of the index patient with an iliac bone mass highlights the bizarre ways in which RCC may present in our clinical practice. BDC is a rare but aggressive subtype of RCC with a poor prognosis. A high index of suspicion with appropriate imaging, early surgery and histopathological investigations are key in early diagnosis and improving outcome.

Competing interests

The authors declare no conflict of interest.

Authors' contributions

Salako, Badmus and Igbokwe were involved in the Radical Nephrectomy and initial write-up of this paper. Ikem, Orimolade and Onuoha performed the bone tumour excision and provided the radiologic photographs and intra-operative pictures. Adelusola and Irabor analysed both the renal and bone specimens. They also provided the micrographs for this paper.

Figures

Figure 1: CT scan showing both (A) right renal and (B) pelvic tumours

Figure 2: Right kidney with solid mass in the hilar region

Figure 3: Micrograph showing (A) dilated bellini ducts in the renal medulla

Figure 4: High power micrograph showing (A) hobnail appearance (B) malignant atypical renal epithelial cells

References

1. Namita Chittoria, Brian I, Rini. Renal Cell Carcinoma: cleveland clinic; 1950 Richmond Road, TR204, Lyndhurst, OH 44124. Cleveland Clinic Foundation. 2013. **Google Scholar**
2. Bozo Kru Lin, Ivana Glumbic, Ante Reljic, Hrvoje Cupic, Boris Ruzic, Goran Stimac et al. Collecting duct carcinoma of the kidney: report of three cases. *Acta Clinica Croat.* 2000; 40: 21-5. **Google Scholar**
3. Yu Hu, Honglan Zhou, Gang Wang, Zhiming Song, Chengwu Zhao, Yuantao Wang. Collecting duct carcinoma of the kidney: a case report. *Oncology Letters.* 2015; 9(6): 2902-4. **PubMed | Google Scholar**
4. Tijani KH, Anunobi CC, Ezenwa EV, Lawal A, Habeebu MYM, Jeje EA et al. Adult renal cell carcinoma in Lagos: experience and challenges at the Lagos University Teaching Hospital. *African Journal of Urology.* 2012; 18(1): 20-3. **Google Scholar**
5. A.A. Salako, T.A. Badmus, K.B. Badmos, R.A. David, A. Laoye, I.A. Akinbola, et al. Renal cell carcinoma in a semi-urban population of south-western Nigeria. *East African Medical Journal.* 2017;94(1):37-43. **PubMed | Google Scholar**
6. Oudard S, Banu E, Vieillefond A, Fournier L, Priou F, Medioni J. Prospective multicenter phase II study of gemcitabine plus platinum salt for metastatic collecting duct carcinoma: results of a GETUG [Groupe d'Etudes des Tumeurs Uro-Genitales] study. *J Urol.* 2007; 177(5): 1698-702. **PubMed | Google Scholar**
7. Dason S, Allard C, Sheridan-Jonah A, Gill J, Jamshaid H, Aziz T et al. Management of renal collecting duct carcinoma: a systematic review and the McMaster experience. *Current Oncology.* 2013; 20(3): e223-32. **PubMed | Google Scholar**
8. Andrew C Harbin, Brett A Styskel, Viren Patel, He Wang, Daniel Eun D. Collecting duct renal cell carcinoma found to involve the collecting system during partial nephrectomy: a case. report *Journal of Kidney Cancer and VHL.* 2015; 2(3): 134-9. **PubMed | Google Scholar**
9. Hisao Nakamura, Yasuyuki Kuirhara, Kazuhiko Matsushita, Akehide Sakai, Toshio Yamaguchi, Yasuo Nakajima. Extrarenal multiorgan metastases of collecting duct carcinoma of the kidney: a case series. *Journal of Medical Case Reports.* 2008; 2: 304. **Google Scholar**
10. Shunsuke Ohnishi, Masayoshi Dazai, Yoshinori Iwasaki, Kazufumi Tsuzaka, Tatsuro Takahashi, Takuto Miyagishima. Undiagnosed Collecting Duct Carcinoma Presenting as Meningeal Carcinomatosis and Multiple Bone Metastases. *Japanese Society of Internal Medicine.* 2010; 49(15): 1541-4. **PubMed | Google Scholar**
11. Mostofi FK, Davis CJ, Sobin LH. Histologic typing of kidney tumours: International histologic classification of tumours. Geneva: World Health Organization. 1981; 25. **Google Scholar**
12. Matz LR, Latham BI, Fabian VA, Vivian JB. Collecting duct carcinoma of the kidney: a report of three cases and review of the literature. *Pathology.* 1997; 29(4): 354-9. **PubMed | Google Scholar**
13. Johan L, Bloem, Inge I, Reidsma. Bone and soft tissue tumors of hip and pelvis. *European Journal of Radiology.* 2012; 81(12): 3793-801. **PubMed | Google Scholar**
14. Srigley JR. The International society of urological pathology [ISUP] vancouver classification of Renal Neoplasia. *Am J Surg Pathol.* 2013; 37(10): 1469-89. **PubMed | Google Scholar**
15. Tokuda N, Naito S, Matsuzaki O, Nagashima Y, Ozono S, Igarashi T. Japanese Society of Renal Cancer, collecting duct [Bellini duct] renal cell carcinoma: a nationwide survey in Japan. *J Urol.* 2006; 176(1): 40-3. **PubMed | Google Scholar**
16. Procopio G, Verzoni E, Iacovelli R, Colecchia M, Torelli T, Mariani L. Is there a role for targeted therapies in the collecting ducts of Bellini carcinoma: efficacy data from a retrospective analysis of 7 cases. *Clin Exp Nephrol.* 2012; 16(3): 464-7. **PubMed | Google Scholar**
17. Peppek J, Johnstone P, Jani A. Influence of demographic factors on outcome of collecting duct carcinoma: a surveillance, epidemiology and End Results [SEER] database analysis. *Clin Genitourin Cancer.* 2009; 7(2): E24-7. **PubMed | Google Scholar**

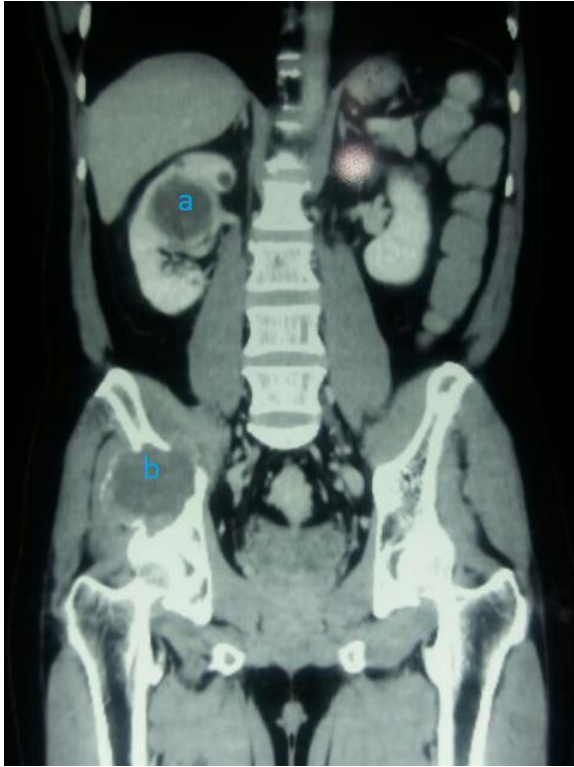

Figure 1: CT scan showing both (A) right renal and (B) pelvic tumours

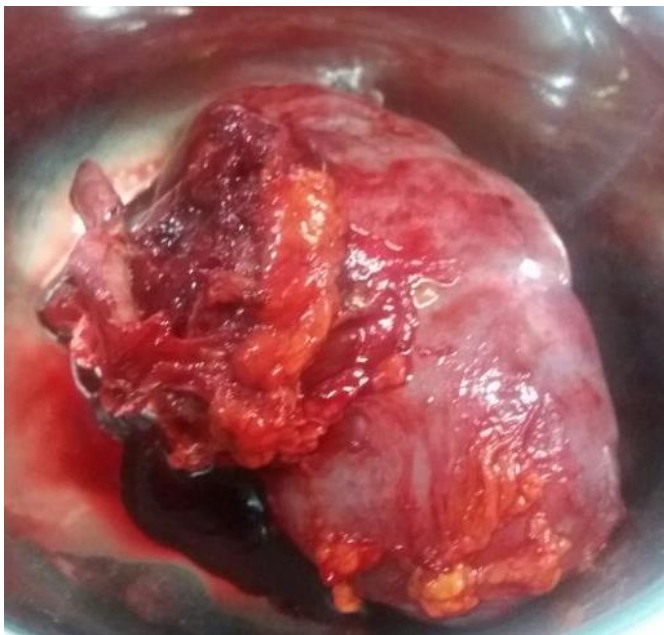

Figure 2: Right kidney with solid mass in the hilar region

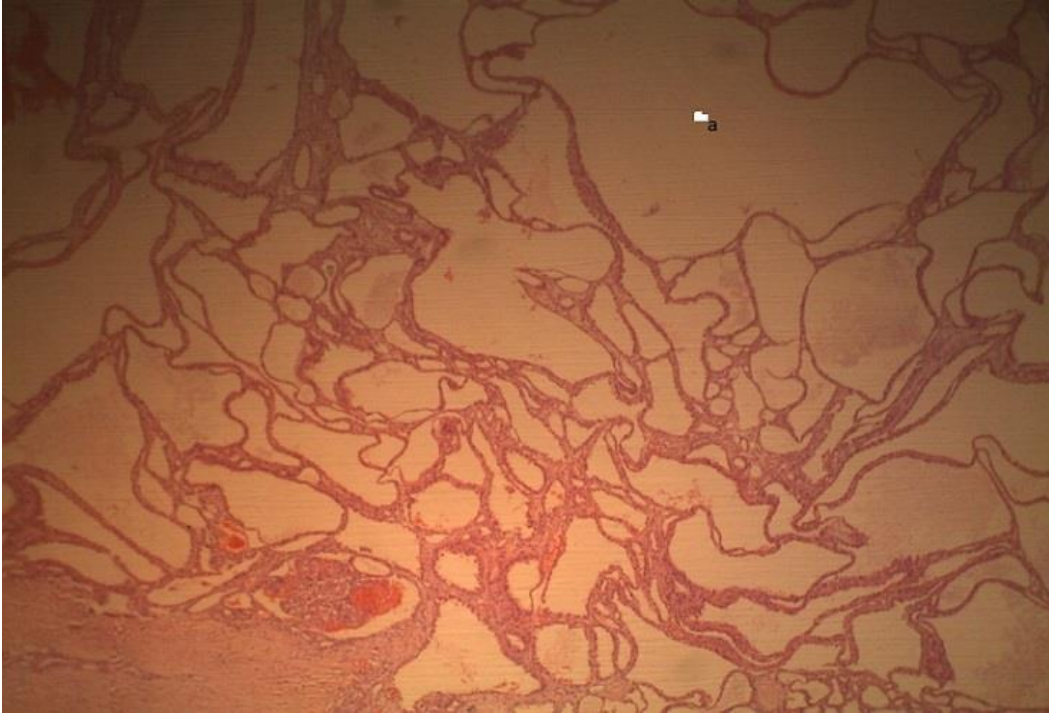


Figure 3: Micrograph showing (A) dilated bellini ducts in the renal medulla

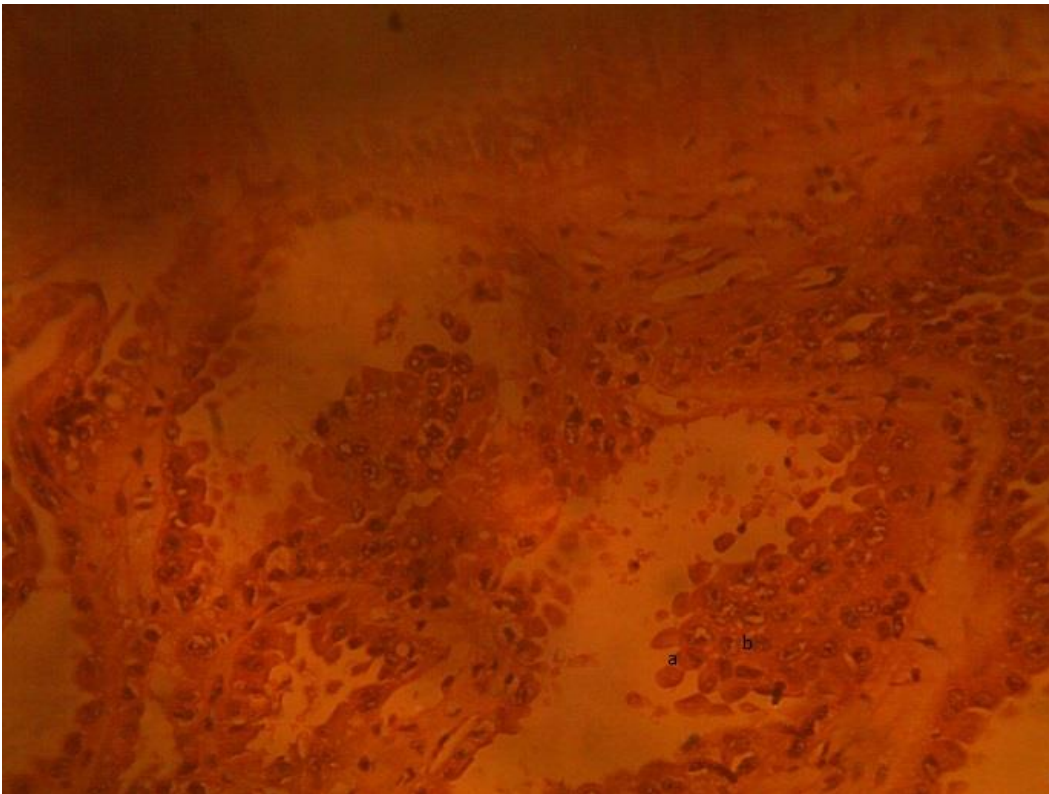


Figure 4: High power micrograph showing (A) hobnail appearance (B) malignant atypical renal epithelial cells