



Original article

Prediction of flexor tendon graft diameter in reconstruction of the anterior cruciate ligament by means of magnetic resonance imaging[☆]



Fabiano Kupczik^a, Luiz Otávio Bombonato Tauscheck^{a,*},
Marlus Eduardo Gunia Schiavon^a, Bruno Sbrissia^a, Lucio Sergio Rocha Ernlund^b,
Ricardo Augusto Lass Alves^a

^a Pontifícia Universidade Católica do Paraná (PUC-PR), Hospital Universitário Cajuru, Curitiba, PR, Brazil

^b Instituto de Joelho e Ombro, Curitiba, PR, Brazil

ARTICLE INFO

Article history:

Received 15 July 2015

Accepted 8 September 2015

Available online 6 June 2016

Keywords:

Anterior cruciate ligament

Anterior cruciate ligament reconstruction

Magnetic resonance spectroscopy

Orthopedic procedures

ABSTRACT

Objective: To evaluate the diameter of the flexor tendons in preoperative magnetic resonance imaging (MRI) examinations and compare this with the diameter of the graft obtained intraoperatively.

Methods: This was a retrospective longitudinal epidemiological study. Forty-four patients were eligible for the study and their MRI examinations and surgical data were evaluated. The tendons were measured on MRI across their largest diameter in the axial plane, using the medial epicondyle of the femur as the slice level. In the surgery, routine graft preparation was performed, consisting of folding the gracilis and semitendinosus tendons to form a four-strand graft. Its measurement was recorded.

Results: To evaluate the association between the variables, Pearson's correlation coefficient was estimated. A significant correlation was found between the measurements of the gracilis and semitendinosus tendons and the final diameter of the graft ($p < 0.001$). A ROC curve was fitted to the sum of the tendon diameters in order to determine a cutoff point associated with the graft diameter (≤ 8 mm or > 8 mm). If the sum was greater than 5.28 mm, the chance of obtaining a graft larger than 8 mm would be 75%.

Conclusion: Measurement of the diameters of the gracilis and semitendinosus tendons through a preoperative MRI examination is a simple and effective way to predict the final size of the graft to be used in ACL reconstruction surgery.

© 2016 Sociedade Brasileira de Ortopedia e Traumatologia. Published by Elsevier Editora Ltda. This is an open access article under the CC BY-NC-ND license (<http://creativecommons.org/licenses/by-nc-nd/4.0/>).

[☆] Study conducted at Hospital Universitário Cajuru, Pontifícia Universidade Católica do Paraná (PUC-PR), Curitiba, PR, Brazil.

* Corresponding author.

E-mail: luizotaviobt@hotmail.com (L.O.B. Tauscheck).

<http://dx.doi.org/10.1016/j.rboe.2016.06.002>

2255-4971/© 2016 Sociedade Brasileira de Ortopedia e Traumatologia. Published by Elsevier Editora Ltda. This is an open access article under the CC BY-NC-ND license (<http://creativecommons.org/licenses/by-nc-nd/4.0/>).

Predição do diâmetro do enxerto dos tendões flexores na reconstrução do ligamento cruzado anterior por meio da ressonância nuclear magnética

R E S U M O

Palavras-chave:

Ligamento cruzado anterior
Reconstrução do ligamento cruzado anterior
Espectroscopia de ressonância magnética
Procedimentos ortopédicos

Objetivo: Avaliar o diâmetro dos tendões flexores em exames de ressonância magnética (RNM) pré-operatória e comparar com o diâmetro do enxerto obtido no ato intraoperatório.
Métodos: Em um estudo epidemiológico longitudinal retrospectivo, 44 pacientes foram elegíveis ao estudo e tiveram os exames de RNM e dados de cirurgias avaliados. Os tendões foram medidos na RNM no seu maior diâmetro no plano axial com o uso do epicôndilo medial do fêmur como nível de corte. Na cirurgia foi feito preparo de rotina do enxerto, dobraram-se os tendões grácil e semitendinoso, formou-se um enxerto quádruplo que teve sua medida registrada.

Resultados: Para a avaliação da associação entre as variáveis foi estimado o coeficiente de correlação de Pearson. Foi encontrada correlação significativa entre as medidas dos tendões grácil e semitendinoso e o diâmetro final do enxerto ($p < 0,001$). Ajustou-se uma curva ROC para a soma do diâmetro dos tendões, para a determinação de um ponto de corte associado ao diâmetro do enxerto (≤ 8 mm ou > 8 mm). Caso a soma seja maior do que 5,28 mm, a chance de obter um enxerto maior do que 8 mm é de 75%.

Conclusão: A medida do diâmetro dos tendões grácil e semitendinoso no exame da RNM pré-operatória é uma maneira simples e eficaz na predição do tamanho final do enxerto a ser usado na cirurgia de reconstrução do LCA.

© 2016 Sociedade Brasileira de Ortopedia e Traumatologia. Publicado por Elsevier Editora Ltda. Este é um artigo Open Access sob uma licença CC BY-NC-ND (<http://creativecommons.org/licenses/by-nc-nd/4.0/>).

Introduction

Rupture of the anterior cruciate ligament (ACL) is the most common knee ligamentous injury, affecting over 100,000 people annually in the United States. Its incidence has been increasing due to a greater stimulus to and practice of sports by the population.^{1,2}

The ACL originates in the posterior portion of the lateral femoral condyle and inserts laterally and anteriorly to the medial tibial spine. It features an intra-articular and extrasynovial course, with a mean length of 38 mm and a mean diameter of 11 mm.³⁻⁵

Currently, it is known that the ACL is composed of two sets of fibers or bands: one anteromedial (AM) and another posterolateral (PL). At the femoral origin, the AM band emerges more proximally and posteriorly, while the PL band emerges more distally and anteriorly. The bands are twisted along their path in the intercondyle zone, and the tibial insertion follows the order which gives them their name: anteromedial for the AM and posterolateral for the PL.⁵⁻⁸

Surgical treatment based on ligament reconstruction is recommended for most ACL injuries. Currently, there are several options for grafts to replace it; the flexor tendons (semitendinosus and gracilis), patellar tendon, and quadriceps tendon are most used.^{2,9} Choice should consider profile and patients' age, type of sport, associated lesions, and surgeons' experience. The ideal graft has not been defined yet; some studies show that grafts with diameters less than 7 mm are associated with a higher chance of failure and relapse.¹⁰⁻¹³

Along with the advancement of imaging, preoperative measurement of the diameter of the tendons on magnetic

resonance imaging (MRI) is possible, which is the gold standard imaging study for the diagnosis of this injury, allowing an objective parameter for the graft to be chosen in ACL reconstruction prior to surgery.^{1,2,14-20}

This study aimed to evaluate the diameter of the flexor tendons on preoperative MRI and compare with the diameter of the graft obtained intraoperatively.

Material and methods

After approval by the Research Ethics Committee through the Platform Brazil website, under the Certificate of Presentation for Ethical Assessment (Certificado de Apresentação para Apreciação Ética [CAAE]) No. 39346814.4.0000.0020, 100 MRI scans and data from surgeries performed between 2012 and 2014 were collected and reviewed for this retrospective, longitudinal, epidemiological study.

Inclusion criteria comprised skeletally mature patients with complete ACL injury and no history of previous ligament or degenerative injuries. Exclusion criteria were: previous surgery, ligamentous laxity, chronic use of steroids, and dysplasia of the intercondylar notch (width of the distal femur/condylar fossa < 0.2).

After subject selection according to inclusion and exclusion criteria, 44 patients were eligible for the study.

Variables of this study were measured on MRI studies by a single radiologist using the following equipment: Achieva 1.5 T (Philips Healthcare, Best, The Netherlands) and HDx 1.5 T (GE Medical Systems, Milwaukee, USA). All studies were made using the proton density technique with fat suppression. On MRI, the semitendinosus and gracilis tendons were measured

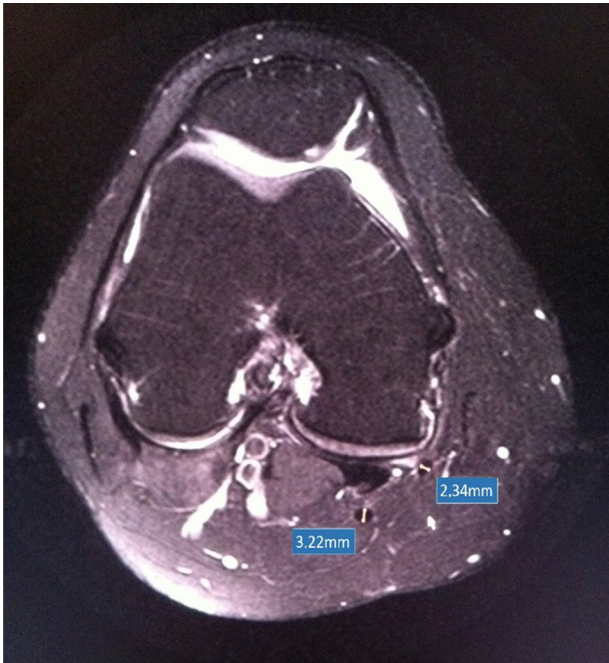


Fig. 1 – Measurement of diameter of the semitendinosus and gracilis tendons.

at their largest diameter in the axial plane, considering the medial epicondyle of the femur as the cutoff level (Fig. 1).

During surgery, tendons were removed by standard fashion technique through a closed tenotomy. Graft was prepared as usual: the gracilis and semitendinosus tendons were folded, forming a quadruple graft. The prepared graft had its diameter measured before drilling the bone tunnels in the tibia and femur. These data were recorded at the surgical report of the patients.

Statistical analysis

To evaluate the association between variables, Pearson's correlation coefficient was estimated. The assessment of the use of the gracilis and semitendinosus variables as predictors of graft diameter was made through simple and multiple linear regression models; to assess the association of the sum of the gracilis and semitendinosus with the probability that the graft diameter was greater than 8 mm, a logistic regression model was adjusted. Wald's test was used to assess the significance of the coefficients.

Regarding the sum of the gracilis and semitendinosus for determining a cutoff point associated with graft diameter (≤ 8 mm or >8 mm), a ROC curve was adjusted. p -values < 0.05 were considered to be statistically significant.

Data were analyzed with IBM SPSS v.20.0.

Results

Of the 44 patients studied, 33 were male (75%) and 11 female (25%). Age ranged from 11 to 54 years, with a mean of 31.8 years.

Table 1 – Graft diameter.

Graft diameter	n	%
6	1	2.3
7	3	6.8
8	24	54.5
9	14	31.8
10	2	4.5
Total	44	100

Mean diameter of the gracilis tendon on MRI was 2.17 mm, ranging from 1.45 to 2.76 mm, while mean diameter of the semitendinosus was 2.96, ranging from 2.52 to 3.73 mm.

During surgery, mean size of grafts used for ACL reconstruction was 8.3 mm, ranging from 6 to 10 mm (Table 1).

Fig. 2 shows the scatter plot graph of the semitendinosus and gracilis variables, highlighting the difference of coordinates according to the diameter of the graft.

Data correlation

Gracilis \times graft diameter

Pearson's correlation coefficient was estimated to be 0.59, and the test result was statistically significant ($p < 0.001$). Thus, there was a significant correlation between the gracilis and graft diameter. Fig. 3 presents the scatter plot of both variables. Each point corresponds to one case.

Semitendinosus \times graft diameter

Pearson's correlation coefficient was estimated to be 0.59, and the test result was statistically significant ($p < 0.001$). Thus, there was a significant correlation between the semitendinosus and graft diameter. Fig. 4 presents the scatter plot of both variables. Each point corresponds to one case.

Sum of gracilis + semitendinosus \times graft diameter

Pearson's correlation coefficient was estimated to be 0.74, and the test result was statistically significant ($p < 0.001$). Thus, there was a significant correlation between the sum of gracilis + semitendinosus and graft diameter. Fig. 5 presents the scatter plot of both variables. Each point corresponds to one case.

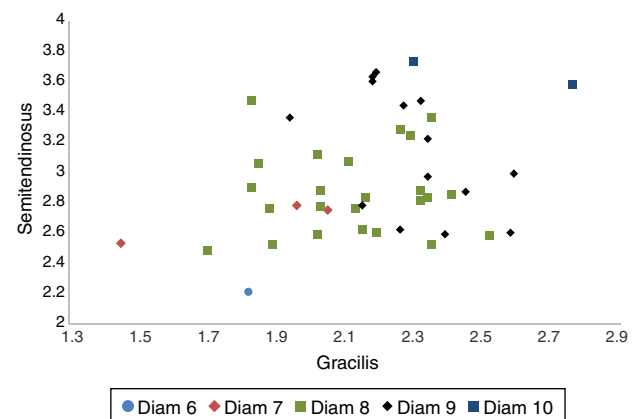


Fig. 2 – Scatter plot of the gracilis and semitendinosus variables.

Table 2 – Gracilis + semitendinosus as a predictor of graft diameter.

Diameter estimated by the model	Diameter observed in the sample									
	6		7		8		9		10	
	n	%	n	%	n	%	n	%	n	%
6	0	0%	0	0%	0	0%	0	0%	0	0%
7	1	100%	1	33.3%	2	8.3%	0	0%	0	0%
8	0	0%	2	66.7%	19	79.2%	6	42.9%	0	0%
9	0	0%	0	0%	3	12.5%	8	57.1%	1	50%
10	0	0%	0	0%	0	0%	0	0%	1	50%
Total	1	100%	3	100%	24	100%	14	100%	2	100%

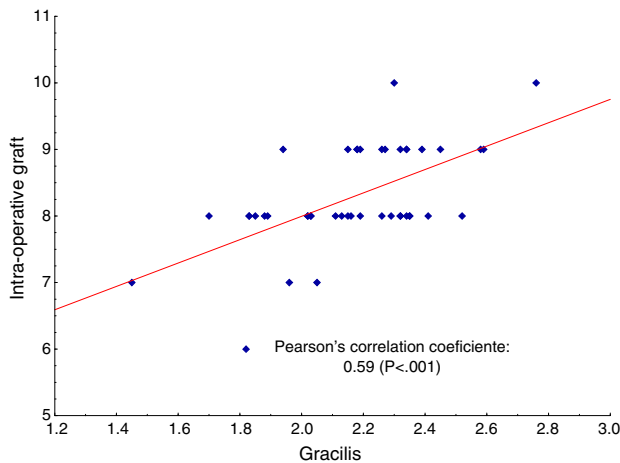


Fig. 3 – Gracilis x graft diameter.

Pearson's correlation coefficient for both tendons showed a moderate positive correlation power, which indicates a tendency that the larger the diameter of the patients' tendon, the greater the final diameter of the graft obtained for ACL reconstruction.

Assessment of the quality of the sum of gracilis + semitendinosus as a predictor of graft diameter

To evaluate the sum of gracilis + semitendinosus as a predictor of graft diameter, a simple linear regression model was

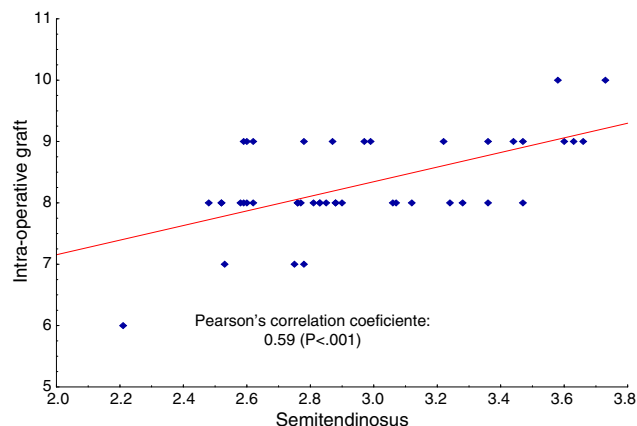


Fig. 4 – Semitendinosus x graft diameter.

adjusted, and the sum was considered as an explanatory variable (independent) and the diameter of the graft as the response variable (dependent). The adjusted model was:

$$\text{Estimated diameter} = 2.618 + 1.107 (\text{gracilis} + \text{semitendinosus}).$$

The estimated diameter for each single value of the sum of gracilis + semitendinosus should be rounded to the nearest integer. For example, for a particular case whose sum of gracilis + semitendinosus is equal to 6.51, the estimated value of the diameter will be:

$$\text{Estimated diameter} = 2.618 + 1.107 \times 6.51 = 9.82.$$

The result diameter to be considered is equal to 10.

Based on the study sample, Table 2 presents the scores obtained with the model for each particular graft diameter.

As a result of interest, the determination coefficient was 55%. Thus, it was estimated that 55% of the diameter variations were explained by the gracilis + semitendinosus.

Assessment of the quality of the sum of gracilis + semitendinosus as a predictor of graft diameter ≤8 mm or >8 mm

The analysis presented below aimed to evaluate whether the sum of gracilis + semitendinosus would discriminate well between graft diameter ≤8 mm or >8 mm.

A logistic regression model was adjusted, considering the sum of gracilis + semitendinosus as the explanatory variable

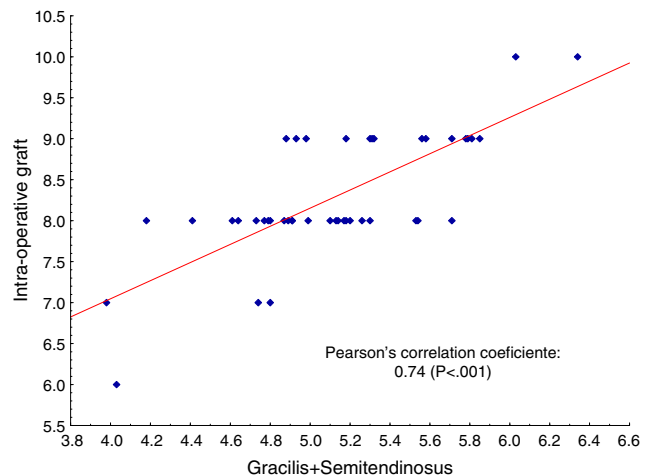


Fig. 5 – Sum of gracilis + semitendinosus x diameter of the graft.

Table 3 – Probability of graft diameter.

Gracilis + semitendinosus	Probability of graft diameter greater than 8 mm
3.5	0.001
4	0.005
4.5	0.035
5	0.201
5.5	0.632
6	0.922
6.5	0.988
7	0.998

and the diameter of the graft (≤ 8 mm or > 8 mm) as the dependent variable. The null hypothesis that there is no association between the sum gracilis + semitendinosus and the probability that the graft diameter is > 8 mm was tested against the alternative hypothesis that there is such an association. The test result indicated the rejection of the null hypothesis ($p = 0.001$) and indicated that the sum of gracilis + semitendinosus significantly influences the probability that the graft diameter is > 8 mm.

Table 3 and Fig. 6 present the values of the sum of gracilis + semitendinosus and the respective probability that the graft diameter is > 8 mm, estimated by the adjusted model.

Determination of a cutoff point for the sum of gracilis + semitendinosus that is associated with graft diameter ≤ 8 mm or > 8 mm (ROC curve)

A ROC curve was adjusted for the sum of gracilis + semitendinosus and considered the diameter of the graft (≤ 8 mm or > 8 mm). The area under the curve was 0.87, with statistical significance ($p < 0.001$). This indicates that the curve fit is good and the sum of gracilis + semitendinosus discriminates well between diameter ≤ 8 mm or > 8 mm.

The optimal cutoff point for the sum of gracilis + semitendinosus was equal to 5.28, with sensitivity of 75% and specificity of 85.7%. Table 4 presents these results.

Sensitivity: probability that the sum of gracilis + semitendinosus is > 5.28 if the graft diameter is > 8 mm.

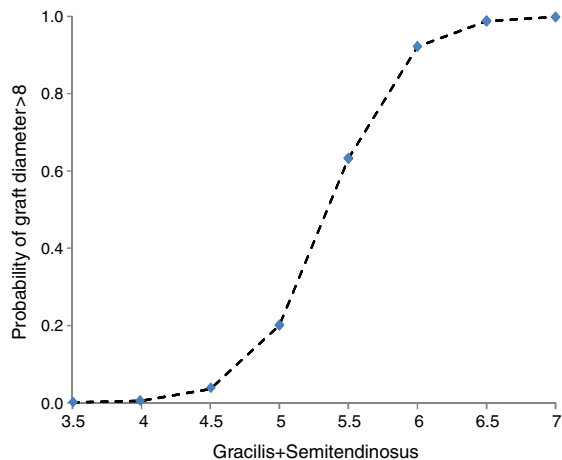


Fig. 6 – Probability of graft diameter.

Table 4 – Sensitivity and specificity according to the cutoff point.

Gracilis + semitendinosus	Graft diameter (mm)	
	≤ 8	> 8
≤ 5.28	24 85.7% (specif)	4 25%
> 5.28	4 14.3%	12 75% (sensit)
Total	28	16

Specificity: probability that the sum of gracilis + semitendinosus is ≤ 5.28 if the graft diameter is ≤ 8 mm.

Fig. 7 shows the adjusted ROC curve.

Fig. 8 presents the sensitivity and specificity values for various values of the sum of gracilis + semitendinosus.

Discussion

In this study, a significant correlation was observed between the measurements of the diameter of the tendons on MRI and the size obtained in surgery.

No studies were retrieved in the literature in which measurements were made in a similar way, i.e., measuring the tendons of the semitendinosus and gracilis at their largest diameter in the axial plane with the cutoff level at the medial femoral epicondyle.

Beyzadeoglu et al.¹ observed statistical significance in the measurement of the cross-sectional area of the flexor tendons measured at two levels on MRI and graft size obtained intra-operatively in 51 patients. The diameters were also measured at these two levels. However, no significant correlation was observed.

In a similar study, Bickel et al.¹⁹ observed a significant correlation between the sum of the semitendinosus and gracilis areas measured on MRI with values above 18 mm^2 and the achievement of a suitable-sized graft in 88% of cases.

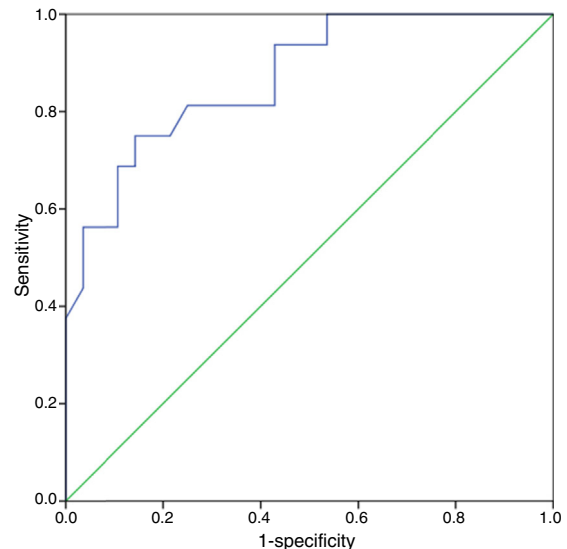


Fig. 7 – ROC curve.

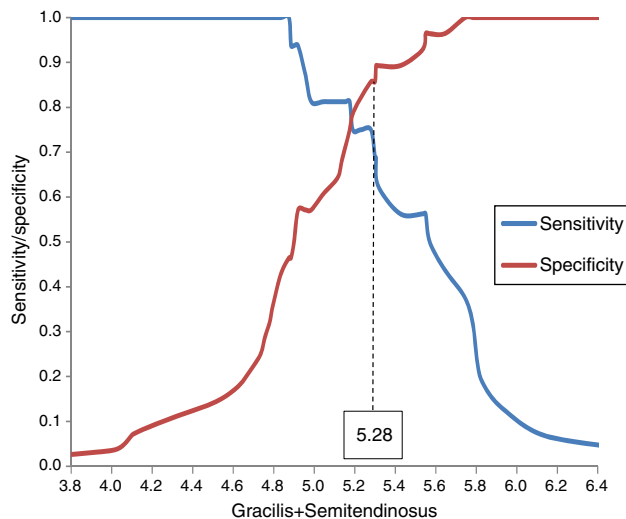


Fig. 8 – Sensitivity and specificity for various values of the sum of gracilis + semitendinosus.

In another study, Wernecke et al.¹⁶ examined the area of the tendons of 34 patients on MRI and recommended a 10 mm²-area for the gracilis tendon and a 17 mm²-area for the semitendinosus tendon to obtain a suitable sized graft, considering a quadruple graft.

Hamada et al.¹⁸ measured the semitendinosus area at MRI in 79 patients and demonstrated that, when the area is larger than 11 mm², a graft greater than or equal to 7 mm is achieved during surgery in 89% of cases.

Differently, Yasumoto et al.²⁰ showed that prediction of the graft size is possible by examining three-dimensional computed tomography in 28 patients.

Other studies have attempted to predict the chance of failure in ACL reconstruction using data such as gender, age, weight, height, and bone mass index (BMI). These studies, in general, have shown that eutrophic (>50 kg) and short (>140-147 cm) women are more likely to have grafts smaller than 7 mm.^{9,13,15}

Magnussen et al.¹⁰ analyzed graft size and age of patients as predictors of early revision ACL reconstruction. Authors demonstrated that the use of grafts smaller than or equal to 8 mm and patients younger than 20 years are associated with higher rates of revision surgery.

In the present study, we demonstrated that prediction of the graft size that will be obtained for ACL reconstruction is possible by measuring the diameter in the axial plane with the cutoff level at the medial femoral condyle.

Through measurements and the proposed algorithm, an estimated diameter of $2.618 + 1.107$ (gracilis + semitendinosus) can indicate the approximate graft size.

Another method to assess whether the graft will have an appropriate size is summing the diameters of the tendons. If sum of gracilis + semitendinosus is greater than 5.28 mm, the probability of obtaining a graft greater than 8 mm is 75%.

Probably, with a greater number of cases, especially those with grafts smaller than or equal to 7, results will be even more accurate to predict graft diameter.

Conclusion

This study demonstrated that measuring the diameter of the gracilis and semitendinosus tendons on preoperative MRI is a simple and effective method to predict the final size of the graft to be used in ACL reconstruction surgery.

Conflicts of interest

The authors declare no conflicts of interest.

REFERENCES

1. Beyzadeoglu T, Akgun U, Tasdelen N, Karahan M. Prediction of semitendinosus and gracilis autograft sizes for ACL reconstruction. *Knee Surg Sports Traumatol Arthrosc.* 2012;20(7):1293-7.
2. Kupczik F, Schiavon MEG, Sbrissia B, Fávoro RC, Valério R. Enxerto ideal para ligamento cruzado anterior: correlação em ressonância magnética entre LCA, isquiotibiais, tendão patelar e tendão quadríceps. *Rev Bras Ortop.* 2013;48(5):441-7.
3. Kweon C, Lederman ES, Chhabra A. Anatomy and biomechanics of the cruciate ligaments and their surgical implications. In: Fanelli GC, editor. *The multiple ligament injured knee.* New York: Springer-Verlag; 2013. p. 17-27.
4. Staebli HU, Adam O, Becker W, Burgkart R. Anterior cruciate ligament and intercondylar notch in the coronal oblique plane: anatomy complemented by magnetic resonance imaging in cruciate ligament-intact knees. *Arthroscopy.* 1999;15(4):349-59.
5. Duthon VB, Barea C, Abrassart S, Fasel JH, Fritschy D, Ménétrey J. Anatomy of the anterior cruciate ligament. *Knee Surg Sports Traumatol Arthrosc.* 2006;14(3):204-13.
6. Tsukada H, Ishibashi Y, Tsuda E, Fukuda A, Toh S. Anatomical analysis of the anterior cruciate ligament femoral and tibial footprints. *J Orthop Sci.* 2008;13(2):122-9.
7. Araujo P, van Eck CF, Torabi M, Fu FH. How to optimize the use of MRI in anatomic ACL reconstruction. *Knee Surg Sports Traumatol Arthrosc.* 2013;21(7):1495-501.
8. Girgis FG, Marshall JL, Monajem A. The cruciate ligaments of the knee joint. Anatomical, functional and experimental analysis. *Clin Orthop Relat Res.* 1975;106:216-31.
9. Treme G, Diduch DR, Billante MJ, Miller MD, Hart JM. Hamstring graft size prediction: a prospective clinical evaluation. *Am J Sports Med.* 2008;36(11):2204-9.
10. Magnussen RA, Lawrence JT, West RL, Toth AP, Taylor DC, Garrett WE. Graft size and patient age are predictors of early revision after anterior cruciate ligament reconstruction with hamstring autograft. *Arthroscopy.* 2012;28(4):526-31.
11. Dwyer T, Whelan DB, Khoshbin A, Wasserstein D, Dold A, Chahal J, et al. The sizing of hamstring grafts for anterior cruciate reconstruction: intra- and inter-observer reliability. *Knee Surg Sports Traumatol Arthrosc.* 2015;23(4):1197-200.
12. Conte EJ, Hyatt AE, Gatt CJ Jr, Dhawan A. Hamstring autograft size can be predicted and is a potential risk factor for anterior cruciate ligament reconstruction failure. *Arthroscopy.* 2014;30(7):882-90.
13. Tuman JM, Diduch DR, Rubino LJ, Baumfeld JA, Nguyen HS, Hart JM. Predictors for hamstring graft diameter in anterior cruciate ligament reconstruction. *Am J Sports Med.* 2007;35(11):1945-9.
14. Fleming BC, Vajapeyam S, Connolly SA, Magarian EM, Murray MM. The use of magnetic resonance imaging to predict ACL graft structural properties. *J Biomech.* 2011;44(16):2843-6.

15. Ma CB, Keifa E, Dunn W, Fu FH, Harner CD. Can pre-operative measures predict quadruple hamstring graft diameter? *Knee*. 2010;17(1):81-3.
16. Wernecke G, Harris IA, Houang MT, Seeto BG, Chen DB, MacDessi SJ. Using magnetic resonance imaging to predict adequate graft diameters for autologous hamstring double-bundle anterior cruciate ligament reconstruction. *Arthroscopy*. 2011;27(8):1055-9.
17. Nakayama Y, Shirai Y, Narita T, Mori A, Kobayashi K. The accuracy of MRI in assessing graft integrity after anterior cruciate ligament reconstruction. *J Nippon Med Sch*. 2001;68(1):45-9.
18. Hamada M, Shino K, Mitsuoka T, Abe N, Horibe S. Cross-sectional area measurement of the semitendinosus tendon for anterior cruciate ligament reconstruction. *Arthroscopy*. 1998;14(7):696-701.
19. Bickel BA, Fowler TT, Mowbray JG, Adler B, Klingele K, Phillips G. Preoperative magnetic resonance imaging cross-sectional area for the measurement of hamstring autograft diameter for reconstruction of the adolescent anterior cruciate ligament. *Arthroscopy*. 2008;24(12):1336-41.
20. Yasumoto M, Deie M, Sunagawa T, Adachi N, Kobayashi K, Ochi M. Predictive value of preoperative 3-dimensional computer tomography measurement of semitendinosus tendon harvested for anterior cruciate ligament reconstruction. *Arthroscopy*. 2006;22(3):259-64.