


CASE REPORT

Sterile pyogranuloma syndrome in a dog successfully treated with immunosuppressive therapy and reconstructive seed grafting

Hilary H. Chan¹  | Amanda K. Burrows¹ | Giselle Hosgood² | Rudayna Ghubash³ | Amanda O'Hara⁴

¹Animal Dermatology Clinic Perth, The Animal Hospital Murdoch University, Murdoch, WA, Australia

²College of Veterinary Medicine, The Animal Hospital Murdoch University, Murdoch, WA, Australia

³Animal Dermatology Clinic, Marina del Rey, CA, USA

⁴Idexx Laboratories Pty Ltd, Rydalmere, NSW, Australia

Correspondence

Hilary Chan, Animal Dermatology Clinic Perth, The Animal Hospital Murdoch University, 90 South Street, Murdoch, Western Australia, 6150, Australia.
Email: hilary.chan@murdoch.edu.au

Funding information

This study was self-funded.

Abstract

This report describes a case of sterile pyogranuloma syndrome managed with immunomodulatory therapy and seed skin grafting. Seed skin grafting can be considered as part of a multimodal treatment approach for cutaneous defects caused by ulcerative immune-mediated diseases where secondary intention healing is delayed or contraindicated, and other forms of wound reconstruction may be prohibitive.

INTRODUCTION

Sterile pyogranuloma syndrome (SPS) is an uncommon immune-mediated skin disease of dogs characterised by plaques, ulcers and draining nodules.¹ Lesions may be solitary or generalised and located on the pinnae, muzzle, periocular regions and distal limbs. Affected dogs may demonstrate systemic signs of lethargy and inappetence. Diagnosis is confirmed by histopathological examination and the exclusion of infectious aetiologies including fungal, bacterial and oomycotic agents.¹ Medical management with prednisolone, azathioprine,² ciclosporin³ and low-level laser therapy⁴ are effective. This report describes the use of seed grafting to enhance epithelialisation of full-thickness skin defects on the distal limbs of a dog that was receiving immunomodulatory medical therapy for SPS.

CASE REPORT

A 3.5-year-old male, castrated shih tzu weighing 4.6 kg presented to a veterinary dermatology referral clinic

with a one month history of severe, progressive, nodular to ulcerative dermatitis. The dog was inappetent, lethargic and dysphagic.

Physical examination revealed a deep, well-demarcated ulcer located on the caudolateral carpal region of the right forelimb (Figure 1a) measuring 40 mm × 32 mm encircling two-thirds of the circumference of the carpus; an erosive lesion with a central tract draining serous discharge affecting the caudomedial tarsal region of the left hind limb measuring 20 mm in diameter, and a focal crusted, ulcerated nodule draining a serous discharge on the dorsal aspect of the head measuring 10 mm × 3 mm. Bilateral submandibular lymphadenomegaly, unilateral enlargement of the left mandibular salivary gland, marked bilateral episcleral injection, ocular discharge and corneal neovascularisation were present. Multiple skin biopsy samples were collected from the right forelimb and left hind limb lesions. Aerobic and anaerobic bacterial and fungal cultures and PCR testing for mycobacterial organisms were negative. Histopathological examination demonstrated a multifocal to coalescing population of neutrophils, histiocytes, eosinophils, lymphocytes, plasma cells and mast cells

This is an open access article under the terms of the [Creative Commons Attribution-NonCommercial](https://creativecommons.org/licenses/by-nc/4.0/) License, which permits use, distribution and reproduction in any medium, provided the original work is properly cited and is not used for commercial purposes.
© 2022 The Authors. *Veterinary Dermatology* published by John Wiley & Sons Ltd on behalf of ESVD and ACVD.

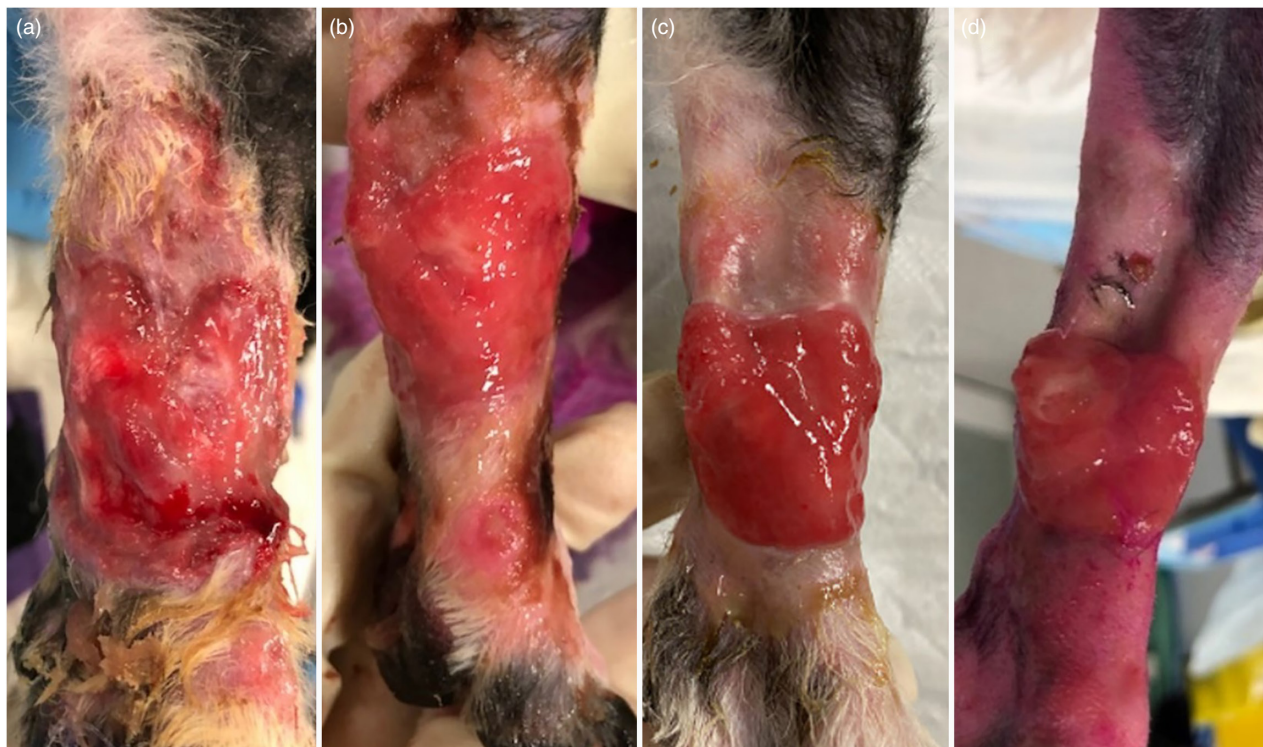

FIGURE 1 Photographic series of the right caudolateral carpus in a dog with sterile pyogranuloma syndrome before seed grafting. (a) Ulcerative wound at initial presentation (40 mm × 32 mm). (b) After two weeks of prednisolone therapy and open wound management. (c) After three weeks of prednisolone therapy: granulation tissue formation with some epithelialisation (28 mm × 25 mm). (d) After four weeks of prednisolone therapy: excessive granulation tissue at the time before seed skin grafting (25 mm × 20 mm)

in the dermis, associated with tissue cavitation, draining sinus formation, consistent with a pyogranulomatous dermatitis, furunculosis and cellulitis (Figures 2a, b). A diagnosis of SPS was confirmed. Haematological analysis revealed a mild neutrophilia and eosinophilia. Serum biochemical analysis was within reference limits. Ultrasound-guided fine needle aspiration (FNA) of the left salivary gland and submandibular lymph nodes confirmed a pyogranulomatous sialoadenitis and lymphadenitis, respectively. Ophthalmological examination confirmed a diagnosis of bilateral superficial keratitis. Treatment with prednisolone 1 mg/kg, twice daily per os, and topical 1% prednisolone acetate and 0.12% phenylephrine hydrochloride (Prednefrin Forte, Allergan Australia Pty Ltd; Sydney, Australia) eye drops, four times daily were instituted.

Cutaneous ulcers were flushed with sterile saline and a propylene glycol hydrogel (INTRASITE Gel, Smith & Nephew; London, UK) applied directly to the surface, which was covered by a hydrophilic nonadhesive foam dressing (KRUUSE; Langeskov, Denmark), rayon fleece (Soffban, Essity; Stockholm, Sweden) and a light conforming bandage (Fun-Flex Pet Bandage; KRUUSE). Dressings were changed twice each week (Figure 1b). After three weeks of prednisolone therapy, there was noticeable contraction of the right forelimb lesion with new epithelium emanating centrally from the margins (Figure 1c). The rate of epithelialisation had plateaued by the fourth week of prednisolone treatment. The open wound remained a substantial size, encircling half of the circumference of the carpus and measured 25 × 20 mm. Granulation tissue had become exuberant and was elevated 3 mm above the

wound surface (Figure 1d). The left hind limb lesion measured 5 mm in diameter (Figure 3). Full-thickness skin seed grafting was recommended to enhance epithelialisation of the open wound and obviate any further contracture.

Seed grafting was performed as described recently.⁵ Full-thickness donor skin of approximately 4 cm² in area was harvested from the right lateral thorax, including the panniculus muscle. The graft was stretched and sutured across a piece of sterile cardboard with the subcutaneous tissue facing uppermost. The panniculus muscle and subcutaneous fat were meticulously excised until the corrugated surface of the dermis was visualised. A 4 mm diameter skin biopsy punch (Biopunch, Ted Pella, Inc.; Redding, CA, USA) was used to harvest the seed grafts from the donor skin. Fifteen seed grafts were implanted into pockets in the granulation tissue of the right forelimb wound (Figures 1d, 4a) and a single seed graft was implanted into the left hind limb wound. The graft sites were covered with petrolatum-impregnated gauze (Jelonet; Smith & Nephew) followed by antimicrobial polyhexamethylene biguanide-impregnated gauze bandage (Kerlix AMD, Cardinal Health; Dublin, OH, USA), absorbent rayon fleece (Soffban; Essity) and a cohesive layer (Fun-Flex Pet Bandage; KRUUSE) for protection. Bandage dressings were changed at 5, 10, 16, 21 and 36 d post-surgery. The grafts became incorporated into the wound bed and progressive epithelialisation emanating from the grafts was noted at sequential bandage changes. Complete epithelialisation of both lesions without contracture was achieved at 46 d post-surgery (Figures 3d, 4b). The graft site was smooth and alopecic with an even surface. The owner was satisfied with the cosmetic outcome and reported

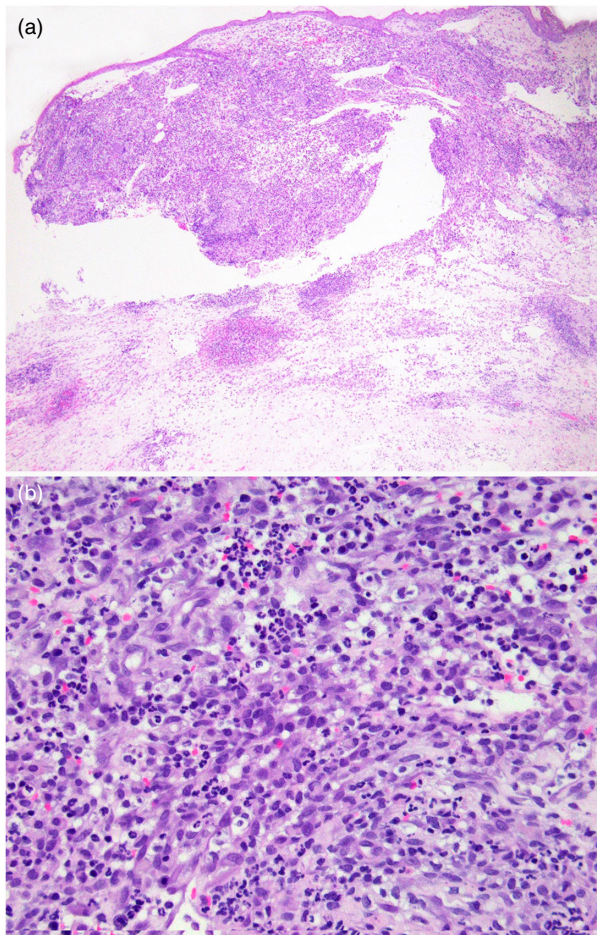


FIGURE 2 Skin biopsy from the right forelimb of a dog with sterile pyogranuloma syndrome. (a) Multifocal and coalescing neutrophilic to pyogranulomatous dermatitis and cellulitis with tissue cavitation and draining sinus formation (haematoxylin & eosin, $\times 12.5$, scale bar = $500\mu\text{m}$). (b) Higher magnification view showing pyogranulomatous dermatitis ($\times 400$, scale bar = $50\mu\text{m}$)

excellent limb function without reduced range of motion of the carpal or tarsal joints.

Prednisolone was tapered to 0.5mg/kg p.o., once daily yet dysphagia and self-trauma of the right carpal region relapsed. Ciclosporin (Atopica, Elanco; Greenfield, IN, USA) 5mg/kg p.o., once daily was commenced and prednisolone dosage was tapered and withdrawn after four weeks. At the 17 month follow-up, ciclosporin (Atopica; Elanco) was reduced to 5mg/kg p.o., every second day as the dog remained in remission with no development of new cutaneous lesions (Figures 3e, 4c) nor evidence of lymphadenitis, sialoadenitis and keratitis.

DISCUSSION

This case report describes the resolution of full-thickness cutaneous ulcerations in a dog caused by SPS, achieved using a combination of immunosuppressive medical therapy and surgical skin seed grafting. We demonstrate the use of prednisolone and ciclosporin to control the immune-mediated SPS and highlight the utility of seed grafting to resolve the challenges in re-epithelialisation of full-thickness wounds

affecting the distal limbs. Such technique provided rapid epithelialisation and coverage of the wound compared to the expected results with the alternative of secondary intention healing. This resulted in minimal contracture, good long-term limb function and an acceptable cosmetic outcome.

A diagnosis of SPS was made based on clinical presentation, histopathological examination, failure to demonstrate an infectious cause and response to therapy. Sterile pyogranulomatous dermatitis and lymphadenitis was considered less likely owing to the presence of dermal nodules and plaques.⁶ Leishmaniasis is not endemic in Australia and therefore was not included as a differential diagnosis.

Immunosuppressive drug therapy is indicated for treatment of SPS. In this case, prednisolone was selected for rapid onset of anti-inflammatory and immunosuppressive effects.³ Following four weeks of medical therapy and wound management, further re-epithelialisation was precluded by excessive granulation tissue and the location of the wound, thereby warranting surgical intervention.

Seed skin graft reconstruction to repair distal limb cutaneous defects caused by trauma or excision of neoplasia has been reported previously in 15 dogs. A successful outcome was reported for all dogs.⁵ Given the location and the relative size of the cutaneous defects in this case, the technique of seed grafting was considered a suitable option to achieve wound epithelialisation and resolution. The time to complete re-epithelialisation in our case was consistent with the average time reported of approximately six weeks.⁵ While new epithelium is, of course, devoid of adnexal structures, skin seed graft sites are reported to undergo partial hair regrowth.⁵ Hair growth can be sporadic and arises from hair follicles in the seeds that survive the transplant process.

Ciclosporin treatment was initiated as a result of excessive polyphagia secondary to prednisolone administration and relapse of dysphagia consistent with sialoadenitis when the prednisolone dosage was tapered. At the time of writing, the dog remains in remission receiving ciclosporin 5mg/kg p.o., every second day.

Extracutaneous signs of lymphadenitis, sialoadenitis and keratitis developed simultaneously with the cutaneous signs. Regional lymphadenopathy has been reported previously in cases of cutaneous SPS.³ Idiopathic pyogranulomatous lymphadenitis is a sterile immune-mediated disease, predominantly affecting the English springer spaniel breed that responds to corticosteroid administration.⁷ Sialoadenitis causing dysphagia and association with cutaneous canine SPS has not been reported previously. Cytological analysis of the FNA from the salivary gland confirmed pyogranulomatous inflammation. The sterile pyogranulomatous submandibular lymphadenitis and sialoadenitis in our case were not confirmed by histopathological or microbiological testing, yet the response to corticosteroid treatment, onset of dysphagia coincident with the skin lesions and relapse with prednisolone withdrawal suggest that there was an immune-mediated aetiology.

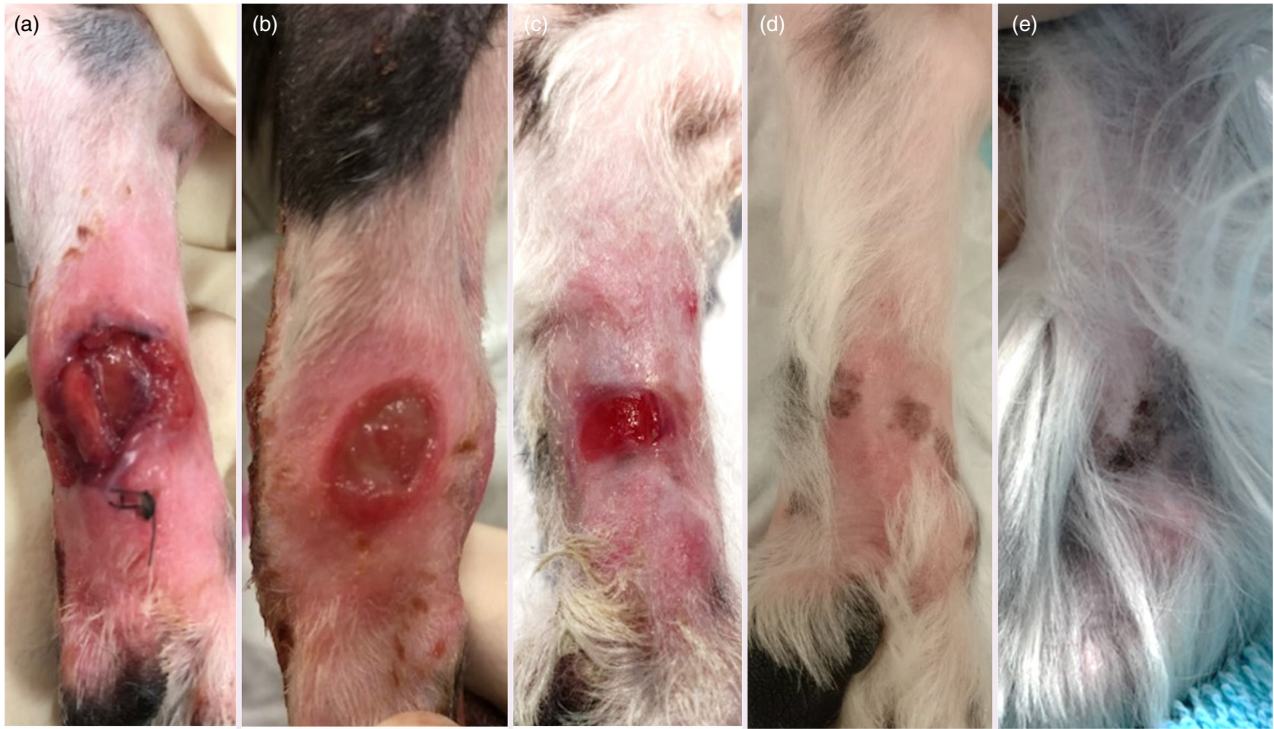


FIGURE 3 Photograph series of the left medial tarsus of a dog with sterile pyogranuloma syndrome. (a) Ulcerative wound exposing underlying tendons at initial presentation. (b) After two weeks of prednisolone and wound management. (c) After four weeks of prednisolone therapy (5mm diameter). (d) Six weeks post-skin graft: complete epithelialisation of the wound without contracture. (e) Seventeen months post-skin graft: alopecia at the site of seed graft

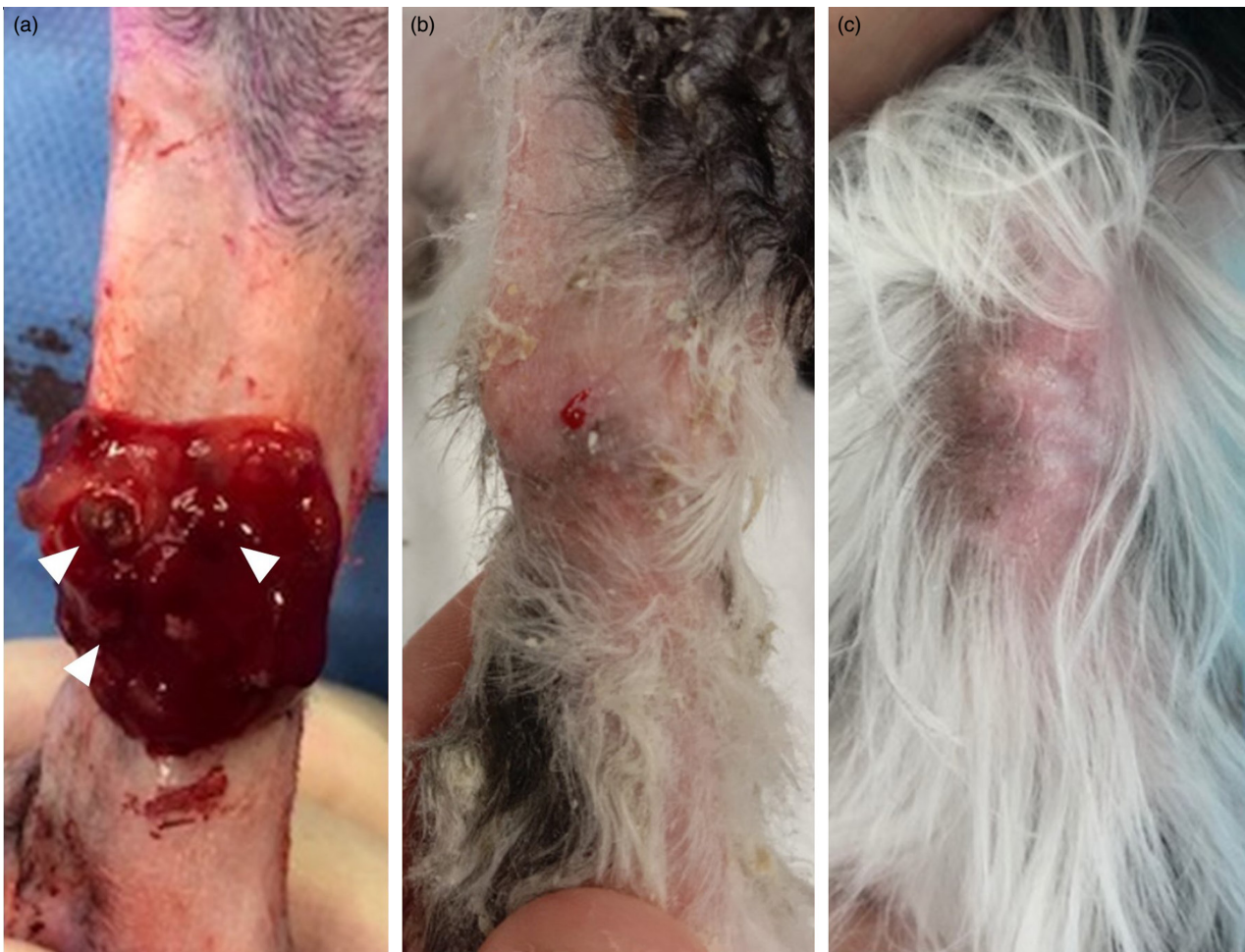

FIGURE 4 Photographic series of the right caudolateral carpus in a dog with sterile pyogranuloma syndrome after seed grafting. (a) Seed skin grafts implanted into wound bed (arrowheads). (b) Six weeks post-graft: complete epithelialisation of wound without contracture. (c) Seventeen months post-skin graft: alopecia at the site of seed graft, no contracture

Immune-mediated keratitis is rare as the cornea is an immune privilege site, yet it has been reported in a single case of SPS.⁸ In the current case, clinical resolution was achieved with topical immunosuppressive therapy suggesting that an immune-mediated process was likely.

This is the first case report using seed grafts for reconstruction of skin defects arising from ulcerative lesions caused by SPS. We have demonstrated that treatment of ulcerative cutaneous immune-mediated disease necessitates not only adequate control of the disease, but also effective resolution of the wounds with consideration of long-term function being of primary importance. Seed grafting is a relatively simple and robust reconstructive technique with minimal adverse effects. It is a procedure that can be performed in a general veterinary practitioner setting. In conjunction with immunosuppressive treatment, seed skin graft reconstruction should be considered as an option for the management of other ulcerative dermatoses, particularly on the distal limbs, where healing by secondary intention is delayed and wound contracture will limit the function of the limb.

AUTHOR CONTRIBUTIONS

Hilary H. Chan: Conceptualisation; Data curation; Formal analysis; Investigation; Writing-original draft.

Amanda K. Burrows: Conceptualisation; Data curation; Investigation; Supervision; Writing-review and editing. **Giselle Hosgood:** Investigation; Writing-review and editing. **Amanda O'Hara:** Investigation. **Rudayna M. Ghubash:** Writing-review and editing.

ACKNOWLEDGEMENTS

The authors would like to thank Wayne Rosenkrantz and Russell Muse for their contributions for their assistance with editing. Open access publishing facilitated by Murdoch University, as part of the Wiley - Murdoch University agreement via the Council of Australian University Librarians.

Résumé

Cet article décrit un cas de syndrome pyogranulome stérile géré avec un traitement immunomodulateur et une greffe de peau. La greffe de peau peut être considérée comme faisant partie d'une approche de traitement multimodal des défauts cutanés causés par des maladies ulcératives à médiation immunitaire où la cicatrisation secondaire est retardée ou contre-indiquée, et pour lesquelles d'autres formes de reconstruction de plaies peuvent être prohibitives.

Resumen

Este artículo describe un caso de síndrome de piogranuloma estéril manejado con terapia inmunomoduladora e injerto de piel por ensemillado. El injerto de piel por ensemillado se puede considerar como parte de un enfoque de tratamiento multimodal para los defectos cutáneos causados por enfermedades ulcerativas inmunomediadas en las que la cicatrización por segunda intención se retrasa o está contraindicada, y otras formas de reconstrucción de heridas pueden ser prohibitivas.

Zusammenfassung

Dieser Bericht beschreibt die Behandlung eines sterilen Pyogranulomata Syndroms, dessen kutane Defekte, die durch eine ulzerative immun-medierte Erkrankung verursacht waren, mit Immunmodulation, da eine Heilung per secundam intentionem bei dieser Erkrankung verzögert oder kontraindiziert sein könnte und auch andere Formen der Wundrekonstruktion prohibitiv sein könnten.

CONFLICTS OF INTEREST

No conflicts of interest have been declared.

ORCID

Hilary H. Chan  <https://orcid.org/0000-0002-1836-9135>

REFERENCES

1. Santoro D, Prisco M, Ciaramella P. Cutaneous sterile granulomas/pyogranulomas, leishmaniasis and mycobacterial infections. *J Small Anim Pract.* 2008; 49: 552–561.
2. Kawarai S, Matsuura S, Yamamoto S et al. A case of cutaneous sterile pyogranuloma/granuloma syndrome in a Maltese. *J Am Anim Hosp Assoc.* 2014; 50: 278–283.
3. Schissler J. Sterile Pyogranulomatous dermatitis and panniculitis. *Vet Clin North Am Small Anim Pract.* 2019; 49: 27–36.
4. Perego R, Proverbio D, Zuccaro A et al. Low-level laser therapy: Case-control study in dogs with sterile pyogranulomatous pododermatitis. *Vet World.* 2016; 9: 882–887.
5. Crowley JD, Hosgood G, Appelgrein C. Seed skin grafts for reconstruction of distal limb defects in 15 dogs. *J Small Anim Pract.* 2020; 61: 561–567.
6. Inga A, Griffeth GC, Drobatz KJ et al. Sterile granulomatous dermatitis and lymphadenitis (juvenile cellulitis) in adult dogs: a retrospective analysis of 90 cases (2004–2018). *Vet Dermatol.* 2020; 31: 219–e47.
7. Ribas Latre A, McPartland A, Cain D et al. Canine sterile steroid-responsive lymphadenitis in 49 dogs. *J Small Anim Pract.* 2019; 60: 280–290.
8. Rahe MC, Corday A, Haynes J. Bilateral sterile pyogranulomatous keratitis in a dog. *Case Rep Vet Med.* 2019; 2019: 8516981.

How to cite this article: Chan HH, Burrows AK, Hosgood G, Ghubash R, O'Hara A. Sterile pyogranuloma syndrome in a dog successfully treated with immunosuppressive therapy and reconstructive seed grafting. *Vet Dermatol.* 2022;33:454–458. [doi:10.1111/vde.13098](https://doi.org/10.1111/vde.13098)

要約

本報告では、免疫調節療法および種皮移植により治療した無菌性化膿性肉芽腫症候群の1例を示す。二次治療が遅延するか禁忌である、潰瘍性免疫介在性疾患による皮膚欠損において、他の形態の創傷再建が困難な場合、種皮移植は多剤併用療法アプローチの一部として考慮することが可能である。

摘要

本报告描述了1例通过免疫调节治疗和颗粒皮肤移植治疗的无菌性脓肉芽肿综合征病例。对于由溃疡性免疫介导的疾病引起的皮肤缺损，如果二期愈合延迟或禁忌，可以考虑将颗粒皮肤移植作为多模式治疗方法的一部分，而其他形式的伤口重建可能无法实施。

Resumo

Este relato descreve um caso de síndrome do piogranuloma estéril tratado com terapia imunomoduladora e enxerto de pele. Enxertia de pele pode ser considerada parte da terapia multimodal para defeitos cutâneos causados por doenças imunomediadas ulcerativas em que a cicatrização por segunda intenção é postergada ou contraindicada, e outras formas de reconstrução de feridas são proibitivas.