



Aggressive Presentation and Rapid Progression of Osteonecrosis of the Femoral Head After COVID-19

Palanisami Dhanasekararaja¹ · Dhanasekaran Soundarrajan¹ · Kanugula Sandeep Kumar¹ · B. T. Pushpa² · Natesan Rajkumar¹ · Shanmuganathan Rajasekaran¹

Received: 4 December 2021 / Accepted: 29 March 2022 / Published online: 25 April 2022
© Indian Orthopaedics Association 2022

Abstract

Background We aim to report the consecutive patients diagnosed with osteonecrosis of femoral head (ONFH) following recovery from COVID-19 disease and elucidate the unique features of ONFH associated with COVID-19.

Methods Consecutive 22 patients (39 hips) recovered from COVID-19 and presented with ONFH from November 2020 to October 2021 were included. All the patients received corticosteroids as a supportive treatment during COVID-19. Patients were classified into two types based on the type of presentation, namely classic ONFH and rapidly destructive coxarthrosis (RDC) depending on radiographs, MRI, inflammatory markers and hip aspiration findings. Harris hip score was used to evaluate the functional outcome before and after treatment.

Results The mean time to diagnose of ONFH from the onset of hip symptoms was 39.3 days (range 10–90 days). The average duration of onset of hip symptoms after COVID 19 infection was 7.5 months (range 3 – 11 months). The average cumulative dose of methylprednisolone equivalent was 811 mg (range 200–2100 mg) and the average duration of steroid intake was 2.8 weeks. There was significant elevation in the inflammatory markers in RDC group compared to classic ONFH ($p < 0.05$). The Harris hip score improved from 63.6 ± 23.2 at presentation to 82.6 ± 9.6 after treatment ($p < 0.05$). Three patients had features of RDC. Among the three patients with RDC, two patients had rapid progression of ONFH and underwent total hip arthroplasty (THA). The third patient is awaiting a THA.

Conclusion ONFH after COVID-19 can have a varied presentation. While the most common presentation is like classical ONFH, some patients can have an acute and aggressive presentation with rapid destruction. They have features like elevated serological markers and extensive periarticular bone and soft tissue edema. A low cumulative dose of steroids in our patients suggests that the COVID-19-associated vasculitis may play a role in the pathogenesis of ONFH.

Keywords Osteonecrosis of the femoral head (ONFH) · Avascular necrosis · Femoral head · Musculoskeletal manifestation · Total hip arthroplasty · COVID-19 · Coronavirus

✉ Palanisami Dhanasekararaja
dhanasekararaja@gmail.com

Dhanasekaran Soundarrajan
soundarortho@gmail.com

Kanugula Sandeep Kumar
sandeepkanugula@gmail.com

B. T. Pushpa
docpushpa@gmail.com

Natesan Rajkumar
drrajkumarn@gmail.com

Shanmuganathan Rajasekaran
rajasekaran.orth@gmail.com

¹ Department of Orthopaedics, Ganga Hospital, 313, Mettupalayam Road, Coimbatore 641 043, India

² Department of Radiology, Ganga Hospital, 313, Mettupalayam Road, Coimbatore 641 043, India

Introduction

COVID-19 pandemic is caused by severe acute respiratory syndrome novel coronavirus 2. (SARS-CoV-2) [1]. According to WHO, globally, as of 8 June 2021, there have been 173,331,478 confirmed cases of COVID-19, including 3,735,571 deaths [2]. Currently, the management for COVID-19 is symptomatic treatment and supportive care. Systemic corticosteroids are administered for moderate to severe disease with desaturation and to fight against the cytokine storm [3]. Osteonecrosis of the femoral head (ONFH) is one of the serious adverse events which occur either due to the COVID-19 disease per se or complications in using the supraphysiologic dose of systemic corticosteroids.

Corticosteroids were widely used in the treatment of the SARS epidemic of 2003 to reduce lung inflammatory infiltration and improve oxygenation. Zheng et al., in a recent review, warned that high doses of systemic corticosteroid might work as a double-edged sword; and might be associated with steroid-induced ONFH [1]. The incidence of steroid-induced ONFH was as high as 24.1% among 539 patients treated for SARS, of which 42 hips required surgical treatment [4]. The various risk factors are male gender, younger age, higher cumulative dose of steroid, long duration of treatment and use of more than one type of steroid [4, 5].

The current evidence on ONFH in patients treated for COVID-19 is limited to a few case reports [6]. We aim to evaluate the clinical and radiological presentation uniquely associated with ONFH in patients recovered from COVID-19.

Patients and Methods

We prospectively analysed 22 consecutive patients (39 hips) who recovered from COVID-19 and were diagnosed with ONFH from November 2020 to October 2021 (Table 1). Patients with prior hip pain before COVID-19 treatment, previous surgery in the involved hip, chronic steroid intake, alcohol abuse, patients with hypercoagulable states were excluded from the study. Patients age, gender, body mass index, duration between COVID-19 infection and initial hip symptoms, duration of hip pain was collected. The institutional ethics and research committee approval (Application no: 2021/02/11) was obtained. Informed consent was obtained from all the patients that their data may be used for publication.

All 22 patients were diagnosed as COVID-19 positive with RT-PCR and/or HRCT of the chest. None of

the patients had previous hip pain or comorbidities confounding to the development of ONFH. All the patients received corticosteroids as a supportive treatment during COVID-19. Methylprednisolone was the most commonly used steroid and other steroid forms like Dexamethasone, Prednisolone and Deflazacort were also used. For uniform reporting, we calculated the methylprednisolone equivalent dose by the conversion factor of 0.8 for prednisolone, 0.6 for deflazacort and 5.3 for dexamethasone [5, 7].

All the patients who presented with acute hip pain to our outpatient clinic were screened with plain radiographs and then with MRI examination. ONFH was diagnosed using MRI and interpreted by a senior musculoskeletal radiologist. The diagnosis of ONFH was made by a single density "bandlike" lesion with a low rim of signal intensity that surrounds necrosis in T1 images and by a "double line sign" consisting of an external low signal intensity rim and a high signal intensity internal rim on the T2 image. Ficat and Arlet grading was used to stage the ONFH in radiographs [8]. Mitchell classification was used to stage the ONFH based on the MRI signal within the centre of the lesion [9]. Japanese investigation Committee (JIC) classification was used to categorize the location of the necrotic lesion at the weight-bearing zone into A, B, C1 and C2 [8–10]. The necrotic angle severity was calculated in midcoronal and midsagittal image in MRI (Fig. 1) and graded by modified Kerboul angle into grade 1 ($< 200^\circ$), grade 2 (200° – 249°), grade 3 (250° – 299°), and grade 4 ($> 300^\circ$) [10]. The edema involving only over the weight-bearing necrotic zone in the femoral head was graded as mild, edema extending into the femoral neck region was graded as moderate and edema involving beyond neck region, acetabulum, periarticular soft tissue with effusion was graded as severe (Table 2).

Laboratory parameters include erythrocyte sedimentation rate (ESR), C-reactive protein (CRP), and White blood cell (WBC) count. Patients were classified into two types, namely classic ONFH and rapidly destructive coxarthrosis (RDC) based on radiographs, MRI and inflammatory markers (Table 3). Hip aspiration was done for patients presenting with elevated inflammatory parameters to rule out associated septic arthritis. All the patients underwent initial conservative therapy with bisphosphonates, calcium and non-steroidal anti-inflammatory agents.

The Student *t* test was used to compare the means between pre and post-treatment Harris hip score, and descriptive statistics were reported as mean (SD) for continuous variables and as frequencies (percentage) for categorical variables. Independent *t* test was used to compare the inflammatory parameters between classic ONFH and RDC group. All analyses were performed using SPSS for Windows Inc. version 22 (IBM Inc., Chicago, IL). A *p* value less than 0.05 was considered significant.

Table 1 Demographic variables, total cumulative steroid dose and laboratory parameters in patients with osteonecrosis of the femoral head after COVID

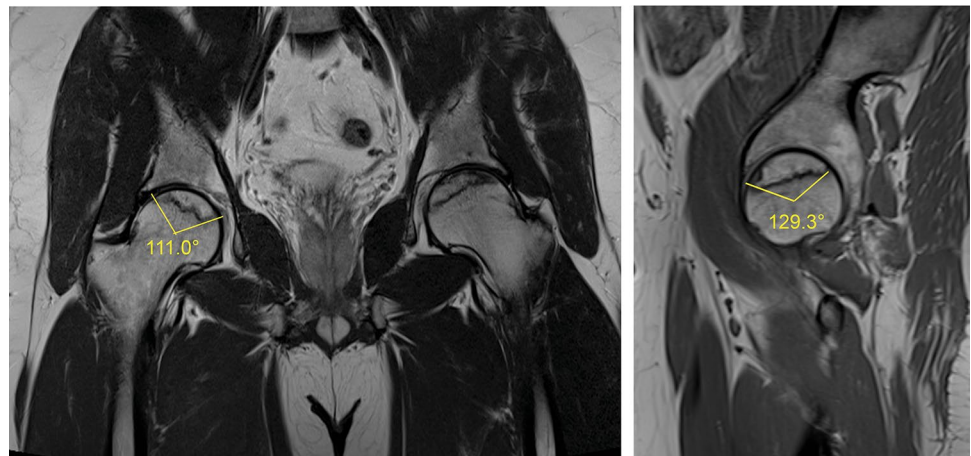
Pt. no	Age	Sex	BMI	Comorbidities	COVID positivity before hip symptoms (in months)	Duration of symptoms (in days)	Affection	Total cumulative steroid dose (methylprednisolone equivalent in mg)	Total duration of steroid intake (in weeks)	Presenting parameters			Follow up parameters			Hip aspiration	Pre-treatment Harris hip score (HSS)	Post-treatment Harris hip score (HSS)
										ESR	CRP	WBC	ESR	CRP	WBC			
1	62	F	28.6	Hypertension, Diabetes	6	60	Bilateral (R>L)	700	3	109	47	12,900	40	9	8400	No growth	26	84
2	74	F	22.4	Hypertension, Diabetes, Hypothyroid, H/o L4-L5 TLJF (2015)	4	90	Bilateral (L>R)	1800	6	130	70.4	12,500	112	11.8	7800	Dry tap	21	90
3	28	M	22.1	Nil	3	45	Right	260	2	13	9.3	8170	NA	NA	NA	No growth	62	78
4	27	M	36.7	Nil	3	25	Bilateral (R>L)	647.2	2.5	NA	NA	NA	15	12.8	8800	Not done	59	78
5	34	M	25	Nil	8	45	Bilateral (R>L)	287.6	4	NA	NA	NA	12	4	9200	Not done	56	74
6	37	M	26.1	Nil	7	30	Left	1247.2	4	NA	NA	NA	10	7.2	6600	Not done	39	68
7	28	M	24.6	Nil	7	15	Bilateral (R>L)	908	3	8	9.7	8200	NA	NA	NA	Not done	71	82
8	37	M	31.1	Nil	4	15	Bilateral (L>R)	1200	3	30	25	8300	NA	NA	NA	Not done	41	83
9	32	M	23.1	Nil	10	60	Bilateral (L>R)	200	3	24	2.3	6800	NA	NA	NA	Not done	86	90
10	54	M	23.8	Nil	3	70	Bilateral (R>L)	1709	3	85	77.74	6400	26	4.4	5200	No growth	19	62
11	34	M	24.5	Nil	3	30	Bilateral (R>L)	496	2.5	20	4	6200	NA	NA	NA	Not done	96	96
12	45	M	33.7	Hypertension	3	30	Bilateral (R=L)	1017.6	1	45	2.1	4600	NA	NA	NA	Not done	82	92
13	51	M	33.5	Nil	11	30	Bilateral (L>R)	460	3	13	5.4	7100	15	7	7200	Not done	82	82
14	29	M	31.7	Nil	11	90	Bilateral (L>R)	540	3.5	4	16.33	7700	16	9	8140	Not done	71	82
15	59	M	24.2	Nil	11	20	Left	260	1	9	15	6500	10	14	6400	Not done	82	92

Table 1 (continued)

Pt. no	Age	Sex	BMI	Comorbidities	COVID positivity before hip symptoms (in months)	Duration of symptoms (in days)	Affection	Total cumulative steroid dose (methylprednisolone equivalent in mg)	Total duration of steroid intake (in weeks)	Presenting parameters			Follow up parameters			Hip aspiration	Pre-treatment Harris hip score (HSS)	Post-treatment Harris hip score (HSS)
										ESR	CRP	WBC	ESR	CRP	WBC			
16	26	M	27.5	Nil	11	30	Right	280	1.5	10	3.67	9570	10	6.8	11,200	Not done	94	99
17	34	M	28	Nil	6	10	Bilateral (R>L)	460	3	19	2.8	12,600	NA	NA	NA	Not done	66	72
18	34	M	25	Nil	10	21	Bilateral (L>R)	2100	4	12	2.6	6300	NA	NA	NA	Not done	41	68
19	27	M	29.2	Nil	9	30	Bilateral (R>L)	742	2	56	7.6	5200	NA	NA	NA	Not done	72	84
20	25	M	25.1	Nil	10	30	Bilateral (R>L)	460	3	NA	NA	NA	10	4	11,550	Not done	82	89
21	57	M	35.9	Hypertension	11	30	Left	1200	2	41	9.2	7100	NA	NA	NA	Not done	80	91
22	20	M	26.2	Nil	6	60	Bilateral (L>R)	869.2	3	NA	NA	NA	4	4	7460	Not done	72	82

NA not available, BMI body mass index, R right, L left, ESR erythrocyte sedimentation rate, CRP C-reactive protein, WBC white blood cell count, HSS Harris hip score

Fig. 1 MRI showing the bilateral osteonecrosis of femoral head with mild edema and necrotic angle calculation in midcoronal and midsagittal image. By modified kerboul method, the combined necrotic angle is measured and divided into four grades



Results

There were 20 males and 2 females. The mean age was 38.8 years (range 20–74 years) and the mean BMI was 27.6 ± 4.4 (Table 1). The mean time to diagnose ONFH was 39.3 days (range 10–90 days). The average duration of onset of hip symptoms after COVID 19 infection was 7.5 months (range 3 – 11 months). Seventeen out of 22 patients had bilateral ONFH. Two patients have diabetes and 18 patients have no associated comorbidities. The average cumulative dose of methylprednisolone equivalent was 811 mg (range 200–2100 mg) and the average duration of steroid intake was 2.8 weeks (Table 1).

Femoral head showed a large necrotic area with grade 3 and 4 in 14 hips (35.9%) according to modified Kerboul angle and type C involvement in 28 hips (71.8%) according to JIC classification (Table 2). There was significant elevation in the inflammatory parameters in RDC group compared to the classic ONFH group ($p < 0.05$). There was a significant reduction in inflammatory parameters compared to the presenting values after treatment (Table 1). There was a significant improvement in Harris hip score from 63.6 ± 23.2 at presentation to 82.6 ± 9.6 after treatment ($p < 0.05$).

The majority of the hips (36/39) had features of classical ONFH (Table 2). Plain radiographs showed a subchondral cyst in the weight-bearing dome and lateral part of the head. MRI showed classical focal serpentine line and double-line sign diagnostic of ONFH in all patients and acetabulum is not involved. They all had symptomatic improvement with conservative therapy and did not have further worsening of the symptoms in the follow-up.

Rapidly destructive coxarthrosis is noted in 3 out of 39 hips. They presented with acute severe pain and radiographs showed the rapid collapse of the femoral head. MRI showed diffuse periarticular soft-tissue edema and marrow edema with joint effusion. The inflammatory parameters were elevated. Two patients (2/3) underwent total hip arthroplasty.

The first patient, a 62-year-old female (Patient 1), MRI showed avascular necrosis of femoral head with edema and fluid collection. Preoperative hip aspiration showed no growth in the culture. Intraoperatively, friable tissues with cyst noted even in the acetabulum. She underwent uncemented total hip arthroplasty. The synovial fluid and tissues sent for culture showed no growth. Histopathology showed acute on chronic nonspecific inflammatory granulation tissue.

The second patient, a 74-year-old female (Patient 2), was treated conservatively with empirical oral antibiotics, analgesics and alendronate. But she had rapid progression with varus collapse of the femoral head (Fig. 2c) within 2 months but ESR and CRP returned to normal. She underwent hybrid total hip arthroplasty (Fig. 2d). Intraoperative synovial fluid aspiration showed normal cell count (total leucocyte cell count 1500 cells/cmm, Neutrophils 62%). Antibiotic bone cement was used for femoral stem fixation. Intraoperative cultures showed no growth and histopathology of the femoral head showed features suggestive of avascular necrosis of the femoral head.

The third patient, a 54-year-old male (Patient 10) presented with acute hip pain for 2 months. MRI showed bilateral ONFH with diffuse periarticular and thigh muscle edema. Hip aspiration showed no growth in the culture. He was started on oral amoxicillin and clavulanic acid 625 mg twice daily for 10 days and analgesics. He improved symptomatically, but radiographs showed femoral head collapse and will require THA in future.

Discussion

Although majority of the patients present with classical features of ONFH after COVID-19, a subgroup of patients have an aggressive presentation and rapid progression resulting in a rapidly destructive coxarthrosis. They have

Table 2 Classification of patients with ONFH based on clinical presentation, MRI findings and correlation with the clinical progression

Pt. no	Side	Ficat and Arlet classification	Mitchel classification	JIC classification	Modified Kerboul angle grade	Periarticular bone and soft tissue edema grade (mild/moderate/severe)	COVID-ONFH classification	Progression
1	Right	IIB	D	C2	4	Moderate	Rapidly destructive coxarthrosis	Total hip arthroplasty
1	Left	IIA	B	B	2	Mild	Classic ONFH	Occasional pain
2	Right	IIA	B	A	1	Mild	Classic ONFH	Occasional pain
2	Left	III	C	C2	4	Severe	Rapidly destructive coxarthrosis	Total hip arthroplasty
3	Right	IIA	B	C2	4	Severe	Classic ONFH	Pain affecting activities of daily living
4	Right	III	A	C2	4	Severe	Classic ONFH	Painful on strenuous activities
4	Left	III	A	C2	3	Moderate	Classic ONFH	Occasional pain
5	Right	IIA	B	B	2	Moderate	Classic ONFH	Asymptomatic
5	Left	IIA	B	C1	3	Moderate	Classic ONFH	Painful on strenuous activities
6	Left	IIA	C	B	3	Moderate	Classic ONFH	Pain affecting activities of daily living
7	Right	IIA	D	C2	3	Mild	Classic ONFH	Pain affecting activities of daily living
7	Left	IIA	B	C1	2	Mild	Classic ONFH	Asymptomatic
8	Right	IIA	B	C1	3	Mild	Classic ONFH	Asymptomatic
8	Left	IIA	B	B	2	Mild	Classic ONFH	Occasional pain
9	Left	IIB	A	B	1	Mild	Classic ONFH	Pain affecting activities of daily living
9	Right	III	C	B	1	Mild	Classic ONFH	Asymptomatic
10	Right	III	B	C2	3	Severe	Rapidly destructive coxarthrosis	Pain affecting activities of daily living and symptomatically improved with conservative management
10	Left	IIB	A	B	1	Mild	Classic ONFH	Occasional pain
11	Right	IIA	A	C2	2	Mild	Classic ONFH	Occasional pain
11	Left	IIA	A	C1	2	Mild	Classic ONFH	Asymptomatic
12	Right	IIA	A	C2	1	Mild	Classic ONFH	Occasional pain
12	Left	IIA	A	B	1	Mild	Classic ONFH	Painful on strenuous activities
13	Left	IIA	A	C2	1	Mild	Classic ONFH	Painful on strenuous activities
13	Right	IIA	A	C2	1	Mild	Classic ONFH	Asymptomatic
14	Left	IIB	A	C2	1	Moderate	Classic ONFH	Underwent core decompression elsewhere
15	Left	IIA	A	C1	2	Mild	Classic ONFH	Painful on strenuous activities
16	Right	IIB	B	A	1	Mild	Classic ONFH	Painful on strenuous activities
16	Left	IIB	B	B	1	Mild	Classic ONFH	Asymptomatic
17	Right	IIA	B	C2	3	Mild	Classic ONFH	Painful on strenuous activities
17	Left	IIA	B	C2	3	Mild	Classic ONFH	Asymptomatic
18	Left	III	A	C2	3	Mild	Classic ONFH	Pain affecting activities of daily living
18	Right	IIA	A	C2	2	Mild	Classic ONFH	Asymptomatic

Table 2 (continued)

Pt. no	Side	Ficat and Arlet classification	Mitchel classification	JIC classification	Modified Kerboul angle grade	Periarticular bone and soft tissue edema grade (mild/moderate/severe)	COVID-ONFH classification	Progression
19	Right	IIA	B	C1	2	Moderate	Classic ONFH	Painful on strenuous activities
19	Left	IIA	B	C1	2	Mild	Classic ONFH	Asymptomatic
20	Right	IIA	A	C1	2	Moderate	Classic ONFH	Painful on strenuous activities
20	Left	IIA	A	C1	1	Moderate	Classic ONFH	Asymptomatic
21	Left	IIA	B	C1	2	Mild	Classic ONFH	Painful on strenuous activities
22	Left	IIA	A	C2	3	Moderate	Classic ONFH	Painful on strenuous activities
22	Right	IIA	A	C1	2	Mild	Classic ONFH	Painful on strenuous activities

JIC classification Japanese investigation Committee (JIC) classification, *ONFH* Osteonecrosis of femoral head

Table 3 Classification of various presentations on osteonecrosis of the femoral head after COVID-19 disease

	Classic ONFH	Rapidly destructive coxarthrosis
Radiographs	Cysts and sclerosis	Acute onset femoral head collapse
MRI	Only femoral head involvement	Acetabular changes present, diffuse periarticular bone and soft tissue edema
Blood parameters (ESR, CRP)	Within normal limits	Elevated
Histology	No inflammation	Mixed findings
Hip aspiration	Sterile	Sterile

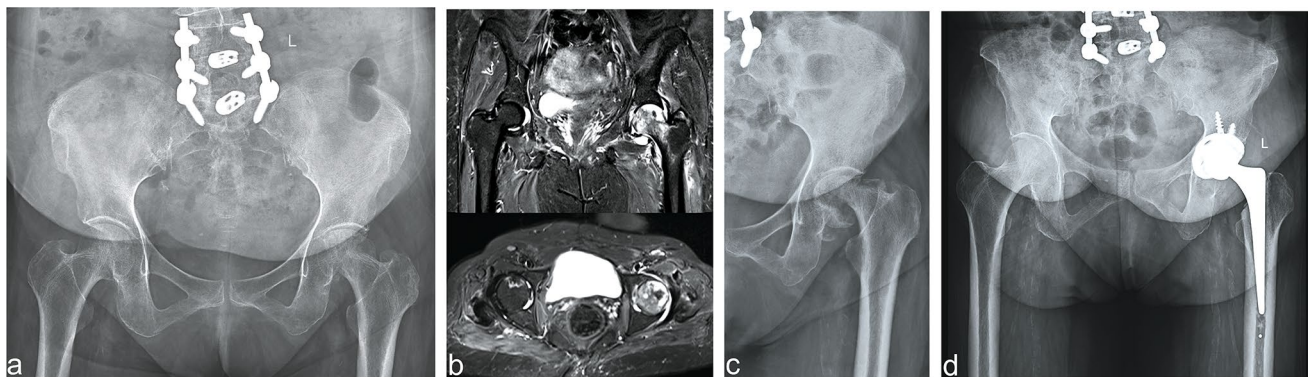


Fig. 2 **a** Radiograph showing subchondral cyst and osteolysis in the left femoral head. **b** MRI showing severe marrow and periarticular soft-tissue edema with joint effusion. **c** rapid progression and varus

collapse of the femoral head at 2 months suggestive of rapid progressive coxarthrosis. **d** radiograph showing hybrid total hip arthroplasty. The intraoperative culture showed no growth

features like elevated serological markers, joint effusion and extensive periarticular bone marrow and soft tissue edema. There is always a high risk for possible coexisting infection, especially in diabetic patients and this needs to be ruled out by preoperative hip aspiration. A low cumulative dose of steroids in our patients suggests that the

COVID-19 itself may play a role in the pathogenesis of ONFH.

ONFH has a multifactorial aetiology that includes genetic factors, corticosteroid usage, conditions with hypercoagulable states, vasculitis and alcohol abuse [4]. A recent meta-analysis showed 1137 patients recovered

from the SARS epidemic showed a significant association between the cumulative dose of steroid and treatment duration on the incidence of ONFH [5]. They concluded that the risk of ONFH is low when the cumulative dose of steroids (methylprednisolone equivalent) is less than 5 g and increased when the dose exceeds 10 g [5].

COVID-19 induces a hypercoagulable state and increases the risk of thrombosis. Immunological studies show pro-inflammatory cytokines like Interleukin (IL)-1, IL-6, tumour necrosis factor-alpha and IL-17 A are elevated [1, 6]. It induces inflammation of blood vessels with subsequent leukocyte/platelet aggregation and impairment of microvascular blood flow [11]. The distinct pathological features are endothelial cell inflammation, vessel wall fragmentation, endothelial cell pyknosis and karyorrhexis. The classic histological findings of vasculitis are predominantly neutrophilic infiltrates affecting small and medium-sized blood vessels [11]. In our series, the cumulative dose of methylprednisolone equivalent dose is less than 5 g in all patients. This shows that steroid use, together with COVID-19 disease-induced thrombosis, may have been the cause of ONFH development [6].

The onset time of ONFH after corticosteroid ranges between 3 weeks and 3 months. MRI is the most sensitive technique to diagnose ONFH and helps in staging and estimating prognosis [12]. STIR MRI showed high-intensity bone marrow lesions as early as 3 weeks after initiation of corticosteroid therapy and it preceded the typical low-intensity band on T1 weighted image characteristic of ONFH [13]. The various described MRI findings in ONFH are concave shaped low-intensity lesions, the geographic pattern of subchondral region, bone marrow edema, subchondral cysts, double-line sign and joint effusion [9, 13]. The unique findings apart from the classical ONFH were the larger involvement of the femoral head, bilateral hip involvement, with extensive marrow and periarticular soft-tissue edema (Tables 1, 2).

We have classified our patients post-COVID ONFH into two groups based on clinical, radiological and inflammatory parameters. They are classical ONFH and rapidly destructive coxarthrosis (RDC) (Table 3). RDC group had an acute and aggressive presentation with elevated serological markers and extensive periarticular bone and soft tissue edema. In a study by Guo et al., involving 539 patients with severe acute respiratory syndrome (SARS) treated with steroids, the incidence of ONFH is found to be more common in younger age group less than 50 years [4]. In our study, the rapid progression was noted in the patients above 50 years (62, 74 and 54 years of age) against the mean age of 38.8 years. It appears as though age is an independent risk factor for RDC, however the sample size is low to make this generalized statement.

The classical ONFH group were treated with bisphosphonates, analgesics, calcium, diabetic control and lifestyle modification. They had symptomatic improvement with conservative therapy in the short-term follow-up. However, these patients need to be reviewed in long term to find the exact natural history of the disease. We have not advocated core decompression in any patients even in the pre-collapse stage in view of the efficacy with bisphosphonate therapy alone and also the poor prognosis associated with steroid induced ONFH [14, 15]. A recently published long-term follow-up study also shows bisphosphonate therapy retard the disease progression and reduce the rate of femoral head collapse [16, 17].

Hip aspiration is recommended to differentiate RDC from primary septic arthritis of hip. In case of muscle and bone edema without any aspirable joint fluid, intraoperative findings along with ESR/CRP trend should be taken into consideration for appropriate treatment. Patients with RDC benefit from total hip arthroplasty. Patients with septic arthritis of hip should be treated with debridement and antibiotic spacer as a first stage and then proceeded by second-stage revision.

The limitations to our study are short-term follow-up and lack of a control group. Moreover,

analysis of all COVID-19 patients who received steroid therapy and following them might give the exact incidence of ONFH after COVID-19. The inflammatory parameters were not analysed in some patients at presentation whose clinical and radiographic features were suggestive of mild disease. However, these patients blood parameters are checked in the follow-up to rule out progression to RDC. Nevertheless, this preliminary study evaluated the large series of patients and elucidated the unique features of ONFH associated with COVID-19. These patients need to be followed up further and a multicentric study with larger numbers is necessary to know the exact natural history of the disease in COVID-19.

Conclusion

Patients who recover from COVID-19 presenting with hip pain should be evaluated by MRI of both hips for early diagnosis of ONFH. The ONFH after COVID-19 can have a varied presentation. While the most common presentation is like classical ONFH, some patients can have an acute and aggressive presentation with rapid destruction. They have features like acute severe pain at presentation, elevated serological markers and extensive periarticular bone and soft tissue edema noted in the MRI. Bisphosphonates may be useful to prevent collapse and slow the disease progression but these patients need a longer follow-up to evaluate its efficacy. A low cumulative dose of steroids in our patients suggests that the COVID-19 associated with vasculitis may play a role in the pathogenesis of ONFH.

Funding This research did not receive any specific grant from funding agencies in the public, commercial, or not-for-profit sectors.

Declarations

Conflict of Interest Palanisami Dhanasekararaja, Dhanasekaran Soundarajan, Kanugula Sandeep Kumar, BT Pushpa, Natesan Rajkumar and Shanmuganathan Rajasekaran declare that they have no conflict of interest.

Ethical Standard Statement This article does not contain any studies with human or animal subjects performed by the any of the authors.

Informed consent All procedures followed were in accordance with the ethical standards of the responsible committee on human experimentation (institutional and national) and with the Helsinki Declaration of 1975, as revised in 2008. Informed consent was obtained from all patients for being included in the study.

References

- Zhang, S., Wang, C., Shi, L., & Xue, Q. (2021). Beware of steroid-induced avascular necrosis of the femoral head in the treatment of COVID-19—Experience and lessons from the SARS epidemic. *DDDT*, 15, 983–995. <https://doi.org/10.2147/DDDT.S298691>
- <https://covid19.who.int>.
- Zhang, B., & Zhang, S. (2020). Corticosteroid-induced osteonecrosis in COVID-19: A call for caution. *Journal of Bone and Mineral Research*, 35(9), 1828–1829. <https://doi.org/10.1002/jbmr.4136>
- Guo, K. J., Zhao, F. C., Guo, Y., Li, F. L., Zhu, L., & Zheng, W. (2014). The influence of age, gender and treatment with steroids on the incidence of osteonecrosis of the femoral head during the management of severe acute respiratory syndrome: A retrospective study. *The Bone & Joint Journal*, 96-B(2), 259–262. <https://doi.org/10.1302/0301-620X.96B2.31935>
- Zhao, R., Wang, H., Wang, X., & Feng, F. (2017). Steroid therapy and the risk of osteonecrosis in SARS patients: A dose-response meta-analysis. *Osteoporosis International*, 28(3), 1027–1034. <https://doi.org/10.1007/s00198-016-3824-z>
- Chacko, A., Babu, M., & Thomas, D. K. (2021). Osteonecrosis of bilateral femoral head in a post COVID-19 patient: Case report. *International Journal of Research and Orthopaedics*, 7(3), 674. <https://doi.org/10.18203/issn.2455-45>
- <https://www.mdcalc.com/steroid-conversion-calculator>.
- Sultan, A. A., Mohamed, N., Samuel, L. T., et al. (2019). Classification systems of hip osteonecrosis: An updated review. *International Orthopaedics (SICOT)*, 43(5), 1089–1095. <https://doi.org/10.1007/s00264-018-4018-4>
- Choudhary, J., Dubepuria, A., Kaushal, L., & Rajput, P. (2019). Magnetic resonance imaging in evaluation of avascular necrosis of femoral head. *International Journal of Scientific Study*, 7(7), 6.
- Takashima, K., Sakai, T., Hamada, H., Takao, M., & Sugano, N. (2018). Which classification system is most useful for classifying osteonecrosis of the femoral head? *Clinical Orthopaedics and Related Research*, 476(6), 1240–1249. <https://doi.org/10.1007/s11999-0000000000000245>
- Becker, R. C. (2020). COVID-19-associated vasculitis and vasculopathy. *Journal of Thrombosis and Thrombolysis*, 22, 1–3.
- Hong, N., & Du, X. K. (2004). Avascular necrosis of bone in severe acute respiratory syndrome. *Clinical Radiology*, 59(7), 602–608. <https://doi.org/10.1016/j.crad.2003.12.008>
- Kubo, Y., Yamamoto, T., Motomura, G., et al. (2015). MRI-detected bone marrow changes within 3 weeks after initiation of high-dose corticosteroid therapy: A possible change preceding the subsequent appearance of low-intensity band in femoral head osteonecrosis. *Rheumatology International*, 35(11), 1909–1912. <https://doi.org/10.1007/s00296-015-3346-6>
- Gianakos, A. L., Moya-Angeler, J., Duggal, S., Zambrana, L., Fields, K. G., Mintz, D. N., Cornell, C. N., & Lane, J. M. (2016). The efficacy of bisphosphonates with core decompression and mesenchymal stem cells compared with bisphosphonates alone in the treatment of osteonecrosis of the hip: A retrospective study. *HSS Journal*, 12(2), 137–144. <https://doi.org/10.1007/s11420-016-9487-7>
- Andronic, O., Weiss, O., Shoman, H., Kriechling, P., & Khanduja, V. (2021). What are the outcomes of core decompression without augmentation in patients with nontraumatic osteonecrosis of the femoral head? *International Orthopaedics*, 45(3), 605–613.
- Agarwala, S., & Vijayvargiya, M. (2021). A paradigm shift in osteonecrosis treatment with bisphosphonates: A 20-year study. *JBJS Open Access*, 6(4), e21.00042.
- Lai, K. A., Shen, W. J., Yang, C. Y., Shao, C. J., Hsu, J. T., & Lin, R. M. (2005). The use of alendronate to prevent early collapse of the femoral head in patients with nontraumatic osteonecrosis: A randomized clinical study. *JBJS*, 87(10), 2155–2159.

Publisher's Note Springer Nature remains neutral with regard to jurisdictional claims in published maps and institutional affiliations.