

Available online at www.sciencedirect.com

ScienceDirect

journal homepage: www.elsevier.com/locate/radcr

Case Report

Thoracic endometriosis presenting as a catamenial hemothorax with discordant video-assisted thoracoscopic surgery ☆,☆☆

Matthew R. McCann, MD^{a,*}, William B. Schenk, MD^a, Aziza Nassar, MD, MPH^b, Santo Maimone, MD^a

^aDepartment of Radiology, Mayo Clinic Florida, Jacksonville, FL, USA

^bDepartment of Laboratory Medicine and Pathology, Mayo Clinic Florida, Jacksonville, FL, USA

ARTICLE INFO

Article history:

Received 12 April 2020

Accepted 29 May 2020

Keywords:

Thoracic endometriosis

Hemothorax

Immunohistochemistry

Cytology

Video-assisted thoracoscopic surgery

ABSTRACT

Thoracic endometriosis is uncommon and may be overlooked, resulting in a delay in diagnosis. We describe the case of a 47-year-old woman presenting with acute onset pleuritic pain and hemothorax secondary to this rare entity. The diagnosis of thoracic endometriosis is driven by a compatible clinical history coupled with supportive imaging and immunohistochemical findings. Imaging features lack specificity, however, computed tomography and magnetic resonance imaging play an important role in identifying pleural/diaphragmatic involvement and excluding other more common diseases. Immunohistochemical pleural fluid analysis can confirm the presence of hormone receptor-positive endometrial glands and stroma. We illustrate a few potential diagnostic pitfalls, specifically the inconsistency in diagnostic yield of video-assisted thoracoscopic surgery/thoracentesis and the variable temporal association of patients' symptoms and pathology with menstruation. Prompt identification of thoracic endometriosis is important as it enables early institution of therapy and limits future complications.

© 2020 The Authors. Published by Elsevier Inc. on behalf of University of Washington.

This is an open access article under the CC BY-NC-ND license.

(<http://creativecommons.org/licenses/by-nc-nd/4.0/>)

☆ Competing Interests: No conflicts of interest exist for Drs. McCann, Schenk, Nassar, and Maimone.

☆☆ Author Contributions MRM contributed to case concept and design, acquisition of data, interpretation of data, and manuscript writing. WBS contributed to case concept and design, interpretation of data, and critical revision of manuscript for intellectual content. AN contributed to case concept and design, interpretation of data, and critical revision of manuscript for intellectual content. SM contributed to case concept and design, interpretation of data, and critical revision of manuscript for intellectual content.

* Corresponding author.

E-mail address: McCann.Matthew@mayo.edu (M.R. McCann).

<https://doi.org/10.1016/j.radcr.2020.05.064>

1930-0433/© 2020 The Authors. Published by Elsevier Inc. on behalf of University of Washington. This is an open access article under the CC BY-NC-ND license. (<http://creativecommons.org/licenses/by-nc-nd/4.0/>)

Introduction

Endometriosis is a common benign condition presenting with endometrial-like glands and stroma outside of the uterus, affecting at least 6%-10% of reproductive-aged women [1]. Although extra-pelvic manifestations of endometriosis are rare, there is a predilection for thoracic involvement [2]. Thoracic endometriosis has a variable clinical presentation, with possible repetitive and debilitating clinical manifestations, thus a high level of clinical suspicion is warranted to allow early diagnosis and prevent disease progression [1].

Case report

A 47-year-old nulliparous woman with a history of asthma and endometriosis presented to the emergency department complaining of acute onset right-sided pleuritic chest pain and dizziness. She denied cough, hemoptysis, shortness of breath, fever, chills, and weight loss. She did endorse a history of occasional transient right-sided chest pain following a thoracentesis for a postoperative pleural effusion approximately one year prior. She had no history of venous thromboembolism. Prior surgical history included unilateral salpingo-oophorectomy, hysterectomy, and intra-abdominal lysis of adhesions one year prior, all of which were related to a history of severe endometriosis. She had no known history of trauma, tuberculosis exposure, positive tuberculosis test, foreign travel, malignancy, bleeding diathesis, or anticoagulant use.

Physical examination disclosed dullness to percussion and diminished breath sounds at the right lung base. Initial chest radiograph revealed a right-sided pleural effusion. A computed tomography (CT) angiogram was obtained to rule out pulmonary embolism. There were no pulmonary arterial filling defects, but the CT depicted a moderate-sized mixed-density right pleural effusion with suggestion of hemorrhagic components (Fig. 1). Coagulation and liver function panels were normal. A chest tube was placed, draining 1200 mL of grossly bloody fluid. Cytology was negative for malignancy. Mycobacterial cultures of the pleural fluid and additional testing for tuberculosis (QUANTIFERON) were negative. Microscopic examination of the fluid revealed predominantly blood elements with rare glands. Immunohistochemical staining confirmed the presence of endometrial glands and stroma in the pleural fluid, suggesting a diagnosis of thoracic endometriosis. Video-assisted thoracoscopic surgery (VATS) was undertaken approximately 1 week later to examine the pleural cavity, but no endometrial implants were identified.

Correlation of this patient's symptoms with menstruation was difficult given the prior hysterectomy. Despite the negative VATS, the patient was started on presumptive hormonal suppression therapy given the history of severe endometriosis and the detection of endometrial glands and stroma in the pleural fluid. The patient later underwent oophorectomy of her remaining ovary and has had no recurrence of her symptoms since.

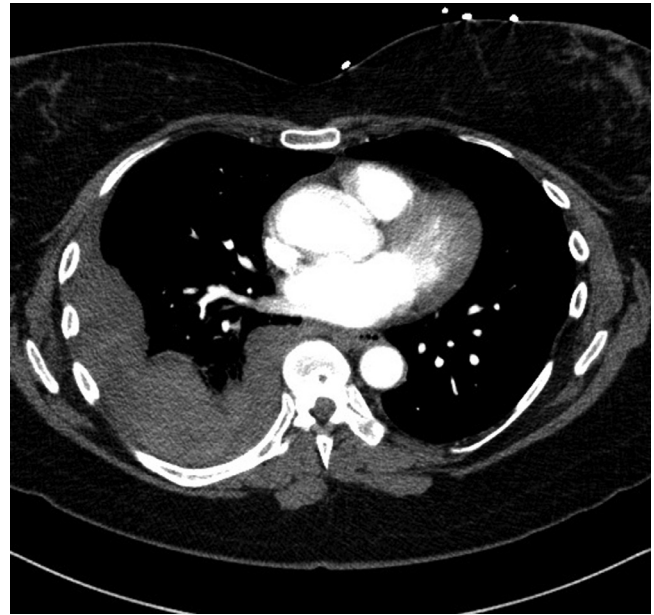


Fig. 1 – Axial contrast-enhanced CT of the chest (2 mm slice thickness, 100 mL IV Omnipaque 300): Mixed-density, loculated right pleural effusion consistent with a hemothorax.

Discussion

Extra-pelvic endometriosis is rare, but often occurs concurrently with pelvic manifestations of this disease [1]. The most common site of extra-pelvic endometriosis is the thorax [2]. The etiology of thoracic endometriosis is uncertain, but two main hypotheses include lymphatic/vascular spread of pelvic endometriosis to the chest cavity (micro-embolization theory) and direct transit from the peritoneum to the pleura through diaphragmatic fenestrations (peritoneal-pleural migration theory) [3–5]. Thoracic endometriosis most frequently presents as pneumothorax (73%), followed by hemothorax (14%), hemoptysis (7%), and pulmonary nodules (6%) [4]. For unclear reasons, thoracic endometriosis involves the right hemithorax in the vast majority of cases [6].

Hemothorax, as seen in our case, has a broad differential diagnosis. More common etiologies such as tuberculosis, pulmonary embolism, vascular pathology (ruptured arteriovenous malformation or abdominal aortic aneurysm), malignancy, trauma, and coagulopathy should first be excluded [7,8]. Diagnosis of thoracic endometriosis requires high clinical suspicion and careful correlation of symptoms with the patient's menstrual cycle. According to a review by Rousset et al., the average interval between symptom onset and diagnosis of thoracic endometriosis ranges from 8 to 19 months, highlighting the difficulty of correctly diagnosing this often-overlooked entity [9]. If guided by clinical history toward thoracic endometriosis, the diagnosis is supported by imaging and pathology findings.

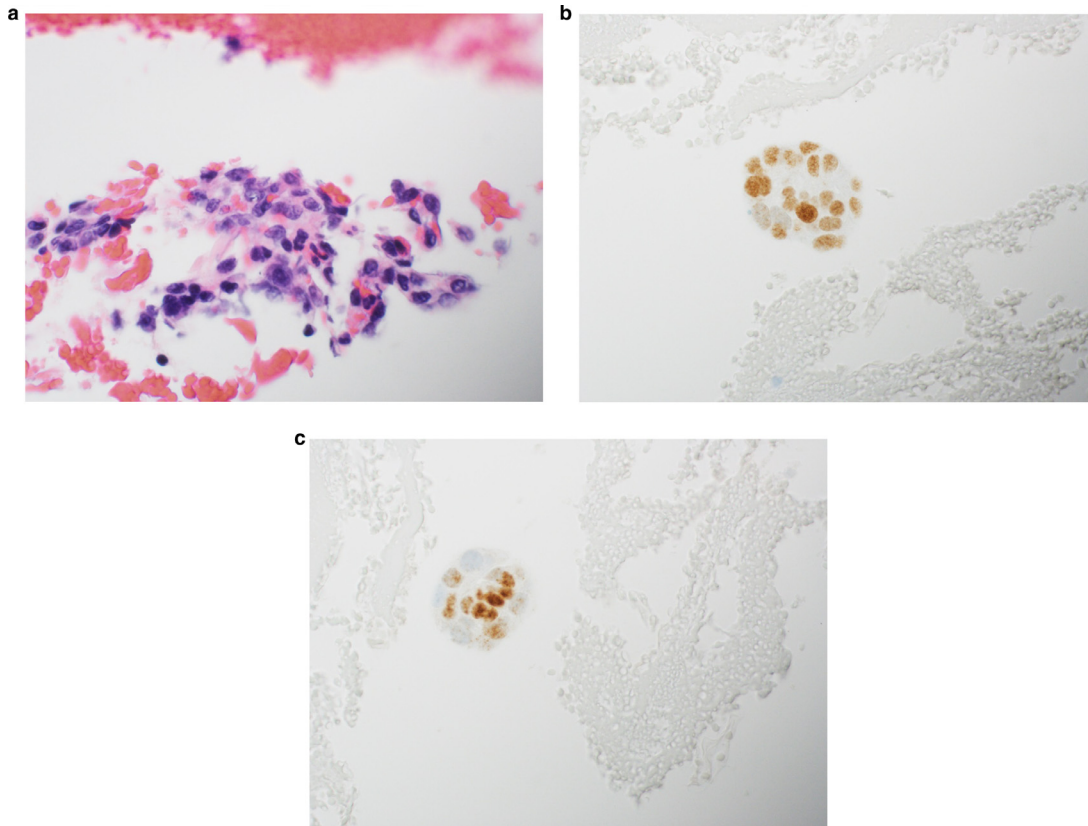


Fig. 2 – All photomicrographs at 60x magnification. (A) Hematoxylin and eosin stain with endometrial cells and stromal cells in pleural fluid. (B) Endometrial glandular cells in pleural fluid exhibiting PAX8 positivity. (C) Endometrial stromal cells in pleural fluid exhibiting WT-1 positivity.

Imaging findings in thoracic endometriosis fluctuate with the menstrual cycle and lack specificity. Compatible chest radiograph findings include unilateral right-sided pathology, with possible effusion, pneumothorax, or hemopneumothorax [6]. Chest CT may reveal hypo- or isoattenuating diaphragmatic endometrial implants, almost exclusively occurring on the right side [6]. Screening of the posterosuperior diaphragm in particular is recommended, as endometrial implants have a propensity to deposit in this location [9]. CT sensitivity for detection of diaphragmatic implants is improved by administration of intravenous contrast [9]. Thin CT slice thickness (1–1.5 mm) and high quality multiplanar reformats are helpful for detecting small lesions and characterizing the spatial relationship to the diaphragm and pleura. Other CT findings include focal pleural thickening, bullae/cyst formation, ground-glass opacities or consolidation suggesting hemorrhage, and peripherally distributed parenchymal nodules which may vary in size based on the menstrual cycle [6,9,10]. In contrast to pleural endometrial disease, parenchymal nodules in thoracic endometriosis are more often bilateral [4]. MR possesses excellent contrast resolution and is helpful in detecting blood products. Pleural and diaphragmatic implants may manifest as T1-hyperintense cystic lesions, reflecting their hemorrhagic components, and will also appear hyperintense on T2-weighted sequences [9,10]. Pleural effusions can demonstrate mixed or heterogeneous sig-

nal when sufficient blood products are present. In general, imaging should exclude other potential etiologies and appropriately guide the differential diagnosis towards thoracic endometriosis.

Identification of hormone receptor-positive endometrial glands and stroma on pathologic evaluation helps cement the diagnosis of thoracic endometriosis. Fluid/blood collected from the pleural space can be submitted for cytologic examination (Fig. 2). Immunohistochemical staining for estrogen receptor and progesterone receptor is observed in both endometrial epithelial and stromal components. Other markers, such as PAX8 can highlight the endometrial glandular cells (Fig. 2B), while CD10 and WT-1 can be used to highlight endometrial stromal cells (Fig. 2C) [11–13]. Identification of intact glands and stroma with hormone receptors can be challenging in practice, as diagnostic yield decreases approximately 48 hours after menstruation due to degradation and autolysis of the proliferative tissues. In our case, the initial chest tube aspirate demonstrated endometrial glands and stroma; however, sampling from a subsequent VATS, which occurred about a week later, did not demonstrate grossly visible endometrial implants. This highlights the variability in diagnostic yield depending on timing with regard to menstruation.

Our patient was started on hormonal suppression as presumptive therapy for thoracic endometriosis. Hormone suppression is a mainstay of treatment, generally recom-

mended for 6-12 months, and includes agents such as gonadotropin-releasing hormone agonists and antagonists, oral contraceptives, progestins, danazol, and aromatase inhibitors [1]. Surgery is considered in patients with refractory or recurrent disease. Localized surgical approaches, such as VATS or video laparoscopy may be considered for implants while definitive surgical therapy is hysterectomy and bilateral salpingo-oophorectomy [1,7].

This case demonstrates the importance of integrating clinical history, imaging, and pathology in arriving at the diagnosis of thoracic endometriosis. Further, it illustrates a few potential diagnostic pitfalls, specifically the inconsistency in diagnostic yield of VATS/thoracentesis and the variable temporal association of patients' symptoms and pathology with menstruation. Timing the effects associated with menstruation is even more challenging in patients with prior hysterectomy, as was noted in this case. Although thoracic endometriosis syndrome occurs infrequently, having an awareness of this entity can help prevent delay in diagnosis, allow timely institution of therapy, and possibly avoid future complications.

REFERENCES

- [1] Nezhat C, Lindheim SR, Backhus L, Vu M, Vang N, Nezhat A, Nezhat C. Thoracic endometriosis syndrome: a review of diagnosis and management. *JLS* 2019;23(3) pii: e2019.00029. doi:10.4293/JLS.2019.00029.
- [2] Bagan P, Berna P, Assouad J, Hupertan V, Le Pimpec Barthes F, Riquet M. Value of cancer antigen 125 for diagnosis of pleural endometriosis in females with recurrent pneumothorax. *Eur Respir J* 2008;31(1):140–2.
- [3] Alifano M, Trisolini R, Cancellieri A, Regnard JF. Thoracic endometriosis: current knowledge. *Ann Thorac Surg* 2006;81(2):761–9.
- [4] Joseph J, Sahn SA. Thoracic endometriosis syndrome: new observations from an analysis of 110 cases. *Am J Med* 1996;100(2):164–70.
- [5] Azizad-Pinto P, Clarke D. Thoracic endometriosis syndrome: case report and review of the literature. *Perm J* 2014;18(3):61–5.
- [6] Woodward PJ, Sohaey R, Mezzetti TP Jr. Endometriosis: radiologic-pathologic correlation. *Radiographics* 2001;21(1):193–216.
- [7] Lee HT, Wang HC, laT Huang, Chang HC, Lu JY. Endometriosis associated with hemothorax. *J Chin Med Assoc* 2006;69(1):42–6.
- [8] Janik M, Straka L, Krajcovic Hejna P, Hamzik J, Novomesky F. Non-traumatic and spontaneous hemothorax in the setting of forensic medical examination: a systematic literature survey. *Forensic Sci Int* 2014;236:22–9.
- [9] Rousset P, Rousset-Jablonski C, Alifano M, Mansuet-Lupo A, Buy JN, Revel MP. Thoracic endometriosis syndrome: CT and MRI features. *Clin Radiol* 2014;69(3):323–30.
- [10] Rankratjevaite L, Samiatina-Morkuniene D. A case report of thoracic endometriosis – A rare cause of haemothorax. *Int J Surg Case Rep* 2017;33:139–42.
- [11] Haga T, Kumasaka T, Kurihara M, Kataoka H, Miura M. Immunohistochemical analysis of thoracic endometriosis. *Pathol Int* 2013;63(9):429–34.
- [12] Arakawa T, Fukuda S, Hirata T, Neriishi K, Wang Y, Takeuchi A, et al. PAX8: A Highly Sensitive Marker for the Glands in Extragenital Endometriosis. *Reprod Sci* 2019. doi:10.1177/1933719119828095.
- [13] Makrigiannakis A, Coukos G, Mantani A, Prokopakis P, Trew G, Margara R, et al. Expression of Wilms' tumor suppressor gene (WT1) in human endometrium: regulation through decidual differentiation. *J Clin Endocrinol Metab* 2001;86(12):5964–72.