

Case Report

Polymorphous light eruption: a common skin disease uncommonly recognized in the Hispanic population

Robert Lew¹ and Jason Jacob^{2,*}¹University of Connecticut Medical Center, Farmington, CT, USA and ²Hartford Hospital, Hartford, CT, USA*Correspondence address. 80 Seymour Street, Hartford, CT 06102, USA. Tel: +1-8609722876;
Fax: +1-8609725057; E-mail: jason.jacob@hhchealth.org

Received 29 August 2014; revised 29 September 2014; accepted 27 October 2014

Polymorphous light eruption (PMLE) is a common acquired disease entity belonging to the idiopathic photodermatoses that is uncommonly considered in the Hispanic population. The pathogenesis of the disease and the mechanism of adaptation in skin (hardening phenomenon) have yet to be elucidated. PMLE is characterized by recurrent abnormal delayed reactions to sunlight ranging from pruritic erythematous papules, papulovesicles and plaques to erythema multiforme. It commonly occurs in the spring or early summer with a predilection for females. A Pubmed review of the literature shows no case reports or literature regarding PMLE in Hispanics. To the best of our knowledge, we report the first case of a 41-year-old Hispanic female diagnosed with PMLE. A high index of suspicion must remain in this group. Additional studies reviewing epidemiology in this group and detailing similar cases may be suggested.

INTRODUCTION

Polymorphous light eruption (PMLE) is a common acquired disease entity belonging to the idiopathic photodermatoses. PMLE affects ~10–15% of the US population [1], but this number may be higher due to underreporting or patients not seeking medical attention. A Pubmed review reveals, to the best of our knowledge, the first case of a 41-year-old Hispanic female diagnosed with PMLE.

CASE REPORT

We present a case of a 41-year-old Hispanic female with no significant past medical history who arrived at our emergency department in June with a 3-day history of fatigue, 2-day onset of diffuse arthralgias and rash for 1 day. Her pain was constant and did not decrease with ibuprofen or naproxen. On the day her joint pain started, she received significant sun exposure while driving and spending the entire day at an amusement park. Her joint pains worsened and she noticed the development of a rash in sun-exposed areas involving her upper extremities starting at her forearms and spread proximally to the shoulders. The lower extremities were affected as well around the knees. Ten point reviews of systems were negative except

for chills and a frontal headache. She lived with her boyfriend in a monogamous relationship. She reported no similar symptoms in family members. Except for childhood small pox, she had no history of sexually transmitted infections, was not on chronic medications, no known drug allergies and had a maternal history of diabetes and arthritis. On presentation to the emergency department, her temperature was 98.3°F (36.8°C), heart rate of 74 bpm, blood pressure of 102/58 mm Hg, respiratory rate of 18 and saturating 94% on room air. On examination, she was a middle-aged female in mild distress, lying still secondary to joint pains. Her cranial nerves were intact, with moist mucus membranes and no oral lesions. Cardiovascular, pulmonary and abdominal examinations were unremarkable. Joint edema was noted over both knees, wrists and interphalangeal joints, with associated tenderness to palpation and decreased range of motion secondary to pain. There were multiple indurated pruritic macules and vesicular lesions bilaterally, greater on the left arm, along with newer erythematous papular lesions (Figs 1 and 2).

The palms, soles, chest and back were spared. Differential included varicella, herpes, tick borne diseases and disseminated gonorrhea, and patient was initially placed on airborne and droplet precautions. Patient was started on acyclovir and ceftriaxone with infectious disease input. Her gonorrhea/

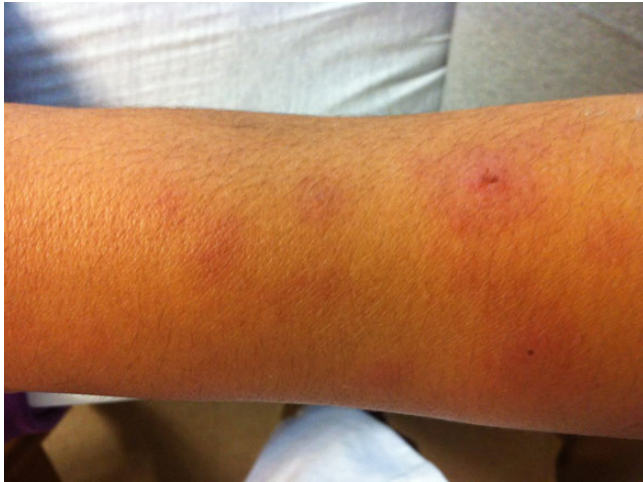

Figure 1: Erythematous clusters of macules and papules on the right arm, small excoriation seen on the top right hand side.

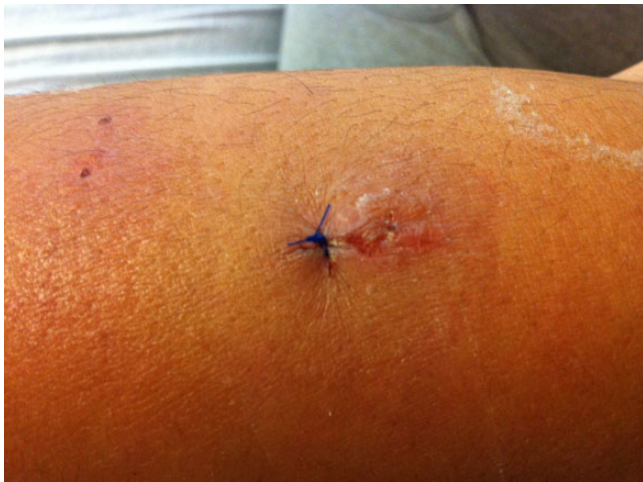

Figure 2: Erythematous papule with scaling and small scab on top from excoriation, suture (blue color) noted where biopsy was taken, and two small macule clusters of erythema seen in the top left corner with small scabs from excoriation.

chlamydia, human immunodeficiency virus (HIV), *Babesia*, blood cultures, *Ehrlichia*, lyme and Coxsackie titers were negative. She had a positive varicella, parvovirus, herpes simplex virus (HSV) 1 and 2 IgG, but negative IgM. Smears done from vesicular fluid were negative for herpes and varicella virus. A biopsy was done with dermatology. Tissue obtained were negative for herpes virus DNA and showed subepidermal edema, spongiosis, rare dyskeratotic keratinocytes and superficial and deep perivascular lymphocytic infiltrates with admixed histiocytes and neutrophils consistent with a PMLE (Figs 3 and 4). There were no sign of vasculitis, fungal elements or prominent mucin to suggest connective tissue disease. Given her abrupt onset of symptoms, a connective tissue disorder was less likely, but a full workup was done with rheumatology input, which revealed negative anti-nuclear antibody, rheumatoid factor, anti-

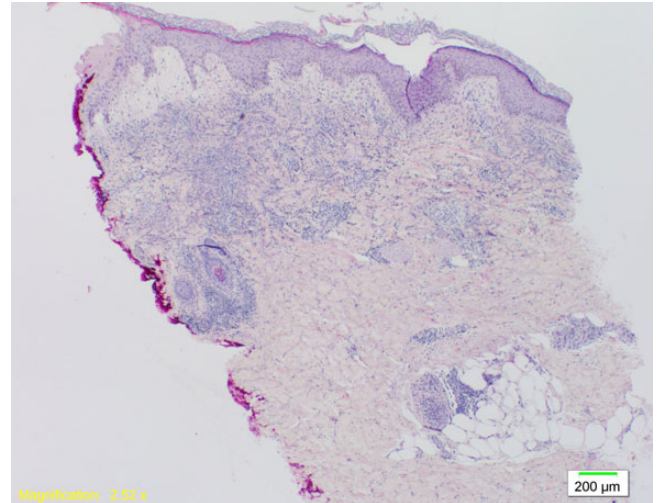


Figure 3: Marked dermal edema with formation of subepidermal cleavage— $\times 2$ (original magnification $\times 20$).

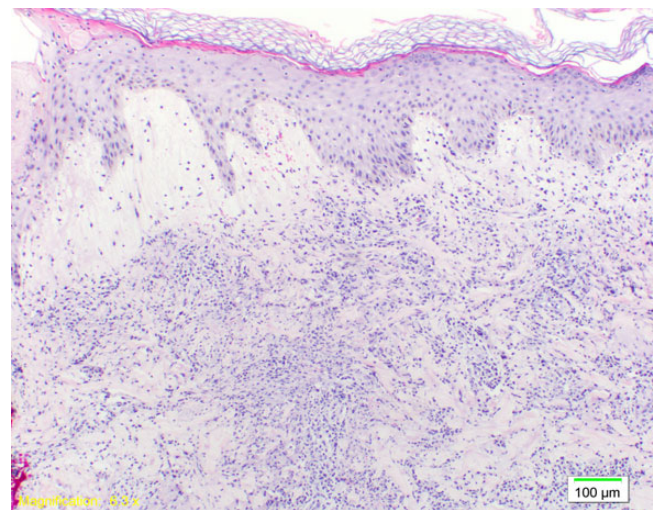


Figure 4: Superficial and mid-dermal perivascular lymphocytic infiltrate with admixed histiocytes and neutrophils with some nuclear fragmentation— $\times 10$ (original magnification $\times 100$).

phospholipid antibody, anti-DS DNA, anti-Smith antibody, anti-ribonucleoprotein antibody and anti-endomysial IgA. Patient had a normal C3, slightly elevated C4 of 46 mg/dl (range 10–40 mg/dl), and elevated IgE 629 kU/l and IgA 625 mg/dl. The patient's symptoms improved the next day with crusting of her lesions, and decreased arthralgias. By Day 4 of hospitalization, joint pains had resolved. She was able to ambulate and was discharged home in the stable condition to complete a 7-day total course of acyclovir 800 mg five times daily and ferrous sulfate for iron deficiency with follow-up.

DISCUSSION

The prevalence of PMLE is higher in females, and there is some evidence that African-Americans are more afflicted

[2, 3]. Reported in 2007, Kerr and Lim [3] identified 280 patients with photodermatoses. 48% were African-Americans, 40% were white and 12% were patients of other races. We consider underreporting may be one of the limitations in finding more cases of PMLE in Hispanics. Wadhvani and Sharma [4] in 2013 noted that the prevalence of PMLE in dark skinned Indian patients is similar to that reported in other parts of the world. A link between erythema multiforme and HSV has been described, but there have been no published reports of HSV as a cause of PMLE [5]. Our patient had a previous exposure to HSV 1 and 2. There have been anecdotal reports of patients with PMLE having resolution of symptoms while taking acyclovir as maybe the case with our patient [5]. This is controversial as a follow-up study by Wackernagel and Zochling [5] failed to show the presence of any HSV DNA in any of the skin biopsies obtained from patients with PMLE. Associations between PMLE have been proposed, specifically with systemic lupus erythematosus and autoimmune diseases; however, there is limited information with infections such as HSV [5, 6]. It is also unclear whether HSV may still be responsible, which further research into the association could elucidate. No HSV DNA was found in the skin biopsies of this patient. Our patient did have arthralgias. This made it more difficult to diagnose PMLE given the atypical presentation. While the histological findings and the paucity of systemic lupus findings favored PMLE, the possibility exists that the joint pains may not be related to PMLE and may have been a separate symptom entity. Subacute cutaneous lupus erythematosus of which arthralgias can occur in 50% of patients and skin lesions are triggered by sunlight was not ruled out [7].

Our limitations in this case report also include that photobiological studies and anti-Ro SSA antibody were not performed. Ongoing research into the immunologic mechanisms, genetic polymorphisms and associations with other autoimmune comorbidities would provide more understanding into this dermatological disease entity. PMLE is not easily recognizable without a targeted history and a high index of suspicion especially in Hispanics.

CONFLICT OF INTEREST STATEMENT

None declared.

REFERENCES

1. Honigsmann H. Polymorphous light eruption. *Photodermatol Photoimmunol Photomed* 2008;**24**:155–61.
2. Honigsmann H, Hojyo-Tomoka MT. *Polymorphous Light Eruption, Hydroa Vacciniforme, and Actinic Prurigo*. *Photodermatology*. New York: Informa Healthcare USA, Inc., 2007, 149–68.
3. Kerr HA, Lim HW. Photodermatoses in African Americans: a retrospective analysis of 135 patients over a 7-year period. *J Am Acad Dermatol* 2007;**57**:638–43.
4. Wadhvani AR, Sharma VK. A clinical study of the spectrum of photodermatoses in dark-skinned populations. *Clin Exp Dermatol* 2013;**38**:823–29.
5. Wackernagel A, Zochling N. Presence of herpes simplex virus DNA in erythema multiforme but not polymorphic light eruption. *Br J Dermatol* 2006;**155**:1084–85.
6. Gronhagen CM, Gunnarsson I. Cutaneous manifestations and serological findings in 260 patients with systemic lupus erythematosus. *Lupus* 2010;**19**:1187–94.
7. O’Gorman SM, Murphy GM. Photoaggravated disorders. *Dermatol Clin* 2014;**32**:385–98.