



Case report

Well-promising outcomes with vacuum-assisted closure in an infected wound following laparotomy: A case report



A. Daskalaki ^a, S. Xenaki ^a, M. Venianaki ^a, A. Topalidou ^{b, *}, E. Athanasakis ^a, E. Chrysos ^{a, b}, G. Chalkiadakis ^{a, b}

^a Department of General Surgery, University Hospital of Heraklion, Crete-Greece

^b Faculty of Medicine, University of Crete, Greece

HIGHLIGHTS

- A VAC device with automated solution distribution (with saline solution plus hypertonic saline), continuous pressure of –125 mmHg with equal distribution was applied.
- Within 4 days bacterial culture was negative.
- On the 7th day the wound was half in diameter and depth.
- After 15 days in total, therapy was discontinued achieving closure.

ARTICLE INFO

Article history:

Received 20 June 2016

Received in revised form

30 July 2016

Accepted 31 July 2016

Keywords:

Vacuum-assisted closure

Negative pressure

Laparotomy

Incisional hernia

Case report

ABSTRACT

Introduction: Negative pressure wound therapy (NPWT) represents an alternative method to optimize conditions for wound healing. Delayed wound closure is a significant health problem, which is directly associated with pain and suffering from patient's aspect, as well with social and financial burden.

Presentation of case: We report a case of vacuum-assisted wound therapy with hypertonic solution distillation and continuous negative pressure application, in an infected wound after laparotomy for incisional hernia reconstruction with mesh placement. Negative pressure was initiated at the wound margins after failure of conventional treatment with great outcomes, achieving a total closure of the incision within two weeks.

Discussion: Each wound has particular characteristics which must be managed. Vacuum assisted closure (VAC) with continuous negative pressure and simultaneous wound instillation and cleanse can provide optimum results, reducing the cavity volume, by newly produced granulated tissue.

Conclusion: The simultaneous use of instillation and constant pressure seemed to be superior in comparison with NPWT alone. Compared to conventional methods, the use of VAC ends to better outcomes, in cases of infected wounds following laparotomy.

© 2016 The Authors. Published by Elsevier Ltd on behalf of IJS Publishing Group Ltd. This is an open access article under the CC BY-NC-ND license (<http://creativecommons.org/licenses/by-nc-nd/4.0/>).

Abbreviations: NPWT, Negative Pressure Wound Therapy; VAC, Vacuum Assisted Closure; MDWT, Microdeformational Wound Therapy; TNP, Topical Negative Pressure therapy; SWT, Subatmospheric Wound Therapy; PVA, Polyvinyl Alcohol PVA; GFS, GranuFoam Silver.

* Corresponding author. University of Crete, Faculty of Medicine, University Hospital of Heraklion, Crete, Greece.

E-mail addresses: daskalaki.a@hotmail.com (A. Daskalaki), sofiabecks@yahoo.gr (S. Xenaki), mb12.med@gmail.com (M. Venianaki), atopalidou@gmail.com (A. Topalidou), eliasathanasakis@yahoo.gr (E. Athanasakis), manolischrysos@gmail.com (E. Chrysos), chalk@med.uoc.gr (G. Chalkiadakis).

<http://dx.doi.org/10.1016/j.amsu.2016.07.027>

2049-0801/© 2016 The Authors. Published by Elsevier Ltd on behalf of IJS Publishing Group Ltd. This is an open access article under the CC BY-NC-ND license (<http://creativecommons.org/licenses/by-nc-nd/4.0/>).

1. Introduction

Surgical wound complications constitute a common problem for both surgeon and patient. There is a broad spectrum of complication severity, ranging from medically unimportant but certainly attention-demanding, to life threatening situations. The most common postoperative wound impairments are seroma, haematoma, necrosis of wound margins and infections. Most of them improve with conservative measures, like daily thorough cleansing of the wound margins and targeted antibiotic therapy [1]. Negative pressure wound therapy (NPWT) is used to promote wound healing in a wide range of difficult to manage acute and chronic wounds [2].

Apart from open abdomen though, there are limited reported publications concerning the vacuum assisted closure (VAC) outcomes, in an impaired wound following scheduled laparotomy for a routine surgical issue, like incisional hernia repair with mesh placement.

2. Presentation of case

We report a case of a 46 year-old woman who was referred to our department for incisional hernia reconstruction. The patient underwent two laparotomies previously, one for left oophorectomy due to an ovarian cyst four years ago and a second one, three months later for complete hysterectomy and right oophorectomy due to cancer that was diagnosed at the first operation. Plastic reconstruction was performed using a 25 × 25cm double layer polypropylene mesh was used. It was placed subcutaneously and was stabilized on the transverse fascia using metallic fascia clips. Before placing the mesh no component separation was conducted. Abdominal pressure was released. The gap was stitched and flaps in diameter of 10cm circumferentially where created so that the mesh could be placed.

A drain tube was placed intraperitoneal to the right Douglas space and two more drains under negative pressure were placed subcutaneous over the mesh. The first subcutaneous drain was removed on the 3rd and the second one on the 10th postoperative day, draining less than 40 cc serous liquid/24h each [3]. Five days after discharge she was hospitalized again due to an obvious inflammation of the subumbilical part of the incision. The wound was re-opened and about 500 cc of serous liquid was drained out of a broad cavity between mesh and adipose tissue. Liquid cultures revealed *S. epidermidis* and *E. faecium*. Targeted double antibiotic coverage was started immediately following the antibiogram results.

Initially, manual drainage of the seroma and careful wound cleansing was performed twice daily. A simple VAC therapy was initiated at postoperative day 25. Based on the directives a standard dressing was put and remained for 10 continuous days without change. The device was working with non-constant pressure, up to –80 mmHg. The dressing was then removed for 24h, new cultures were sent and it was formed back again until discharge, 25 days in total, with two intermediate dressing changes and repositions. The culture result revealed *S. epidermidis* alone. Prolonged hospital stay caused excessive stress to our patient, who insisted in getting a discharge for a few days. After non satisfactory outcomes, a mini council of the patient's surgeon and other surgeon's of the clinic was conducted, who decided to change strategy of management and proceed to a new VAC application. She was let go with alginate antimicrobial silver pad (Silvercel-by Systagenix) combined with hydrolymer adhesive foam dressing (Tielle Plus-by Systagenix an Acelyty company, San Antonio, TX, USA), with the advice to be changed every 24 hours and return in a week.

Seven days later the patient was re-hospitalized and a negative pressure device -VAC Ultra- (KCI, an Acelyty company, San Antonio, TX, USA) with automated solution distribution and removal was applied. In order to optimize the installation therapy, to distribute negative pressure evenly and to achieve even distribution and removal of topical wound solution across the wound, a special VAC VeraFlo Dressing (KCI, an Acelyty company, San Antonio, TX, USA) was used. Aiming at the best result, the spiral foam dressing was inserted into the wound with such pressure that its pores could remain free enough. Moreover, a skin protecting drape was placed around the wound edges in order to exert the pressure directly to the subcutaneous wound area and reduce tension on the wound edges on the one hand and secondarily to avoid contact and irritation. At each cycle, saline solution plus hypertonic saline (500 ml

NaCl 0,9%: 75 meq NaCl) was instilled at a soak time of 5 minutes and therapy time of 8 hours on a continuous pressure of –125 mmHg. First dressing change performed after 4 days. New bacterial culture was ordered, which resulted negative. On the seventh day the second dressing change was performed. The wound was already half in diameter and depth (Fig. 1). After 15 days in total, therapy was discontinued achieving closure (Table 1). By discharge, the cavity had been closed, the wound had been healed almost completely and no signs of wound inflammation were apparent.

3. Discussion

NPWT, or else known among others as VAC, microdeformational wound therapy (MDWT), topical negative pressure therapy (TNP), subatmospheric wound therapy (SWT) [4] consists a new weapon in management of demanding wound problems that require more than conventional, conservative treatment. The whole VAC system could be analyzed in three main components: a type of sponge that fits the wound size, an adherent dressing, put as an airtight seal over the wound and a device that provides negative pressure to the wound bed and dressing. Special attention should be given to certain parameters such as the pressure power, the sponge type, the use of instillation, the solution used, the structure-geometry of the wound and the frequency of dressing changes.

Referring to the negative pressure, although reported values in the literature range from –75 mmHg to –125 mmHg, it is strongly believed that in cases of highly infected exudates, a pressure of –125 mmHg is most effective [5–7]. In a study with seawater-immersed wound healing in experimental animal models – 180 mmHg pressure seems to be optimal [8]. Generally, the maximum pressure that does not cause pain or discomfort to the patient is the desired and the most effective. Moreover, constant pressure appears to be superior to intermediate [1,5,7].

Regarding the dressing changes most researchers recommend changes every 2 or 4 days [7–9]. The most common material used

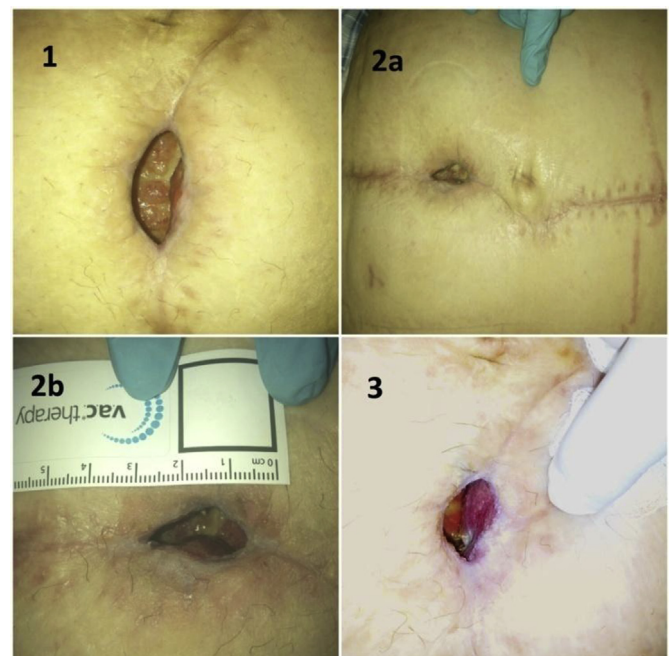


Fig. 1. 1) Wound just before VAC application, 2a-b) Seventh day, significant reduction of wound cavity, 3) After 13 days, the granulation tissue is evident.

Table 1
VAC therapy calendar.

Action	Day	Result
V.A.C. VeraFlo application	1st day	
1st dressing change	4th day	Negative bacterial culture (1st)
2nd dressing change	7th day	Wound: half diameter and depth
3rd dressing change	10th day	Negative bacterial culture (2nd)
4th dressing change	13th day	Preparation for closure
Therapy discontinued	15th day	Closure

for sponge formation is polyurethane, an hydrophobic reticulated foam, with tiny pores that creates thousands of suction cups on the wound surface when vacuum is applied [10]. Polyvinyl Alcohol (PVA) foam and GranuFoam Silver (GFS) are other, less used sponge materials. The type of sponge and the use of instillation are directly related to the type of the wound, its localization, and the level of exudate. Of these parameters, the use of instillation significantly predominates. Yusuf E et al. [11] claim that bacterial load remains high in NPWT sponges, and routine changing does not reduce the load. Therefore, the significance of the instillation is evident. Depending on the culture results, the recommended solutions are: Hypochloride based solutions (e.g. Hypochlorous acid, Sodium hypochloride), silver nitrate (0,5%), sulfur-based solutions (sulfonamides), biguanides (Polyhexanide), acetic acid, cationic solutions (Octenidine, Benzalkonium Chloride) and isotonic solutions [12–14]. Finally, the geometry of the wound and the included tissues are playing an important role in the way that the foam will be instilled, succeeding optimum result without incurring the flanking regions.

Detailed analysis of negative pressure micro-wound-effects is far from the objectives of current publication. Ultimate goal is the shrinkage of the wound surface and reduction of the cavity volume, by newly produced granulation tissue [15]. Vacuum system results in the removal of wound exudates, which takes along infectious materials, reducing the local bioburdain. This results an infection reduction and local microvasculature constriction, achieving a healing-friendly environment. If not adequately closed with the method, the wound bed can reach an appropriate status, to be further managed surgically or reconstructed with a graft or flap [16].

The case presented is one of confined number of published cases concerning an impaired surgical wound treated with the VAC system, in general surgery field [1]. However, each wound is unique and should be treated on an individual base, with respect to its particularities. Our patient was treated at first with suture removal, manual drainage of the seroma, thorough cleansing of the wound margins and dressing changes twice a day, according to the practice guidelines for the management of surgical site infections [17]. Targeted antibiotic coverage, based on antibiogramm was initiated from the beginning. After no significant improvement an improvised vacuum system was applied to the wound for 25 more days in total, with non-constant/non-continous pressure up to -80 mmHg and one intermediate dressing change. Culture results showed decrease in bacterial load and macroscopically the cavity was smaller, but still with no great results. This led to the application of a superior VAC device with the ability of continuous negative pressure (-125 mmHg) and simultaneous wound instillation and cleanse with the appropriate for the wound solution. Moreover, the special sensors of the new device secured equal distribution of pressure to the surgical wound through the sponge, achieving optimum results. However, surgeons must be aware of the contraindications (malignancy in the wound, untreated coagulopathy and osteomyelitis, sepsis, fistulae to organs or body cavities, presence of necrotic tissue, exposed organs and vessels to the area) and the

possible complications (bleeding, pain and discomfort, foam retention within the wound and tissue adherence). Both pain and bleeding can be avoided by reducing the pressure level [2,5,7,14,15].

Responsible wound management requires both clinical and economic considerations. It is in fact difficult to evaluate the exact cost, as far as routine, intra-hospital wound care is concerned. Wound dressings, nursing time, cultures and other relative exam tests, hospitalization and adverse events (infections, reoperations) cannot be strictly measured and translated to a certain amount of money. In addition, patient's duration of hospital stay reflects a social productivity loss and a significant insurance burden. On the other hand, topical negative pressure therapy is considered an expensive intervention, due to the higher cost of supplies used. Several studies [18–20] tried to compare the cost-effectiveness of conventional versus TNP method of wound healing. NPWT has been shown to reduce cost through a combination of improved outcomes (faster healing, avoidance of reoperation), which impacts in less hospital stay and limited use of nursing time. However, the number of relevant publications, as well as the total number of patients treated with the VAC system is limited enough to extract safe conclusions. Additional research should focus on the clinical outcomes of TNP treatment, its economic impact and patient's quality of life.

4. Conclusions

NPWT, in combination with hypertonic saline solution instillation is used to promote wound healing. The vacuum technique however should not be considered a standard of care in every infected wound. Its application should be considered in an individual base. The simultaneous use of instillation and constant pressure seemed to be superior in comparison with NPWT alone. Compared to conventional methods, the use of VAC ends to better outcomes, both cosmetic and functional, especially in infected wounds, with significant reduction of hospital stay and its impact to the national insurance system. Nevertheless, there are a small number of prospective randomized studies at the time and the method's clinical efficacy needs to be proven.

Ethical approval

There was no ethics approval required for this case report. Written informed consent was obtained from the patient for publication of this case report and accompanying images.

Sources of funding

We certify that no funding has been received for the conduct of this study and/or preparation of this manuscript.

Author contribution

DA contributed to initial draft and interpretation of data and was engaged in patient's care in his hospital coarse including surgery under the supervision of CE and CG. CE also reviewed the final manuscript. XS and VM helped with data collection, interpretation and writing of the paper. TA contributed to study concept/design, interpretation, review of manuscript and its final submission. AE was engaged in patient's care after the surgery. CG reviewed the final manuscript. All authors have read and approved this manuscript for publication.

Conflicts of interest

The authors declare that there are no conflicts of interest.

Guarantor

George Chalkiadakis.

Acknowledgements

We certify that no funding has been received for the conduct of this study and/or preparation of this manuscript.

References

- [1] R.E. Horch, Incisional negative pressure wound therapy for high-risk wounds, *J. Wound Care* 24 (4 Suppl) (2015) 21–28.
- [2] K.V. Lambert, P. Hayes, M. McCarthy, Vacuum assisted closure: a review of development and current applications, *Eur. J. Vasc. Endovasc. Surg.* 29 (3) (2005) 219–226.
- [3] E.B. Deerenberg, L. Timmermans, D.P. Hogerzeil, et al., A systematic review of the surgical treatment of large incisional hernia, *Hernia* 19 (1) (2015) 89–101.
- [4] P.E. Banwell, L. Teot, Topical negative pressure (TNP): the evolution of a novel wound therapy, *J. Wound Care* 12 (1) (2003) 22–28.
- [5] L.P. Kamolz, D.B. Lumenta, D. Parvizi, et al., Skin graft fixation in severe burns: use of topical negative pressure, *Ann. Burns Fire Disasters* 27 (3) (2014) 141–145.
- [6] M.J. Listewnik, P. Sielicki, K. Mokrzycki, et al., The use of Vacuum-Assisted Closure in purulent complications and difficult-to-heal wounds in cardiac surgery, *Adv. Clin. Exp. Med.* 24 (4) (2015) 643–650.
- [7] A.S. Patmo, P. Krijnen, W.E. Tuinebreijer, R.S. Breederveld, The effect of vacuum-assisted closure on the bacterial load and type of bacteria: a systematic review, *Adv. Wound Care (New Rochelle)* 3 (5) (2014) 383–389.
- [8] L. Cao, M.M. Peng, J.J. Sun, X.C. Yu, B. Shi, Application of vacuum-assisted closure in seawater-immersed wound treatment under different negative pressures, *Genet. Mol. Res.* 14 (2) (2015) 6146–6155.
- [9] C. Huang, T. Leavitt, L.R. Bayer, D.P. Orgill, Effect of negative pressure wound therapy on wound healing, *Curr. Probl. Surg.* 51 (7) (2014) 301–331.
- [10] E.W. Kubek, A. Badeau, S. Materazzi, et al., Negative-pressure wound therapy and the emerging role of incisional negative pressure wound therapy as prophylaxis against surgical site infections. Microbial pathogens and strategies for combating them: science, technology and education, *FORMATEX* (2013) 1833–1846.
- [11] E. Yusuf, X. Jordan, M. Clauss, et al., High bacterial load in negative pressure wound therapy (NPWT) foams used in the treatment of chronic wounds, *Wound Repair Regen.* 21 (5) (2013) 677–681.
- [12] W. Raad, J.C. Lantis, L. Tyrie, et al., Vacuum-assisted closure instill as a method of sterilizing massive venous stasis wounds prior to split thickness skin graft placement, *Int. Wound J.* 7 (2) (2010) 81–85.
- [13] T. Wolvos, The evaluation of combined negative pressure wound therapy and negative pressure wound therapy with instillation system for the treatment of difficult to heal wounds: an initial experience, in: *Clinical Symposium on Advances in Skin and Wound Care*, 2011, pp. 9–12.
- [14] A. Gabriel, J. Shores, C. Heinrich, et al., Negative pressure wound therapy with instillation: a pilot study describing a new method for treating infected wounds, *Int. Wound J.* 5 (3) (2008) 399–413.
- [15] D. Bolero, B. Driver, P. Glat, et al., The role of negative pressure wound therapy in the spectrum of wound healing. A guidelines document, *Ostomy Wound Manage* 56 (5 suppl) (2010) 1–18.
- [16] A.J. DeFranzo, K. Pitzer, J.A. Molnar, et al., Vacuum-assisted closure for defects of the abdominal wall, *Plast. Reconstr. Surg.* 121 (3) (2008) 832–839.
- [17] D.L. Stevens, A.L. Bisno, H.F. Chambers, et al., Practice guidelines for the diagnosis and management of skin and soft tissue infections: 2014 update by the infectious diseases society of America, *Clin. Infect. Dis.* 59 (2) (2014) e10–e52.
- [18] H. Birke-Sorensen, M. Malmso, P. Rome, et al., Evidence-based recommendations for negative pressure wound therapy: treatment variables (pressure levels, wound filler and contact layer)-steps towards an international consensus, *J. Plast. Reconstr. Aesthet. Surg.* 64 (Suppl:S1–16) (2011).
- [19] A. Braakenburg, M.C. Obdeijn, R. Feitz, et al., The clinical efficacy and cost effectiveness of the vacuum-assisted closure technique in the management of acute and chronic wounds: a randomized controlled trial, *Plast. Reconstr. Surg.* 118 (2) (2006) 390–397.
- [20] L.S. Lewis, P.A. Convery, C.S. Bolac, et al., Cost of care using prophylactic negative pressure wound vacuum on closed laparotomy incisions, *Gynecol. Oncol.* 132 (3) (2014) 684–689.