

CASE REPORT

Open Access



Decidualized ovarian endometrioma mimicking malignancy in pregnancy: a case report and literature review

Min Yin^{1,2}, Tao Wang^{1,2}, Sijian Li^{1,2}, Xinyue Zhang^{1,2} and Jiaxin Yang^{1,2*}

Abstract

Background: Ovarian endometrioma is a common gynecologic disease among reproductive-aged women. Pregnancy-related hormonal status may lead to changes of decidualization, which may resemble ovarian malignancies in sonographic appearance. Here we present a case of decidualized ovarian endometrioma clinically mimicking malignant transformation.

Case presentation: A 37-year-old pregnant woman presented to our hospital at 25 + 5 weeks of gestation with a persistent left adnexal mass that was first detected on routine ultrasound in the first trimester. Transvaginal and transabdominal ultrasound showed a cystic mass of size 8.4 × 5.8 cm in the left ovary with abundant blood flow signals in the papillary medium echo of the capsule wall and inner wall, raising concern for malignant ovarian tumor. After a multidisciplinary discussion, the patient underwent laparoscopic left salpingo-oophorectomy. The results of the frozen section revealed decidualized endometrioma and the final histopathology confirmed endometrioma with extensive decidualization. The patient's postoperative recovery was uneventful and she was discharged on the 4th postoperative day.

Conclusions: Decidualized ovarian endometrioma is rare. Sonography and magnetic resonance imaging are helpful for differential diagnosis. Conservative management of expectant management and serial monitoring should be adopted if decidualized endometriosis is suspected.

Keywords: Decidualized endometrioma, Pregnancy, Ultrasound, Magnetic resonance imaging

Background

Adnexal mass is the most common indication for gynecologic surgery during pregnancy, occurring in 0.1 to 2.4% of pregnant women [1]. Most adnexal masses discovered in pregnant women are unexpectedly found during routine prenatal ultrasonography. The treatment of an adnexal mass is generally conservative because that most are physiologic or benign tumors. In contrast, surgical intervention is required when the mass is suspicious of

potential malignancy or severe abdominal pain caused by mass rupture and torsion. Endometriosis is the presence of ectopic endometrial glands and stroma outside the confines of the uterine endometrium [2]. Ovarian endometriomas are a common gynecologic disease among reproductive-aged women. Although ovarian endometrioma with typical traits is easily diagnosed under ultrasonography, changes will occur during pregnancy due to great alterations of the hormone. During pregnancy, the ectopic endometrium takes the change of increasing glandular epithelial secretion, stromal vascularity, and edema under progesterone action, which is defined as decidualization [3]. Decidualized endometrioma with increased blood flow and with intraluminal papillary

*Correspondence: yjxpumch@163.com

² National Clinical Research Center for Obstetric & Gynecologic Diseases, Beijing, China

Full list of author information is available at the end of the article



© The Author(s) 2022. **Open Access** This article is licensed under a Creative Commons Attribution 4.0 International License, which permits use, sharing, adaptation, distribution and reproduction in any medium or format, as long as you give appropriate credit to the original author(s) and the source, provide a link to the Creative Commons licence, and indicate if changes were made. The images or other third party material in this article are included in the article's Creative Commons licence, unless indicated otherwise in a credit line to the material. If material is not included in the article's Creative Commons licence and your intended use is not permitted by statutory regulation or exceeds the permitted use, you will need to obtain permission directly from the copyright holder. To view a copy of this licence, visit <http://creativecommons.org/licenses/by/4.0/>. The Creative Commons Public Domain Dedication waiver (<http://creativecommons.org/publicdomain/zero/1.0/>) applies to the data made available in this article, unless otherwise stated in a credit line to the data.

vegetations results in difficulties in the differential diagnosis from the malignant ovarian tumor [4]. Here we present a case whose decidualized ovarian endometrioma clinically mimicked malignant ovarian tumor.

Case presentation

A 37-year-old pregnant woman, gravida 2, para 1, without any systemic disease, was referred to our hospital at 25 + 5 weeks of gestation to evaluate a persistent and growing left adnexal mass found by the first-trimester routine ultrasound. No other obstetric abnormalities were detected in regular antenatal examinations. A left ovarian cyst, 3.4 cm × 2.5 cm, was noted by an ultrasound scan at 7 weeks of gestation. Follow-up sonography showed moderate echogenic protrusions in the ovarian cysts, growing gradually. At the presentation to our hospital, a transvaginal/transabdominal ultrasound was repeated, showing a cystic mass of size 8.4 × 5.8 cm in the left ovary with abundant blood flow signals in the papillary medium echo of the capsule wall and inner wall, which raised concern for malignant ovarian tumor (Fig. 1A and B). Her serum level of CA125 was 44.9 U/mL (normal range, 0–35 U/mL) and CA199 was 41.4 U/mL (normal range, 0–34 U/mL).

After a multidisciplinary discussion with doctors from obstetrics, gynecology oncology, and ultrasound departments, it was considered that the left adnexal mass was likely to be ovarian malignancy. Compare with ovarian cystectomy, salpingo-oophorectomy can effectively reduce the incidence of tumor rupture, therefore avoiding the intraperitoneal dissemination of tumor cells and avoiding the increased clinical stage caused by the operation as much as possible. Based on the above

considerations, laparoscopic left salpingo-oophorectomy was recommended instead of ovarian cystectomy. After fully informed consent, the patient chose to undergo left salpingo-oophorectomy at 26 + 1 weeks of gestation. It was observed that an 8 cm left ovarian multilocular cyst can be seen and the cyst adhered to the left pelvic wall and mesorectum (Fig. 2A). Adhesion lysis was performed and the cyst ruptured during manipulation. Brown cystic content and irregular and rounded internal cyst wall were observed. After left salpingo-oophorectomy, we did careful examination if the specimens: the left ovarian cyst is multilocular, and the inner wall of the cyst is thickened and villous (Fig. 2B). The results of the frozen section showed decidualized ovarian endometriomas, and the final histopathology confirmed endometrioma with extensive decidualization (Fig. 3). The patient’s postoperative recovery was uneventful, and the fetal heart rate was detected before and after surgery to evaluate the fetal status. She was discharged on the 4th postoperative day.

Discussion

Adnexal masses during pregnancy are problematic because of the increased difficulty of surgery and the risk of abortion and preterm birth. The incidence of adnexal masses during pregnancy varied, 11% of which are endometriomas and the reported incidence of ovarian malignancy is only 1% [5]. During pregnancy, normal endometrium will convert into a specialized uterine lining adequate for optimal accommodation of the pregnancy, which is called decidualization. Under the action of progesterone, hypertrophy of the endometrial stromal cells leads to cyst enlargement and irregular and vascular solid components, mimicking

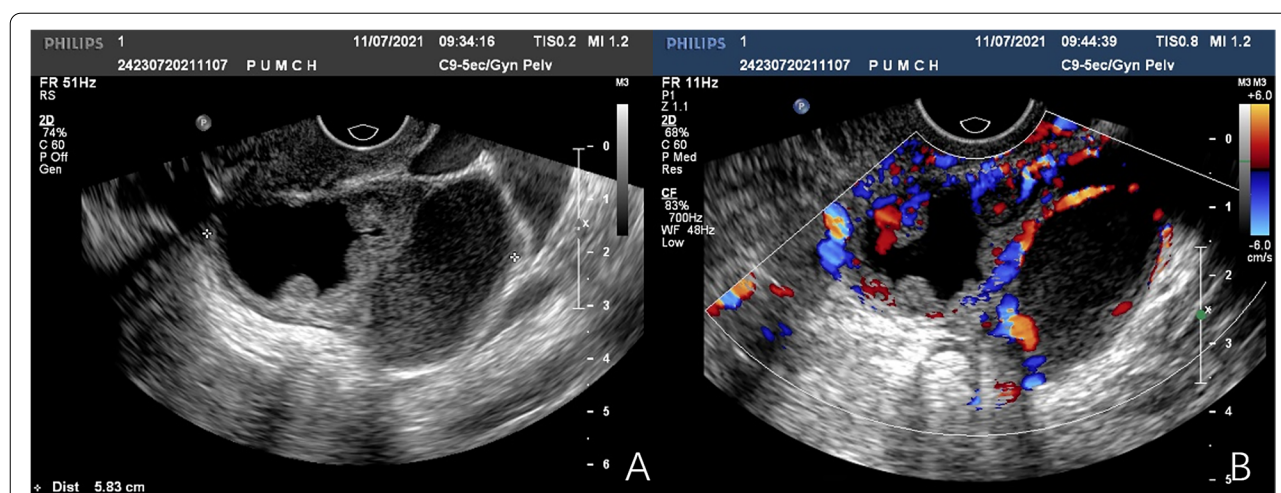
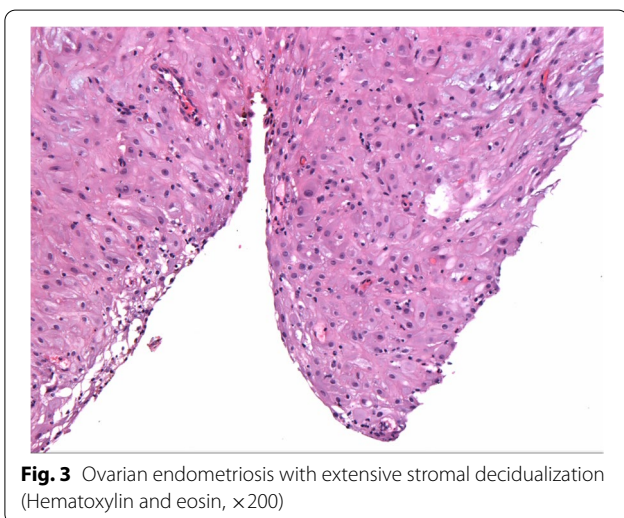
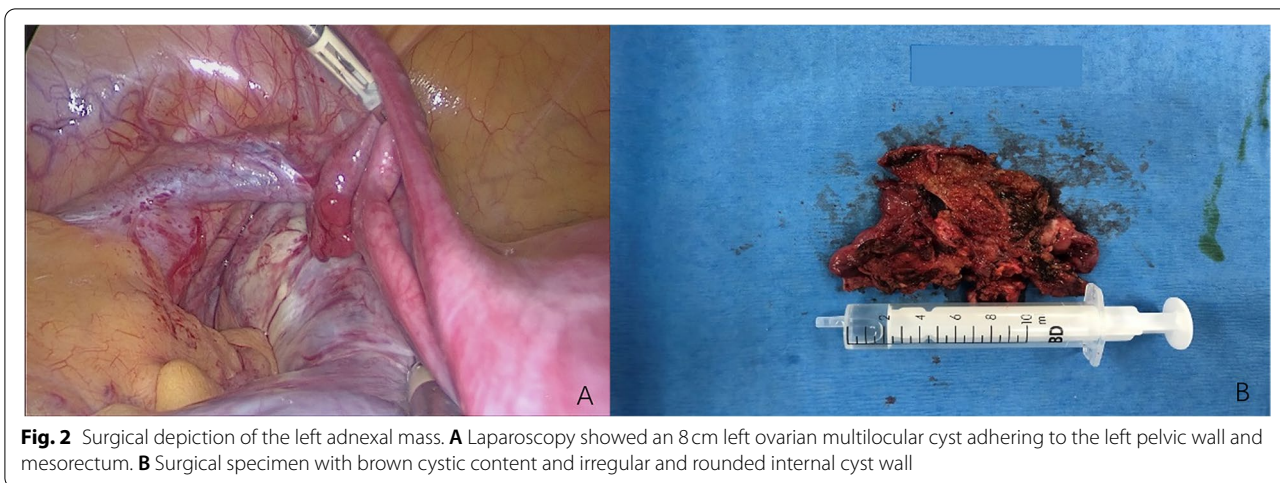


Fig. 1 Transvaginal ultrasound imaging of the left adnexal mass. **A** Transvaginal ultrasound depicting multilocular cyst with thick internal walls and papillary projection protruding into the cavity. **B** Doppler ultrasound depicting vascularity within capsule wall and papillary projections



malignancy on imaging, potentially leading to unnecessary surgical intervention. Decidualized ovarian endometrioma in pregnancy is a rare condition and we only identify 18 studies comprising a total of 61 cases of ovarian decidualized endometriomas during pregnancy after the literature review [3, 4, 6–21]. The main characteristics of the published cases are summarized in Table 1.

Surgeries during pregnancy may be avoided or at least delayed until the term or postpartum period if diagnostic accuracy can be improved. Sonography is regarded as the gold standard imaging method for the diagnosis of ovarian endometriomas in non-pregnant women, with the reported sensitivity and specificity to be 84–100% and 90–100%, respectively [15]. The typical feature of an ovarian endometrioma is a round-shaped

cystic mass with regular margins, homogeneous low echogenic fluid content with scattered internal echoes, and without papillary proliferations. Several case reports have shown the sonographic findings of decidualized endometriomas with septations, nodularity, and marked blood flow, which are similar to those that may be seen in borderline or malignant tumors, posing a challenging diagnostic dilemma. Barbieri M et al. [16] reported three cases with an ovarian endometrioma in pregnancy mimicking malignancy and performed a literature review from 1990 to 2008. They found that rapidly growing and vascularized intracystic excrescences were consistently documented, but septations or significant free fluid was never reported. What’s more, they reported an interesting case suggesting that decidualized endometrioma is a transitory transformation.

Mascilini F et al. [19] retrospectively reviewed 18 women with a histological diagnosis of decidualized endometrioma during pregnancy from seven ultrasound centers. They found that 14 of the 17 decidualized endometriomas manifested vascularized rounded papillary projections with a smooth contour and ground-glass or low-level echogenicity of the cyst fluid when using pattern recognition. Therefore, they suggested expectant management of cysts with papillary projections detected during pregnancy if an endometrioma was diagnosed before pregnancy and manifests the typical signs of decidualized endometrioma. Furthermore, Groszmann Y et al. [20] described the sonographic characteristics of 22 decidualized endometriomas in 17 patients. They used the International Ovarian Tumor Analysis Group definitions for adnexal masses but failed to identify characteristic sonographic features to distinguish decidualized endometrioma from ovarian malignancy. However, they suggested delaying surgery until delivery or postpartum if

Table 1 Summary of reported decidualized ovarian endometrioma cases during pregnancy

Author, reference	Publication year	No. of cases	Age, range	CA125 (U/ml)	Laterality	Size (cm)	Solid part (cm)	Intracystic papillae	Septa	Blood flow	MRI	Surgery GA	Surgical procedure	
Miyakoshi K et al. [6]	1998	1	28	NR	Unilateral	Dmax 8.5	NR	+	-	+	+	20	Oophorectomy	
Tanaka YO et al. [7]	2002	1	27	103	Unilateral	12 × 8 × 7	NR	+	+	NR	+	12	Cystectomy	
Fruscella E et al. [8]	2004	1	39	76	Unilateral	Dmax 5.5	0.8 × 1.0 and 0.5 × 0.5	+	-	+	+	18	Oophorectomy	
Sammour RN et al. [4]	2005	2	36	NR	Unilateral	3.7 × 2.7 × 3.5	1.5 × 2.0 × 2.5	+	-	+	+	15	Oophorectomy	
			28	NR	Unilateral	4.0 × 5.0 × 6.3	2.3 × 1.8 × 1.4	+	-	+	-	16	Oophorectomy	
Guerriero S et al. [9]	2005	1	38	109	Bilateral	4.0 × 4.8	NR	+	-	+	-	37 (CS)	Bilateral Cystectomy	
Iwamoto H et al. [10]	2006	1	31	28.3	Unilateral	Dmax 7.5	NR	+	-	+	+	22	Oophorectomy	
Asch E et al. [11]	2007	1	NR	NR	Unilateral	NR	NR	+	-	+	-	After delivery	Bilateral cystectomy	
Podder L et al. [12]	2008	1	34	24	Unilateral	Dmax 6.2	+	+	-	+	+	38 (CS)	Oophorectomy	
Machida S et al. [13]	2008	3	32	119	Unilateral	8 × 5	NR	+	-	+	+	19	Oophorectomy	
			41	220	Unilateral	Dmax 16	NR	+	+	NR	+	14	Oophorectomy	
Yoshida S et al. [14]	2008	2	24	34	Bilateral	Dmax 5	NR	+	-	NR	+	14	Cystectomy	
			29	NR	Unilateral	8.5 × 5.3	NR	+	-	-	+	14	Oophorectomy	
			28	NR	Unilateral	7.4 × 4.8	NR	+	-	-	+	19	Oophorectomy	
Takeuchi M et al. [15]	2008	5	20–32	NR	Unilateral	4–9	2 (max)	+	-	-	-	NR	NR	
Barbieri M et al. [16]	2009	3	32	30	Unilateral	6.6 × 4.4	2 × 1.4	+	-	+	-	NR	Cystectomy	
			36	159	Bilateral	8.5 × 6.3, 5 × 3	2.7 × 1.4, 0.7 × 0.7	+	-	+	-	-	None	None
			39	85	Unilateral	3.8 × 1.4	1.9 × 1.2	+	-	+	-	-	None	None
Sayasneh A et al. [17]	2012	1	35	89	Unilateral	3 × 4 × 4	1.5	+	-	+	-	-	None	None
Tazegül A et al. [3]	2013	1	32	220	Unilateral	6.5 × 5.7	1.4 × 0.8	+	-	+	-	12	Cystectomy	
Proulx F et al. [18]	2014	1	30	NR	Unilateral	Dmax 4	NR	+	-	+	+	-	None	

Table 1 (continued)

Author, reference	Publication year	No. of cases	Age, range	CA125 (U/ml)	Laterality	Size (cm)	Solid part (cm)	Intracystic papillae	Septa	Blood flow	MRI	Surgery GA	Surgical procedure
Masclini F et al. [19]	2014	18	20–43	12–285	3 bilateral and 15 unilateral	4.1–12.1	17 cases +	17 cases +	7 cases +	16 cases +	–	–	13 cases
Groszmann Y et al. [20]	2014	17	22–43	NR	5 bilateral and 12 unilateral	3–27	14 cases +	NR	8 cases +	12 cases +	–	–	8 cases
Alsalem H et al. [21]	2021	1	28	134	Unilateral	NR	+	+	–	+	+	38 (CS)	Cystectomy

Abbreviations: MRI magnetic resonance imaging, GA gestational age, NR not reported, Dmax maximum diameter, CS Cesarean section

the mass showed no change in size over 4 weeks or lacked solid components and vascularity. Recently, Alsalem H et al. [21] reported a case with a growing left adnexal mass and elevated CA125 at 134kU/L. After a transvaginal/transabdominal ultrasound, the possibility of a benign decidualized endometrioma was raised and the patient consented to an ovarian cystectomy at her cesarean section, preventing an unnecessary oophorectomy during pregnancy and reducing the anxiety of malignancy. Finally, the histopathology confirmed endometriosis with extensive decidualization and no malignancy.

Gadolinium-free magnetic resonance imaging (MRI) during pregnancy is considered safe and can be used to evaluate ultrasound-undetermined adnexal lesions. Because of the vascularization and edema, the apparent diffusion coefficient (ADC) of decidualized endometrial tissues was significantly higher than that of ovarian cancers [15]. Nobuko Morisawa et al. [22] investigate the MRI findings of 18 decidualized endometriotic cysts in comparison with 24 endometriotic cysts associated with ovarian cancers. They found that the heights of the solid components in the decidualized endometrioma were significantly lower compared with the ovarian cancers, and solid component showing high signal intensities on T2-weighted imaging is highly indicative of decidualization. Recently, Takeuchi et al. [23] evaluated the diagnostic ability of computed diffusion-weighted imaging (DWI) for differentiating decidualized endometrioma from ovarian cancer. In this study, mural nodules in decidualized endometriomas showed high signal intensity on DWI with b values of 800 s/mm² due to T2 shine-through effect. However, the decidualized endometriomas showed a signal decrease on computed DWI with b values of 1500 s/mm², whereas cancers did not. Hence, computed DWI with b values of 1500 s/mm² may be useful to distinguish decidualized endometriomas from ovarian malignancy. Overall, ADC measurement and DWI with high b values are recommended as additional diagnostic tools.

As for serum tumor markers, some studies indicated that CA125 levels have a limited value of differential diagnosis in pregnant patients because it is physiologically elevated [24]. However, some studies have proposed a potential diagnostic role of continuous measurement of CA125 or the levels of CA125 above 1000 U/ml at or after mid-pregnancy [25]. Moreover, the serum concentration of human epididymis protein 4 (HE4) marker was reported to increase with the duration of pregnancy. Gasiorowska E et al. [26] demonstrated that the upper limit values of normal HE4 levels are 55 pmol/l, 80 pmol/l, and 106 pmol/l for the first, second, and third trimesters, respectively. Therefore, the combined evaluation of CA125 and HE4 may play

a potential role in the differential diagnosis of adnexal masses during pregnancy.

Actually, it is a dilemma between expectant treatment and surgical intervention concerning the management of adnexal masses during pregnancy. This may lead to unnecessary resection of benign tumors, or even worse, conservative observation of a malignant ovarian tumor. Therefore, it is necessary to hold a multidisciplinary discussion to balance the fetal and maternal risks, gestational age, and degree of malignant suspicion. It is worth noting that, according to published literature, the pregnancy outcome of patients undergoing surgery is safe, only one patient suffered a preterm rupture of membranes on the day of laparotomy at the 19th gestational week [13]. Among the published literature shown in Table 1, all patients who chose to surgery underwent laparotomy. Nowadays with the development of laparoscopic techniques, laparoscopy performed by an experienced surgeon has been reported to be a safe approach during pregnancy [27]. In our case, laparoscopic left salpingo-oophorectomy was performed and the patient recovered smoothly without postoperative complications.

Conclusion

Pregnancy-related changes of ovarian endometrioma leading to the vascularized intracapsular vegetation mimicking malignancies are rare but possible events. In this case, we reported a decidualized ovarian endometrioma mimicking malignant transformation during pregnancy. Sonographic findings and the use of MRI are helpful for differential diagnosis. Conservative management of expectant management and serial monitoring should be adopted if decidualized endometriosis is suspected.

Abbreviations

MRI: Magnetic resonance imaging; ADC: Apparent diffusion coefficient; DWI: Diffusion-weighted imaging; HE4: Human epididymis protein 4.

Acknowledgments

We thank Dr. Weixun Zhou at pathology department of our hospital for pathologic review.

Authors' contributions

JXY and TW diagnosed the case. SJL and XYZ assisted with literature review. MY, TW and JXY were major contributors towards the preparation of the final draft of the manuscript. All the authors contributed towards the preparation of final version of the manuscript. The authors read and approved the final manuscript.

Funding

This work was supported by the Chinese Academy of Medical Sciences Initiative for Innovative Medicine (CAMS-2017-I2M-1-002).

Availability of data and materials

All the generated data are included in this article.

Declarations

Ethics approval and consent to participate

The article was exempted by the Ethical Review Committee (ERC) of Peking Union Medical College Hospital.

Consent for publication

Informed consent was acquired from the patient.

Competing interests

The authors declare that they have no competing interests.

Author details

¹Department of Obstetrics and Gynecology, Peking Union Medical College Hospital, Chinese Academy of Medical Sciences & Peking Union Medical College, Beijing, China. ²National Clinical Research Center for Obstetric & Gynecologic Diseases, Beijing, China.

Received: 21 January 2022 Accepted: 27 February 2022

Published online: 09 March 2022

References

- Webb KE, Sakhel K, Chauhan SP, Abuhamad AZ. Adnexal mass during pregnancy: a review. *Am J Perinatol*. 2015;32(11):1010–6. <https://doi.org/10.1055/s-0035-1549216>.
- Chapron C, Marcellin L, Borghese B, Santulli P. Rethinking mechanisms, diagnosis and management of endometriosis. *Nat Rev Endocrinol*. 2019;15(11):666–82. <https://doi.org/10.1038/s41574-019-0245-z>.
- Tazegül A, Seçilmiş Kerimoğlu O, Incesu FN, Doğan NU, Yılmaz SA, Celik C. A case presentation: decidualized Endometrioma mimicking ovarian Cancer during pregnancy. *Case Rep Obstet Gynecol*. 2013;2013:728291. <https://doi.org/10.1155/2013/728291>.
- Sammour RN, Leibovitz Z, Shapiro I, et al. Decidualization of ovarian endometriosis during pregnancy mimicking malignancy. *J Ultrasound Med*. 2005;24(9):1289–94. <https://doi.org/10.7863/jum.2005.24.9.1289>.
- Leiserowitz GS, Xing G, Cress R, Brahmabhatt B, Dalrymple JL, Smith LH. Adnexal masses in pregnancy: how often are they malignant? *Gynecol Oncol*. 2006;101(2):315–21. <https://doi.org/10.1016/j.ygyno.2005.10.022>.
- Miyakoshi K, Tanaka M, Gabionza D, et al. Decidualized ovarian endometriosis mimicking malignancy. *AJR Am J Roentgenol*. 1998;171(6):1625–6. <https://doi.org/10.2214/ajr.171.6.9843300>.
- Tanaka YO, Shigemitsu S, Nagata M, et al. A decidualized endometrial cyst in a pregnant woman: a case observed with a steady-state free precession imaging sequence. *Magn Reson Imaging*. 2002;20(3):301–4. [https://doi.org/10.1016/s0730-725x\(02\)00499-x](https://doi.org/10.1016/s0730-725x(02)00499-x).
- Fruscella E, Testa AC, Ferrandina G, et al. Sonographic features of decidualized ovarian endometriosis suspicious for malignancy. *Ultrasound Obstet Gynecol*. 2004;24(5):578–80. <https://doi.org/10.1002/uog.1736>.
- Guerriero S, Ajossa S, Piras S, Parodo G, Melis GB. Serial ultrasonographic evaluation of a decidualized endometrioma in pregnancy. *Ultrasound Obstet Gynecol*. 2005;26(3):304–6. <https://doi.org/10.1002/uog.1986>.
- Iwamoto H, Suzuki M, Watanabe N, Minai M, Hirata S, Hoshi K. Case study of a pregnant woman with decidualized ovarian endometriosis whose preoperative findings suggested malignant transformation. *Eur J Gynaecol Oncol*. 2006;27(3):301–3.
- Asch E, Levine D. Variations in appearance of endometriomas. *J Ultrasound Med*. 2007;26(8):993–1002. <https://doi.org/10.7863/jum.2007.26.8.993>.
- Poder L, Coakley FV, Rabban JT, Goldstein RB, Aziz S, Chen LM. Decidualized endometrioma during pregnancy: recognizing an imaging mimic of ovarian malignancy. *J Comput Assist Tomogr*. 2008;32(4):555–8. <https://doi.org/10.1097/RCT.0b013e31814685ca>.
- Machida S, Matsubara S, Ohwada M, et al. Decidualization of ovarian endometriosis during pregnancy mimicking malignancy: report of three cases with a literature review. *Gynecol Obstet Investig*. 2008;66(4):241–7. <https://doi.org/10.1159/000147171>.
- Yoshida S, Onogi A, Shigetomi H, et al. Two cases of pregnant women with ovarian endometrioma mimicking a malignant ovarian tumor. *J Clin Ultrasound*. 2008;36(8):512–6. <https://doi.org/10.1002/jcu.20496>.
- Takeuchi M, Matsuzaki K, Nishitani H. Magnetic resonance manifestations of decidualized endometriomas during pregnancy. *J Comput Assist Tomogr*. 2008;32(3):353–5. <https://doi.org/10.1097/RCT.0b013e3181238362>.
- Barbieri M, Somigliana E, Oneda S, Ossola MW, Acaia B, Fedele L. Decidualized ovarian endometriosis in pregnancy: a challenging diagnostic entity. *Hum Reprod*. 2009;24(8):1818–24. <https://doi.org/10.1093/hum-rep/dep089>.
- Sayasneh A, Naji O, Abdallah Y, Stalder C, Bourne T. Changes seen in the ultrasound features of a presumed decidualized ovarian endometrioma mimicking malignancy. *J Obstet Gynaecol*. 2012;32(8):807–11. <https://doi.org/10.3109/01443615.2012.707256>.
- Proulx F, Levine D. Decidualization of endometrioma in pregnancy. *Ultrasound Q*. 2014;30(3):211–2. <https://doi.org/10.1097/RUQ.0000000000000106>.
- Mascilini F, Moruzzi C, Giansiracusa C, et al. Imaging in gynecological disease. 10: clinical and ultrasound characteristics of decidualized endometriomas surgically removed during pregnancy. *Ultrasound Obstet Gynecol*. 2014;44(3):354–60. <https://doi.org/10.1002/uog.13323>.
- Groszmann Y, Howitt BE, Bromley B, Feltmate CM, Benacerraf BR. Decidualized endometrioma masquerading as ovarian cancer in pregnancy. *J Ultrasound Med*. 2014;33(11):1909–15. <https://doi.org/10.7863/ultra.33.11.1909>.
- Alsaem H, Tigdi J, Osmond M, Leyland N, Tang S, Leonardi M. Stop, think, and re-evaluate: a decidualized Endometrioma can mimic malignancy in pregnancy. *J Minim Invasive Gynecol*. 2021;28(11):1803–5. <https://doi.org/10.1016/j.jmig.2021.06.022>.
- Morisawa N, Kido A, Kataoka M, Minamiguchi S, Konishi I, Togashi K. Magnetic resonance imaging manifestations of decidualized endometriotic cysts: comparative study with ovarian cancers associated with endometriotic cysts. *J Comput Assist Tomogr*. 2014;38(6):879–84. <https://doi.org/10.1097/RCT.0000000000000136>.
- Takeuchi M, Matsuzaki K, Harada M. Computed diffusion-weighted imaging for differentiating decidualized endometrioma from ovarian cancer. *Eur J Radiol*. 2016;85(5):1016–9. <https://doi.org/10.1016/j.ejrad.2016.03.009>.
- Aslam N, Ong C, Woelfer B, Nicolaidis K, Jurkovic D. Serum CA125 at 11–14 weeks of gestation in women with morphologically normal ovaries. *BJOG*. 2000;107(5):689–90. <https://doi.org/10.1111/j.1471-0528.2000.tb13314.x>.
- Goh W, Bohrer J, Zalud I. Management of the adnexal mass in pregnancy. *Curr Opin Obstet Gynecol*. 2014;26(2):49–53. <https://doi.org/10.1097/GCO.0000000000000048>.
- Gasirowska E, Kluz T, Lipski D, Warchol W, Tykarski A, Nowak-Markwitz E. Human Epididymis Protein 4 (HE4) Reference Limits in Polish Population of Healthy Women, Pregnant Women, and Women with Benign Ovarian Tumors. *Dis Markers*. 2019;2019:3890906. Published 2019 Aug 22. <https://doi.org/10.1155/2019/3890906>.
- Xiao J, Fu K, Duan K, Wang J, Sunkara S, Guan X. Pregnancy-preserving Laparoscopic single-site surgery for gynecologic disease: a case series. *J Minim Invasive Gynecol*. 2020;27(7):1588–97. <https://doi.org/10.1016/j.jmig.2020.02.009>.

Publisher's Note

Springer Nature remains neutral with regard to jurisdictional claims in published maps and institutional affiliations.