

Aortic Valve Replacement Using Balloon Catheter for Thoracic Endovascular Aortic Repair to Patient with Calcified Aorta

In Sook Kim, M.D.¹, Joung Hun Byun, M.D., Ph.D.², Byung Ha Yoo, M.D.², Han Yong Kim, M.D.², Sang Won Hwang, M.D.², Yun Gyu Song, M.D.³

A 79-year-old man was admitted to Samsung Changwon Hospital due to chest pain and dyspnea. The ejection fraction was 31% and mean pressure gradient between the left ventricle and aorta was 69.4 mmHg on echocardiography. Chest computed tomography showed severe calcification of the ascending aorta. Aortic valve replacement was successfully performed using a thoracic endovascular aortic repair balloon catheter without classic aortic cross clamping. The patient was discharged on the eleventh postoperative day.

Key words: 1. Aortic valve
2. Aorta
3. Calcification

CASE REPORT

A 79-year-old man was admitted due to severe chest pain and dyspnea for 3 days. The patient's medical history showed that he had undergone treatment for sustained ventricular tachycardia six years ago. The patient had been taking hypertension medicine.

During the evaluation, the patient complained of mild chest pain. Preoperative chest radiography showed cardiomegaly and aortic arch calcification (Fig. 1). Electrocardiography showed a normal sinus rhythm. Echocardiography showed an ejection fraction of 31%, severe aortic valve stenosis ($V_{max}=5.26$ m/sec, mean pressure gradient [PG]=69.4 mmHg, aortic valve area by continuity equation=0.6 cm²) and mild to moderate mitral valve regurgitation (proximal isovelocity surface area radius=0.7 cm). Coronary angiography showed no

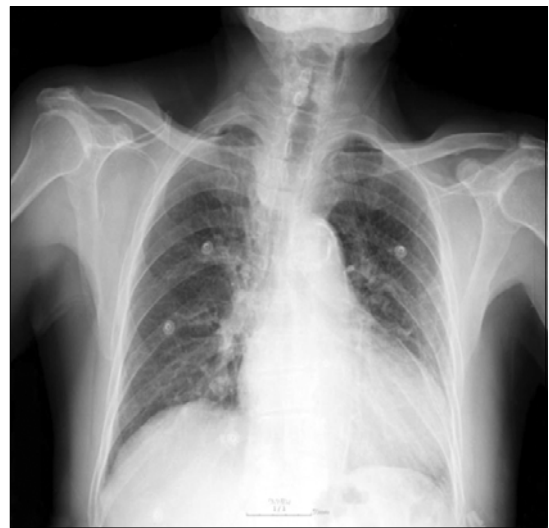

Fig. 1. This figure shows the preoperative simple chest radiography.

¹Department of Thoracic and Cardiovascular Surgery, Samsung Medical Center, Sungkyunkwan University School of Medicine, Departments of ²Thoracic and Cardiovascular Surgery and ³Radiology, Samsung Changwon Hospital, Sungkyunkwan University School of Medicine
Received: August 16, 2012, Revised: October 29, 2012, Accepted: October 30, 2012

Corresponding author: Joung Hun Byun, Department of Thoracic and Cardiovascular Surgery, Samsung Changwon Hospital, Sungkyunkwan University School of Medicine, 158 Paryong-ro, Masanhoewon-gu, Changwon 630-723, Korea
(Tel) 82-55-290-6019 (Fax) 82-55-290-6785 (E-mail) jhunikr@naver.com

© The Korean Society for Thoracic and Cardiovascular Surgery. 2013. All right reserved.

© This is an open access article distributed under the terms of the Creative Commons Attribution Non-Commercial License (<http://creativecommons.org/licenses/by-nc/3.0>) which permits unrestricted non-commercial use, distribution, and reproduction in any medium, provided the original work is properly cited.

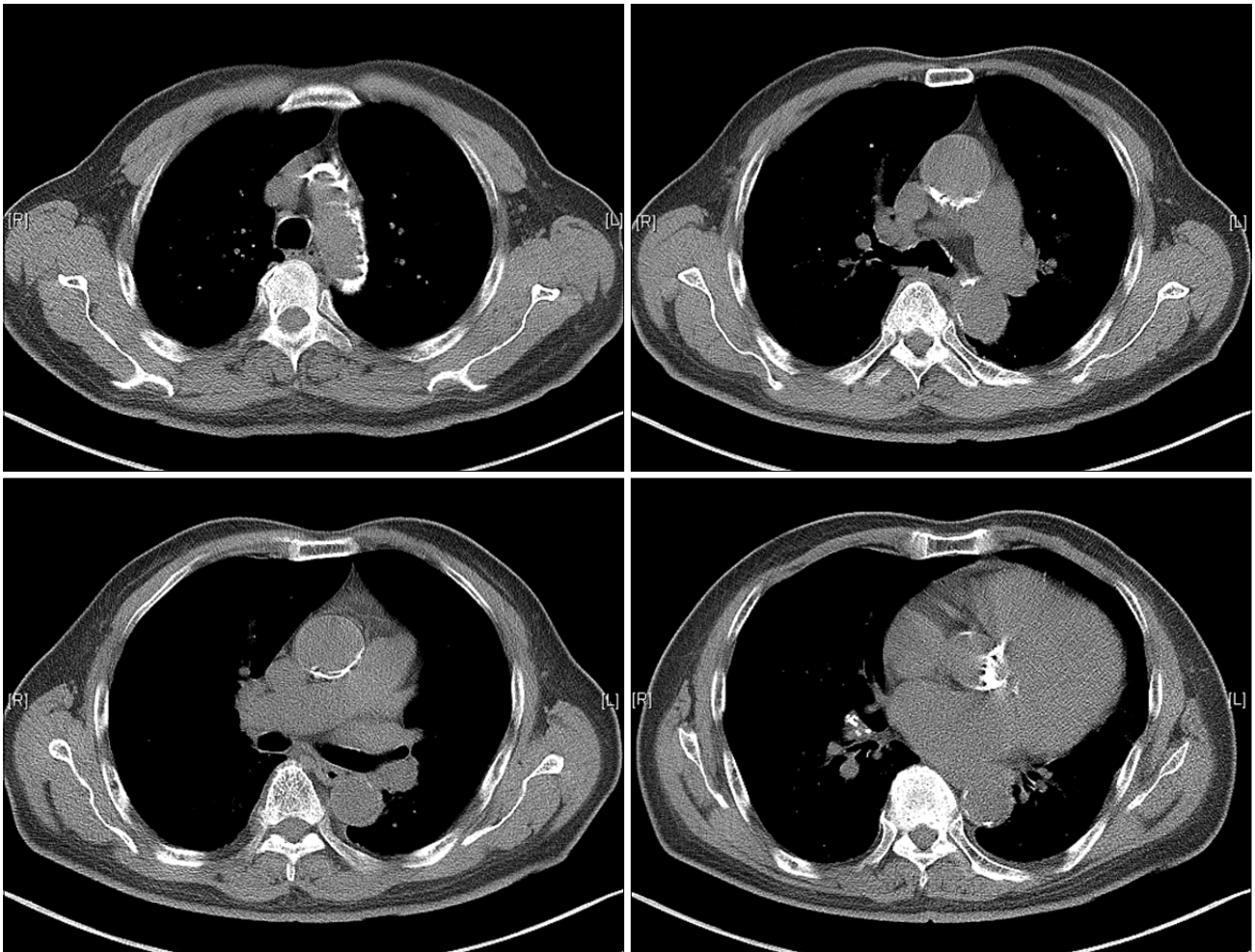


Fig. 2. Preoperative computed tomography showed severe calcification of the aorta.

significant coronary artery disease, while chest computed tomography showed calcification of the posterior wall of the ascending aorta (Fig. 2). The patient underwent surgery under general anesthesia via median sternotomy. After pericardiotomy, arterial cannulation was accomplished in the right axillary artery.

Venous drainage was accomplished with a single double-staged cavoatrial cannula. A vent cannula was inserted into the left ventricle via the right superior pulmonary vein. A root cannula was inserted into the ascending aorta. A thoracic endovascular aortic repair (TEVAR) balloon catheter (40×30 mm) for endo-aortic occlusion was inserted into the ascending aorta via the left superficial femoral artery using a C-arm (GE, Bayern, Germany) (Fig. 3). After initiation of car-

diopulmonary bypass (CPB) with moderate hypothermia, endo-aortic occlusion was accomplished by inflation of the TEVAR balloon (Fig. 3). Blood cardioplegia solution was administered to arrest the heart via root cannula, and then this solution was administered via direct cardioplegia cannula every 20 minutes. Aortic valve replacement was performed with valve tissue. Termination of CPB was performed without complication.

The patient was extubated on the first postoperative day. Follow-up echocardiography showed an ejection fraction of 33%, a well-functioning aortic prosthetic valve (mean PG= 22.4 mmHg) and minimal mitral valve regurgitation. The patient recovered without complication and was discharged on the eleventh postoperative day.

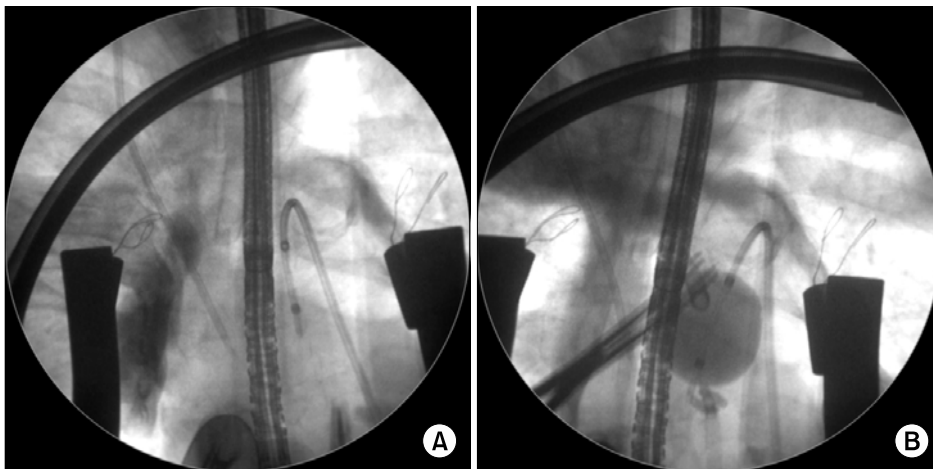


Fig. 3. Intraoperative X-ray view of endoarterial balloon occlusion. (A) Catheter inserted through right femoral artery. (B) Balloon is positioned in the ascending aorta.

DISCUSSION

As an increasing number of older patients undergo cardiac operations, severe atherosclerosis of the ascending aorta has been appearing more frequently. As much as 13% of the patients undergoing cardiac surgery will have a significant associated atheromatous disease of the ascending aorta [1]. In a patient with severe atherosclerosis of the ascending aorta, conventional aortic valve surgery can be technically demanding and is associated with high morbidity and mortality. To clamp an atherosclerotic aorta during a cardiac operation can increase the risk of cerebral embolism by atherosclerotic debris. Therefore, aortic valve surgery in a patient with severe atherosclerosis of the ascending aorta requires modifications of techniques for CPB.

Several reports have described modifications of surgical techniques for managing aortic valve disease in limited numbers of patients with a severely calcified ascending aorta. Gillinov et al. [2] reported on 62 of 4,983 patients that had undergone an aortic valve replacement and were noted to have atherosclerosis of the ascending aorta. Hypothermic circulatory arrest (HCA) including ascending aortic endarterectomy, ascending aortic replacement, and balloon occlusion of the ascending aorta were used for the patients [2]. Byrne et al. [3] have described a “no-touch” technique under deep HCA for the porcelain aorta. Svensson et al. [4] reported successful aortic endarterectomy to facilitate aortic valve replacement with a calcified ascending aorta. Cosgrove [5] reported a forward-balloon occlusion of the ascending aorta after per-

forming an aortotomy with the aid of HCA.

Although various surgical strategies have been described for managing atherosclerotic aorta in patients requiring aortic valve replacement, the appropriate techniques are unknown. In addition, these strategies all need HCA. Okamoto et al. [6] have described HCA as a useful method for replacing the aortic valve in a patient with an atherosclerotic aorta. However, it has a limitation in its safe duration without ischemic injury occurring to the brain, and longer cardiac arrest time is also associated with high mortality and morbidity [6]. In our case, we performed aortic valve replacement using retrograde endoarterial balloon occlusion without HCA. This is the first such case in Korea. Abe et al. [7] reported that four valve surgeries were performed with balloon occlusion without HCA. We maintained the patient’s body at a temperature of about 32°C, unlike during HCA. This procedure was performed successfully, and postoperatively, the patient recovered without any complications. Although this technique still has a greater risk of dislodging emboli than the “no-touch” technique under HCA, we believe that it was effective and could be a good option for high-risk patients who have a pathology of the ascending aorta while reducing the risk of cerebral embolism and without the burden of HCA. Future studies will be required to ascertain the safety of endoarterial balloon occlusion.

CONFLICT OF INTEREST

No potential conflict of interest relevant to this article was

reported.

REFERENCES

1. Mills NL, Everson CT. *Atherosclerosis of the ascending aorta and coronary artery bypass. Pathology, clinical correlates, and operative management.* J Thorac Cardiovasc Surg 1991;102:546-53.
2. Gillinov AM, Lytle BW, Hoang V, et al. *The atherosclerotic aorta at aortic valve replacement: surgical strategies and results.* J Thorac Cardiovasc Surg 2000;120:957-63.
3. Byrne JG, Aranki SF, Cohn LH. *Aortic valve operations under deep hypothermic circulatory arrest for the porcelain aorta: "no-touch" technique.* Ann Thorac Surg 1998;65:1313-5.
4. Svensson LG, Sun J, Cruz HA, Shahian DM. *Endarterectomy for calcified porcelain aorta associated with aortic valve stenosis.* Ann Thorac Surg 1996;61:149-52.
5. Cosgrove DM. *Management of the calcified aorta: an alternative method of occlusion.* Ann Thorac Surg 1983;36:718-9.
6. Okamoto H, Fujimoto K, Tamenishi A, Itoh Y, Niimi T. *Aortic valve replacement in a heavily calcified "porcelain" aorta.* Jpn J Thorac Cardiovasc Surg 2001;49:453-6.
7. Abe T, Ito T, Sunada M, Yoshizumi T, Kawamura A, Yamana K. *Balloon occlusion of the ascending aorta without hypothermic circulatory arrest in valve surgery for patients with a porcelain aorta.* Heart Surg Forum 2010;13:E251-3.