

REVIEW ARTICLE

Two-Stage Revision Hip Arthroplasty with or without the Use of an Interim Spacer for Managing Late Prosthetic Infection: A Systematic Review of the Literature

Angshuman Khanna, MBBS, MCh¹ , Bernie Carter, PhD, BSc² , Inder Gill, MBBS, FRCS¹

¹Department of Trauma and Orthopaedics, Salford Royal NHS Foundation Trust, Salford and ²Faculty of Health, Social Care and Medicine, Edge Hill University, Ormskirk, UK

The aim of the present paper was to identify, appraise, and synthesize the available evidence on two-stage revision hip arthroplasty with or without the use of an interim spacer for managing late prosthetic infection. The review methodology was designed by referencing the Preferred Reporting Items for Systematic Reviews and Meta-analyses (PRISMA) checklist and flow diagram, and a Population, Intervention, Comparator, Outcomes and Study (PICOS) design framework was used to search for studies to incorporate within the review. Two independent investigators were involved in searching for relevant articles that fulfilled the inclusion criteria for the study. Critical appraisal of the selected articles was carried out using the relevant Critical Appraisal Skills Programme checklists. From an initial pool of 125 articles, four studies satisfied the inclusion criteria and quality assessment and were included for final review. Two patient groups were identified from within the selected studies: spacer and non-spacer. Both groups were assessed in terms of functional outcome, infection cure rates, and technical difficulties encountered during treatment. Better functional outcome was reported in the spacer group, both in the interim period between the two stages and after completion of treatment. The use of spacers reduced operative difficulty during the second stage and accelerated patient discharge. Reinfection and infection persistence rates were higher in the non-spacer group. Within the spacer group, articulated spacers performed better in all parameters. The results of this review reinforce the available evidence supporting the use of interim hip spacers in revision hip arthroplasty for managing prosthetic infection and also indicate that articulated hip spacers could be an attractive option going forward.

Key words: Arthroplasty; Hip; Infection; Revision

Introduction

A two-stage revision hip arthroplasty is a popular approach in the treatment of late infection after total hip replacement (THR)^{1,2}. Following an initial operation to remove the infected prosthesis, the hip is either left with a temporary implanted spacer device or in a situation like a Girdlestone arthroplasty³ for a period ranging from a few weeks to a few months. Systemic targeted antibiotic therapy is maintained during this period. Once the infection is cured and the local soft tissue condition has settled, reimplantation

of the definitive prosthesis is undertaken as the second-stage procedure.

Antibiotic-loaded cement spacers are a popular choice among orthopaedic surgeons^{2,4,5}. They are reported to provide a formidable local antimicrobial effect by eluting antibiotics, that are mixed with the cement, into the soft tissues around the hip⁶. The presence of the spacer device also appears to help preserve some functionality in the hip and reduces the amount of soft tissue scarring and contractures, thereby facilitating an easier second operation⁷.

Address for correspondence Bernie Carter, Faculty of Health, Social Care and Medicine, Room H217a, Edge Hill University, St Helens Road, Ormskirk, UK L39 4QP Tel: 01695 657771; Email: bernie.carter@edgehill.ac.uk

Disclosure: The authors declare that they have no relevant or material financial interests that relate to the research described in this paper.

Received 13 May 2020; accepted 25 October 2020

Orthopaedic Surgery 2021;13:384-394 • DOI: 10.1111/os.12875

This is an open access article under the terms of the Creative Commons Attribution-NonCommercial-NoDerivs License, which permits use and distribution in any medium, provided the original work is properly cited, the use is non-commercial and no modifications or adaptations are made.

In contrast, while good infection cure rates have been reported without spacer use^{8,9}, functional outcomes are often poor and rates of complications high. For example, shortening of the leg, persistent limp, and hip instability have been documented^{2,8}. Furthermore, soft tissue scarring and blurring of tissue planes, tissue contractures, and osteoporosis due to inactivity are reported to significantly increase the technical difficulty of reimplanting the definitive prosthesis during the second-stage procedure¹⁰.

There are very few studies that directly compare the technical aspects and treatment outcomes of the above two strategies. While the benefits of spacer use are much celebrated, it is worth considering that reinfection or persistence of infection following hip spacer implantation can lead to higher revision surgery rates and increase overall rates of morbidity and mortality¹¹. Moreover, spacers are associated with their own unique set of complications. Monoblock spacers are linked with spacer fractures and bone resorption, while two-part spacers can generate abraded cement particles and, occasionally, dislocate^{10,12}. Systemic complications, such as allergic reactions to the spacer component or even hepatic or renal failure, have also been reported^{10,11}.

This systematic review aimed to identify, appraise, and synthesize the evidence on two-stage revision hip arthroplasty with or without the use of an interim spacer for managing late prosthetic infection. The following outcomes of interest were assessed in the two groups:

1. The functional outcome in the patient groups, both in the interim period between the two stages and following the second-stage procedure.
2. The technical difficulties encountered and complications, if any, during each stage of surgery.
3. The overall infection eradication rates.

Methods

The review methodology was designed by referencing the Preferred Reporting Items for Systematic Reviews and Meta-analyses (PRISMA) checklist and flow diagram¹³.

Inclusion Criteria for Studies

A Population, Intervention, Comparator, Outcomes and Study (PICOS) designs framework¹⁴ was used to search for studies to incorporate within the review. Accordingly, the following inclusion criteria were identified:

1. Population. The population of interest included all patients who had undergone a two-stage revision hip arthroplasty for prosthetic hip infection.
2. Intervention(s). The exposure of interest was the use of temporary hip spacer devices during the first-stage procedure. No preference was given to a device type or to the use of antibiotic-loaded cement in the spacer.
3. Comparator(s). The results of surgery in the intervention group were compared against patients in whom no temporary spacer device was implanted during the first stage. Studies in which other non-mechanical constructs, such

as antibiotic cement beads, were used in place of spacers were also included, as it was anticipated that such an approach would function in a manner like the Girdlestone hip.

4. Outcome(s) of interest. Studies were sought that reported functional outcomes in the two groups of patients during the treatment period and/or following the completion of the second stage, the successful eradication of hip infection, as well as the technical difficulties encountered during the surgery and perioperative period.
5. Study design(s) to be included. No limitations on type of study design were imposed. However, only studies that directly compared the two treatment strategies (i.e. use and non-use of hip spacers) and the subsequent outcomes of interest in the two groups of patients were included. This was done with the aim to ensure results were compared among similar patient populations, research strategies, and outcomes of interest. In addition, no time limit was imposed upon studies for selection. Only studies published in peer reviewed journals were included.

Exclusion Criteria for Studies

The following studies were excluded: (i) studies reporting outcomes of single-stage revision hip arthroplasty or two-stage revision surgery for indications other than prosthetic hip infections; and (ii) studies comparing different types of hip spacer devices in revision hip arthroplasty.

Search Strategy

Two independent investigators (AK and IG) were involved in searching for relevant articles that fulfilled the inclusion criteria for the study. These were sought out within Medical Literature Analysis and Retrieval System Online (MEDLINE), PubMed, Cumulative Index to Nursing and Allied Health Literature (CINAHL) and Excerpta Medica dataBASE (EMBASE) search engines. The keywords “arthroplasty, replacement, hip,” “two-stage” and “spacer” or “hip spacer” were used while searching databases. No search limits, including date or language restrictions, were applied to the search strategy (Appendix 1). Relevant gray literature was searched for by using the search engine portals “OpenGrey” and “Google Scholar.” Furthermore, the PubMed “related articles” feature as well as the Google Scholar “cited by” feature were used to identify other appropriate research articles. The reference lists of relevant papers were checked, and cited articles relevant to the study were hand-searched and added.

Review Method

All relevant titles and abstracts were screened by the two investigators, and studies that satisfied the inclusion criteria were identified. Full text versions of the chosen articles were reviewed and, following satisfactory quality appraisal, were included in the review. Any disagreement arising between the two investigators at any stage during the review process

was resolved by discussion, with mediation by a third author (BC) when differences remained. One of the articles that was included in the review process was in Czech and an interpreter was enlisted to translate its contents.

Quality Assessment

Critical appraisal of the selected articles was carried out using the relevant Critical Appraisal Skills Programme (CASP) checklists^{15,16}.

Data Extraction and Outcome Measures

A bespoke data extraction form, designed by two investigators (AK and IG), was used to collect data on objective measures of: (i) functional outcomes during and after treatment; (ii) control or eradication of infection; and (iii) technical ease or difficulties encountered during treatment in the two patient groups within the review studies. The chief outcome measures described by the review articles included the following.

Harris Hip Score

The Harris hip score (HHS) is an outcome measure frequently used for the assessment of postoperative hip function¹⁷. It is made up of four subscales: (severity of) pain, function (daily activities and gait), (absence of) deformity, and range of motion. Each subscale is awarded points guided by a questionnaire as based on patient response, with a score range of 0–100, with higher scores denoting better hip function.

Merle d'Aubigné and Postel Hip Score

The Merle d'Aubigne and Postel score is an outcome measure for hip function and includes the parameters pain, mobility, and ability to walk¹⁸. Each response is rated from 0 to 6 points, with 0 denoting the worst and 6 denoting the best.

Western Ontario and McMaster Universities Arthritis Index

The Western Ontario and McMaster Universities Arthritis Index (WOMAC) is used for the evaluation of hip and knee function¹⁹. It consists of a questionnaire assessing 24 parameters divided over three primary subscales: pain, stiffness, and physical function. The answers are scored on a scale of 0–4, with higher scores denoting worse outcomes.

Visual Analogue Scale

The visual analogue scale (VAS) is a measurement device used to measure a characteristic or response that is subjective and often difficult to measure directly²⁰. It is frequently used to assess pain. In its simplest form, it asks patients to indicate their pain intensity as a point on a straight line, where the left limit of the line denotes worst pain and the right limit denotes best or no pain.

Erythrocyte Sedimentation Rate and C-Reactive Protein

The erythrocyte sedimentation rate (ESR) is a non-specific measure of inflammation in the human body. It measures the rate of sedimentation of red blood cells in a sample of anticoagulated blood within a thin-walled hematology glass tube. Faster sedimentation rates are encountered in the presence of an inflammatory response in the body, and by monitoring these rates over a period of time, it is possible to assess the control or eradication of infection.

C-reactive protein (CRP) is an acute phase reactant produced by the liver in response to acute inflammation in the human body. In general, CRP levels of above 10 mg/L of blood are indicative of a significant inflammatory response. Similar to ESR, serial CRP levels can be monitored to assess the progress or resolution of infection.

Criteria for Successful Total Hip Replacement Reimplantation According to Tsukayama *et al.* (1996)

Based on their experiences in treating 106 infections in 96 hips that had undergone THR, Tsukayama *et al.*²¹ defined five criteria for denoting successful eradication of infection in those hips. These criteria were: (i) a functional hip joint; (ii) non-painful or minimally painful hip joint when walking; (iii) X-ray findings denoting no signs of loosening or other signs of infection; (iv) a minimum time interval of 24 months since the procedure; and (v) no clinical signs of infection in the hip. Each criterion had to be met for successful infection eradication to be established.

Data Analysis

Data from each paper was extracted onto a separate form and these were created, maintained and stored electronically. Considering the small number of studies included in the final review and the non-uniform nature of reporting results in each study, the decision was made to present the results as a narrative synthesis. However, where possible, trends have been identified and reported within each outcome.

Results

Search Results

A total of 123 papers were identified following the use of the outlined search strategy, while a further two papers were identified through other sources. Following removal of duplicate records, 120 papers were available for screening; of these, 116 were excluded following the review of titles and abstracts. The key reasons for exclusion were the reporting of outcomes of a single treatment strategy only (spacer or non-spacer) or comparing outcomes between different types of spacers within two-stage revision hip arthroplasty, and the reporting of treatment strategies not relevant to the review, such as partial implant retention in two-stage exchange and one-stage revision arthroplasty. Only four studies were identified that satisfied the inclusion criteria for this systematic review^{22–25}. Full-text reports of these four studies were then obtained. All four full-text articles were deemed fit for

inclusion in the systematic review following quality appraisal and eligibility checks conducted by both investigators (AK and IG). A summary of the literature search and screening process based on the PRISMA flow diagram¹³ is presented in Fig. 1.

Study Characteristics

The four studies were published between the years 2003 and 2016 and comprised a total of 353 patients treated for late prosthetic hip infection with two-stage revision hip arthroplasty. There was a considerably higher proportion of male patients ($n = 231$) compared to female patients ($n = 122$). The mean age of the review population was 61.9 years, with the youngest patient aged 16 years and the oldest aged 90 years.

A total of 170 patients were included in the intervention group and treated with the use of a temporary hip spacer during the first-stage surgery. Different types of spacer devices were used in the studies. One study reported the use of a custom articulated spacer with incorporated antibiotic-loaded bone cement²³; two reported the use of a cemented monoblock spacer (antibiotic-loaded)^{22,25}, while the fourth reported the use of a commercially available antibiotic-loaded unipolar spacer device that was implanted without the use of bone cement¹⁹.

There were 183 patients included in the control group treated without a hip spacer. In one study²³, antibiotic-loaded cement beads were used to fill the dead space created

after the resection arthroplasty. Both groups of patients, intervention and control, were planned for reimplantation of definitive hip prosthesis during the second-stage surgery.

Patients across both groups were followed up for a mean duration of 57.8 months (range 24–128 months). All four studies assessed patients in terms of functional outcome and recurrence of infection, while radiographic assessment was formally carried out in two studies^{22,23}. Of the four studies included in the review, three were retrospective cohort studies^{22,23,24}, while one was a randomized controlled trial.²⁵

Assessment of Study Quality

Quality assessment was undertaken using the relevant CASP checklists for cohort studies and randomized controlled trials^{15,16}. Although each study included in the review had unique methodological strengths and weaknesses (Tables 1 and 2), they managed to satisfy the overall requirements for eligibility for inclusion within the review. All four studies addressed a clearly focused clinical problem and provided reproducible research methods as well as objective measurements of outcomes for both patient groups.

Functional Outcome

All four studies reported an overall improvement in primary hip score results from initial assessment to final follow up in both groups of patients; this improvement was comparatively more in the treatment group. Using the HHS¹⁷, Marczak *et al.*²⁴ reported an improvement in hip function by an

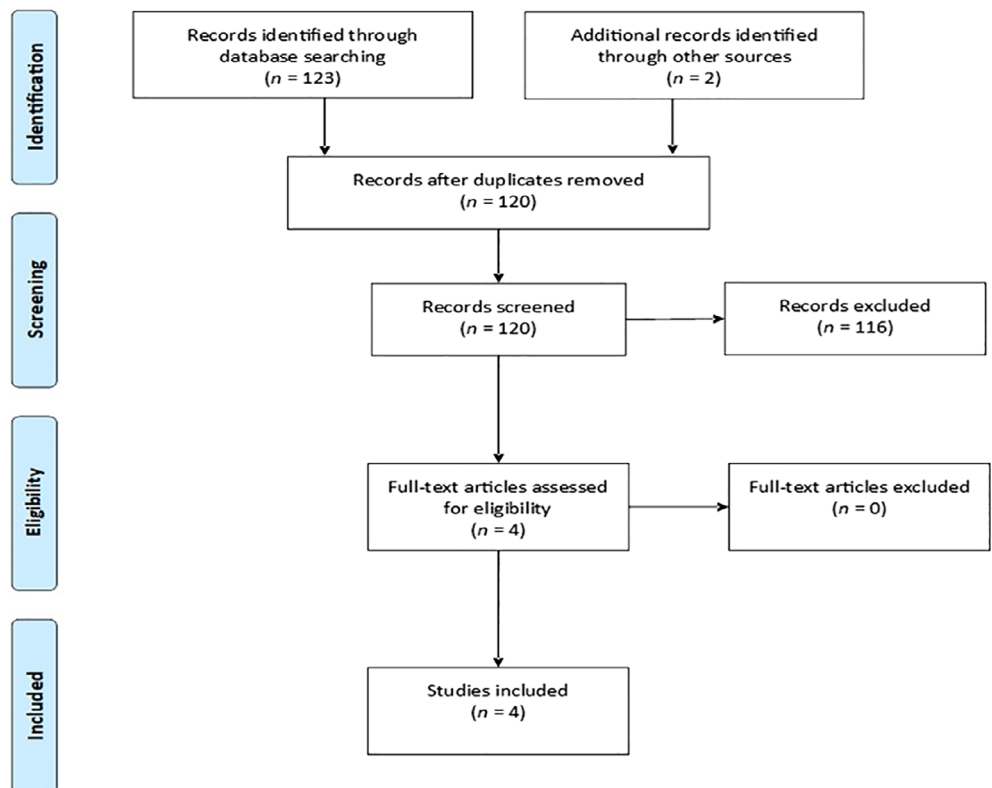


Fig. 1 Flow diagram summarizing the literature search and screening process.

TABLE 1 Summary of CASP quality assessment of cohort studies¹⁵

Checklist questions	Marczak <i>et al.</i> ²⁴	Hsieh <i>et al.</i> ²³	Jahoda <i>et al.</i> ²²
Section A: Are the results of the study valid			
1 Did the study address a clearly focused issue?	Y	Y	Y
2 Was the cohort recruited in an acceptable way?	Y	Y	CT
3 Was the exposure accurately measured to minimize bias?	Y	Y	Y
4 Was the outcome accurately measured to minimize bias?	Y	Y	CT
5(a) Have the authors identified all important confounding factors?	CT	CT	CT
5(b) Have they taken account of the confounding factors in the design and/or analysis?	N	CT	N
6(a) Was the follow up of subjects complete enough?	Y	Y	Y
6(b) Was the follow up of subjects long enough?	Y	Y	Y
Section B: What are the results?			
7 What are the results of this study?	ST	ST	ST
8 How precise are the results?	SR	SR	SR
9 Do you believe the results?	Y	Y	Y
Section C: Will the results help locally?			
10 Can the results be applied to the local population?	CT	CT	CT
11 Do the results of this study fit with other available evidence?	N	Y	Y
12 What are the implications of this study for practice?	CT	Y	CT
CASP, Critical Appraisal Skills Programme; CT, Cannot tell; N, No; SR, Sufficiently robust; ST, See text – Results; Y, Yes.			

average of 10.1 points in the interim period following the first-stage operation and by 25.2 points after prostheses replantation in the treatment group. In contrast, the HHS dropped by a mean of 2.6 points in the interim period in the control group, while it improved to an overall increase by 16.6 points after the second-stage surgery. The difference in the HHS between the two groups of patients at both periods in treatment was reported as statistically significant (P -value > 0.0001 and 0.0005). Hsieh *et al.*²³ used the Merle d'Aubigné and Postel hip score¹⁸ to report improved hip scores from a mean of 8.1 to 13.3 in the interim period, and to 15.8 at final follow up in the treatment group; in the control group, scores at similar points in time were noted as 7.9, 10.2, and 15.3, respectively. The difference between the hip

TABLE 2 Summary of CASP quality assessment of Randomized Controlled Trial¹⁶

Checklist questions	Cabrera <i>et al.</i> ²⁵
Section A: Are the results of the study valid?	
1 Did the trial address a clearly focused issue?	Y
2 Was the assignment of patients to treatments randomized?	Y
3 Were all of the patients who entered the trial properly accounted for at its conclusion?	N
4 Were patients, health workers and study personnel 'blind' to treatment?	CT
5 Were the groups similar at the start of the trial?	CT
6 Aside from the experimental intervention, were the groups treated equally?	Y
Section B: What are the results?	
7 How large was the treatment effect?	ST
8 How precise was the estimate of the treatment effect?	SR
Section C: Will the results help locally?	
9 Can the results be applied to the local population, or in your context?	CT
10 Were all clinically important outcomes considered?	Y
11 Are the benefits worth the harms and costs?	CT
CASP, Critical Appraisal Skills Programme; CT, Cannot tell; N, No; SR, Sufficiently robust; ST, See text – Results; Y, Yes.	

scores of the two groups in the interim period was deemed statistically significant (P -value < 0.05). Their study also reported better mobility among treatment group patients during the interim period.

Marczak *et al.*²⁴ also reported a statistically significant improvement in the WOMAC score¹⁹ in the treatment group in the interim period (mean improvement of 5.8 points against -4.0 points; P -value 0.000001). The control group was, however, reported to have a statistically significant lower VAS score²⁰ during the interim period (mean of 4.0 points against 5.2 points; P -value 0.0006). A summary of the trends in hip scores across two review studies at the three stages of treatment is presented in Fig. 2. Cabrera *et al.*²⁵ reported less treatment-related mortality, less final leg length discrepancy, and a statistically significant higher percentage of good results (81.5% vs 60.0%; P -value < 0.001) in the treatment group (Fig. 3).

Eradication of Infection

Three studies reported better infection control with the use of spacer during first-stage surgery (Fig. 4). This difference was statistically significant in one study²⁵ (P -value 0.002). Three of the review studies used serial testing for various markers of inflammation, namely ESR, CRP and white blood cell counts, as well as subjective clinical and radiological signs to help determine eradication of infection among their patients^{23,24,25}. Among these studies, Marczak *et al.*²⁴ reported recurrence of infection in six (12.8%) patients from

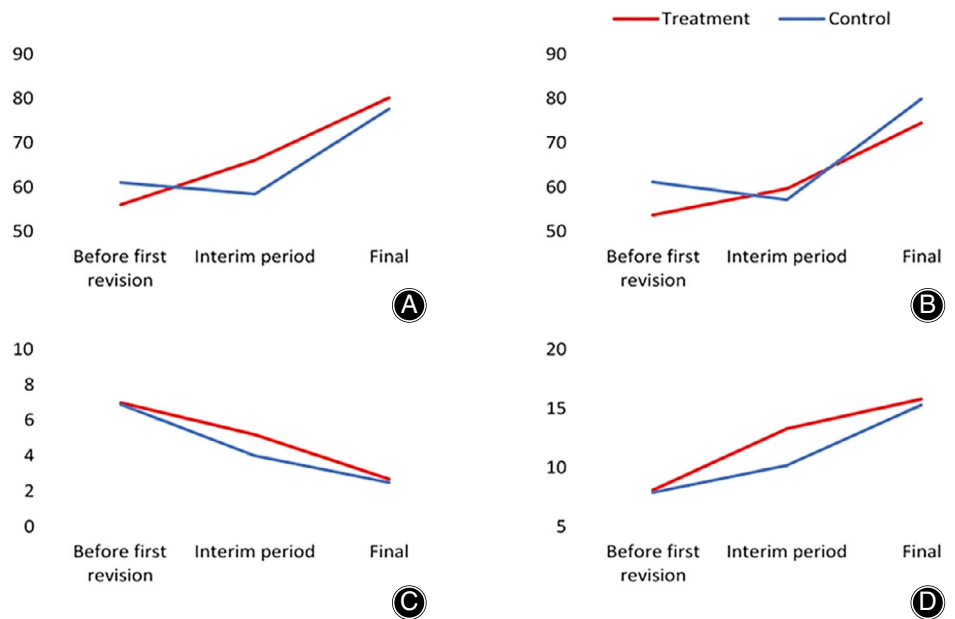


Fig. 2 Trends in hip scores across two review studies. (A) Trends in Harris hip scores (Marczak *et al.*). (B) Trends in Western Ontario and McMaster Universities Arthritis Index (Marczak *et al.*). (C) Trends in visual analog scale (Marczak *et al.*). (D) Trends in Harris hip scores (Hsieh *et al.*).

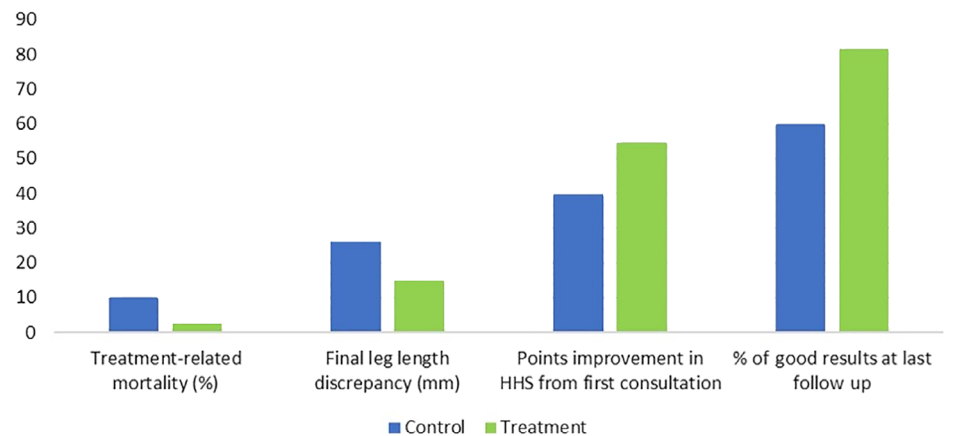


Fig. 3 Comparison of functional outcomes among control and treatment groups at final follow-up in one study (Cabrita *et al.*²⁵). HSS, Harris hip score.

the spacer group and three (6.4%) patients from the non-spacer group, while Hsieh *et al.*²³ reported complete infection control in 56 of 58 patients (96.6%) in the treatment group and 66 of 70 patients (94.3%) in the control group at final follow up. Cabrita *et al.*²⁵ also utilized microbiological culture results from intra-articular fluid samples to determine correct timing of prosthesis replantation. They reported a significantly higher failed infection cure rate of 33.3% in the control group, compared to 10.5% in the treatment group patients. Jahoda *et al.*²² reported 96.5% and 94.3% infection cure rates in the intervention and control groups, respectively. They used the criteria laid down by Tsukayama *et al.*²¹ to define successful eradication of infection after treatment.

Technical Difficulties and Complications

In three studies, the duration of the second-stage procedure was reported to be significantly greater in the control

group^{23,24,25}. In the study by Cabrita *et al.*²⁵, the mean duration of hospital stay after the first-stage surgery was 24.7 days in the treatment group against 34.6 days in the control group (P -value < 0.001). Likewise, Hsieh *et al.*²³ reported a mean hospital stay of 18.3 days vs 24.8 days in the spacer and non-spacer groups, respectively (P -value < 0.001). The reduction in mean duration of hospital stay in the treatment group reported by both of these studies was statistically significant. In addition, Cabrita *et al.*²⁵ reported a shorter mean hospital stay of 8.2 days in the treatment group against 11.7 days in the control group, as well as a shorter mean stay in the intensive care unit of 1.4 days in the treatment group against 4.1 days in the control group after the second-stage procedure. Both these differences between the two groups were statistically significant (P -value 0.004 for both).

One study reported a mean blood loss of 952 mL and a mean of 1.4 units of blood transfused during the procedure in the treatment group, compared to a mean blood loss of

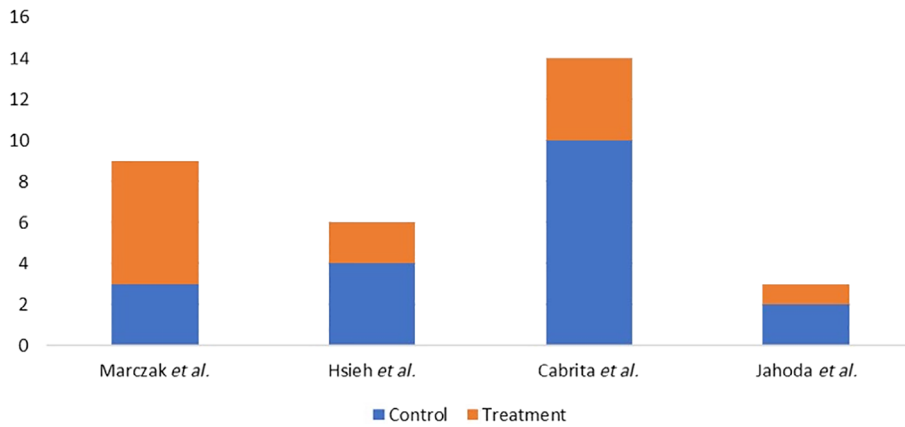


Fig. 4 Overall number of patients with recurrence of infection in treatment and control groups across the review studies.

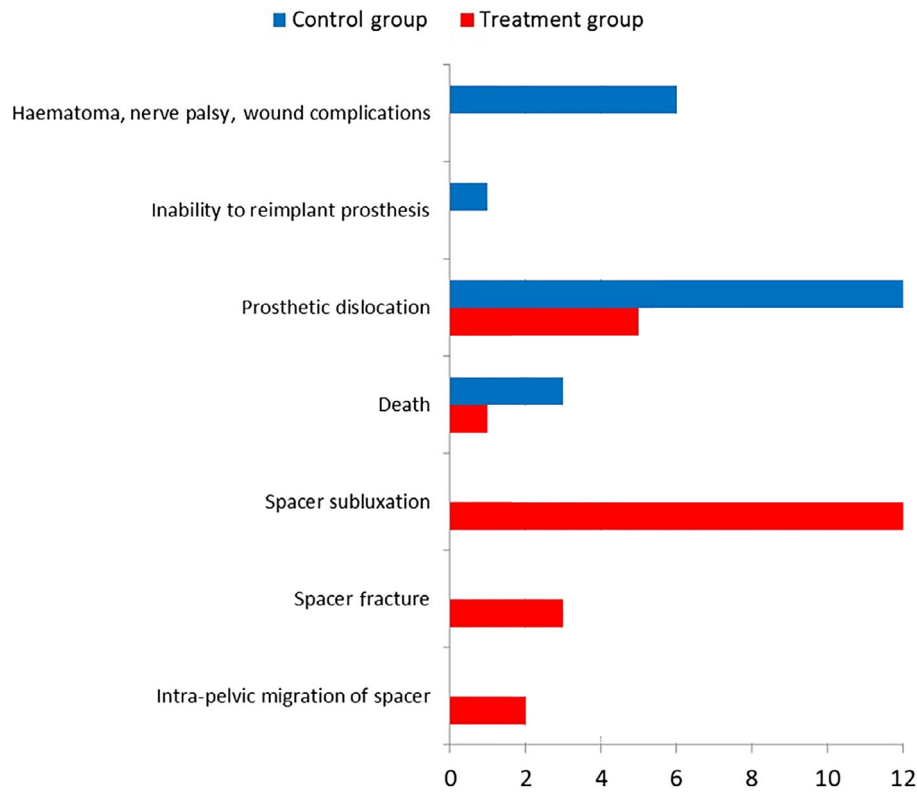


Fig. 5 Chief complications and frequency reported in treatment and control groups.

2033 mL and a mean of 3.7 units of blood transfused in the control group²³. This reduction in intraoperative blood loss and requirement for blood transfusion in the treatment group was statistically significant (P -value < 0.001 for both). Cabrita *et al.*²⁵ also reported a statistically significant lower volume of fluid drained after each stage of surgery in the spacer group (P -value 0.007 for first stage and 0.01 for second stage).

Hsieh *et al.*²³ divided the complications encountered among their patients into early and late, depending on whether these occurred during the interim period or after

final revision, respectively. Early complications encountered in the control group included hematoma and delayed wound healing in three patients, sacral pressure sores in two patients, femoral fracture at the time of replantation in one patient, and a temporary peroneal nerve palsy in one patient. Nine patients in the control group had postoperative dislocation after definitive revision surgery. In the treatment group, two patients had dislocation of the spacer, while another two had fracture of the cement spacer. All these patients were managed nonoperatively and underwent an early second-stage procedure. One patient had prosthetic dislocation in

the treatment group after second-stage surgery. Six cases of spacer subluxation were reported by Jahoda *et al.*²², while Marczak *et al.*²⁴ reported one case of spacer subluxation that did not require operative intervention, and the patient underwent a planned second-stage revision. Jahoda *et al.*²² reported four cases of postoperative dislocation after the second-stage procedure, with two each in control and treatment groups. Cabrita *et al.*²⁵ reported the death of three patients in the control group during the study; among them, one patient died from septicemia after the first stage, while two patients died due to hemorrhagic complications after the second-stage surgery. In the treatment group, one patient died due to internal injuries resulting from pelvic migration of the spacer. Three cases of spacer dislocation and one case of spacer fracture were reported. A summary of the chief complications encountered in the two groups of patients across the four studies is presented in Fig. 5.

Discussion

All four review studies reported better functional outcome at final follow up after completion of treatment in the spacer group. The average increase in HHS across three review studies from before initiation of treatment to final follow up was 36.2 points. Two review studies also reported significantly improved function in the spacer group during the interim period. This is comparable to other reports in the published literature, including Haddad *et al.*²⁶, who showed an improvement in the mean HHS from 34 points before treatment to 56 points during the spacer stage, and Chalmers *et al.*²⁷, who reported a rise in mean HHS from 58 to 71 points before and after spacer implantation; both of these studies had retrospectively assessed two-stage revision hip arthroplasty for prosthetic hip infections. In their prospective study assessing the outcome of preformed gentamicin spacers in two-stage revision hip arthroplasty, Pattyn *et al.*²⁸ reported that 46 out of 61 patients (75.4%) were able to be discharged from hospital in between the two stages. Likewise, in their systematic review of studies on antibiotic-loaded spacers in prosthetic hip infection, Anagnostakos *et al.*²⁹ reported that spacer implantation allowed patients to mobilize early after the operation and thereby paved the way for early recovery and discharge from hospital.

Within this review, Hsieh *et al.*²³ also reported that 51 out of 63 patients treated without spacers in their study were unable to walk in the interim period. These findings correlate with reports in the literature that attribute leg shortening and hip instability following a resection arthroplasty to causing problems with mobility². Hsieh *et al.*²³ also reported better outcomes in the interim period using custommade articulated spacers. This is worth noting as the use of an articulating spacer has been further reported to improve hip mobility and reduce pain during the interim period while awaiting second-stage surgery^{4,30,31}.

The overall infection cure rate across the four studies at the completion of treatment was 92.4% in the spacer

group against 87.2% in the non-spacer group. Only Marczak *et al.*²⁴ reported a higher infection recurrence rate in the spacer group compared to the non-spacer group, although this difference was not statistically significant. Elsewhere in the wider literature, similarly reliable infection control rates with spacer use have been reported. Chalmers *et al.*²⁷ reported 92% and 88% rates of infection-free prosthesis survivorship after reimplantation at 2 and 5 years follow-up respectively, following two-stage revision hip arthroplasty for prosthetic infection treated with an antibiotic-loaded spacer. Likewise, Biring *et al.*³² reported infection cure rates of 96% at a mean follow up of 12 years among 99 patients treated for chronically infected hip prosthesis with two-stage revision surgery using antibiotic-impregnated prosthesis of antibiotic-loaded acrylic cement (PROSTALAC) spacers. Better infection control with spacer use could be explained by the incorporation of thermostable antibiotics mixed with bone cement and used as part of the spacer frame, which has been shown to generate high local anti-microbial concentrations within the hip joint^{33,34}.

The overall incidence of prosthetic dislocation in the control group across the four studies was 6.5%. Similarly, other studies have also reported prosthetic dislocation to be the most commonly encountered complication following reimplantation of total hip prosthesis after Girdlestone arthroplasty^{8,35}. Within this review, surgeons were unable to attempt prosthetic reimplantation in three patients in the non-spacer group (1.6%). The technical difficulties encountered by surgeons during the second stage in surgeries without a spacer, where it is often difficult to identify bony landmarks and dissect soft tissue planes, has led to other documented failures of reimplantation^{8,36}.

In the treatment group, a subluxation or dislocation of the spacer was the most commonly recurring complication (overall incidence 7.1% across the four studies), followed by spacer fracture (1.8%) and intra-pelvic migration of the device (1.2%); in one patient, this resulted in injury to the iliac blood vessels and subsequent death of the patient. In the wider literature, incidence rates of spacer migration have not been extensively documented. Jung *et al.* reported one case of spacer protrusion out of 88 hip spacer implantations (1.1%)¹¹. It is worth mentioning that within the review, Cabrita *et al.*²⁵ attributed the unipolar nature of the spacer and the presence of preexisting acetabular weakness in the patient as the cause of the spacer migration. They recommended using articulated spacers in patients with acetabular bone weakness to avoid this complication. Elsewhere in the literature, Shen *et al.*³⁷ have also implicated unipolar cement spacers in a deficient acetabulum to be a causative factor, while Jung *et al.*¹¹ have also advocated the use of articulated hip spacers to prevent such disastrous pelvic migration.

None of the review studies reported spacer subluxation or fracture as causing any significant functional impairment, and no patient required additional surgery as a result of

these two complications. Within the studies reviewed, the causes of spacer dislocations and fractures were not discussed. Interestingly, Jahoda *et al.*²² reported one case where the decision to implant a spacer had to be abandoned during the operation itself and a resection arthroplasty was instead performed due to the presence of extensive acetabular bone defects. In another study within the review, Marczak *et al.*²⁴ clearly state that the surgeons in their study decided not to use spacers in those patients with poor acetabular bone stock, and they attribute this caveat to be responsible for the lower rate of spacer-related mechanical complications encountered in their results. A similar message has also been conveyed in the wider literature, where researchers have advocated the use of resection arthroplasty if spacer use is contraindicated due to factors such as severe acetabular bone loss, patient non-compliance, or muscular imbalance³⁸.

The use of articulated spacers was reported by one study within the review²³. This was in the form of a custom-made antibiotic-loaded cement spacer with three or more large Kirschner wires placed inside the femoral component as endoskeleton and using a cement-on-cement articulation. The authors considered this method to be simple, inexpensive, and easily reproducible. Because the spacer was fixed to bone using manual cementing, they believed that the use of these spacers could be generalized across various sizes. Elsewhere in literature, similar reports on the greater financial viability and generalizability of custom-made articulated cement spacers are available³⁸. Other studies in the literature have reported the use of prefabricated mobile spacers such as the PROSTALAC system and their advantages over custom-made spacers, such as less risk of spacer fractures, more consistent antibiotic dosing and elution, and reduced operative time spent in assembling the spacer construct^{5,30}. A cost *vs* benefit analysis for the use of either articulated spacer variant has not been reported within this review or elsewhere in the literature.

The overall incidence of spacer retention in the review was 5.8%. The cause behind spacer retention was not specified. In other reported cases of spacer retention in the literature, this has been attributed to recurring infection, poor patient health, or unwillingness of the patient to undergo another operation³⁹. While the effects of prolonged spacer retention on patient health and hip function were not reported within the review, other published studies on retained spacers within the hip have shown satisfactory outcomes^{39,40}. In particular, based on good hip function scores following the use of PROSTALAC spacers, Scharfenberger *et al.*⁴¹ have suggested its suitability for long-term retention, if required. More detailed reporting of spacer retention in future studies would be helpful in determining its impact on patient outcomes.

Strengths and Limitations

As far as the authors are aware, this is the first systematic review to be conducted comparing the treatment outcomes

following the use or non-use of temporary spacer devices in two-stage revision hip arthroplasty for prosthetic hip infection. This study has employed a robust methodology as guided by the PRISMA checklist¹³ to ensure conformity to review protocol throughout. Comparisons across matching populations and treatment protocols within each study have been undertaken, thereby increasing the validity of the results. The review has been able to generate trends in study outcomes from among the results and thereby satisfy the study objectives. The chief limitation of this review is the small number of studies that could be included. However, this can be attributed to a scarcity of relevant available literature that satisfies the inclusion criteria. Another limiting factor is the fact that the included studies differed in methodological structure. These factors have limited the review analysis to a narrative synthesis.

Implications for Future Research and Practice

Based on the findings of this study, the following recommendations can be made:

1. Given the the limited evidence available, the use of articulated hip spacer constructs with antibiotic-loaded bone cement incorporated in the spacer should be considered while performing the first stage of two-stage revision hip arthroplasty for prosthetic hip infection.
2. The benefits of a retrospective study design with consecutive sampling, where the surgeon and assessor are both blinded to study objectives, suggest that this is an appropriate design for future studies.
3. National or regional surveys should be conducted among hip surgeons to identify how many of them are confident and well-versed in the use of articulated hip spacer constructs or require to be further trained in this regard.
4. Studies on cost *vs* benefit analysis of commercially available articulated spacers should be undertaken to create evidence to support (or not) their regular use.
5. Studies on custom-made spacer constructs could be undertaken to determine their relevance as alternatives to commercially available prefabricated spacers.

Conclusion

This systematic review has demonstrated that better functional outcomes occur with the use of temporary spacer devices when used during the first stage of a planned two-stage revision hip arthroplasty for prosthetic hip infection, compared to the non-use of spacers. The use of spacers allows patients to ambulate early after the first-stage operation, facilitates early discharge from hospital, and provides better overall hip function at the end of treatment. The risks of increased blood loss during the prosthetic reimplantation and of postoperative dislocation are significantly lowered with spacer use. The use of antibiotic-loaded cement in the spacer construct enables good, sustained infection control rates not less than that offered by a resection arthroplasty

during the interim period. Articulated spacers, such as PROSTALAC and other custom-made, cost-effective constructs, provide better function and improved spacer longevity, and they reduce the risk of intra-pelvic spacer migration. Their use could also allow spacers to be retained in unforeseen circumstances when a second surgery for prosthetic reimplantation is no longer feasible or desired. However, in certain situations where spacer use is contraindicated by patient non-compliance, severe acetabular or femoral bone deficiency or muscular imbalance, performing a resection arthroplasty is still the most reasonable option.

Acknowledgments

The authors acknowledge the help and support received from the faculty and staff at Edge Hill University, Ormskirk, who were always available for guidance whenever approached. They also acknowledge the help received from the staff at Salford Royal NHS Foundation Trust Library in gaining access to full-text articles and other research material for the Review. The authors would also like to thank Mr Tomas Jurasek, who provided his valuable service in translating one of the review articles from Czech to English.

References

- Hanssen AD, Osmon DR. Evaluation of a staging system for infected hip arthroplasty. *Clin Orthop Relat Res*, 2002, 403: 16–22.
- Fink B. Revision of late periprosthetic infections of total hip endoprostheses: pros and cons of different concepts. *Int J Med Sci*, 2009, 6: 287–295.
- Girdlestone GR. Acute pyogenic arthritis of the hip: an operation giving free access and effective drainage. *Lancet*, 1943, 241: 419–421.
- Takahira N, Itoman M, Higashi K, Uchiyama K, Miyabe M, Naruse K. Treatment outcome of two-stage revision total hip arthroplasty for infected hip arthroplasty using antibiotic-impregnated cement spacer. *J Orthop Sci*, 2003, 8: 26–31.
- Sukeik M, Haddad FS. Two-stage procedure in the treatment of late chronic hip infections – spacer implantation. *Int J Med Sci*, 2009, 6: 253.
- Bertazzoni Minelli E, Benini A, Magnan B, Bartolozzi P. Release of gentamicin and vancomycin from temporary human hip spacers in two-stage revision of infected arthroplasty. *J Antimicrob Chemother*, 2004, 53: 329–334.
- Burnett RS, Kelly MA, Hanssen AD, Barrack RL. Technique and timing of two-stage exchange for infection in TKA. *Clin Orthop Relat Res*, 2007, 464: 164–178.
- Charlton WP, Hozack WJ, Teloken MA, Rao R, Bissett GA. Complications associated with reimplantation after girdlestone arthroplasty. *Clin Orthop Relat Res*, 2003, 407: 119–126.
- Macheras GA, Koutsostathis SD, Kateros K, Papadakis S, Anastasopoulos P. A two stage re-implantation protocol for the treatment of deep periprosthetic hip infection. Mid to long-term results. *Hip Int*, 2012, 22: 54–61.
- Leunig M, Chosa E, Speck M, Ganz R. A cement spacer for two-stage revision of infected implants of the hip joint. *Int Orthop*, 1998, 22: 209–214.
- Jung J, Schmid NV, Kelm J, Schmitt E, Anagnostakos K. Complications after spacer implantation in the treatment of hip joint infections. *Int J Med Sci*, 2009, 6: 265.
- Disch AC, Matziolis G, Perka C. Two-stage operative strategy without local antibiotic treatment for infected hip arthroplasty: clinical and radiological outcome. *Arch Orthop Trauma Surg*, 2007, 127: 691–697.
- Moher D, Liberati A, Tetzlaff J, Altman DG. Preferred reporting items for systematic reviews and meta-analyses: the PRISMA statement. *Int J Surg*, 2010, 8: 336–341.
- O'Connor D, Green S, Higgins JPT. Defining the review question and developing criteria for including studies. In: JPT H, Green S, eds. *Cochrane Handbook for Systematic Reviews of Interventions*. Chichester, UK: John Wiley & Sons, 2008.
- Critical Appraisal Skills Programme. CASP Cohort Checklist. (2018). Available from: www.casp-uk.net (accessed 31 July 2019).
- Critical Appraisal Skills Programme. CASP Randomized Control Trial Checklist, 2018. Available from: www.casp-uk.net (accessed 31 July 2019).
- Harris WH. Traumatic arthritis of the hip after dislocation and acetabular fractures: an end-result study using a new method of result evaluation. *J Bone Joint Surg Am*, 1969, 51: 737–755.
- d'Aubigne RM, Postel M. Functional results of hip arthroplasty with acrylic prosthesis. *J Bone Joint Surg Am*, 1954, 35: 451–475.
- Bellamy N, Buchanan WW, Goldsmith CH, Campbell J, Stitt LW. Validation study of WOMAC: a health status instrument for measuring clinically important patient relevant outcomes to antirheumatic drug therapy in patients with osteoarthritis of the hip or knee. *J Rheumatol*, 1988, 15: 1833–1840.
- Crichton N. Visual analogue scale (VAS). *J Clin Nurs*, 2001, 10: 706.
- Tsukayama DT, Estrada R, Gustilo RB. Infection after total hip arthroplasty. A study of the treatment of one hundred and six infections. *J Bone Joint Surg Am*, 1996, 78: 512–523.
- Jahoda D, Sosna A, Landor I, Vavrik P, Pokorný D, Hudec T. Two-stage reimplantation using spacers - the method of choice in treatment of hip joint prosthesis-related infections. Comparison with methods used from 1979 to 1998. *Acta Chir Orthop Traumatol Cech*, 2003, 70: 17–24.
- Hsieh PH, Shih CH, Chang YH, Lee MS, Shih HN, Yang WE. Two-stage revision hip arthroplasty for infection: comparison between the interim use of antibiotic-loaded cement beads and a spacer prosthesis. *J Bone Joint Surg Am*, 2004, 86: 1989–1997.
- Marczak D, Synder M, Sibiński M, Polgaj M, Dudka J, Kowalczewski J. Two stage revision hip arthroplasty in periprosthetic joint infection. Comparison study: with or without the use of a spacer. *Int Orthop*, 2017, 41: 2253–2258.
- Cabrera HB, Croci AT, Camargo OP, Lima AL. Prospective study of the treatment of infected hip arthroplasties with or without the use of an antibiotic-loaded cement spacer. *Clinics*, 2007, 62: 99–108.
- Haddad FS, Masri BA, Garbuz DS, Duncan CP. The treatment of the infected hip replacement: the complex case. *Clin Orthop Relat Res*, 1999, 369: 144–156.
- Chalmers BP, Mabry TM, Abdel MP, Berry DJ, Hanssen AD, Perry KI. Two-stage revision total hip arthroplasty with a specific articulating antibiotic spacer design: reliable periprosthetic joint infection eradication and functional improvement. *J Arthroplasty*, 2018, 33: 3746–3753.
- Pattyn C, De Geest T, Ackerman P, Audenaert E. Prefabricated gentamicin spacers in two-stage revision hip arthroplasty: functional results and complications. *Int Orthop*, 2011, 35: 1471–1476.
- Anagnostakos K, Fürst O, Kelm J. Antibiotic-impregnated PMMA hip spacers: current status. *Acta Orthop*, 2006, 77: 628–637.
- Duncan CP, Beauchamp C. A temporary antibiotic-loaded joint replacement system for management of complex infections involving the hip. *Orthop Clin North Am*, 1993, 24: 751–759.
- Koo KH, Yang JW, Cho SH, et al. Impregnation of vancomycin, gentamicin, and cefotaxime in a cement spacer for two-stage cementless reconstruction in infected total hip arthroplasty. *J Arthroplasty*, 2001, 16: 882–892.
- Biring GS, Kostamo T, Garbuz DS, Masri BA, Duncan CP. Two-stage revision arthroplasty of the hip for infection using an interim articulated Prostalac hip spacer: a 10-to 15-year follow-up study. *J Bone Joint Surg [Br]*, 2009, 91: 1431–1437.
- Masri BA, Duncan CP, Beauchamp CP. Long-term elution of antibiotics from bone-cement: an in vivo study using the prosthesis of antibiotic-loaded acrylic cement (PROSTALAC) system. *J Arthroplasty*, 1998, 13: 331–338.
- Isiklar ZU, Demirörs H, Akpinar S, Tandogan RN, Alparslan M. Two-stage treatment of chronic staphylococcal orthopaedic implant-related infections using vancomycin impregnated PMMA spacer and rifampicin containing antibiotic protocol. *Bull Hosp Jt Dis*, 1999, 58: 79–85.
- Ikebe S, Sonohata M, Kitajima M, Kawano S, Mawatari M. Total hip arthroplasty following Girdlestone arthroplasty. *J Orthop Sci*, 2018, 23: 532–537.
- Fitzgerald RH Jr. Total hip arthroplasty sepsis. Prevention and diagnosis. *Orthop Clin North Am*, 1992, 23: 259–264.
- Shen DL, Yu CT, Chang IL, Chen SJ. Iliac vessel injury by a cement spacer: report of a case. *Int Surg*, 2007, 92: 78–81.
- Anagnostakos K, Jung J, Schmid NV, Schmitt E, Kelm J. Mechanical complications and reconstruction strategies at the site of hip spacer implantation. *Int J Med Sci*, 2009, 6: 274.
- Choi HR, Freiberg AA, Malchau H, Rubash HE, Kwon YM. The fate of unplanned retention of prosthetic articulating spacers for infected total hip and total knee arthroplasty. *J Arthroplasty*, 2014, 29: 690–693.
- Hofmann AA, Goldberg TD, Tanner AM, Cook TM. Ten-year experience using an articulating antibiotic cement hip spacer for the treatment of chronically infected total hip. *J Arthroplasty*, 2005, 20: 874–879.
- Scharfenberger A, Clark M, Lavoie G, O'Connor G, Masson E, Beaupre L. Treatment of an infected total hip replacement with the PROSTALAC system. Part 2: Health-related quality of life and function with the PROSTALAC implant in situ. *Can J Surg*, 2007, 50: 29.

APPENDIX 1

Search strategy employed across the Medline, PubMed, and EMBASE databases for purposes of this review

Current search strategy: MCH						
	Database(s)	Search Term				
<input type="checkbox"/> 1	Medline	exp "ARTHROPLASTY, REPLACEMENT, HIP"/	View Results (24,398)	Edit		
<input type="checkbox"/> 2	Medline	(revision).ti,ab	View Results (72,650)	Edit		
<input type="checkbox"/> 3	Medline	exp INFECTION/	View Results (1,359,004)	Edit		
<input type="checkbox"/> 4	Medline	(1 AND 2 AND 3)	View Results (884)			
<input type="checkbox"/> 5	Medline	(spacer).ti,ab	View Results (27,366)	Edit		
<input type="checkbox"/> 6	Medline	("hip spacer").ti,ab	View Results (30)	Edit		
<input type="checkbox"/> 7	Medline	(5 OR 6)	View Results (27,366)			
<input type="checkbox"/> 8	Medline	(4 AND 7)	View Results (123)			
<input type="checkbox"/> 9	PubMed	(hip arthroplasty).ti,ab	View Results (20,144)	Edit		
<input type="checkbox"/> 10	PubMed	(revision).ti,ab	View Results (68,421)	Edit		
<input type="checkbox"/> 11	PubMed	(infection).ti,ab	View Results (1,609,763)	Edit		
<input type="checkbox"/> 12	PubMed	(9 AND 10 AND 11)	View Results (1,418)			
<input type="checkbox"/> 13	PubMed	(spacer).ti,ab	View Results (31,951)	Edit		
<input type="checkbox"/> 14	PubMed	(12 AND 13)	View Results (103)			
<input type="checkbox"/> 15	EMBASE	(infection).ti,ab	View Results (1,255,462)	Edit		
<input type="checkbox"/> 16	EMBASE	exp "HIP ARTHROPLASTY"/	View Results (21,401)	Edit		
<input type="checkbox"/> 17	EMBASE	exp "HIP REPLACEMENT"/	View Results (2,779)	Edit		
<input type="checkbox"/> 18	EMBASE	exp "TWO-STAGE REVISION"/	View Results (180)	Edit		
<input type="checkbox"/> 19	EMBASE	exp "REVISION ARTHROPLASTY"/	View Results (1,403)	Edit		
<input type="checkbox"/> 20	EMBASE	(16 OR 17)	View Results (21,401)			
<input type="checkbox"/> 21	EMBASE	(18 OR 19)	View Results (1,403)			
<input type="checkbox"/> 22	EMBASE	(20 AND 21)	View Results (282)			
<input type="checkbox"/> 23	EMBASE	(15 AND 22)	View Results (103)			
<input type="checkbox"/> 24	EMBASE	(spacer).ti,ab	View Results (28,376)	Edit		
<input type="checkbox"/> 25	EMBASE	(23 AND 24)	View Results (13)			

All

 AND
 OR