

CASE REPORT

doi: 10.5455/medarch.2017.71.449-452

MED ARCH. 2017 DEC; 71(6): 449-452

RECEIVED: OCT 29, 2017 | ACCEPTED: NOV 28, 2017

¹Clinic for Heart, Blood Vessel and Rheumatic Diseases. University Clinical Center Sarajevo, Rajevo, Bosnia and Herzegovina

²Clinic for Cardiovascular Surgery, University Clinical Center Sarajevo, Sarajevo, Bosnia and Herzegovina

Corresponding author: Enisa Hodzic, MD, PhD. Clinic for Heart, Blood Vessel and Rheumatic Diseases. University Clinical Center Sarajevo, Rajevo, Bosnia and Herzegovina. E-mail: hodzice@bih.net.ba

Gigantic Thrombus of the Left Atrium in Mitral Stenosis

Enisa Hodzic¹, Nermir Granov²

ABSTRACT

Introduction: Excess dilatation of the left atrium >65 mm is known in the literature as gigantic atrium. This dilation is most commonly encountered in the mitral insufficiency of rheumatic etiology, but also in severe prolapses of the mitral valve, permanent atrial fibrillation, and at the left right shunt with cardiac insufficiency. **Case report:** In this paper is presented a case study of echocardiographically verified giant thrombus in left atrium in a 50 years old female patient aged 50 hospitalized because of tiredness, choking, heartburn and urinary tract symptoms. The patient had rheumatic fever at age of 18 years. At age of 35, she was diagnosed with mitral stenosis. In permanent atrial fibrillation with anamnestic data on the previous cerebrovascular stroke (CVI) and the repeated transitional ischemic seizures. Echocardiographic examination confirmed severe mitral stenosis with moderate aortic insufficiency and gigantic left atrium (LA) with gigantic thrombus. Invasive diagnostics were indicated and performed, followed by an acute cardiac surgery including left atrial thrombectomy and implantation of the mechanical aortic and mitral valve. The surgical course was without complications. **Conclusion:** On eleven postoperative day, after mobilization, the patient experiences stroke with motor aphasia. She was clinically recovering from stroke consequences, and remains cardiologically stable.

Keywords: mitral stenosis, gigantic left atrium, gigantic thrombus, atrial fibrillation, ICV, thrombectomy.

1. INTRODUCTION

Excess dilatation of the left atrium >65 mm is known in the literature as gigantic atrium (1). This dilation is most commonly encountered in the mitral insufficiency of rheumatic etiology, but also in severe prolapses of the mitral valve, permanent atrial fibrillation, and at the left right shunt with cardiac insufficiency (1-3). Most commonly, it is accompanied by more severe rheumatic mitral defects, followed by a left and right pressure and/or volume load. Atrial dilation is actually a compensatory mechanism with increased intracavitary pressure to reduce pulmonary failure and prevent pulmonary hypertension and pulmonary edema (4). Chronic mitral valve disease is not always associated with the development of gigantic thrombus in LA. It is encountered in about 19% of cases of mitral insufficiency (5).

2. CASE REPORT

Female patient aged 50 years, hospitalized due to increased tiredness, choking and heartburn. Symptoms started six months ago. For the last couple of weeks have intensified sweating, without fever, with loss of appetite and frequent urination.

Symptoms are more pronounced during night. For the last three years patient have high blood pressure, with occasional hypertensive crises. At the age of 18, she had rheumatic fever. At age 35, she was diagnosed with mitral stenosis, and during the same year, after the grade III burns, during the hospitalization, she experienced acute cerebrovascular insult. Later, in a couple of occasions, transitory ischemic insult. Father died of the stroke. The therapy, until hospitalization, included enalapril, medigoxin, metoprolol, furosemide and oral anticoagulants, without regular INR control.

Physical examination showed no signs of pulmonary stasis. The action of the heart is tachyarrhythmia, the tones clear, the strange diastolic noise of stroke and the Erb's point. Blood pressure at admission 190/110 mmHg, hearth rate 110/min. Physical finding on the abdomen is normal. Extremities mobile, without edema, preserved peripheral arterial pulses.

From laboratory findings: he-mogram, blood glucose, minerals, nitrogenous substances, bilirubin, transaminase and lipid status within the limits of reference values as well

© 2017 Enisa Hodzic, Nermir Granov

This is an Open Access article distributed under the terms of the Creative Commons Attribution Non-Commercial License (<http://creativecommons.org/licenses/by-nc/4.0/>) which permits unrestricted non-commercial use, distribution, and reproduction in any medium, provided the original work is properly cited.

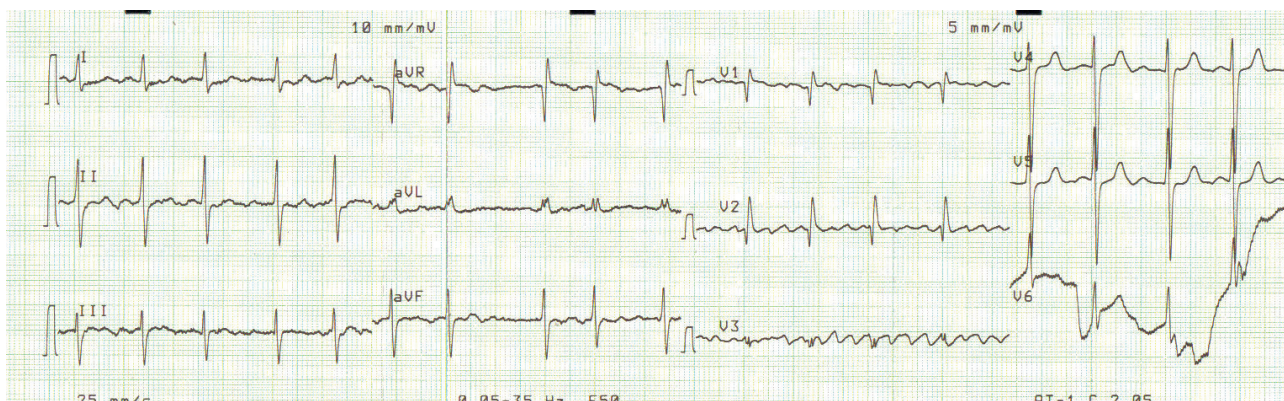


Figure 1. ECG finding of permanent atrial fibrillation.

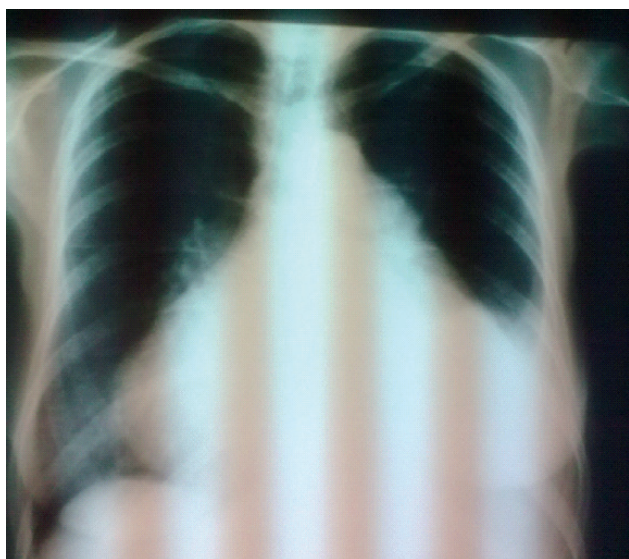

Figure 2. X-ray of the heart and lungs; a markedly enlarged cardiac shadow of the mitral configuration

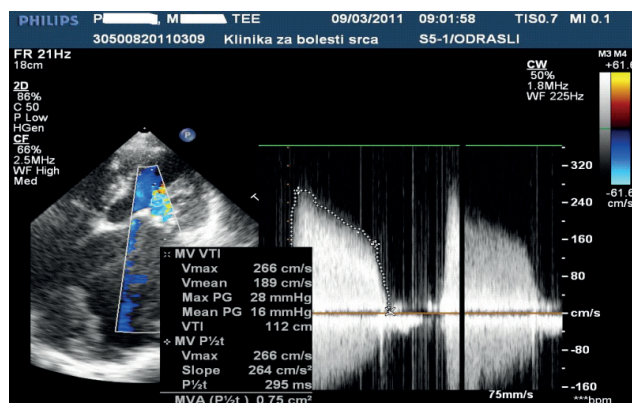
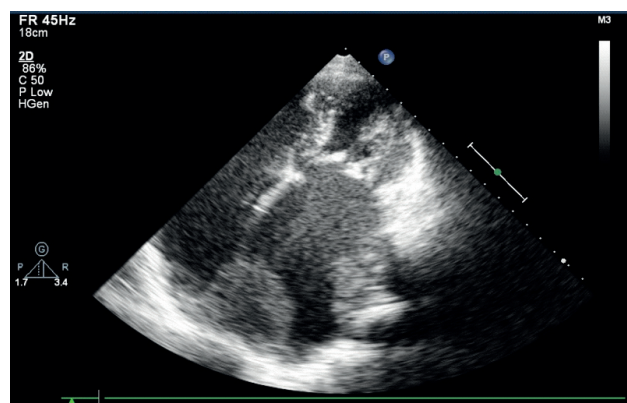


Figure 3. Echocardiographic presentation of intracavitary mass in left atrium with severe mitral stenosis

shows intracavitary masses, characterized by thrombus, beside septal wall measuring 4.7x3.6 cm, and along the left wall of the left atrium of 7x5.5 cm, with a spontaneous echo contrast inside the left atrium. The mitral veins thickened and partially calcified with the “doming” phenomenon of the frontal mitral cusp and hemodynamic signs of severe mitral stenosis (area of the mitral inflow 0.75 cm, peak pressure gradient 28 mmHg, mean pressure gradient 16 mmHg). Aortic valve truncated, edges of hemogenic veins, with moderate aortic insufficiency, without signs of stenosis. Mild to moderate tricuspid regurgitation. RVSP elevated, and amounts to about 60 mm Hg, and is in favor of heavier pulmonary hypertension. Kinetics of LV walls are preserved. Correct systolic function of the LV with EF about 54%.

It is pharmacologically treated with the anticoagulant therapy with enoxaparin with acetylsalicylic acid, medigoxin, metoprolol, lisinopril, amlodipine, furosemide and antibiotic treatment of Escherichia coli in urine with trimethoprim sulfamethoxazole (according to resistance



as thyroid hormone status. Protein levels, mild albumin globulin inversion with a slight increase of β_2 globulin and γ globulin. Urine blurred, 0.5g protein, 20-25 white blood cell 8-10 erythrocytes, amorphous urate and plenty of bacteria. Isolated from Escherichia coli 10^5 in urine. Staphylococcus aureus isolated from the nose swab.

ECG at admission: absolute ventricle arrhythmia based on atrial fibrillation, average ventricle frequency about 110 / min., leftgram.

Echocardiographic finding: an enlarged left atrium measuring 6.9x7.5x9.7 cm in diameter. The left atrium

test). Patient has undergone heart catheterization. The result of cardiac characterization: a coronagraphically normal finding, ventriculography was not performed. Suggested cardiac surgery. It is decided to undergo an emergency surgery to perform left atrial thrombectomy with implantation of artificial mechanical mitral and aortic valves.

Surgically is removed the gigantic thrombotic mass of a cauliflower appearance. The surgery has gone smoothly. The tenth postoperative day experiences a repeat cere-

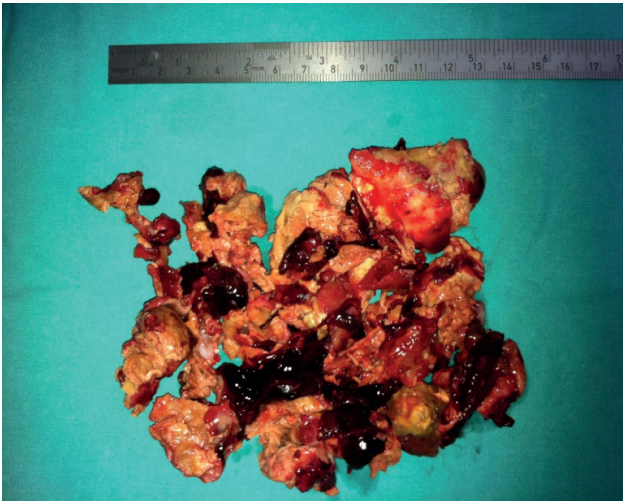


Figure 4. Gigantic cauliflower like thrombus LA

brovascular insult from which it is successfully recovering and remains cardiologically stable.

The pathohistological finding confirmed the thrombotic nature of the echocardiographed verified intracavitary mass, surgically removed from the left atrium.

3. DISCUSSION

The cause of left ventricular dilatation is not only an increase in intracavitary pressure but also a consequence of rheumatic carditis with chronic inflammation and myocardial fibrosis (2, 3). Such dilation and atrophic fibrosis are the basis for the formation of atrial fibrillation which is the most common cause of ischemic cerebrovascular incidents, and in itself causes further dilation of LA. Patients with severe mitral stenosis and atrial fibrillation, as shown, have an increased risk and require adequate anticoagulant treatment. In patients with mitral stenosis, the level of fibrinopeptide A, thrombin antithrombin III complex and VonWillebrand factor in the left atrium are increased (7). The coagulation system in a patient with mitral stenosis and dilatation of LA has been shown to be more active in the proper application and control of anticoagulant therapy attributed to the influence of local factors and myocardial infarction. The dilation of LA is associated with the blood trauma and the formation of a thrombus, and the risk of thromboembolism increases with the enlargement of the left atrial dimension, independent of the administration of anticoagulant (8). The incidence of the left ventricular thrombus in a patient with mitral stenosis and atrial fibrillation varies between 7 and 38% (5,9). The differential diagnosis of intracavitary masses, particularly LA, may be quite wide and can be a case of primary intracardial tumor (usually myxoma), thrombus, intracardial cyst or vegetation. The diagnostic method of choice is echocardiography, trans aortal or thalassophonean (TTE or TEE). High specificity (98.8%) and acceptable sensitivity (58.8%) of these methods were demonstrated (10).

Our patient had an earlier cerebrovascular insult, with a postoperative cerebrovascular incident. In the patient, there is a dilated gigantic left atrium, atrial fibrillation so the mechanic mitral and aortic valve are implanted,

therefore there are several risk factors associated with the postoperative course after the previous thrombectomy of giant thrombus. Post-operative intravenous administration of unbound heparin is recommended during the first 24 hours after surgery and then early introduction of oral anticoagulants after implantation of the valve with an individual risk assessment of bleeding (11). Heparin is excluded from the therapy after achieving INR therapeutic values (2.5-3.5).

Another risk factor in the described case is the previous urinary tract infection with *Escherichia coli* which could be the cause of bacteremia and the emergence of such cauliflower thrombus as described in the literature, and it is recommended, in addition to the pathohistological and bacteriological analysis of the thrombus, that is, if the preoperative isolator of the infection is necessary target antibiotic treatment (12-14). As causes of infected thrombus in literature, besides *Escherichia coli* also referred to as *Coxiella burnetii*, *Listeria monocytogenes*, *Aspergillus fumigatus* and other pathogens (15). It can be assumed that infection and inflammation in an already existing rheumatic gigantic left atrium can be a trigger for the left atrium gigantic thrombus.

4. CONCLUSION

In the patient, postoperative pressure reduction in the left atrium and pulmonary arterial pressure lead to reduction of problem of subjective sense of shortness of breath and fatigue, and the patient was postoperatively, after implantation of mechanical valves, with residual permanent atrial fibrillation treated with oral anticoagulants (vitamin K antagonists) with regular cardiologic supervision.

- **Disclosure:** The work was not sponsored, nor was financial or any other non-medical interest involved during preparation of this article.

REFERENCES

1. Plaschkes J, Broman JB, Mercin G, Milwidsky H. Giant left atrium in rheumatic heart disease: a report of 18 cases treated by mitral valve replacement. *Ann Surg.* 1971; 174: 194-201. doi: 10.1097/00000658-197108000-00004
2. Hurst W. Memories of patients with a giant left atrium. *Circulation.* 2001; 104: 2630-1. doi: 10.1161/hc4701.100775.
3. Schwammenthal F, Vered Z, Agranat O, Kaplinsky E, Rabinowitz B, Feinberg MS. Impact of atrioventricular compliance on pulmonary artery pressure in mitral stenosis: an exercise echocardiographic study. *Circulation.* 2000; 102: 2378-84. doi: 10.1161/01.CIR.102.19.2378.
4. Kawazoe K, Beppu S, Takahara Y, Nakajima N, Tanaka K, Ichinashi K, Fujita T, Manabe H. Surgical treatment of giant left atrium combined with mitral valvular disease. Plication procedure for reduction of compression to the left ventricle, bronchus, and pulmonary parenchyma. *J Thorac Cardiovasc Surg.* 1983; 85: 885-92.
5. Piccoli GP, Massini C, Di Fusanio G, Rallerini I, Lacobone G. Giant left atrium and mitral valve disease: early and late results of surgical treatment in 40 cases. *J Cardiovasc Surg (Torino)* 1984; 25: 328-36.
6. <http://www.msd-prirucnici.placebo.hr/msd-prirucnik/kardi>

- ologija/aritmije-i-poremecaji-provodjenja/fibrilacija-atriza Accessed: September 05th, 2017.
7. Ates M, Sensoz Y, Abay G, Akcar M. Giant left atrium with rheumatic mitral stenosis. *Tex Heart Inst J.* 2006; 33(3): 389-91.
 8. Sanfalippo A, Abascal V, Sheehan M, Oertel LB, Harrigan P, Hughes RA, Weyman AE. Atrial enlargement as a consequence of atrial fibrillation. *Circulation.* 1990; 82: 792-7. doi: 10.1161/01.CIR.82.3.792.
 9. Funk M, Perez M, Santana O. Asymptomatic giant left atrium. *Clin Cardiol.* 2010; 33: E104-E105. doi: 10.1002/clc.20736.
 10. Shrestha NK, Moreno FL, Narciso FV, Torres L, Calleja HB. Two-dimensional echocardiographic diagnosis of left-atrial thrombus in rheumatic heart diseases. A clinicopathologic study. *Circulation.* 1983; 67: 341-7.
 11. Ageno W, Turpie AG, Steidl L, Ambrosini F, Cattaneo R, Codari RL, Nardo B, Venco A. Comparison of a daily fixed 2.5-mg warfarin dose with a 5-mg, international normalized ratio adjusted, warfarin dose initially following heart valve replacement. *Am J Cardiol.* 2001; 88: 40-4. doi: 10.1016/S0002-9149(01)01582-X.
 12. Panagiotis D, Antonios R, Efstratios NK, Dimitrios Z, Panagiotis H, Christos P, Christina B, Konstantinos B. Left atrial giant thrombus infected by *Escherichia Coli*. Case report *thorac Surg.* 2008; 3: 18.
 13. Ogata C, Nakatani S, Yasumura Y, Kitakaze M, Yamagishi M. Cauliflower-like giant left atrial thrombus successfully treated by anticoagulants without systemic complication: a case-report. *J Cardiol.* 2003; 41: 291-5.
 14. Ruiz MF, Medrano FL, Navas FA, Aguado JM. *Coxiella burnetii* infection of left atrial thrombus mimicking an atrial myxoma. *International Journal of Infectious Diseases.* 2010 Sep; 14(Supl. 3): e319-e321.
 15. Segura J, Anguita M, Vivancos R, Franco M, Romo E, Suárez de Lezo J. et al. [*Listeria monocytogenes* endocarditis in a patient with mitral prosthesis, left auricular thrombus and adenocarcinoma of the colon]. *Rev Esp Cardiol.* 1992; 45: 483-5.