

The effect of pelvic tilt and cam on hip range of motion in young elite skiers and nonathletes

Anna Swärd Aminoff¹

Cecilia Agnvall^{2,3}

Carl Todd¹

Páll Jónasson⁴

Mikael Sansone¹

Olof Thoreson¹

Leif Swärd¹

Jon Karlsson¹

Adad Baranto¹

¹Department of Orthopaedics, Institute of Clinical Sciences at Sahlgrenska Academy, University of Gothenburg, and Sahlgrenska University Hospital, Gothenburg, Sweden; ²Sports Medicine Åre, Åre, Sweden; ³Åre Ski Academy, Åre, Sweden; ⁴Orkuhúsið Orthopedic Clinic, Reykjavik, Iceland

Background: Current knowledge of the effect of changes in posture and the way cam morphology of the hip joint may affect hip range of motion (ROM) is limited.

Purpose: To determine the effect of changes in pelvic tilt (PT) on hip ROM and with/without the presence of cam.

Study design: This was a cross-sectional study.

Materials and methods: The hip ROM of 87 subjects (n=61 young elite skiers, n=26 nonathletes) was examined using a goniometer, in three different seated postures (flexed, neutral, and extended). The hips of the subjects were further subgrouped into cam and no-cam morphology, based on the magnetic resonance imaging findings in the hips.

Results: There was a significant correlation between the hip ROM and the seated posture in both extended and flexed postures compared with the neutral posture. There was a significant decrease in internal hip rotation when the subjects sat with an extended posture with maximum anterior PT ($p < 0.0001$). There was a significant increase in internal hip rotation when the subjects sat with a flexed posture with maximum posterior PT ($p < 0.001$). External rotation was significantly decreased in an extended posture with maximum anterior PT ($p < 0.0001$), but there was no difference in flexed posture with maximum posterior PT. The hips with cam morphology had reduced internal hip rotation in all three positions, but they responded to the changes in position in a similar manner to hips without cam morphology.

Conclusion: Dynamic changes in PT significantly influence hip ROM in young people, independent of cam or no-cam morphology.

Keywords: hip, cross-sectional studies, rotation, hip joint, range of motion (articular), pelvis, posture, magnetic resonance imaging

Introduction

Femoroacetabular impingement syndrome (FAIS) is defined as a combination of symptoms, clinical signs, and imaging findings (abnormal morphology).¹ The abnormal morphology of FAIS can be divided into two categories, occurring alone or as a combination of both: cam (femoral based) and pincer (acetabular based).²⁻⁵ Cam morphology refers to a less spherical femoral head. A measure that quantifies this sphericity is the α -angle; the larger the α -angle, the less the sphericity, and in previous studies a threshold of $>55^\circ$ has been considered clinically relevant (Figure 1).⁶⁻⁹ The mechanism of cam-type impingement is a collision between the abnormally formed femoral neck/head (cam) and the acetabular margin during hip flexion and internal rotation of the hip.⁴ FAIS has been associated with reduced internal rotation of the hip

Correspondence: Anna Swärd Aminoff
Åre Hälsocentral, Box 25, SE-830 14 Åre,
Sweden
Tel +46 647 166 00
Fax +46 647 166 02
Email a.m.k.sward@gmail.com

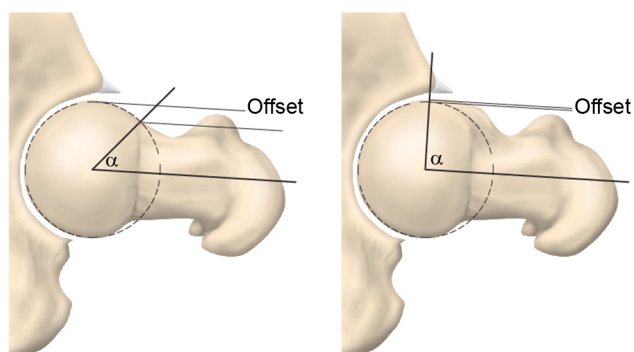


Figure 1 The α -angle is used to define the presence of cam morphology and, in this study, a threshold of $>55^\circ$ has been considered relevant.

in 90° of flexion, reduced passive hip flexion, and a positive impingement test.^{3,10–12}

Hip range of motion (ROM) is affected by many parameters such as age, pain, degenerative changes, and hip morphology.^{12–14} Skiing, both Mogul and Alpine, is a sport that exposes the body to great forces (high speed and G-forces).^{15–17} The hips and spine act as important dampers for these forces and are placed in vulnerable positions in both flexion and extension. There is a constant shift in the motion of the hips, from extended to an almost maximally flexed position. In Mogul skiing, acrobatic jumps also lead to high forces that affect the hips and spine when landing. Force transfer is dependent on adequate ROM, where joints of adjacent segments interact and their positions affect each other.

Ross et al demonstrated in patients with FAIS, using three-dimensional models of the hips from computed tomographic scans, that an increase in anterior pelvic tilt (PT) resulted in a significant decrease in internal hip rotation and an increase in posterior PT resulted in a significant increase in internal hip rotation.¹⁸ No previous studies, that we are aware of, describe how hip ROM is clinically affected by posture; this study therefore focuses on how hip ROM is affected by posture assessed by clinical measurements.

The purpose of the present study is to 1) investigate how different postural positions and PT affect hip ROM, 2) investigate whether there is a difference in response to these dynamic changes between hips with a magnetic resonance imaging (MRI)-verified α -angle $\geq 55^\circ$ (cam morphology) and hips with an α -angle $< 55^\circ$ (no-cam morphology), and 3) validate the study method of MRI and goniometer examinations.

Materials and methods

All the students attending the Åre Ski Academy (grades 1–4, $n=76$), elite skiers between 16 and 20 years of age of both

genders, were invited, both orally and in writing, to participate in this cross-sectional study.

To recruit nonathletes, two of the authors visited several high schools and presented the project orally in class. The nonathletes were included in the study to cover different aspects of society. Written information was also handed out. The invited nonathletes were all first-year high-school pupils, of both genders, and lived in the same geographical area as the skiers.

Seventy-five skiers and 27 nonathletes agreed to participate in the present study.

The exclusion criteria for both groups were previously diagnosed hip, spine, or pelvic disease, anomalies, and previous surgery on the hips, spine, or pelvis (Figure 2).

The MRI examinations were performed at the Radiographic Department, Östersund Hospital, Sweden, and clinical testing was carried out at the Åre Ski Academy and at the Orthopedic Department, Östersund Hospital, Sweden.

Participation was completely voluntary and the participants could withdraw at any time. Written informed consent was given by all the individuals and, for participants younger than 18 years, written informed consent was also obtained from their parents.

The present study was approved by the Regional Ethical Review Board at Sahlgrenska Academy, Gothenburg University, Gothenburg, Sweden (ID number: 692-13).

The subjects in the images in the present study are identifiable and therefore written informed consent for publishing the images was obtained prior to publication.

MRI examination

All subjects underwent MRI on both hips without contrast. The MRI equipment was a GE Optima 450 Wide 1.5T (GE Healthcare Bio-Sciences Corp, Piscataway, NJ, USA), at Östersund Hospital, Sweden. Cor T2 Fat Sat and Ax 3D Cube sequences were obtained at an angle on the femoral neck using a coil surface of HD 8 Channel Cardiac Array (GE Healthcare Bio-Sciences Corp). The α -angle was measured on the superior half of the femoral head. Seven measurements, from 9 o'clock to 3 o'clock (180°), were used to determine the morphological features of the femoral head-neck junction (Figures 3 and 4).⁴ Measurement of the α -angle was performed according to Nötzli et al.¹⁹ The α -angle was measured between the femoral neck axis and a line from the center of the femoral head to a point at which the contour of the femoral head-neck junction exceeds the radius of the femoral head. In the present study, cam morphology was considered to be present when the α -angle was $\geq 55^\circ$.^{6–9}

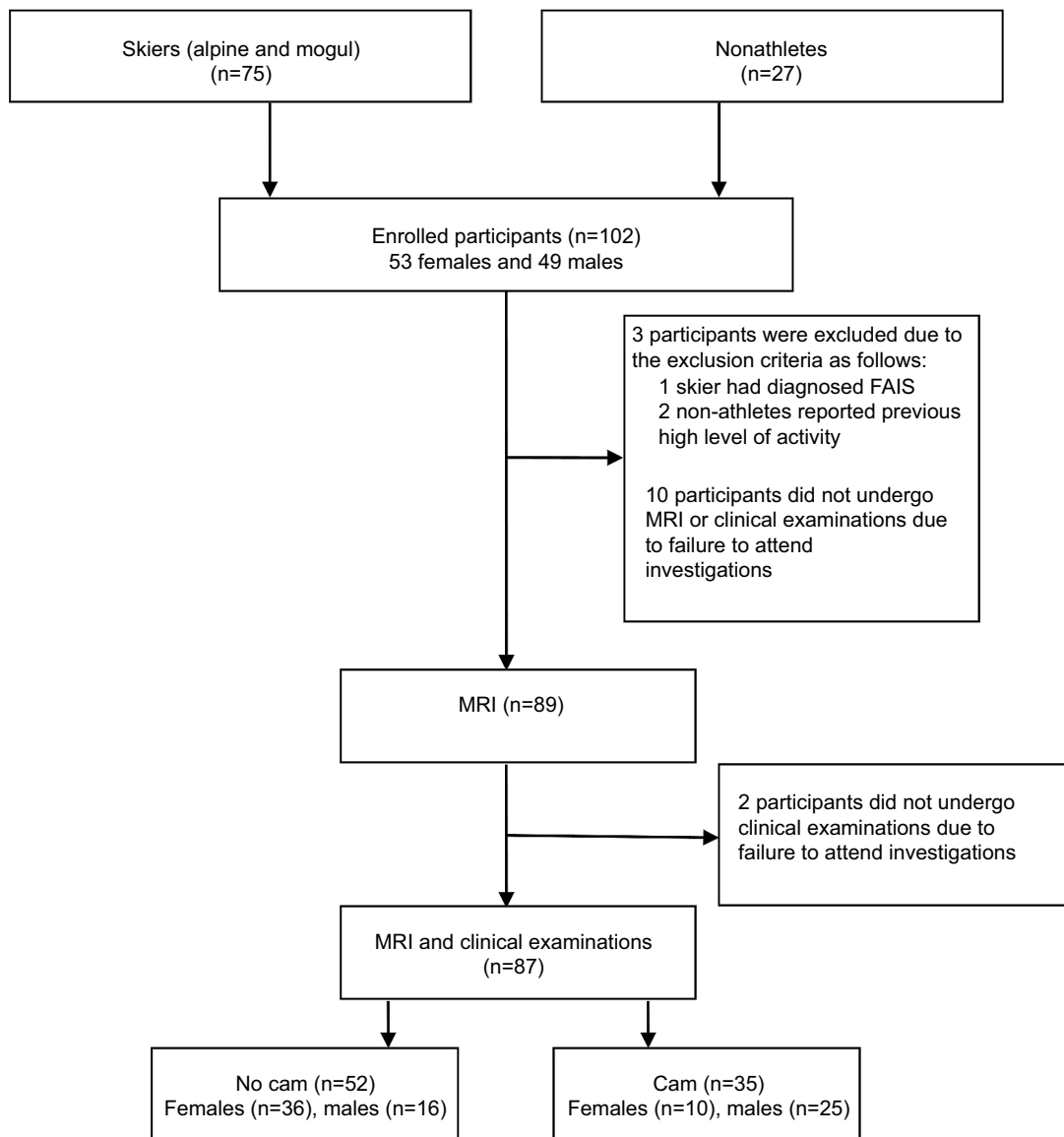


Figure 2 Prisma diagram presenting the participants enrolled in the present study and the MRI results concerning the presence of cam morphology among them. **Abbreviations:** MRI, magnetic resonance imaging; FAIS, femoroacetabular impingement syndrome.

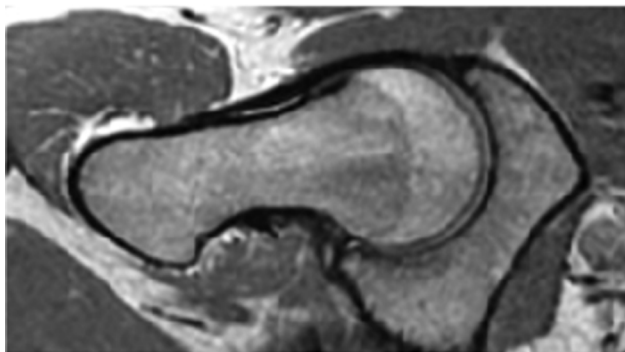


Figure 3 Hip joint with normal morphology of the head-neck junction.

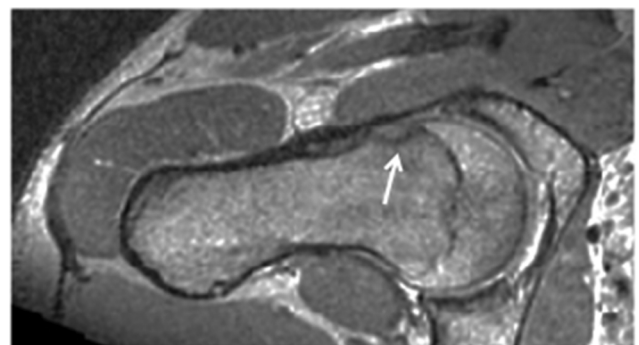


Figure 4 Hip joint with cam morphology (α -angle $\geq 55^\circ$). **Note:** MRI examination of a male skier showing cam morphology with an α -angel above $>55^\circ$ (arrow).

Reliability of α -angle measurements

A resident radiologist, under the guidance of a senior consultant radiologist, measured the α -angle. The radiologists had no prior information about the subjects. The subjects' names and the social security number of each subject were removed from the MRI examinations and replaced by a number. The images were measured according to a standardized protocol, including standardized assessments of the α -angle, as previously described. To test the interobserver reliability, MRI images were selected randomly from 10 participants and were reexamined by a consultant radiologist.

Clinical examination

All the examinations were performed by two of the authors (CA and ASA) following a standardized schedule to optimize the accuracy of the measurements. Both CA and ASA performed the intra-observer tests. Four months passed between the first and second examination. The subjects included in the intra-observer test confirmed that there were no clinical relevant changes in their health between the two examinations, otherwise they would be excluded. Interobserver tests were performed comparing CA and ASA; the test was performed on the same day and the examiners were blinded to each other's measurements. Both the intra- and interobserver tests included 10 of the skiers.

The sitting position was selected because it made it possible in a standardized manner to investigate the relationship between the position of the pelvis and lumbar spine and the hip ROM. To increase the reliability of the sitting examination, according to Reichenbach et al, a special chair was constructed to allow participants to sit freely with their legs hanging over the edge (Figure 5).²⁰ Sitting with both hips and knees placed at a 90° angle, the thighs were held in position by four wooden bolsters to prevent hip abduction/adduction translation. Due to the anatomical differences in the thigh circumference distally, a 1-cm thick pad was placed under the distal femurs to ensure that the femurs were in a horizontal position.

To standardize the sitting position, the subjects were instructed to focus on a point straight ahead on the wall and fold their arms across their chest, with their hands on opposite shoulders.

Sitting hip joint internal and external rotation ROM testing

A goniometer is widely used for evaluating patient ROM and it has been used in previous studies in terms of cam morphology in athletes.^{7,21,22} In the present study, a digital



Figure 5 Participant sitting with a neutral posture, with both hips and knees at a 90° angle and the thighs held in position by four wooden bolsters to prevent hip abduction/adduction translation.

goniometer (DG) was used (HALO Medical Devices, Australia).²³ Measurements of the internal and external rotation of the hip joints were made using the DG, calibrated, zeroed, and handheld, along a marked reference line along the tibial border (Figure 6). The reference line made it possible to set the goniometer laser beams during the measurement, to optimize the accuracy. Measurements of the lumbar spinal sagittal position using the Debrunner kyphometer (Protek AG, Bern, Switzerland), were carried out as described by Todd et al.^{24–26} PT was measured clinically using the PALM palpation meter (Performance Attainment Associates, St Paul, MN, USA) as previously described by Todd et al and Azevedo et al.^{26,27} The anterior superior iliac spine (ASIS) was palpated anteriorly to the most superior prominent protrusion of the iliac crest and the posterior superior iliac spine (PSIS) was palpated posteriorly to the most prominent protrusion of the iliac crest. The caliper tips, of the PALM palpation meter, were placed on ASIS and PSIS and firmly compressed as suggested by

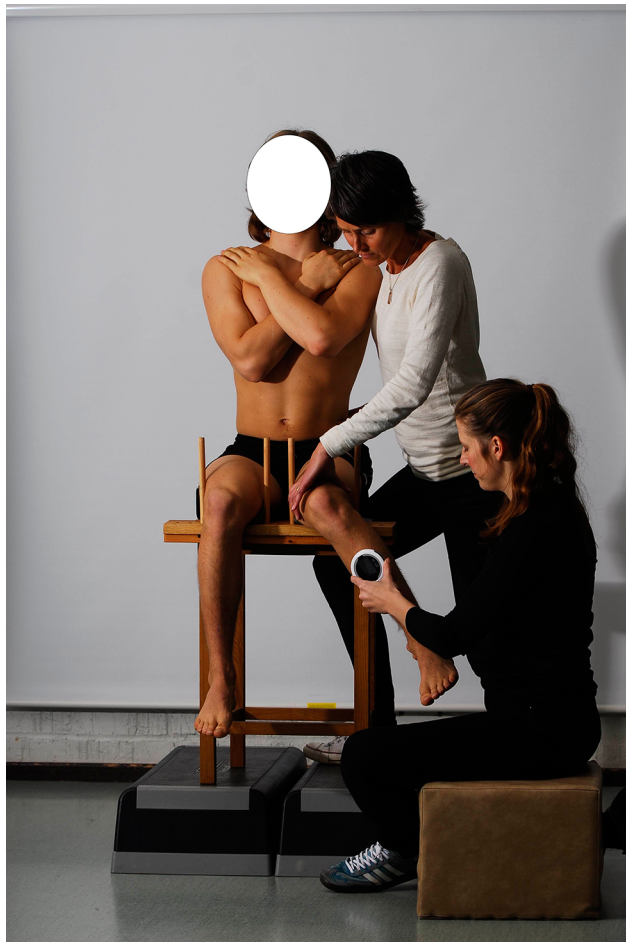

Figure 6 Clinical assessment of internal and external hip rotation using a digital goniometer.

Gajdosik et al²⁸ and the angle of PT was measured on both sides and recorded in degrees.

When measuring the internal and external rotation of the hips, the lumbar spine position was reevaluated, using the kyphometer, before changing sides, to ensure the same lumbar position when measuring both hips. One examiner stabilized the thigh and pelvis on the examined side and passive rotation (internal or external) was then performed, to the point of initial resistance, by the other examiner. The examiner stabilizing the thigh and pelvis also observed the initial movement of the pelvis, which matched the end point of hip rotation palpated by the other examiner. In this way, the accuracy of the hip rotation was double-checked. The rotation was recorded in degrees. Internal and external rotation was measured in three different sitting postures as follows.

Neutral posture

In the neutral posture, the subject was instructed to sit in an upright position, thus creating a vertical line from his/her

shoulder to the hip. The lumbar spine position and the angle of PT were measured in degrees. Internal and external rotations of the hips were examined as described above and the rotation was recorded in degrees (Figure 7).

Extended posture

The subjects were instructed to tilt their pelvis forward maximally and arch their lumbar spine in order to increase pelvic anterior tilt and lumbar lordosis. The lumbar spine position and the angle of PT were measured in degrees. In this position, passive internal and external hip rotation was measured in degrees. The participants were instructed to adopt a neutral posture between each test for a short rest duration, before measuring the other hip (Figure 8).

Flexed posture (slump position)

The participants were instructed to tilt their pelvis backwards maximally and flex their lumbar spine, essentially increasing pelvic posterior tilt and lumbar kyphosis. The lumbar

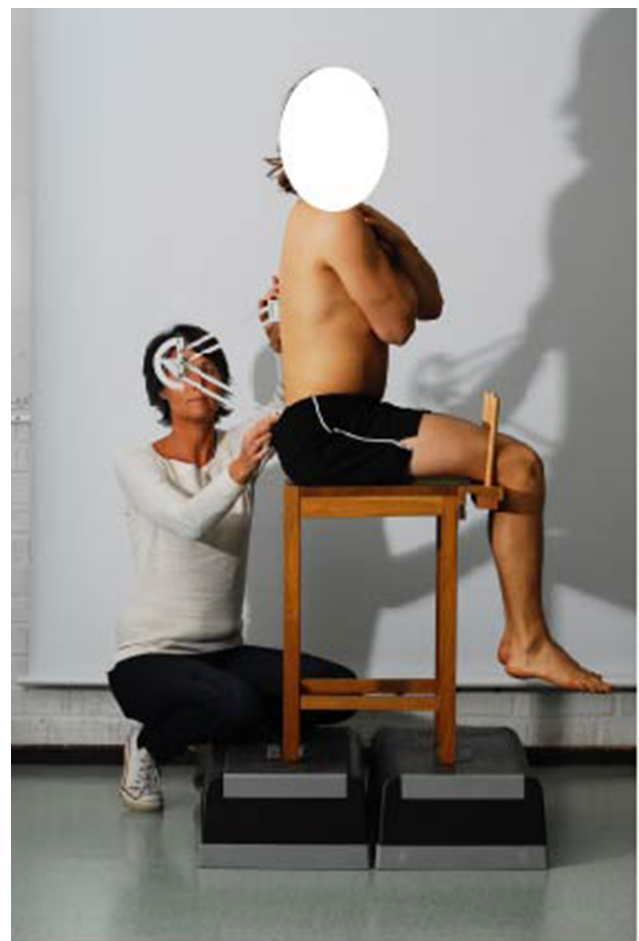


Figure 7 Participant sitting with a neutral posture.



Figure 8 Participant sitting with an extended posture, with maximum anterior pelvic tilt.

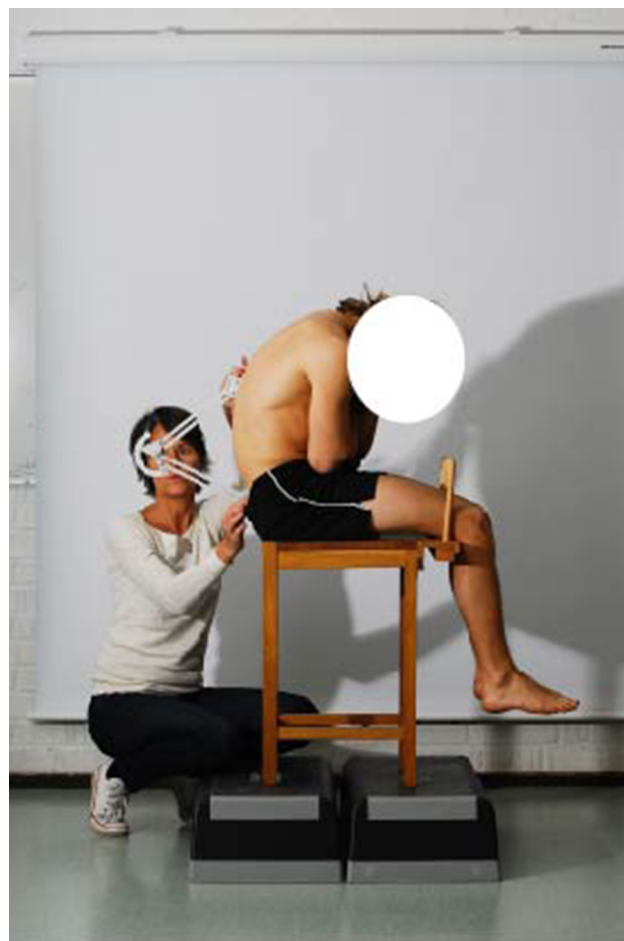


Figure 9 Participant sitting with a flexed posture, with maximum posterior pelvic tilt.

spine position and angle of PT were measured as previously described. In this position, passive internal and external hip rotation was measured in degrees. The participants were instructed to adopt a neutral posture between each test for a short rest duration and the slump position was remeasured before measuring the other hip (Figure 9).

Statistical analysis

Data were analyzed using IBM SPSS Statistics for Windows, version 24.0 (IBM Corporation, Armonk, NY, USA). The description of data was given in terms of the mean and standard deviation. The normal distribution of the data was tested with a Kolmogorov–Smirnov test. The intra- and inter-rater reliability of the measurements was determined with the intraclass correlation coefficient (ICC, 2,1) (two-way random model, absolute agreement, single measurements). To categorize the level of agreement between ICC values, we used the classification system proposed by Shrout and Fleiss.²⁹ ICC values <0.40 represent poor reliability, values between 0.4

and 0.75 represent fair to good, and values >0.75 represent excellent reliability. Standard error of the mean (SEM), a reliability statistic which quantifies measurement error in the same units as the original measurement, was calculated as $SEM = SD \sqrt{1 - ICC}$, where SD is the standard deviation of the difference between observations. All the tests were two-sided and significance was set at $p < 0.05$ for each test.

An independent two-sample *t*-test was used to compare hip ROM, pelvic and lumbar positions between the hips with cam morphology and those without. A dependent *t*-test for paired samples was used to compare hip ROM dependent on the position of the pelvic and lumbar spine. Pearson chi-square test was used to evaluate the distribution of cam between the genders.

Results

The result of the interobserver test (ICC) analysis for the α -angle indicated a good level of agreement (α -angle ICC 0.75 [SEM 1.8]).

The result of the intra-observer test (ICC) for all physical examinations indicated an excellent agreement (internal rotation ICC 0.78 [SEM 1.23], external rotation ICC 0.82 [SEM 0.77]). The interobserver test (ICC) indicated an excellent level of agreement (internal rotation ICC 0.94 [SEM 1.11], external rotation ICC 0.91 [SEM 0.76]).

Table 1 presents the baseline characteristics of the entire study population. Seventy-five skiers, 35 females and 40 males, agreed to participate. Twenty-seven nonathletes, 18 females and 9 males, agreed to participate in the present study. Three subjects had to withdraw from the study due to the exclusion criteria. Failure to attend investigations meant that MRI data from only 89 participants and physical examination data from 87 participants were available for the final analysis (Figure 2). In 87 participants, altogether 174 hips were analyzed.

According to the MRI results, a total of 53 hips were shown to have cam morphology with no difference in the distribution between right and left. Thirty-five subjects had cam and 21% had bilateral cam. There was a significant difference ($p=0.001$) between the prevalence of cam morphology between females (22%) and males (61%) (Table 1).

Compared with the neutral posture, there was a significant decrease in internal hip rotation when the subjects sat with an extended posture with maximum anterior PT ($p<0.001$). On the other hand, there was a significant increase in internal hip rotation when the subjects sat with a flexed posture with maximum posterior PT ($p<0.001$, Table 2). Compared

with the neutral posture, there was a significant decrease in external hip rotation when the subjects sat with an extended posture with maximum pelvic anterior tilt, compared with the neutral posture ($p<0.001$), but no significant difference was observed between neutral posture and when the subjects sat with a flexed posture with maximum posterior PT (Table 2).

With an 11.5° increase in anterior tilt of the pelvis there was a 10.8° decrease in internal hip rotation compared with internal rotation when sitting with a neutral posture. When the posterior tilt was increased by 10.5°, compared with a neutral posture, there was a 4.1° increase in internal hip rotation.

No significant differences were found between the hips with or without cam when analyzing how the posture of the pelvis and lumbar spine affects hip ROM (Table 3). Hips with cam morphology had reduced internal hip rotation (but not external hip rotation) in all three positions, but they responded to the changes in position in a similar manner to hips without cam morphology. There was a significant correlation between the α -angle and internal rotation of the hip. Hips with large α -angles demonstrated a significantly reduced internal rotation meaning that the larger the α -angle the lower the internal rotation. This was found among both the skiers and nonathletes.

Discussion

The most important finding in the present study shows that there is a correlation between hip ROM and the position of the pelvis and the lumbar spine (flexed, neutral, extended posture). Hips with cam morphology had reduced internal hip rotation (but not external hip rotation) in all three positions, but they responded to the changes in position in a similar manner to hips without cam. Moreover, the study method displayed good to excellent reliability.

Using three-dimensional models of the hip, Ross et al demonstrated that, in patients with FAIS, an increase of 10° in anterior PT resulted in a significant decrease in internal hip rotation in 90° of flexion.¹⁸ They also demonstrated that a 10° increase in posterior PT resulted in a significant increase in internal hip rotation in 90° of flexion. This correlates well with the clinical findings in the present study.

Moreover, the present study showed that there was no difference in the response to the position changes between hips with MRI-verified cam morphology (α -angle $>55^\circ$) and those without. However, the hips with cam had reduced internal hip rotation in all three positions, ranging between 20.3° and 32.5°, compared with the hips without cam, ranging between 25.5° and 40.9°. Agnvall et al previously described this in detail in the same group of asymptomatic subjects.¹²

Table 1 Baseline characteristics of all subjects and stratified by group

	All subjects (n=87)	Cam (n=35)	No cam (n=52)	p-value
Age (years) ^a	17.7 (1.3)	18.1 (1.2)	17.4 (1.3)	0.019
Sex, n (%)				
Female	46 (53)	10 (22)	36 (78)	<0.001*
Male	41 (47)	25 (61)	16 (39)	

Notes: ^aValues are represented as mean (SD). *Chi-square test, cam/no-cam prevalence between females and males.

Table 2 Pelvic tilt, internal and external hip rotation of all hips in three different positions of the lumbar spine, independent of cam morphology

Variable	Neutral	Max extension	p-value	Max flexion	p-value ^a
Pelvic tilt	-3.1	8.4	<0.001	-13.6	<0.001
Internal rotation (°)	34.8	24.0	<0.001	38.9	<0.001
External rotation (°)	36.7	30.8	<0.001	36.5	0.53

Note: ^aPaired t-test between neutral and max flexion.

Table 3 Pelvic tilt, internal and external hip rotation of all hips in three different positions of the lumbar spine, comparing hips with cam vs no cam

Variable	Neutral	Max extension	p-value	Max flexion	p-value ^a
Cam, pelvic tilt	-3.6	7.8	<0.001	-13.3	<0.001
No cam, pelvic tilt	-2.7	8.8	<0.001	-13.6	<0.001
Cam, internal rotation (°)	30.3	20.5	<0.001	34.3	<0.001
No cam, internal rotation (°)	37.5	25.9	<0.001	41.6	<0.001
Cam, external rotation (°)	36.0	29.5	<0.001	35.0	0.36
No cam, external rotation (°)	36.9	30.8	<0.001	36.8	0.81

Note: ^aPaired t-test between neutral and max flexion.

The results of this present study indicated that cam morphology results in potential premature contact between the proximal femur and the acetabulum, thereby reducing hip ROM, but the hip joint is affected by changes in posture in the same way, independent of cam morphology.

In a laboratory study of cadaveric human pelvises, Birmingham et al showed that, when a hip with cam morphology was internally rotated, the motion at the pubic symphysis increased significantly more compared with a hip without cam morphology.³⁰ This implies that the loss of hip ROM imposes higher demands on surrounding structures, increasing the risk of overload injuries. For this group of young elite athletes, this may be highly relevant.

In young male football players, Agricola et al showed that cam morphology develops gradually during growth, but, after growth plate closure, there is no significant increase in the prevalence of cam.³¹ Baranto et al showed that the weakest part of the growing porcine lumbar spine, when compressed into flexion and extension, was the growth zone.³² The ring apophysis might fuse to the vertebrae as late as at the age of 24–25 years, which is several years later than the development of cam morphology.^{33,34} Therefore, it may be possible that a reduction in hip ROM, caused by cam morphology, forces the lumbar spine to increase kyphosis, to measure the demands of elite skiing; perhaps, this could increase the anterior load on the open ring apophysis causing overload injuries/growth disturbances.

Thoreson et al showed that elite Mogul skiers have significantly greater spinal radiological abnormalities compared with nonathletes.³⁵ Witwit et al showed that Alpine and Mogul skiers have significantly more degenerative disc changes compared with nonathletes.³⁶ The correlation between back problems and hip ROM has been recognized among patients undergoing total hip arthroplasty where it has been showed that patients with multilevel degenerative disc disease (DDD) sit with significantly more hip flexion than spine flexion compared with patients without DDD.³⁷ They also sit and

stand with an increased posterior PT. This indicates a possible causal correlation between spinal pathologies and hip ROM and further investigation of the relationship is of importance.

Clinical relevance

The results of this study contribute to the increasing knowledge on cam morphology in young athletes. The effect of the pelvic and lumbar position on hip ROM and vice versa are clinically relevant not only for preventing injuries on these anatomic areas among young athletes but also for a general understanding of the function of the hip and spine. It is of importance to identify a decreased hip ROM, caused by a cam morphology, as early as possible not only so that the athletes can be guided when training to prevent overload injuries on surrounding structures, but also to avoid damaging and painful collisions of the cam morphology with the acetabulum.

Strengths and limitations

The method included both athletes and nonathletes of both genders living in the same geographical area with a relatively large cohort size. A larger sample group might, however, have revealed greater differences between the hips with and without cam. The inclusion criteria in the present study selected only a healthy population; however, this may have limited the ability to distinguish greater differences in ROM in the presence of cam morphology, compared with a symptomatic group. Other limitations include accuracy and interpretation of the radiological measurements. Clinical examination is always dependent on the examiner, but we attempted to increase the accuracy by limiting the number of examiners to just two and using a standardized method. The study method was validated with good results for both the MRI and goniometer methods and this observation strengthens the results in the present study. It is believed that the development of cam morphology does not occur once the growth plate is closed and the skeleton is mature.^{9,31} All the subjects in the present study had closed growth plates in the hip and were in this way comparable.

Conclusion

Changes in PT and posture (flexed, neutral, or extended) significantly influence hip ROM in hips with or without cam morphology. The hips with cam morphology had reduced internal hip rotation in general, but the effect of PT and posture on hip ROM was the same in both the hips with or without cam. The intimate relationship between hip ROM, PT, and lumbar spine posture is important and must be taken into consideration during a clinical examination.

Acknowledgments

The authors acknowledge the financial support of the Research and Development Unit, Jämtland Härjedalen County Council, Sweden, the Swedish National Centre for Research in Sports, and Carl Bennet AB. The authors would also like to thank Flemming Pedersen, MD, and Zaid Obady, MD, at the Department of Radiology at Östersund Hospital, Sweden, for their help with the radiological examination, and Christer Johansson, OrigoVerus AB, Gothenburg, Sweden, for statistical assistance. The authors also thank Åke Hamberg, MD, at the Department of Orthopaedics at Östersund Hospital, Sweden, for helping with the recruitment of young nonathletes.

Disclosure

The authors report no conflicts of interest in this work.

References

- Griffin DR, Dickenson EJ, O'Donnell J, et al. The Warwick Agreement on femoroacetabular impingement syndrome (FAI syndrome): an international consensus statement. *Br J Sports Med*. 2016;50(19):1169–1176.
- Beck M, Kalthor M, Leunig M, Ganz R. Hip morphology influences the pattern of damage to the acetabular cartilage: femoroacetabular impingement as a cause of early osteoarthritis of the hip. *J Bone Joint Surg Br*. 2005;87(7):1012–1018.
- Ganz R, Parvizi J, Beck M, Leunig M, Notzli H, Siebenrock KA. Femoroacetabular impingement: a cause for osteoarthritis of the hip. *Clin Orthop Relat Res*. 2003;417:112–120.
- Ito K, Minka MA 2nd, Leunig M, Werlen S, Ganz R. Femoroacetabular impingement and the cam-effect. A MRI-based quantitative anatomical study of the femoral head-neck offset. *J Bone Joint Surg Br*. 2001;83(2):171–176.
- Pfirrmann CW, Mengiardi B, Dora C, Kalberer F, Zanetti M, Hodler J. Cam and pincer femoroacetabular impingement: characteristic MR arthrographic findings in 50 patients. *Radiology*. 2006;240(3):778–785.
- Agricola R, Waarsing JH, Thomas GE, et al. Cam impingement: defining the presence of a cam deformity by the alpha angle: data from the CHECK cohort and Chingford cohort. *Osteoarthritis Cartilage*. 2014;22(2):218–225.
- Siebenrock KA, Kaschka I, Frauchiger L, Werlen S, Schwab JM. Prevalence of cam-type deformity and hip pain in elite ice hockey players before and after the end of growth. *Am J Sports Med*. 2013;41(10):2308–2313.
- Siebenrock KA, Ferner F, Noble PC, Santore RF, Werlen S, Mamisch TC. The cam-type deformity of the proximal femur arises in childhood in response to vigorous sporting activity. *Clin Orthop Relat Res*. 2011;469(11):3229–3240.
- Philippon MJ, Ho CP, Briggs KK, Stull J, LaPrade RF. Prevalence of increased alpha angles as a measure of cam-type femoroacetabular impingement in youth ice hockey players. *Am J Sports Med*. 2013;41(6):1357–1362.
- Clohisy JC, Knaus ER, Hunt DM, Leshner JM, Harris-Hayes M, Prather H. Clinical presentation of patients with symptomatic anterior hip impingement. *Clin Orthop Relat Res*. 2009;467(3):638–644.
- Sink EL, Gralla J, Ryba A, Dayton M. Clinical presentation of femoroacetabular impingement in adolescents. *J Pediatr Orthop B*. 2008;28(8):806–811.
- Agnvall C, Swärd Aminoff A, Todd C, et al. Range of hip joint motion is correlated with MRI-verified cam deformity in adolescent elite skiers. *Orthop J Sports Med*. 2017;5(6):2325967117711890.
- Tak I, Glasgow P, Langhout R, Weir A, Kerkhoffs G, Agricola R. Hip range of motion is lower in professional soccer players with hip and groin symptoms or previous injuries, independent of cam deformities. *Am J Sports Med*. 2016;44(3):682–688.
- Manning C, Hudson Z. Comparison of hip joint range of motion in professional youth and senior team footballers with age-matched controls: an indication of early degenerative change? *Phys Ther Sport*. 2009;10(1):25–29.
- Heinrich D, van den Bogert AJ, Nachbauer W. Relationship between jump landing kinematics and peak ACL force during a jump in downhill skiing: a simulation study. *Scand J Med Sci Sports*. 2014;24(3):e180–e187.
- Kurpiers N, McAlpine PR, Kersting UG. Perspectives for comprehensive biomechanical analyses in Mogul skiing. *Res Sports Med*. 2009;17(4):231–244.
- Sporri J, Kroll J, Haid C, Fasel B, Muller E. Potential mechanisms leading to overuse injuries of the back in Alpine ski racing: a descriptive biomechanical study. *Am J Sports Med*. 2015;43(8):2042–2048.
- Ross JR, Nepple JJ, Philippon MJ, Kelly BT, Larson CM, Bedi A. Effect of changes in pelvic tilt on range of motion to impingement and radiographic parameters of acetabular morphologic characteristics. *Am J Sports Med*. 2014;42(10):2402–2409.
- Nötzli HP, Wyss TF, Stoecklin CH, Schmid MR, Treiber K, Hodler J. The contour of the femoral head-neck junction as a predictor for the risk of anterior impingement. *J Bone Joint Surg Br*. 2002;84(4):556–560.
- Reichenbach S, Juni P, Nuesch E, Frey F, Ganz R, Leunig M. An examination chair to measure internal rotation of the hip in routine settings: a validation study. *Osteoarthritis Cartilage*. 2010;18(3):365–371.
- Gajdosik RL, Bohannon RW. Clinical measurement of range of motion. Review of goniometry emphasizing reliability and validity. *Phys Ther*. 1987;67(12):1867–1872.
- Holm I, Bolstad B, Lutken T, Ervik A, Rokkum M, Steen H. Reliability of goniometric measurements and visual estimates of hip ROM in patients with osteoarthritis. *Physiother Res Int*. 2000;5(4):241–248.
- Furness J, Johnstone S, Hing W, Abbott A, Climstein M. Assessment of shoulder active range of motion in prone versus supine: a reliability and concurrent validity study. *Physiother Theory Pract*. 2015;31(7):489–495.
- Ohlen G, Aaro S, Bylund P. The sagittal configuration and mobility of the spine in idiopathic scoliosis. *Spine*. 1988;13(4):413–416.
- Ohlen G, Spangfort E, Tingvall C. Measurement of spinal sagittal configuration and mobility with Debrunner's kyphometer. *Spine*. 1989;14(6):580–583.
- Todd C. Clinical spino-pelvic parameters in skiers and non-athletes. *J J Sport Med*. 2016;3(3):22.
- Azevedo DC, Santos H, Carneiro RL, Andrade GT. Reliability of sagittal pelvic position assessments in standing, sitting and during hip flexion using palpation meter. *J Bodyw Mov Ther*. 2014;18(2):210–214.
- Gajdosik R, Simpson R, Smith R, DonTigny RL. Pelvic tilt. Intratester reliability of measuring the standing position and range of motion. *Phys Ther*. 1985;65(2):169–174.
- Shrout PE, Fleiss JL. Intraclass correlations: uses in assessing rater reliability. *Psychol Bull*. 1979;86(2):420–428.
- Birmingham PM, Kelly BT, Jacobs R, McGrady L, Wang M. The effect of dynamic femoroacetabular impingement on pubic symphysis motion: a cadaveric study. *Am J Sports Med*. 2012;40(5):1113–1118.

31. Agricola R, Heijboer MP, Ginai AZ, et al. A cam deformity is gradually acquired during skeletal maturation in adolescent and young male soccer players: a prospective study with minimum 2-year follow-up. *Am J Sports Med.* 2014;42(4):798–806.
32. Baranto A, Ekstrom L, Hellstrom M, Lundin O, Holm S, Sward L. Fracture patterns of the adolescent porcine spine: an experimental loading study in bending-compression. *Spine.* 2005;30(1):75–82.
33. Matsumoto M. [Radiological and histological studies on the growth of lumbar vertebra]. *Nihon Seikeigeka Gakkai Zasshi.* 1988;62(4):331–343. Japanese.
34. Edelson JG, Nathan H. Stages in the natural history of the vertebral end-plates. *Spine.* 1988;13(1):21–26.
35. Thoreson O, Kovac P, Sward A, Agnvall C, Todd C, Baranto A. Back pain and MRI changes in the thoraco-lumbar spine of young elite Mogul skiers. *Scand J Med Sci Sports.* 2017;27(9):983–989.
36. Witwit WA, Kovac P, Sward A, et al. Disc degeneration on MRI is more prevalent in young elite skiers compared to controls. *Knee Surg Sports Traumatol Arthrosc.* 2018;26(1):325–332.
37. Esposito CI, Miller TT, Kim HJ, et al. Does degenerative lumbar spine disease influence femoroacetabular flexion in patients undergoing total hip arthroplasty? *Clin Orthop Relat Res.* 2016;474(8):1788–1797.
38. Moher D, Liberati A, Tetzlaff J, Altman DG; The PRISMA Group. Preferred reporting items for systematic reviews and meta-analyses: the PRISMA statement. *PLoS Med.* 2009;6(7):e1000097.

Open Access Journal of Sports Medicine

Publish your work in this journal

The Open Access Journal of Sports Medicine is an international, peer-reviewed, open access journal publishing original research, reports, reviews and commentaries on all areas of sports medicine. The journal is included on PubMed. The manuscript management system is completely online and includes a very quick and fair

peer-review system. Visit <http://www.dovepress.com/testimonials.php> to read real quotes from published authors.

Submit your manuscript here: <http://www.dovepress.com/open-access-journal-of-sports-medicine-journal>

Dovepress