

Ultrasound-guided ethanol injection for the treatment of parathyroid adenoma: A prospective self-controlled study

Amir Ali Yazdani¹, Nooshin Khalili², Mansour Siavash², Albert Shemian³, Amir Reza Goharian², Mozhgan Karimifar², Babak Tavakoli⁴, Maryam Yazdi^{2,5}

¹Jam Medical Imaging and Interventional Radiology Center, Isfahan, Iran, ²Isfahan Endocrine and Metabolism Research Center, Isfahan University of Medical Sciences, Isfahan, Iran, ³Department of Internal Medicine, School of Medicine, Isfahan University of Medical Sciences, Isfahan, Iran, ⁴Arman Medical Imaging and Interventional Radiology Institute, Isfahan, Iran, ⁵Child Growth and Development Research Center, Research Institute for Primordial Prevention of Non-Communicable Disease, Isfahan University of Medical Sciences, Isfahan, Iran

Background: Parathyroidectomy, the standard treatment of primary hyperparathyroidism (PHP) due to parathyroid adenoma, is not suitable for all patients. We evaluated the efficacy of ultrasound-guided ethanol ablation of parathyroid adenoma in a group of patients with PHP. **Materials and Methods:** In a prospective self-controlled trial, 39 patients with parathyroid adenoma, who were not candidates for surgery, were enrolled. Ethanol injections were performed by two experienced interventional radiologists under the guidance of real-time ultrasonography. Adenoma size changes were assessed at about 1 month later. Serum levels of parathyroid hormone, calcium, phosphate, 25-OH Vitamin D, and alkaline phosphatase were evaluated at the baseline, 1, 3, 6, and 12 months after the injections. The treatment effects on outcome variables were assessed by repeated measures analysis. **Results:** Volume of the adenomas decreased during the study period from $1.87 \pm 6.45 \text{ cm}^3$ to $0.38 \pm 0.48 \text{ cm}^3$ ($P < 0.001$). Corrected serum calcium levels decreased from $10.40 \pm 0.96 \text{ mg/dl}$ to $8.82 \pm 0.58 \text{ mg/dl}$ ($P < 0.001$), and remained stable during one year follow-up. Serum levels of parathyroid hormone decreased gradually from 129.85 ± 63.37 to $72.58 \pm 53.86 \text{ pg/mL}$ after 3 months and to $44.78 \pm 28.04 \text{ pg/mL}$ after 1 year ($P < 0.001$). Overall, 46% of the patients improved after 1 month of ethanol ablation therapy which increased to 84.5% during 1-year follow-up. No major complications were observed. **Conclusion:** The current study showed the efficacy of ultrasound-guided ethanol injection in PHP and may be considered as a suitable alternative treatment in patients who are not candidates for the surgery. It has also a good safety profile without major complications if performed by experienced hands.

Key words: Ethanol ablation, hypercalcemia, parathyroid adenoma, primary hyperparathyroidism

How to cite this article: Yazdani AA, Khalili N, Siavash M, Shemian A, Goharian AR, Karimifar M, *et al.* Ultrasound-guided ethanol injection for the treatment of parathyroid adenoma: A prospective self-controlled study. *J Res Med Sci* 2020;25:93.

INTRODUCTION

Primary hyperparathyroidism (PHP) is a common endocrine disorder, with worldwide incidence of 21.6 cases per 100,000.^[1] The main cause of PHP is solitary adenoma (87%–91%), generally originating from chief cells,^[2] although the other causes include hyperplasia (6%) and parathyroid carcinoma (<1%).^[3] Parathyroid adenoma may present with hypercalcemia, kidney stone, osteoporosis, bone pain, depression, peptic

ulcer, and many other clinical manifestations.^[4] The standard treatment for parathyroid solitary adenoma or carcinoma is surgical excision.^[5] However, surgical approach may not be appropriate for some patients due to clinical considerations, or it may fail in some patients.^[6,7] Medical treatments, although may be effective, but does not usually lead to long-term sustained control of hypercalcemia and needs life-long therapy.^[8]

Percutaneous ethanol injection treatment of parathyroid adenomas is introduced as an alternative therapeutic

Access this article online	
Quick Response Code: 	Website: www.jmsjournal.net
	DOI: 10.4103/jrms.JRMS_553_19

This is an open access journal, and articles are distributed under the terms of the Creative Commons Attribution-NonCommercial-ShareAlike 4.0 License, which allows others to remix, tweak, and build upon the work non-commercially, as long as appropriate credit is given and the new creations are licensed under the identical terms.

For reprints contact: WKHLRPMedknow_reprints@wolterskluwer.com

Address for correspondence: Dr. Mansour Siavash, Sedigheh Tahereh Medical Research Complex, Khorram Street, Isfahan, Iran.
E-mail: iavash@med.mui.ac.ir.

Submitted: 21-Sep-2019; **Revised:** 02-Dec-2019; **Accepted:** 08-Jun-2020; **Published:** 28-Oct-2020

approach with a relatively high response rate which has been introduced in only some case reports.^[9,10] Moreover, little data are available concerning the long-term results of the percutaneous ethanol injection.^[9] On the other hand, direct injection of alcohol has some advantages which have not been studied as well, including lower costs as it is an outpatient procedure without needing general anesthesia, repeatability, and lack of interference with other therapeutic methods such as surgery. Finally, ethanol injection is a minimally invasive procedure with much less morbidity and mortality and few side effects in comparison to the surgery.^[10]

There are few prospective clinical trials about the efficacy of ethanol injection in the treatment of parathyroid adenoma and subsequent laboratory changes in the long term.^[11,12] In the current study, we evaluated and compared the clinical efficacy of percutaneous ethanol injection in the treatment of parathyroid adenoma through a prospective self-controlled study.

METHODS

Study design and target group

This prospective, self-controlled, open-label study was conducted in Isfahan endocrine and metabolism research center (IEMRC), Isfahan, Iran during November 2014 to November 2017. We evaluated patients with a probable diagnosis of PHP who were referred to endocrinology clinics of IEMRC. Then, based on clinical, biochemical/hormonal and imaging (ultrasound \pm sestamibi scan) assessments, the diagnosis was confirmed and decision for surgery were made based on the last guidelines.^[13] The participants were selected based on the following criteria: 1 patient in whom parathyroid adenoma was clearly visible by ultrasound and confirmed by fine-needle aspiration (FNA) and parathyroid hormone (PTH) wash out of the suspected mass, 2 patients who did not accept surgery, or surgery was not an appropriate plan for them,^[13] and 3 patients who choose ultrasound-guided parathyroid alcohol ablation. Patients who needed second or third injection, but were not satisfied with the procedure after the first or second time had the option to stop the procedure and to be followed or introduced for the surgery. We explained the protocol of the study to all participants, and a signed written consent was obtained from them. For elderly patients aged more than 70, we also obtained informed consent from their legal caregivers. The study received ethics approval from the Ethics Committee of Isfahan University of Medical Sciences (396431).

Intervention and measurements

All percutaneous ethanol injection procedures were performed by two experienced interventional radiologists

after FNA biopsy of the suspected mass. The ultrasound characteristics of parathyroid adenomas was usually a single fusiform and well-capsulated nodule, with moderate-to-high vascularity and most of the time significantly hypoechoic. The ultrasonography was performed by Samsung R730 ultrasound. After sterilization of the skin, a small amount of local anesthetic (lidocaine 2%) was injected into subcutaneous tissue before alcohol injection. A 25G needle was used to inject ethanol. Needle of the syringe containing 96% ethanol was inserted into the parathyroid adenoma under the guidance of real-time ultrasonography by the radiologist. Between 3 and 6 mL of ethanol, depending on the vascularity and size of adenomas was injected into the four quadrants of parathyroid adenoma with alcohol diffusion monitoring by ultrasonography. One month after the first injection, ultrasound was repeated. Then, based on the biochemical and sonographic findings, a decision for the second ethanol injection was made. The third and fourth injections were repeated at later months if needed as well.

Serum levels of PTH, calcium, phosphate, 25-OH Vitamin D, and alkaline phosphatase (ALP) were evaluated before, 1 month, 3 months, 6 months, and 1 year after the procedure. Successful ablation was defined by a significant reduction of adenoma size and vascularity on Doppler ultrasonography, decreased level of serum calcium (returning to normal range), and PTH (returning to normal range or more than 50% decrease). The study flow diagram is presented in Figure 1.

Serum calcium was measured by Arsenazo method (normal range: 8.6–10.3 mg/dl). Serum PTH was measured by ELISA (Uroimmune, Deutschland, normal range: 10.9–54.8 pg/dl). Serum 25-(OH) D was measured by ELISA (Biorex fars, Iran, normal range: 20–100 ng/ml). Serum ALP was measured by calorimetry (normal range: 64–306 mg/dl). Serum phosphate was measured by calorimetry (normal range: 2.5–5 mg/dl).

The patients with PHP were defined and categorized in three groups: elevated PTH and high normal serum calcium, elevated serum calcium and high normal PTH and elevated both PTH and serum calcium. To unify these three groups in one group for statistical analysis by the software in a more straightforward way, and as a practical guideline, we also proposed a variable ($PTH \times \text{serum calcium} > 550$ and $\text{serum calcium} > 9.8$ mg/dl) for defining PHP.

Statistical analysis

Continuous data were reported as mean \pm standard deviation (SD) and categorical data as frequency (percentage). Normality of continuous data was evaluated using the Kolmogorov–Smirnov test and Q-Q plot. Right skewed data were subjected to logarithmic transformation.

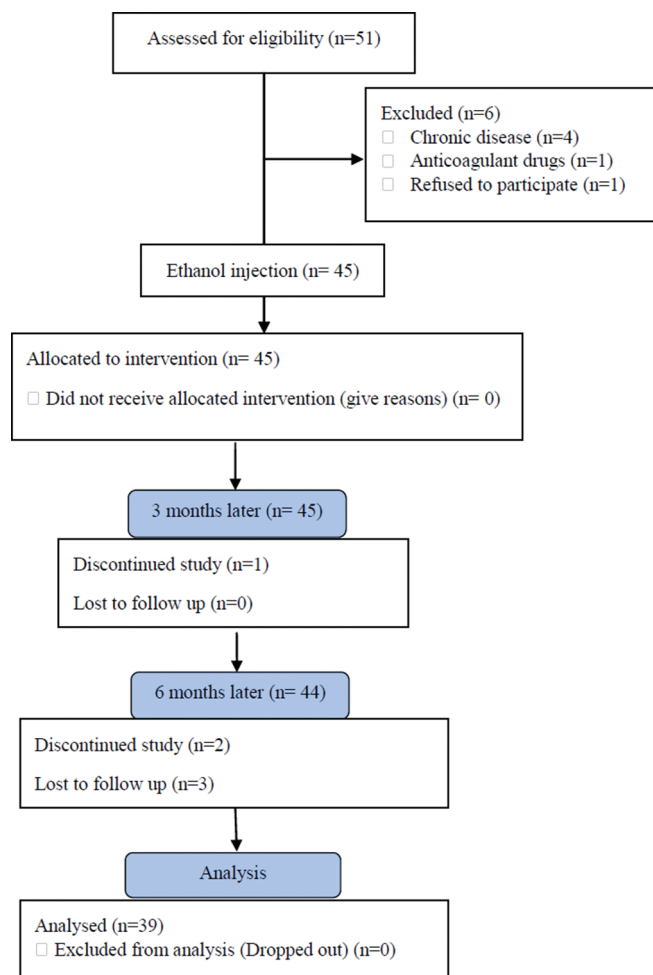


Figure 1: The study flow diagram

Baseline characteristics were compared across age groups by independent sample *t*-test. To compare the outcome variables between different periods, repeated measures analysis was used. All statistical analyses were conducted using the SPSS software version 20 (IBM Corp. Released 2013. IBM SPSS Statistics for Windows, version 20.0, Armonk, NY, USA: IBM Corp.). The two-tailed $P < 0.05$ was considered statistically significant.

RESULTS

After 1 year follow-up, 39 patients remained in the study that 35 (87.5%) of them were females. The mean age of the participants was 61.28 ± 10.37 years, ranging from 33 to 83 years. Baseline characteristics of the participants are presented in Table 1. About 51.3% of participants were < 60 years old. Adenoma size was slightly larger among older age group (0.82 ± 0.74 cm³ vs. 2.98 ± 9.21 cm³, $P = 0.302$). Serum calcium as well was significantly higher in older patients (10.52 ± 0.75 vs. 11.07 ± 0.84 , $P = 0.039$). Other characteristics did not show any significance difference between the age groups ($P > 0.05$). Mean 24 h urinary calcium was 267 mg/24 h.

Table 1: Baseline characteristics of participants

	Age groups (years)		Total	P ^c
	<60	≥60		
n (%)	20 (51.3) ^b	19 (48.7)	39	
Sex (female)	18 (90.0)	17 (89.5)	35 (89.7)	0.957
Length (mm)	13.60±4.70	16.58±9.55	15.05±7.52	0.22
Width (mm)	7.71±3.04	9.49±7.40	8.58±5.60	0.325
Diameter (mm)	6.46±2.54	6.47±4.92	6.46±3.84	0.991
Calcium	10.52±0.75	11.07±0.84	10.79±0.83	0.039
Phosphate	3.15±0.49	3.07±0.60	3.11±0.54	0.662
Albumin	4.46±0.56	4.30±0.36	4.38±0.47	0.322
25-(OH)-Vitamin D3	44.99±22.59	34.82±14.96	40.04±19.69	0.108
ALP	247.65±91.11	238.84±79.17	243.36±84.50	0.75
PTH	116.72±48.44	143.68±74.89	129.85±63.37	0.188
Serum creatinine	0.97±0.15	1.16±0.15	1.09±0.17	0.001

^aMean±SD; ^bn (%); ^cResulted from Chi-square test for qualitative variable and independent *t*-test for quantitative variables. PTH=Parathyroid hormone; ALP=Alkaline phosphatase; SD=Standard deviation

Overall, 26 (66.7%) patients underwent one injection, 8 (20.5%) twice, 4 (10.3%) three times, and one patient (2.6%) four times.

After the injections, mean of the adenoma volume decreased significantly from 1.87 ± 6.45 cm³ to 0.38 ± 0.48 cm³ ($P < 0.001$). Adenoma size did not decrease in only one patient [Figure 2].

Table 2 indicates the changes of measured outcomes during the follow-up. Corrected serum calcium levels decreased significantly after the 1st month and remained stable during 1 year follow-up ($P < 0.001$). Serum PTH as well decreased significantly after the 1st month and continued to decrease during 1 year follow-up ($P < 0.001$) [Figure 3]. Serum phosphate increased significantly after 3 months and increased gradually after that during the follow-up period ($P < 0.001$). Serum ALP had a non-significant decrease after 3 months and remained stable during the follow-up period ($P = 0.07$). Serum 25-OH Vitamin D increased progressively during the study (by prescribed or personal supplement intake) ($P < 0.001$).

About 46% of the patients with hyperparathyroidism improved after one month of ethanol ablation therapy which increased to 84.5% during 1 year follow-up.

No major complications were observed in the participants during or after ethanol injection and during 1 year of follow-up. Minor complications such as local pain and injection site irritation were observed rarely in some patients, which usually subsided rapidly.

DISCUSSION

The present study showed that ethanol injection could control hyperparathyroidism in 85% of the patients and decrease

Table 2: Serial serum levels of parathyroid hormone, corrected calcium, phosphate, 25-OH Vitamin D, and alkaline phosphatase during the follow-up

	Follow up					F (df) ^b	P
	Baseline	1 month later	3 months later	6 months later	12 months later		
PTH (pg/mL)	129.85±63.37	84.99±71.26	72.58±53.86	68.43±43.49	44.78±28.05	8.69 (4, 152)	<0.001
Corrected calcium (mg/dL)	10.41±0.97	9.45±0.83	9.35±0.79	9.10±0.65	8.83±0.59	43.04 (4, 152)	<0.001
Phosphate (mg/dL)	3.11±0.54	3.23±0.46	3.32±0.49	3.37±0.53	3.48±0.38	6.21 (4, 152)	<0.001
25-OH Vitamin D (ng/mL)	40.04±19.69	40.32±18.61	51.71±53.47	56.45±31.06	76.84±42.49	23.71 (4, 152)	<0.001
ALP (IU/L)	243.36±84.50	240.77±87.76	228.23±75.06	227.33±68.55	228.69±63.28	2.87 (4, 152)	0.070

^aMean±SD; ^bF statistic value and degrees of freedom in a repeated measures analysis. PTH=Parathyroid hormone; ALP=Alkaline phosphatase; SD=Standard deviation

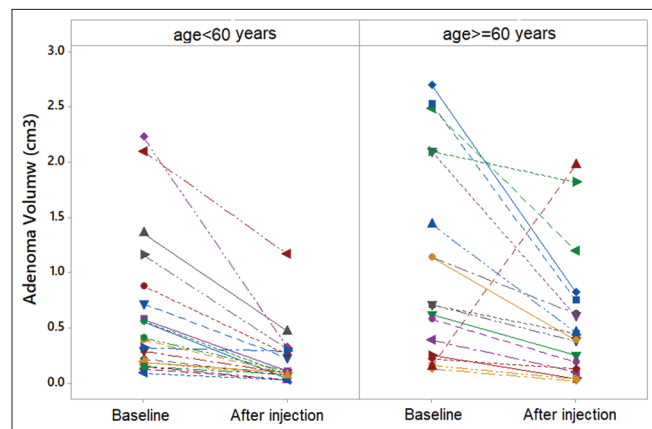


Figure 2: Trajectories of Adenoma volume before and after the percutaneous ethanol injection in 39 patients of two age groups

serum corrected calcium, PTH and adenoma volume in them. Parathyroidectomy, a surgical procedure, is currently the treatment of choice in PHP. If performed by an experienced parathyroid surgeon, parathyroidectomy is curative in 95%–98% of the patients.^[14] Despite this high success rate, it might have various complications, such as hematoma and neck swelling,^[15] while the ethanol injection method was relatively safe and did not show any major complications.

To the best of our knowledge, there are not enough clinical trials on the ethanol injection for PHP, and only some case reports/series and animal studies have been published. Vergès *et al.* showed that ultrasound-guided percutaneous ethanol injection of parathyroid adenomas was effective in 64.5% of patients with PHP during the 5-year follow-up. It was very effective in patients with contraindications to the surgery.^[16] Another study performed by Cercueil *et al.* revealed a biochemical recovery (i.e. reduction of plasma calcium and PTH, and increase in serum phosphate levels) of 58%. It also showed only 7% failure rate and finally concluded that acquired results in ethanol injection were remarkable but not as good as surgery method.^[11]

Guttin *et al.* performed a study on the efficacy of percutaneous ultrasound-guided ethanol ablation on the outcomes of 24 dogs with PHP with parathyroid nodules. They showed that ethanol ablation was an effective treatment for those dogs,

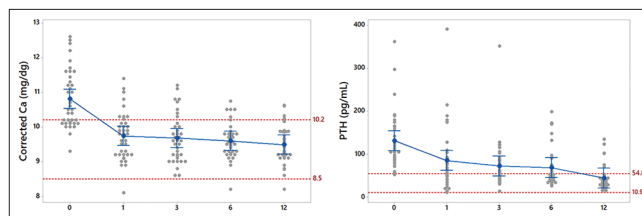


Figure 3: Serial changes of mean (Bonferroni 95% confidence interval) of corrected calcium and parathyroid hormone (Parathyroid hormone) of 39 patients during the follow-up (baseline until 12th month). Dash lines indicate to normal ranges

with lower duration of anesthesia, lower complications, and low risk for hypocalcemia.^[17]

Montenegro *et al.* reported a case with unresectable parathyroid carcinoma who responded to ultrasound-guided ethanol injection. They observed the reduction in PTH levels from 2990 pg/mL to 2230 pg/ml after the first injection, and decreased to 1104 pg/mL after the second injection and reduction in calcium serum levels from 19.8 mg/dL to 16.1 mg/dL and to 14.5 mg/dL, respectively, without serious complication.^[18]

Alherabi *et al.* reported ultrasound-guided ethanol injection of parathyroid adenomas as an alternative to the surgery in patients with significant medical comorbidities. They observed significant response in laboratory tests and clinical findings.^[10]

Cappelli *et al.* reported two cases of PHP with parathyroid adenoma who underwent ultrasound-guided ethanol injection. Both cases showed remarkable response in clinical manifestation and laboratory variables to alcohol injection after 20 months of follow-up.^[9]

Harman *et al.* had reported four indications, including medical comorbidities, patient choice, difficult surgery technically, and partial ablation.^[19] Percutaneous alcohol ablation is less expensive, less invasive, with less extensive preparation, and reduces the usual risks of surgery.^[12] Shenoy *et al.* used radiofrequency ablation followed by percutaneous ethanol ablation for a case. They observed a reduction of adenoma size and a decrease in PTH level after the procedure.^[20]

Few complications have been reported with the percutaneous alcohol ablation, including incomplete necrosis of the adenoma, recurrent laryngeal nerve injury,^[19] hypocalcemia, and peri-glandular fibrosis,^[12,21,22] which have not been observed in our study.

Limitations

Our study has some limitations: first, we did not have the control group, and it was an open-label study. As it was a pilot study, we recommend designing an RCT for better evaluation of the method, its efficacy, side effects, and acceptability. Second: duration of follow-up of this study was 1 year, and we do not have sufficient data regarding the recurrence or stability of the condition after that time. Furthermore, we did not include bone mineral density (BMD), because based on the guidelines, it was not mandatory for all the patients. Limited number of participants is another limitation of the present study. We suggest larger and if possible, randomized controlled studies with longer duration of follow-up for better elucidation of this alternative management technique.

CONCLUSIONS

The results of the present study suggest the beneficial effects of ultrasound-guided ethanol injection in controlling PHP due to parathyroid adenoma, which could be considered as a suitable alternative treatment instead of surgery in patients with contraindication for surgery and significantly lead to better control in the short term and increase the quality of life for a long time. Further investigation on a larger sample size of patients is needed to guarantee the efficacy and safety of the proposed procedure in contrast to surgery method for longer periods of follow-up.

Acknowledgments

The present study was financially supported by Vice Chancellor of Research, Isfahan University of Medical Sciences, Isfahan, Iran, and IEMRC. We gratefully acknowledge the dedicated efforts of the coordinators, especially Professor Ashraf Aminorroaya, Atsa Norouzi, and the patients who participated in this study.

Financial support and sponsorship

Nil.

Conflicts of interest

There are no conflicts of interest.

REFERENCES

- Mackenzie-Feder J, Sirrs S, Anderson D, Sharif J, Khan A. Primary hyperparathyroidism: An overview. *Int J Endocrinol* 2011;2011:251410.
- Piggott RP, Waters PS, Ashraf J, Colesky F, Kerin MJ. Water-clear cell adenoma: A rare form of hyperparathyroidism. *Int J Surg Case Rep* 2013;4:911-3.
- Ruda JM, Hollenbeak CS, Stack BC Jr. A systematic review of the diagnosis and treatment of primary hyperparathyroidism from 1995 to 2003. *Otolaryngol Head Neck Surg* 2005;132:359-72.
- Kandemir O, Kelkit PA, Karakuş K. Synchronous parathyroid adenoma and papillary thyroid carcinoma: 99mTc-MIBI Scan Findings. *Niger J Clin Pract* 2017;20:1510-2.
- Matthews C, Matthews A, Safavi K. Clinical images: Four-dimensional computed tomography-future of preoperative parathyroid adenoma imaging. *Ochsner J* 2017;17:220-2.
- Chigot JP, Menegaux F, Achrafi H. Should primary hyperparathyroidism be treated surgically in elderly patients older than 75 years? *Surgery* 1995;117:397-401.
- Farford B, Presutti RJ, Moraghan TJ. Nonsurgical management of primary hyperparathyroidism. *Mayo Clin Proc* 2007;82:351-5.
- Rizzoli R, Ammann P. Non-surgical treatment of primary hyperparathyroidism. *Acta Endocrinol (Copenh)* 1993;129:375-6.
- Cappelli C, Pelizzari G, Pirola I, Gandossi E, De Martino E, Delbarba A, *et al.* Modified percutaneous ethanol injection of parathyroid adenoma in primary hyperparathyroidism. *QJM* 2008;101:657-62.
- Alherabi AZ, Marglani OA, Alfiky MG, Raslan MM, Al-Shehri B. Percutaneous ultrasound-guided alcohol ablation of solitary parathyroid adenoma in a patient with primary hyperparathyroidism. *Am J Otolaryngol* 2015;36:701-3.
- Cercueil JP, Jacob D, Vergès B, Holtzmann P, Lerais JM, Krause D. Percutaneous ethanol injection into parathyroid adenomas: Mid- and long-term results. *Eur Radiol* 1998;8:1565-9.
- Stratigis S, Stylianou K, Mamalaki E, Perakis K, Vardaki E, Tzenakis N, *et al.* Percutaneous ethanol injection therapy: a surgery-sparing treatment for primary hyperparathyroidism. *Clin Endocrinol (Oxf)* 2008;69:542-8.
- Bilezikian JP, Brandi ML, Eastell R, Silverberg SJ, Udelsman R, Marcocci C, *et al.* Guidelines for the management of asymptomatic primary hyperparathyroidism: Summary statement from the Fourth International Workshop. *J Clin Endocrinol Metab* 2014;99:3561-9.
- Iglesias P, Díez JJ. Current treatments in the management of patients with primary hyperparathyroidism. *Postgrad Med J* 2009;85:15-23.
- Meltzer C, Klau M, Gurushanthaiah D, Titan H, Meng D, Radler L, *et al.* Risk of complications after thyroidectomy and parathyroidectomy: A case series with planned chart review. *Otolaryngol Head Neck Surg* 2016;155:391-401.
- Vergès B, Cercueil JP, Jacob D, Vaillant G, Brun JM. Treatment of parathyroid adenomas with ethanol injection under ultrasonographic guidance. *Ann Chir* 2000;125:457-60.
- Guttin T, Knox VW 4th, Diroff JS. Outcomes for dogs with primary hyperparathyroidism following treatment with percutaneous ultrasound-guided ethanol ablation of presumed functional parathyroid nodules: 27 cases (2008-2011). *J Am Vet Med Assoc* 2015;247:771-7.
- Montenegro FL, Chammas MC, Juliano AG, Cernea CR, Cordeiro AC. Ethanol injection under ultrasound guidance to palliate unresectable parathyroid carcinoma. *Arq Bras Endocrinol Metabol* 2008;52:707-11.
- Harman CR, Grant CS, Hay ID, Hurley DL, van Heerden JA, Thompson GB, *et al.* Indications, technique, and efficacy of alcohol injection of enlarged parathyroid glands in patients with primary hyperparathyroidism. *Surgery* 1998;124:1011-9.
- Shenoy MT, Menon AS, Nazar PK, Moorthy S, Kumar H, Nair V,

- et al.* Radiofrequency ablation followed by percutaneous ethanol ablation leading to long-term remission of hyperparathyroidism. *J Endocr Soc* 2017;1:676-80.
21. Chen HH, Hsu MT, Wu CJ, Chen YW, Yang TL. Effects of percutaneous ethanol injection therapy on subsequent parathyroidectomy. *Am J Surg* 2008;196:155-9.
22. Veldman MW, Reading CC, Farrell MA, Mullan BP, Wermers RA, Grant CS, *et al.* Percutaneous parathyroid ethanol ablation in patients with multiple endocrine neoplasia type 1. *AJR Am J Roentgenol* 2008;191:1740-4.