

# Displaced distal forearm fractures in children with an indication for reduction under general anesthesia should be percutaneously fixated

Pim W. van Egmond · Inger B. Schipper ·  
Peter A. van Luijt

Received: 2 March 2011 / Accepted: 1 June 2011 / Published online: 14 June 2011  
© The Author(s) 2011. This article is published with open access at Springerlink.com

## Abstract

**Purpose** Worldwide, many displaced distal forearm fractures in children are treated by closed reduction under local anesthesia and cast immobilization. If mal-alignment of the fracture persists after initial reduction attempt, final fracture reduction will be performed under general anesthesia, followed by cast immobilization. The purpose of this study was to analyze the results of minimally invasive fixation with K-Wire or ESIN after fracture reduction in children under general anesthesia, compared with the results of closed reduction and plaster immobilization. We hypothesize that primary percutaneous fixation prevents secondary redisplacement and reduces the number of secondary interventions.

**Methods** All skeletally immature children who sustained a distal forearm fracture, and treated under general anesthesia in the operation room (OR), were included. The patients were analyzed according to three treatment groups and fracture type. The primary outcome measure was the number of patients who required a second procedure of fracture reduction after initial treatment.

**Results** A considerable amount of children with displaced distal forearm fractures treated by closed reduction and cast immobilization show loss of reduction and require secondary reduction (43.7%). After closed reduction with

primary internal fixation, with minimally invasive techniques such as K-wires or ESIN, secondary loss of reduction did not occur.

**Conclusions** Additional internal fixation after reduction of a forearm fracture minimizes the secondary displacement risk and the subsequent risk of a re-intervention. Therefore, primary minimal invasive fixation of displaced distal forearm fractures after closed reduction under general anesthesia seems preferable to closed reduction only and is strongly recommended as the preferred treatment strategy.

**Keywords** Pediatric · Distal forearm fractures · Closed reduction · Percutaneous fixation · Secondary reduction

## Introduction

Forearm fractures in childhood are commonly presented in the emergency department (ED) [1]. In fact, 45% of all fractures in childhood are forearm fractures, accounting for 62% of all pediatric upper limb fractures. The location most susceptible to injury is the distal third of the forearm. Worldwide, many displaced distal forearm fractures in children are treated by closed reduction under local anesthesia and cast immobilization. If mal-alignment of the fracture persists after initial reduction attempt, final fracture reduction will be performed under general anesthesia, followed by cast immobilization. Redisplacement within the first 2 weeks after reduction is reported in 7–34% [2–5]. In children with significant remaining growth capacity, remodeling may occur. Generally, in children with remaining growth of 2 or more years, coronal angulations of  $<10^\circ$  and sagittal angulations of  $<30^\circ$  are accepted, expecting that remodeling during growth will correct residual deformity.

P. W. van Egmond · I. B. Schipper · P. A. van Luijt (✉)  
Department of Surgery-Traumatology,  
Leiden University Medical Centre, K6-50,  
PO Box 9600, 2300 RC Leiden, The Netherlands  
e-mail: P.A.van\_Luijt@lumc.nl

P. W. van Egmond  
e-mail: P.W.van\_Egmond@lumc.nl

I. B. Schipper  
e-mail: I.B.Schipper@lumc.nl

If satisfactory alignment cannot be achieved with closed reduction alone, several operative techniques can be used for the fixation of distal forearm fractures. Three-point fixation with pre-bent titanium rods, the so-called Elastic Stable Intramedullary Nailing (ESIN), and standard Kirschner-Wires (K-wires) are most commonly used for the fixation of dislocated distal forearm fractures. ESIN is mainly used in diaphyseal fractures, K-wires primarily in metaphyseal fractures. Many studies published results of these relatively minimally invasive percutaneous fixations and showed these methods to be safe and effective in forearm fractures in children [5, 6–12].

The purpose of this study was to analyze the results of minimally invasive fixation of displaced fractures of the distal forearm with K-Wire or ESIN after fracture reduction in children under general anesthesia, compared with the results of closed reduction and plaster immobilization. We hypothesize that primary percutaneous fixation prevents secondary redisplacement and reduces the number of secondary interventions.

## Materials and methods

This study comprises a retrospective descriptive cohort study in skeletally immature children, with displaced fractures of the distal forearm. The medical records and radiographs of the patients included at the Leiden University Medical Centre, over a period of 10 years, were reviewed.

Eligible patients included all skeletally immature children with displaced extra-articular fractures in the distal forearm, who underwent fracture reduction, either open or closed, with or without percutaneous fixation, under general anesthesia. All other arm fractures, and (non-) displaced distal forearm fractures not needing primary reduction under general anesthesia in the OR, were excluded. Also, patients with radial head, Galeazzi or fractures of the proximal two-thirds forearm and any patient with a pathologic fracture secondary to tumor or bone metabolic disease were excluded from this study. Data were obtained by retrospective analyses of the medical reports of all children with forearm injuries after. All data used were anonymous; therefore, no ethical board approval was needed. The study design was approved by the Scientific Committee of the Leiden University Medical Center.

Patients were subdivided into four AO classification groups by the authors of this study, according to location (metaphysis/diaphysis) and fracture type (complete/greenstick) [13]. When an antebrachii fracture consisted of a complete and a greenstick fracture, it was regarded a complete fracture. When an antebrachii fracture consisted of one bone fractured in the metaphysis and one bone fractured in the diaphysis, it was considered a diaphyseal

fracture. In the AO classification for children, the metaphysis is identified by a square whose side has the same length as the widest part of the bone physis on the AP radiographic view [13].

Skeletal immaturity was defined by open radial and ulnar physes on the radiographs. The patients were treated according to one of the three following treatment strategies: closed reduction alone, closed reduction and percutaneous fixation, and open reduction and percutaneous fixation. All patients were treated under general anesthesia in the OR. The type of treatment used depended on the personal experiences, and preferences, of the operating surgeon. All patients were treated either by an orthopedic surgeon or a trauma surgeon. Percutaneous fixation was performed with ESIN for diaphyseal fractures or with K-wires in the case of metaphyseal fractures. Depending on the age and stability of the fracture, plastercast immobilization was given for 2–4 weeks. Pin wounds were cleaned daily after the removal of the cast. Instructions for mobilization were standardized and given to both parents and the child.

The data collected from the radiographs were measured using standard techniques [14]. The angulations of the fractures were measured in the anteroposterior plane as well as in the lateral plane by the authors of this study. These angles were followed in time and measured after reduction, contingent percutaneous fixation, union and, when available, remodeling during follow-up visits.

A secondary reduction was defined as a fracture reduction that was not conducted in the same session and was again performed under general anesthesia in the OR. A fracture was considered radiological united when a periosteal callus of approximately the same density as the cortex visibly bridged the fracture gap in both the anteroposterior (AP) and lateral plane. Union of the fractures was recorded on the radiographs. The data from the radiograph and the OR were used to calculate the duration until union. If these data were not available, or the final radiographs were missing, the time to union was obtained from the written medical records. Complications, if present, were documented as infections, refractures, malunion, nonunion, and nerve damage.

## Outcome measures

For analysis, the patient groups were divided into three treatment groups, according to their primary treatment under general anesthesia: closed reduction alone, closed reduction with percutaneous fixation, and open reduction with internal fixation. The primary outcome measure was the need for a second fracture reduction or surgical intervention because of redisplacement. A second intervention could involve any of the three treatment options. The secondary outcome measure was the amount of the angulation deformity during follow-up and at union.

## Data analysis

Data were gathered in an SPSS-based database. Statistical analysis was performed using a factorial analysis of variance (ANOVA) for grouped statistics. An  $P$ -value  $<0.05$  was considered statistical significant. All statistical analyses were performed using SPSS version 17.0 for Windows (SPSS Inc., Chicago, IL).

## Results

Over the period 1-1-1997 till 1-1-2007, 251 skeletally immature patients with extra-articular displaced fractures in the distal third of the forearm were treated under general anesthesia in the OR. Forty-three patients were excluded because either the medical chart or the radiographs before or after treatment were missing. The remaining 208 patients, 134 boys and 74 girls, were included for further analysis. The average age at the time of treatment was 9 years (range 3–17,  $SD = 3$ ). The treatment options were closed reduction ( $n = 103$ ), internal fixation after closed reduction ( $n = 89$ ), or internal fixation after open reduction ( $n = 16$ ) (Table 1). Mean follow-up was 22 weeks (range 4–204,  $SD = 32$ ). The average time to union was 49 days (range 23–129). The mean primary displacement angle in the radius or ulna, in both directions, did not differ between treatment groups.

The patients were divided into four groups, according to fracture type. A total of 93 metaphyseal fractures were seen: AO 23 M/2.1 ( $n = 12$ ), AO 23M/3.1 ( $n = 81$ ). Diaphyseal fractures were seen in 115 patients: AO 22D/2.1 ( $n = 18$ ) and AO 22D/3.1 ( $n = 97$ ) (Table 2).

In the group with metaphyseal greenstick fractures (AO 23 M/2.1,  $n = 12$ ), 5 patients were treated with percutaneous fixation (K-wires) after closed reduction, whereas 7 patients were treated by closed reduction alone. Of these 7

**Table 1** Descriptives and results; subdivided for the three treatment groups

|                                            | Closed reduction | CRIF          | ORIF           |
|--------------------------------------------|------------------|---------------|----------------|
| Number of patients                         | 103              | 89            | 16             |
| Male/female                                | 70/33            | 55/34         | 10/6           |
| Age (years $\pm$ SD)                       | 9.3 $\pm$ 3.4    | 9.1 $\pm$ 2.9 | 10.6 $\pm$ 3.5 |
| Average time to bone union (days $\pm$ SD) | 48 $\pm$ 14      | 48 $\pm$ 18   | 56 $\pm$ 22    |
| Wound infection                            | 0                | 2             | 1              |
| Second procedure (CR/CRIF/ORIF)            | 5/32/8           | 0             | 0              |
| Refracture                                 | 2                | 3             | 0              |

CR closed reduction; CRIF closed reduction and internal fixation; ORIF open reduction and internal fixation; SD standard deviation

**Table 2** Subdivision of patients according to fracture type and treatment group

|                  | Fracture type |            |            |            | Total |
|------------------|---------------|------------|------------|------------|-------|
|                  | AO 23M/2.1    | AO 23M/3.1 | AO 22D/2.1 | AO 22D/3.1 |       |
| Treatment method |               |            |            |            |       |
| Closed reduction | 7             | 41         | 11         | 44         | 103   |
| CRIF             | 5             | 37         | 6          | 41         | 89    |
| ORIF             | –             | 3          | 1          | 12         | 16    |
| Total            | 12            | 81         | 18         | 97         | 208   |
| Second reduction |               |            |            |            |       |
| Yes              | 2             | 17         | 4          | 22         | 45    |
| No               | 5             | 24         | 7          | 22         | 58    |
| Total            | 7             | 41         | 11         | 44         | 103   |

And subdivision of patients in the closed reduction without percutaneous fixation group, according to fracture type and the need for a second reduction procedure

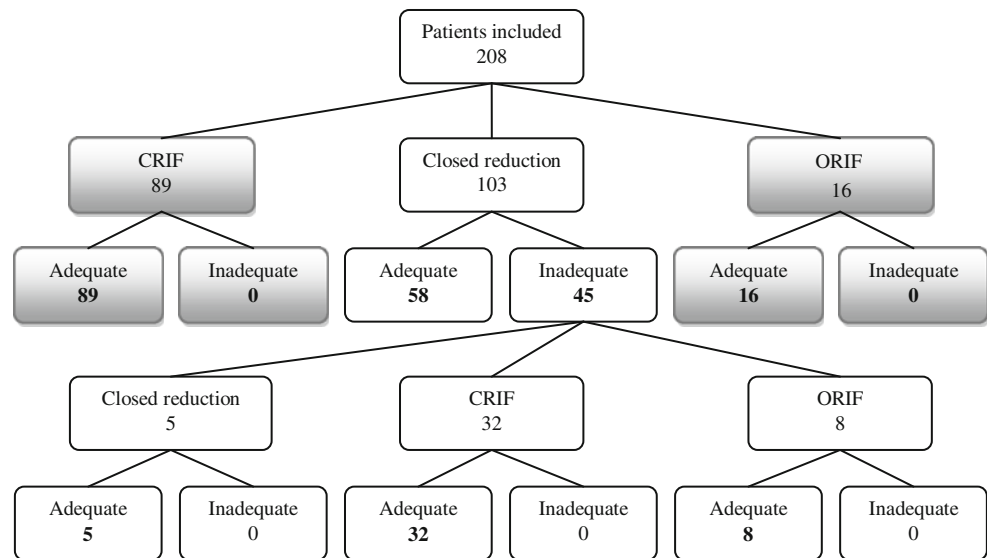
patients, two needed a secondary reduction. This was not significant ( $P = 0.2$ ).

In the group regarding metaphyseal complete fractures (AO 23 M/3.1,  $n = 81$ ), 40 patients were treated by percutaneous fixation (K-wires) after closed ( $n = 37$ ) or open ( $n = 3$ ) reduction. A total of 41 patients were treated by closed reduction alone; of these 17 patients (42%) required secondary reduction, which was a significant difference ( $P = 0.000$ ). None of the patients in the fixation groups required a secondary reduction.

In the diaphyseal groups, similar results were found. In the greenstick fracture subgroup (AO 22D/2.1,  $n = 18$ ), 7 patients were treated with internal fixation (ESIN) after closed ( $n = 6$ ) or open ( $n = 1$ ) reduction, and 11 patients were treated by closed reduction alone. Of these 11 patients, 4 required secondary reduction ( $P = 0.195$ ). In the diaphyseal complete fracture group (AO 22D/3.1,  $n = 97$ ), 53 patients were treated with internal fixation (ESIN) after closed ( $n = 41$ ) or open ( $n = 12$ ) reduction. Another 44 patients were treated with closed reduction alone, of which 22 patients (50%) required secondary reduction ( $P = 0.000$ ). Again, none of the patients in the fixation groups required a secondary reduction.

Overall closed reduction and cast immobilization under general anesthesia were performed in 103 patients. In 45 (43.7%) of these patients, reduction was not maintained, necessitating a second intervention: 32 of these patients were treated with closed reduction and percutaneous fixation, 8 patients with open reduction and internal fixation, and 5 patients underwent a second closed reduction under general anesthesia. In the 105 patients who were primarily treated with closed or open reduction and internal fixation, no secondary procedure was necessary (Fig. 1).

**Fig. 1** Adequate means adequate and stable reduction till union. (*CRIF* closed reduction and internal fixation, *ORIF* open reduction and internal fixation)



No specific fracture type group seemed to be more susceptible for loss of reduction. In each group, roughly the same proportion (25–50%) of patients who had been treated with closed reduction alone needed a secondary reduction (Table 2).

Most fractures were treated by trauma surgeons ( $n = 175$ ), as compared to orthopedic surgeons. Differences in treatment strategy were not significant. The same portion of patients in each fracture type group was treated with closed reduction or internal fixation after open or closed reduction. This was not dependent on the primary displacement angle. Similar percentages of second reduction after closed reduction were seen in the group operated by trauma surgeons (43.2%) and the group operated by orthopedic surgeons (45.5%).

The majority of the patients who were treated under general anesthesia in the OR were between 4 and 13 years old. When all patients were divided by age into two groups: <13 years of age and >13 years of age, there seemed to be a tendency toward treatment with closed reduction in children older than 13 years of age. Patients in the younger age group were primarily treated with closed reduction or CRIF; again the closed reduction group had a high rate of second interventions, whereas the groups with percutaneous fixation needed none (Table 3). No apparent, nor significant, differences in distribution of fracture type or average age at treatment were found between the closed reduction and internal fixation groups.

The average time to union was 6–8 weeks and did not differ significantly between treatment groups.

As mentioned earlier, the mean primary displacement angle in the radius or ulna, in both directions, did not differ between treatment groups. Again, when divided into groups by age and fracture type, the results remained

**Table 3** Subdivision of patients according to treatment method and age

| Treatment method | Age       |           | Total |
|------------------|-----------|-----------|-------|
|                  | <13 years | >13 years |       |
| Closed reduction | 88        | 15        | 103   |
| CRIF             | 82        | 7         | 89    |
| ORIF             | 13        | 3         | 16    |
| Total            | 183       | 25        | 208   |
| Second reduction |           |           |       |
| Yes              | 34        | 11        | 45    |
| No               | 54        | 4         | 58    |
| Total            | 88        | 15        | 103   |

And subdivision of patients in the closed reduction without percutaneous fixation group, according to fracture type and the need for a second reduction procedure

*CRIF* closed reduction and internal fixation, *ORIF* open reduction and internal fixation

comparable, no significant difference in primary displacement angle. However, greenstick fractures of the radius showed a larger primary displacement angle than complete fractures in the closed reduction group (29° vs. 21°,  $P = 0.032$ ). This was only true in the AP direction. No significant difference in residual angulation after union, between the internal fixation after closed reduction group and the internal fixation after open reduction group, was found.

In both the internal fixation after closed reduction group and the internal fixation after open reduction group, the residual angle at the time of union was less compared with the closed reduction group without fixation. This was true for both the radius and ulna and in the anteroposterior as

well as the lateral direction. The difference in angulation favoring both fixation groups was significant concerning the lateral direction of the radius in the fixation after open reduction group. In the fixation after closed reduction group, all angulations at time of union were significantly less compared with the closed reduction-only group. Both internal fixation groups showed similar results (Table 4). These results showed to be the same when analyzed in subgroups for type of fracture and different age groups.

### Complications

Numbers of infections, refractures, malunions, nonunions, compartment syndromes, and of neurovascular injury were analyzed [4, 15]. In our series, we documented 5 refractures, 3 of which occurred in the internal fixation group after removal of hardware and two in the reduction-only group. Two patients were diagnosed with transient nerve damage. In both cases, this nerve damage was sustained during the primary injury and diagnosed before initial treatment. Superficial pin tract infections were seen twice in the percutaneous fixation after closed reduction group, and once in the internal fixation after open reduction group. All three infections healed after removal of the pins at the time of union. A deep infection was not seen. In 198 of the total 208 patients (95.2%), no complications were seen.

### Discussion

The purpose of this study was to analyze the results of minimally invasive fixation of displaced fractures of the distal forearm with K-wire or ESIN after fracture reduction

in children under general anesthesia, compared with the results of closed reduction and plaster immobilization. We hypothesized that primary percutaneous fixation would prevent secondary redisplacement and subsequently would reduce the number of secondary interventions.

The results of our study revealed that after closed reduction and plaster immobilization of distal forearm fractures, redisplacement and second reduction rate occurred in more than forty percent of the patients. When divided for fracture type, this percentage proved to be lower, and for greenstick fractures not significantly different from internal fixated greenstick fractures. None of the internal fixated fractures required a second reduction.

Open or closed fracture reduction with additional internal fixation is generally accepted for adult forearm fractures, but controversy surrounds this treatment method for children. With a greater ability to remodel, closed reduction and cast immobilization are often the method of choice with satisfactory results [12, 16]. A proportion of these pediatric forearm fracture reductions occur under general anesthesia in the OR.

Closed treatment, however, has a reported 7–34% redisplacement, requiring secondary reduction procedure [2, 6–8, 17]. Proctor et al. even found a 73% of redisplacement in completely displaced fractures when reduction was imperfect [6]. In concordance with these previous reports, our study showed that 43.7% of the children treated with unfixed reduction of a displaced fracture in the distal forearm needed a secondary procedure under general anesthesia. Also after subanalyses for age groups and for type of fracture, the rate of a second intervention remained high in the closed reduction group (Table 2). In the metaphyseal and diaphyseal complete fracture type groups

**Table 4** Primary displacement angles of fractures and residual angulation in the follow-up; subdivided according to treatment method

|                                 | Closed reduction | CRIF                   | ORIF                   |
|---------------------------------|------------------|------------------------|------------------------|
| Radius, anteroposterior         | <i>n</i> = 100   | <i>n</i> = 85          | <i>n</i> = 16          |
| Primary displacement            | 23.3 ± 14.2      | 16.6 ± 9.4             | 22.1 ± 13.7            |
| Residual angle displacement     | 9.8 ± 6.7        | 4.3 ± 3.5              | 4.3 ± 2.1              |
| Residual angle at time of union | 5.3 ± 4.9        | 3.5 ± 3.8 <sup>b</sup> | 3.5 ± 2.1              |
| Radius, lateral                 | <i>n</i> = 100   | <i>n</i> = 85          | <i>n</i> = 16          |
| Primary displacement            | 10.7 ± 8.3       | 12.9 ± 12.0            | 12.9 ± 10.1            |
| Residual angle displacement     | 5.0 ± 3.4        | 3.7 ± 3.0              | 3.4 ± 2.1              |
| Residual angle at time of union | 7.7 ± 7.0        | 3.4 ± 3.3 <sup>a</sup> | 3.6 ± 2.5 <sup>d</sup> |
| Ulna, anteroposterior           | <i>n</i> = 84    | <i>n</i> = 82          | <i>n</i> = 14          |
| Primary displacement            | 20.5 ± 16.8      | 23.9 ± 15.7            | 19.7 ± 13.9            |
| Residual angle displacement     | 6.4 ± 4.6        | 3.0 ± 1.4              | 3.2 ± 2.6              |
| Residual angle at time of union | 5.0 ± 4.2        | 3.6 ± 3.1 <sup>c</sup> | 4.1 ± 2.5              |
| Ulna, lateral                   | <i>n</i> = 84    | <i>n</i> = 82          | <i>n</i> = 14          |
| Primary displacement            | 12.7 ± 13.2      | 17.7 ± 17.0            | 15.7 ± 11.7            |
| Residual angle displacement     | 4.3 ± 3.3        | 2.6 ± 2.0              | 2.0 ± 1.3              |
| Residual angle at time of union | 5.4 ± 4.7        | 3.3 ± 2.6 <sup>a</sup> | 3.6 ± 2.4              |

Significance of difference versus closed reduction:

<sup>a</sup> *P* ≤ 0.001; <sup>b</sup> *P* = 0.012;

<sup>c</sup> *P* = 0.020; <sup>d</sup> *P* = 0.043

(AO 23M/3.1 and AO 22D/3.1), this was significantly higher. In the smaller greenstick fracture groups (AO 23 M/2.1 and AO 22D/2.1), the same tendency was seen. However, in these two smaller groups, there was no significance. Because none of the internally fixated fractures required a secondary reduction and in both greenstick fracture groups redisplacement after closed reduction was more than 25%, we feel internal fixation can also be of additional value in stabilizing greenstick fractures.

Distal forearm fractures in children that need reduction under general anesthesia are a selected group of patients, in which satisfactory alignment after closed reduction under local anesthesia and cast immobilization could not be achieved. Especially in this group, additional fixation, to stabilize the fracture, can be of aid.

Intramedullary nailing with ESIN, for diaphyseal fractures, allows accurate fracture reduction, provides stabilization for fracture healing, results in minimal cosmetic deformity, and allows easy removal of hardware. Many studies have shown that minimal invasive internal fixation, with either K-wires or ESIN, is a safe and effective procedure that can provide precise fracture reduction and maintains stabilization for fracture healing [10, 11, 18–21]. Flynn et al. discussed the complications of operative management of pediatric forearm fractures and concluded differently [22]. They found a complication rate of 14.6% in their study group, with a 6.7% reported incidence of compartment syndrome. In our study, we did not encounter such high complication rates or a compartment syndrome.

In this study, the patients were followed up to union of the fracture. The remaining angulation at the consolidated fracture area was less in both fixation groups, compared with the plaster cast immobilization group. This means better alignment at union. A study concerning this topic found small fracture displacements ( $5^{\circ}$ – $10^{\circ}$ ) of the midshaft of the forearm to result in a 17–90% reduction of normal pronation and a 73–95% reduction of supination [23].

In children, the potential for distal forearm displacement correction is immense because of the great remodeling potential of the bone. Depending on patient age and deformity direction, angulations of  $10^{\circ}$ – $15^{\circ}$  are accepted. Although many of these angulations will remodel to near anatomical position, in some patients a residual angulation will remain, which may cause limitation of function [5, 24].

Internal fixation seems to have better alignment at union and, thus, would theoretically have better results. The authors of a Cochrane study regarding this topic suggested that external fixation and percutaneous pin fixation give better radiographic outcomes and may have better functional outcomes when compared with cast immobilization.

In the current study, we did not intend to compare functional outcomes in the different treatment groups. Although the alignment at the time of union in the fixation

groups was better than in the closed reduction group, we do not deem this clinically relevant. All displacement angles at the time of union were within  $10^{\circ}$ , and many authors have shown that complete remodeling of those displacement angles will occur.

Some marginal objective, and transient, loss of function could be expected in some of the patients in this study. Although none, so far, have reported or been objectified with such complaints. This is not surprising since the majority of daily activities can be performed with a rotation range of  $100^{\circ}$ , equally divided for pronation and supination [25]. Furthermore, even if there is an objective limitation of rotation, and thus function, patients are not inclined to present with complaints [26].

In our study, we were not able to ascertain the surgeons' motivation for the choice of treatment method in the OR. In retrospect, we did not find any substantial differences in primary displacement or fracture type between the treatment groups. This supported our empirical proposition that treatment method mainly depends on the treating surgeon. The ORIF group, however, is far too small to understate this conclusion. In this specific group, the most common cause of conversion to open reduction is thought to be soft tissue interposition [27].

Because of the retrospective nature of this study, we could not account for possible deviations in plaster technique, which may be seen as a limitation of this study. Three-point molding was always the preferred splinting technique. Furthermore, we were not able to specify the exact reason for individual choices of treatment by surgeons, including the decision to remanipulate the fracture and to proceed to open reduction and/or internal fixation or not. The interpretation of an inadequate reduction was not always recorded in the medical records. However, an angulation greater than can be accepted considering the age of the child or a loss of reduction, indicating an unstable fracture, were the main arguments for a second reduction. Also, we did not document the long-term clinical outcome in patients.

A randomized controlled trial in which the internal fixation of distal forearm fractures in children is compared with closed reduction in patients, who are treated under general anesthesia in the OR, would be ideal. Patients should be subdivided for metaphyseal/diaphyseal and complete/greenstick fractures with attention to plaster technique, reason of second reduction and radiographic follow-up.

## Conclusion

A considerable amount of children with displaced distal forearm fractures treated by closed reduction and cast immobilization show loss of reduction and require secondary reduction (43.7%). Closed reduction with primary

internal fixation, with minimally invasive techniques such as K-wires or ESIN, reduced the rate of secondary loss of reduction, and subsequent re-interventions, to 0%. The complication rate of percutaneous fixation is low, whereas the benefits of stable fixation and optimal alignment are clearly present. Therefore, primary minimal invasive fixation of displaced distal forearm fractures after closed reduction under general anesthesia seems preferable to closed reduction only. To end controversy in the treatment of these fractures, detailed prospective studies are necessary.

**Conflict of interest** The authors of this article do not have any financial or personal relationships with other people, or organizations, that could inappropriately influence this article. There are no conflicts of interest.

**Open Access** This article is distributed under the terms of the Creative Commons Attribution Noncommercial License which permits any noncommercial use, distribution, and reproduction in any medium, provided the original author(s) and source are credited.

## References

- Bachmann D, Santora S (2000) Orthopedic trauma. In: Fleischer G, Ludwig S, Henretig FM (eds) Textbook of pediatric emergency medicine. Lippincott Williams & Wilkins, Philadelphia, pp 1455–1557
- Kreder HJ, Agel J, McKee MD, Schemitsch EH, Stephen D, Hanel DP (2006) A randomized, controlled trial of distal radius fractures with metaphyseal displacement but without joint incongruity: closed reduction and casting versus closed reduction, spanning external fixation, and optional percutaneous K-wires. *J Orthop Trauma* 20:115–121
- Lee S, Nicol RO, Stott NS (2002) Intramedullary fixation for pediatric unstable forearm fractures. *Clin Orthop Relat Res* 402:245–250
- Van der Reis WL, Otsuka NY, Moroz P, Mah J (1998) Intramedullary nailing versus plate fixation for unstable forearm fractures in children. *J Pediatr Orthop* 18:9–13
- Yung SH, Lam CY, Choi KY, Ng KW, Maffulli N, Cheng JC (1998) Percutaneous intramedullary Kirschner wiring for displaced diaphyseal forearm fractures in children. *J Bone Joint Surg Br* 80:91–94
- Proctor MT, Moore DJ, Paterson JM (1993) Redisplacement after manipulation of distal radial fractures in children. *J Bone Joint Surg Br* 75:453–454
- Voto SJ, Weiner DS, Leighley B (1990) Redisplacement after closed reduction of forearm fractures in children. *J Pediatr Orthop* 10:79–84
- Zamzam MM, Khoshhal KI (2005) Displaced fracture of the distal radius in children: factors responsible for redisplacement after closed reduction. *J Bone Joint Surg Br* 87:841–843
- Deluca PA, Lindsey RW, Ruwe PA (1988) Refracture of bones of the forearm after the removal of compression plates. *J Bone Joint Surg Am* 70:1372–1376
- Qidwai SA (2001) Treatment of diaphyseal forearm fractures in children by intramedullary Kirschner wires. *J Trauma* 50:303–307
- Yung PS, Lam CY, Ng BK, Lam TP, Cheng JC (2004) Percutaneous transphyseal intramedullary Kirschner wire pinning: a safe and effective procedure for treatment of displaced diaphyseal forearm fracture in children. *J Pediatr Orthop* 24:7–12
- Schmittbecher PP, Fitze G, Godeke J, Kraus R, Schneidmuller D (2008) Delayed healing of forearm shaft fractures in children after intramedullary nailing. *J Pediatr Orthop* 28:303–306
- Slongo T, Audige L, Schlickewei W, Clavert JM, Hunter J (2006) Development and validation of the AO pediatric comprehensive classification of long bone fractures by the pediatric expert group of the AO foundation in collaboration with AO clinical investigation and documentation and the international association for pediatric traumatology. *J Pediatr Orthop* 26:43–49
- Greenspan A (2000) Orthopedic radiology: a practical approach. Lippincott Williams & Wilkins, Philadelphia
- Bednar DA, Grandwilewski W (1992) Complications of forearm-plate removal. *Can J Surg* 35:428–431
- Zionts LE, Zalavras CG, Gerhardt MB (2005) Closed treatment of displaced diaphyseal both-bone forearm fractures in older children and adolescents. *J Pediatr Orthop* 25:507–512
- Rodriguez-Merchan EC (2005) Pediatric fractures of the forearm. *Clin Orthop Relat Res* 432:65–72
- Choi KY, Chan WS, Lam TP, Cheng JC (1995) Percutaneous Kirschner-wire pinning for severely displaced distal radial fractures in children. A report of 157 cases. *J Bone Joint Surg Br* 77:797–801
- Lascombes P, Haumont T, Journeau P (2006) Use and abuse of flexible intramedullary nailing in children and adolescents. *J Pediatr Orthop* 26:827–834
- Flynn JM, Waters PM (1996) Single-bone fixation of both-bone forearm fractures. *J Pediatr Orthop* 16:655–659
- Waseem M, Paton RW (1999) Percutaneous intramedullary elastic wiring of displaced diaphyseal forearm fractures in children. *Injury* 30:21–24
- Flynn JM, Jones KJ, Garner MR, Goebel J (2010) Eleven years experience in the operative management of pediatric forearm fractures. *J Pediatr Orthop* 30:313–319
- Tarr RR, Garfinkel AI, Sarmiento A (1984) The effects of angular and rotational deformities of both bones of the forearm. An in vitro study. *J Bone Joint Surg Am* 66:65–70
- Richter D, Ostermann PA, Ekkernkamp A, Muhr G, Hahn MP (1998) Elastic intramedullary nailing: a minimally invasive concept in the treatment of unstable forearm fractures in children. *J Pediatr Orthop* 18:457–461
- Morrey BF, Askew LJ, Chao EY (1981) A biomechanical study of normal functional elbow motion. *J Bone Joint Surg Am* 63:872–877
- Daruwalla JS (1979) A study of radioulnar movements following fractures of the forearm in children. *Clin Orthop Relat Res* 139:114–120
- Lascombes P, Prevot J, Ligier JN, Metaizeau JP, Poncelet T (1990) Elastic stable intramedullary nailing in forearm shaft fractures in children: 85 cases. *J Pediatr Orthop* 10:167–171