



Case report

Pulmonary hemorrhage following anabolic agent abuse: Two cases

Helene S. Hvid-Jensen^{a, *}, Finn Rasmussen^b, Elisabeth Bendstrup^a^a Department of Respiratory Diseases and Allergy, Aarhus University Hospital, Noerrebrogade 44, DK-8000, Aarhus, Denmark^b Department of Radiology, Aarhus University Hospital, Noerrebrogade 44, DK-8000, Aarhus, Denmark

ARTICLE INFO

Article history:

Received 15 January 2016

Received in revised form

6 April 2016

Accepted 11 April 2016

ABSTRACT

Numerous adverse effects follow anabolic agent abuse. Pulmonary hemorrhage is not considered one of them. We present two cases of young male bodybuilders who developed diffuse alveolar bleeding as a result of anabolic steroid abuse. Diffuse alveolar hemorrhage associated with anabolic agent abuse has not been described previously in the literature. Both patients developed acute dyspnea and hemoptysis with consistent radiological findings. In both cases symptoms promptly resolved with cessation of exposure and no medical intervention was required and no signs of persistent lung damage were seen. It is crucial to be aware of pulmonary hemorrhage as an acute complication of anabolic agent abuse. It should be considered an important differential diagnosis in the athletic patient presenting with respiratory symptoms.

© 2016 The Authors. Published by Elsevier Ltd. This is an open access article under the CC BY-NC-ND license (<http://creativecommons.org/licenses/by-nc-nd/4.0/>).

1. Introduction

Abuse of anabolic agents is associated with numerous adverse effects including cardiac and thromboembolic complications [1,2] cerebral hemorrhagic infarction [3,4] and intraabdominal hemorrhage [5–7]. Previously, the literature has not reported on pulmonary hemorrhage related to anabolic steroids abuse. We report two cases with young bodybuilders experiencing diffuse pulmonary hemorrhage following anabolic steroids abuse.

1.1. Case 1

A 26-year old man presented in the emergency room with malaise, dyspnea and hemoptysis. He had a history of intermittent anabolic steroid abuse (AS) to enhance the results of his bodybuilding exercises. Six weeks prior to admission he had resumed abuse, taking metandienone (60 mg p.o. daily), 57 testosterone enanthate (1000 mg i.m. weekly), nandrolone (1 ampoule i.m. weekly) and rapid-acting insulin (16l U s.c. daily). He denied any other drug abuse and used no other types of medication. Prior to admission he described five days with malaise, night sweats, dyspnea, cough and bloody sputum. Except for tachypnea and testicular atrophy, the physical exam was normal. Routine laboratory testing showed only marginally increased C-reactive protein

(12.0 mg/l), leukocytes $13.0 \times 10^9/l$ and creatinine 142 $\mu\text{mol/l}$. Apart from a marginally elevated platelet count ($378 \times 10^9/l$) and International Normalized Ratio (INR) at 1.3 coagulation studies were within normal limits. Troponin T was marginally elevated (20 ng/l) but this normalised spontaneously within 4 h. The other parameters, including arterial blood gases, were normal. Chest x-ray showed left apical infiltration and basal atelectasis. An echocardiography was performed showing slightly above-average right and left ventricle size, normal ejection fraction and a slightly elevated tricuspid regurgitation gradient of 27–30 mmHg, indicates a marginally elevated pulmonary arterial pressure. High resolution computed tomography (HRCT) showed areas of ground-glass opacity in both lungs predominantly in peripheral regions; this caused suspicion of diffuse alveolar hemorrhage (Fig. 1). The patients was referred to our hospital 10 days later where a bronchoscopy revealed no abnormal findings apart from increased vascularisation of the bronchial mucosa. Microbiological and pathological studies of the bronchoalveolar lavage (BAL) were normal, including white blood cell differential and only few red blood cells were detected. Additional blood tests showed normal levels of immunoglobulin, a negative autoantibodies test and a negative interferon gamma release assay (T-spot) were made. The patient received no further medical treatment. Two and six months following discharge a renewed HRCT showed complete disappearance of the previously described findings. Lung function and diffusion capacity for carbon monoxide were normal. He denied re-exposure to AS since admission.

* Corresponding author. Vestre Ringgade 80B, 8000, Aarhus C, Denmark.
E-mail address: Helene_email@yahoo.dk (H.S. Hvid-Jensen).

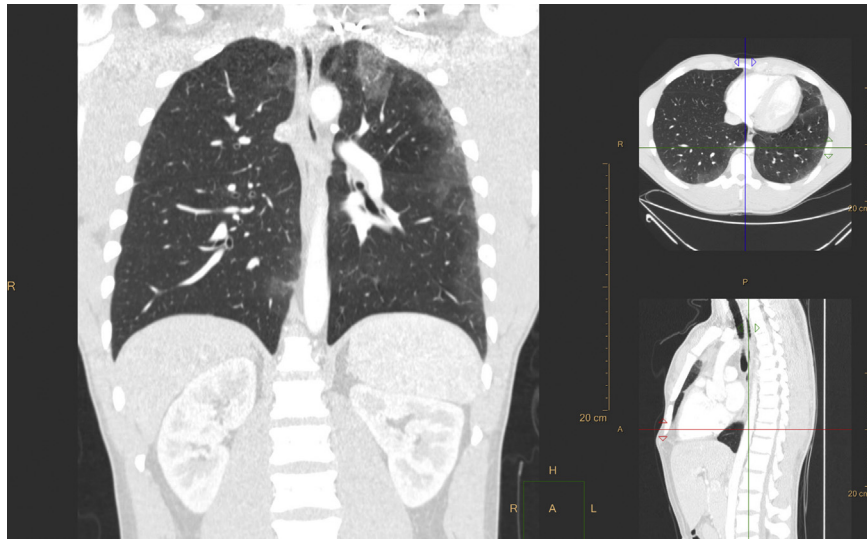


Fig. 1. HRCT showed patchy areas with ground glass opacities located primarily in the periphery of the lungs.

1.2. Case II

A previously healthy 19-year-old man presented in the emergency room with a two-week history of cough and increasing dyspnea. The past two days he had experienced hemoptysis. He reported a 3-year history of anabolic agent polydrug abuse. Two weeks prior to admission, abuse had escalated; content consisted of a mixture of oxymetholone (p.o.), methandriol (p.o.), trienolone (i.m.) and nandrolone (i.m.). Specific dosages could not be specified, as the patient had no clear recollection. He took no medication, including anticoagulants, and denied any additional abuse of drugs. On admission he was tachypneic, otherwise the physical examination was normal. Laboratory tests showed marginally increased C-reactive protein (14.0 mg/l). Other parameters, including leucocytes and differential count were normal. D-dimer was slightly elevated (0.72 mg/l FEU), additional coagulation studies were within normal limits. Blood gasses demonstrated slight hypoxemia (arterial PO₂ 9.6 kPa) with no hypercapnia (arterial PCO₂ 4.7 kPa). Spirometry showed slightly reduced forced expiratory volume in 1 second (FEV₁) of 3.38 L (74%) and forced vital capacity (FVC) of 4.53 L (83%). A heart ultrasonography was normal. A chest CT showed large areas of patchy ground glass in the periphery of the lung parenchyma consistent with diffuse alveolar bleeding (Fig. 2). Bronchoscopy three days after admission revealed multiple small blood clots in bilateral airways. The bronchoalveolar lavage fluid was bloody with 20% hemosiderin-containing macrophages. There was no sign of infectious micro-organisms and the white blood cell count was normal. Transbronchial lung biopsies revealed alveolar tissue with diffuse bleeding and hemosiderin-laden macrophages. Additional blood tests showed normal levels of immunoglobulin and negative autoantibodies. He was diagnosed with drug-induced alveolar hemorrhage. The patient was discharged without medication and two weeks later he reported disappearance of pulmonary symptoms. Three and a half months following admission a new HRCT showed disappearance of the previous findings. Spirometry had normalised with FEV₁ of 5.56 L (122%) and FVC of 6.74 L (124%). He no longer abused anabolic agents.

2. Discussion

Diffuse alveolar hemorrhage (DAH) is characterised by bleeding into the alveolar spaces of the lungs due to disruption of the

alveolar-capillary basement membrane. Clinical signs of the syndrome are dyspnea, hemoptysis, hypoxemic respiratory failure and diffuse pulmonary infiltrates, but may be present in variable proportions. DAH should be considered a potentially life-threatening disorder due to the significant morbidity and mortality [8]. Common conditions known to be associated with DAH include autoimmune diseases (such as polyangiitis and granulomatosis formerly known as Wegener's granulomatosis and Goodpasture syndrome), sepsis and endocarditis [9]. The diagnosis is made by bronchoscopy with BAL, laboratory tests, including coagulation assays, platelet counts and , and a HRCT. On HRCT alveolar hemorrhage is most often demonstrated as diffuse areas with ground glass shadowing. Here, we report two cases of clinically relevant diffuse alveolar hemorrhage associated with anabolic agent abuse. While AS abuse is known to cause hemorrhage in other organs such as the liver and brain [2,5], pulmonary hemorrhage due to AS abuse has not previously been reported. In both cases the patients' symptoms and HRCT findings promptly disappeared following cessation of AS use. No medical intervention was needed and both patients showed no signs of persistently reduced lung function. The use of injectable compounds dissolved in oil or silicone has been described to be associated in rare cases with systemic complications and acute respiratory distress [9,10]. Pathophysiology remains unclear but is believed to be comparable with the mechanisms involved in fat embolism syndrome (FES), involving a ventilation-perfusion mismatch combined with local and systemic toxic and inflammatory responses. Acute chest syndrome associated with fluid silicone, most often used for cosmetic purposes in transsexual individuals, is known as the silicone embolism syndrome. Patients develop amongst other chemical pneumonitis and alveolar hemorrhage. The clinical presentation varies but usually involves acute onset of fever, dyspnea, tachycardia, hemoptysis and neurological symptoms. In silicone embolism syndrome, the symptoms usually present within the first few hours following injection [10]. Radiological findings typically reveal focal areas of consolidation and ground glass predominantly in the peripheral and basilar regions. There is one case report of a patient with oil-embolism syndrome following accidental intravenous administration of an oil-steroid solution [11]. This patient developed acute respiratory distress and hypoxemia 24 hours after injection. In our two cases the patients reported abusing testosterone enanthate, an oil-based injectable steroid solution. We were unable to detect the precise

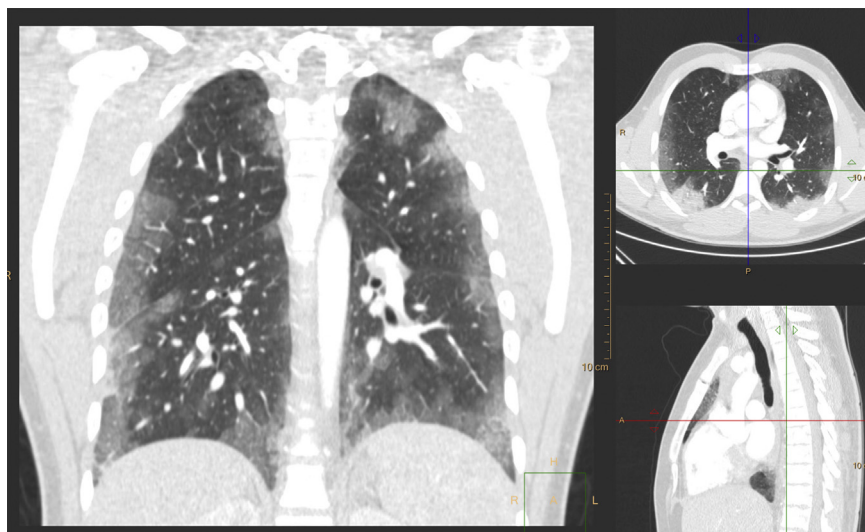


Fig. 2. HRCT showed large areas with ground glass opacities in the periphery of the lung parenchyma.

excipient in the present cases. The most common excipient for testosterone enanthate is vegetable oil, such as castor or sesame oil, which can cause lung problems [12,13]. In both cases the patients' symptoms slowly progressed over days/weeks and there was no information about possible accidental intravenous administration of the steroid solutions. Neither of the patients reported symptom onset directly related to the time of injection. The symptomatology of FES, silicone emboli syndrome and DAH is in many ways similar and the radiological findings can be comparable but are not always diagnostic. In the case of acute symptom onset and suspicion of accidental intravenous administration of the steroid solution, pulmonary embolism should be considered as a possible though rare differential diagnosis. Due to the low incidence of symptomatic events, radiological findings, bronchoalveolar lavage, clinical presentation and the patient's history can help make the diagnosis. Although long-term effects of AS abuse such as myocardial hypertrophy and thromboembolic complications are known. Our cases illustrate the importance of raising awareness of the 180 acute and possibly life-threatening adverse effects of anabolic steroid abuse. In the case of HRCT, findings with predominantly ground glass opacity primarily in the peripheral regions in an extremely athletic patient, suspicion of anabolic agents induced DAH should be considered. If DAH is suspected, bronchoscopy should be performed immediately to establish. The diagnosis and withdrawal of the suspected drug is crucial.

Conflicts of interest

None declared.

References

- [1] J.P. Higgins, A. Heshmat, C.L. Higgins, Androgen abuse and increased cardiac risk, *South Med. J.* 105 (12) (2012) 670–674.
- [2] M.C. Kennedy, A.B. Corrigan, S.T. Pilbeam, Myocardial infarction and cerebral haemorrhage in a young body builder taking anabolic steroids, *Aust. N. Z. J. Med.* 23 (6) (1993) 713.
- [3] J. Moss-Newton, Anabolic steroid use and cerebellar haemorrhage, *Med. J. Aust.* 158 (11) (1993) 794.
- [4] Z. Shiozawa, S. Tsunoda, A. Noda, M. Saito, H. Yamada, Cerebral hemorrhagic infarction associated with anabolic steroid therapy for hypoplastic anemia, *Angiology* 37 (10) (1986) 725–730.
- [5] N.M. Martin, B.K. Abu Dayyeh, R.T. Chung, Anabolic steroid abuse causing recurrent hepatic adenomas and hemorrhage, *World J. gastroenterol.* 14 (28) (2008) 4573–4575.
- [6] S. Bagia, P.M. Hewitt, D.L. Morris, Anabolic steroid-induced hepatic adenomas with spontaneous haemorrhage in a bodybuilder, *Aust. N. Z. J. Surg.* 70 (9) (2000) 686–687.
- [7] J. Schumacher, G. Muller, K.F. Klotz, Large hepatic hematoma and intra-abdominal hemorrhage associated with abuse of anabolic steroids, *N. Engl. J. Med.* 340 (14) (1999) 1123–1124.
- [8] A. Parrot, M. Fartoukh, J. Cadranet, Alveolar hemorrhage, *Rev. Mal. Respir.* 32 (4) (2015) 394–412.
- [9] R.J. Meyer, M. Mann, Pulmonary oil micro-embolism (POME) syndrome: a review and summary of a large case series, *Curr. Med. Res. Opin.* 31 (4) (2015) 837–841.
- [10] S. Bartsich, J.K. Wu, Silicone emboli syndrome: a sequela of clandestine liquid silicone injections. A case report and review of the literature, *J. plastic, Reconstr. aesthet. Surg. JPRAS* 63 (1) (2010) e1–3.
- [11] M. Russell, A. Storck, M. Ainslie, Acute respiratory distress following intravenous injection of an oil-steroid solution, *Can. Respir. J.* 18 (4) (2011) e59–61.
- [12] J.R. Hain, Subcutaneous corn oil injections, fat embolization syndrome, and death, *Am. J. Forensic Med. Pathol.* 30 (4) (2009) 398–402.
- [13] H. Kiyokawa, K. Utsumi, K. Minemura, I. Kasuga, Y. Torii, M. Yonemaru, et al., Fat embolism syndrome caused by vegetable oil injection, *Intern Med.* 34 (5) (1995) 380–383.