

OPEN

# Interface Fluid Syndrome Induced by Uncontrolled Intraocular Pressure Without Triggering Factors After LASIK in a Glaucoma Patient

## A Case Report

Nobuyuki Shoji, MD, PhD, Akira Ishida, MD, Takahiro Haruki, MD, Kazuhiro Matsumura, MD, Masayuki Kasahara, MD, PhD, and Kimiya Shimizu, MD, PhD

**Abstract:** This study sought to describe a glaucoma patient with interface fluid syndrome (IFS) induced by uncontrolled intraocular pressure (IOP) without triggering factors after laser in situ keratomileusis (LASIK).

Case report and review of the literature.

A 23-year-old man with open-angle glaucoma underwent bilateral LASIK for myopia in 2009. Two years later, the patient reported sudden vision loss. The IOP in the right eye was not measurable using Goldmann applanation tonometry (GAT), but was determined to be 33.7 mm Hg using a noncontact tonometer. IFS was diagnosed based on the presence of space-occupying interface fluid on anterior segment optical coherence tomography images. After a trabeculectomy was performed, the IOP decreased to 10 mm Hg, and GAT measurement became possible. However, the corneal fold remained visible in the flap interface. Six months later, the IOP in the left eye increased, and a trabeculectomy was performed during the early stages of this increase in IOP. Following this procedure, the IOP decreased, and visual acuity remained stable.

In glaucoma cases that involve a prior increase in IOP, IOP can continue to increase during the disease course even if temporary control of IOP has been achieved. If LASIK is performed in such cases, the treatment of glaucoma becomes insufficient because of underestimation of the typical IOP. In fact, the measurement of IOP can become difficult because of high-IOP levels. Therefore, LASIK should not be performed on patients with glaucoma who are at high risk of elevated IOP.

(*Medicine* 94(39):e1609)

**Abbreviations:** GAT = Goldmann applanation tonometry, HFA = Humphrey Field Analyzer, IFS = interface fluid syndrome, IOP =

intraocular pressure, LASIK = laser in situ keratomileusis, MD = mean deviation, MMC = mitomycin C, NCT = noncontact tonometer, VA = visual acuity.

## INTRODUCTION

Interface fluid syndrome (IFS) can develop after laser in situ keratomileusis (LASIK). If IFS occurs, intraocular pressure (IOP) measurements become unreliable. As a result, glaucomatous optic neuropathy progresses, followed by a detectable increase in IOP and a rapid decline in visual function.<sup>1–10</sup>

Reports have described IFS cases resulting from increased IOP secondary to postoperative steroid administration<sup>1–6,10</sup> or to corneal endothelial dysfunction triggered by scleral buckling surgery for retinal detachment,<sup>7,8</sup> a shallow anterior chamber after trabeculectomy,<sup>9</sup> or uveitis.<sup>11</sup> To our knowledge, no reports have described the development of IFS because of uncontrolled IOP after LASIK during glaucoma management in the absence of these triggering factors. In this study, we report on a patient who underwent LASIK after IOP had been controlled using topical antiglaucoma medications. Two years later, despite the absence of triggers such as steroid use or a history of previous ocular surgery, IFS developed in association with IOP elevation and marked loss of visual function.

## PRESENTING CONCERNS

A 23-year-old man was diagnosed with glaucoma at an eye clinic in January 2009 based on elevated IOP in the right eye, and treatment with an unspecified topical antiglaucoma medication was initiated. One month later, the patient was informed that the IOP had normalized, and he spontaneously terminated the use of antiglaucoma eye drops. Approximately 6 months later, the patient underwent LASIK for myopia at a LASIK center. He underwent several medical examinations after LASIK, but he did not report glaucoma at that center. Therefore, he had not used any antiglaucoma medication after LASIK. In September 2010, an eye doctor at another clinic measured an IOP of 29 mm Hg in the right eye and 16 mm Hg in the left eye using noncontact tonometer (NCT). Topical latanoprost 0.005% (Pfizer Inc, New York, NY) once daily and topical timolol maleate 0.5% twice daily in the right eye were initiated, and the patient was referred to Kitasato University Hospital for further management.

## CLINICAL FINDINGS

At the hospital, Goldmann applanation tonometry (GAT) revealed IOPs of 13 and 14 mm Hg, and NCT revealed IOPs of 13.9 and 15.2 mm Hg in the right and the left eye, respectively.

Editor: Iok-Hou Pang.

Received: June 28, 2015; revised: August 21, 2015; accepted: August 25, 2015.

From the Orthoptics and Visual Science Course (NS), Kitasato University School of Allied Health Sciences; and Department of Ophthalmology (NS, AI, TH, KM, MK, KS), Kitasato University Hospital, Kanagawa, Japan.

Correspondence: Nobuyuki Shoji, Orthoptics and Visual Science Course, Kitasato University School of Allied Health Sciences, 1-15-1 Kitasato, Minami-ku, Sagami-hara, Kanagawa 252-0373, Japan (e-mail: nshoji@kitasato-u.ac.jp).

This study was conducted in accordance with the Declaration of Helsinki, and written informed consent was obtained from the subject after the study was approved by the Ethics Committee of Kitasato University Hospital (B14-53).

The authors have no funding and conflicts of interest to disclose.

Copyright © 2015 Wolters Kluwer Health, Inc. All rights reserved.

This is an open access article distributed under the Creative Commons Attribution-NonCommercial-NoDerivatives License 4.0, where it is permissible to download, share and reproduce the work in any medium, provided it is properly cited. The work cannot be changed in any way or used commercially.

ISSN: 0025-7974

DOI: 10.1097/MD.0000000000001609

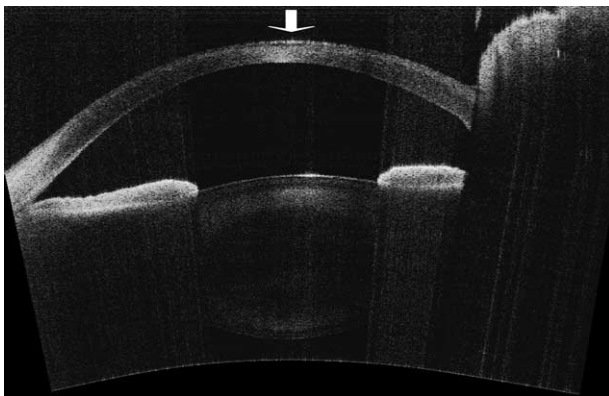
No opacity or edema was observed in the flap or the interface, and there was no inflammation in the anterior chamber. Gonioscopy indicated an open angle. Funduscopy revealed cup-to-disc ratios of approximately 0.9 in the right eye, along with superior and inferior rim thinning, and 0.7 in the left eye. An attached referral form indicated that the Humphrey Field Analyzer (HFA; Carl Zeiss Meditec Inc, Dublin, CA) mean deviations (MDs) were  $-25.28$  dB in the right eye and  $-1.85$  dB in the left eye using the Swedish interactive threshold algorithm standard 30-2 program.

The patient's medical history revealed that before undergoing LASIK, the patient had worn contact lenses to correct  $-8$  diopters (D) of myopia, with the assumption that the measured IOP of 4 to 5 mm Hg was underestimated.<sup>12</sup> On follow-up, the IOP in the right eye decreased to 9 to 11 mm Hg (GAT) until December 2010.

On June 6, 2011, the patient presented to our hospital because of significantly blurred vision. The visual acuity (VA) of the right eye was hand motion, and GAT measurement was impossible because the inner edges of the 2 fluorescein semicircles in the prism head were blurred and irresolvable. The IOP was presumed to be high (at least 30 mm Hg) based on digital palpation and the positioning of the outer edges of the fluorescein semicircles. An intravenous mannitol drip was immediately administered, and the IOP decreased to 24.0 mm Hg, as measured using an NCT. Oral acetazolamide (500 mg/d and 2 types of antiglaucoma eye drops were prescribed.

#### DIAGNOSTIC FOCUS AND ASSESSMENT

On June 13, 2011, GAT measurement of the right eye remained impossible. The IOP measured using an NCT was 33.7 mm Hg. Pachymetry measurements indicated that the central corneal thickness was  $540\ \mu\text{m}$  in the right eye and  $490\ \mu\text{m}$  in the left eye. The corneal endothelial cell densities were  $2414/\text{mm}^2$  in the right eye and  $2521/\text{mm}^2$  in the left eye. Minimal opacity was detected in the flap interface, and no substantial water gap was observed based on slit-lamp examination (Figure 1); however, an optically empty space corresponding to an interface fluid pocket was detected using AXSUN anterior optical coherence tomography (Kitasato University, Kanagawa, Japan).<sup>13</sup> IFS was diagnosed based on these clinical findings and the patient's clinical course.



**FIGURE 1.** Anterior segment findings for the right eye on July 4, 2011. An anterior segment optical coherence tomography image of the right eye. The arrow indicates a small empty space corresponding to an interface fluid pocket visualized using AXSUN anterior optical coherence tomography.<sup>13</sup>

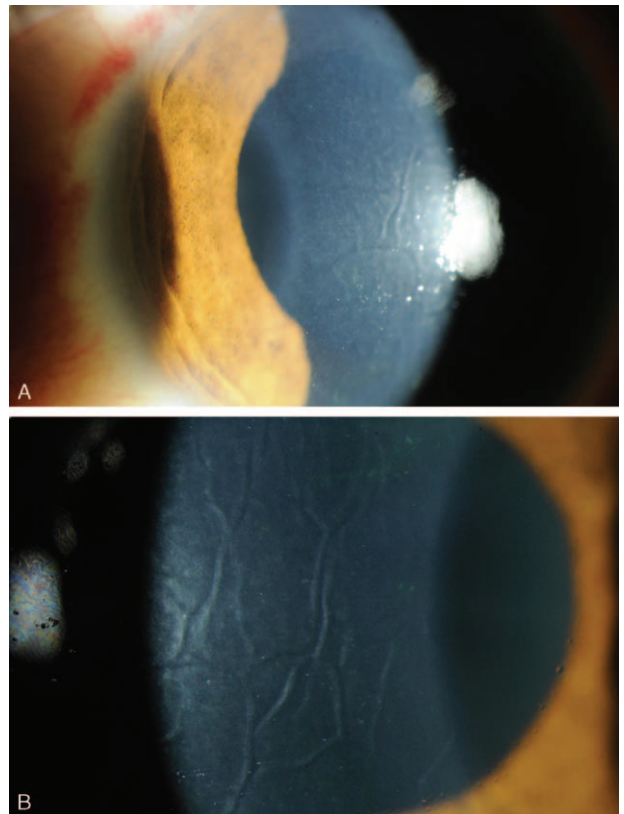
#### THERAPEUTIC FOCUS AND ASSESSMENT

On July 13, 2011, a trabeculectomy with mitomycin C (MMC) was performed on the patient's right eye. The IOP of the right eye was measured postoperatively by GAT. This pressure remained stable at 2 mm Hg for 1 month; subsequently, an average IOP of 5 mm Hg was maintained during the first postoperative year. No apparent hypotonic maculopathy was observed. The corneal flap interface was wrinkled. After surgery, VA improved slightly from the preoperative level of light projection to hand motion. A temporal island of the visual field, as measured by Goldmann kinetic perimetry, remained unchanged after surgery.

On July 23, 2012, IOP was stable at 5 mm Hg in the right eye, but was increased to 37 mm Hg (as measured by GAT) in the left eye, accompanied by minimal corneal edema. Systemic acetazolamide (750 mg/d) was prescribed, but was insufficiently effective. No symptoms of IFS were observed in the right eye; however, a trabeculectomy with MMC was performed on the patient's left eye on August 1, 2012.

#### FOLLOW-UP AND OUTCOMES

In July 2013, the IOPs were 6 mm Hg in the right eye and 7 mm Hg in the left eye (as measured by GAT). At this time point, the right eye VA was hand motion, whereas the uncorrected VA of the left eye was 1.2 (20/16). A fold was observed on the corneal flap interface in the right eye 2 years postoperatively; this fold diminished over time, but did not completely resolve. No



**FIGURE 2.** Slit-lamp biomicroscopy of the right eye 2 weeks after trabeculectomy. (A) A fold was observed in the corneal flap interface. (B) An enlargement of the interface fold.

corneal fold was detected postoperatively in the left eye. No hypotonic maculopathy developed in either eye. There were no significant differences between the preoperative and 6-month postoperative HFA MD values ( $-2.23$  dB and  $-2.20$  dB, respectively).

## DISCUSSION

IFS, which is associated with inaccurately low measurements of central IOP<sup>1-3,5-8</sup> because of cushioning of the fluid-filled pocket,<sup>5</sup> can result from increased IOP secondary to postoperative steroid use<sup>1-6,10</sup> or corneal endothelial dysfunction after vitreous surgery<sup>7,8</sup> or trabeculectomy.<sup>9</sup> A study of human eye bank corneas reported 2 mechanisms of IFS: increased IOP (the high-IOP form of IFS) and corneal endothelial dysfunction (the endothelial cell damage form of IFS).<sup>14</sup> In the current case, no steroid treatment was administered before the onset of IFS, and specular microscopy produced unremarkable findings. This case was classified as the high-IOP form of IFS despite a minimal increase in corneal thickness and opacity under the flap because there was no opacity or edema in the flap itself. Both Hamilton et al<sup>3</sup> and Kang et al<sup>9</sup> reported that IFS is associated with glaucoma, but the mechanisms underlying IFS differed between these 2 studies. The former report indicated that IOP increased with steroid use, whereas the latter report cited corneal endothelial dysfunction resulting from aggressive surgery and 5-fluorouracil intervention as the possible cause of increased IOP. The case described here may be the first reported instance in which IFS developed because of uncontrolled IOP during glaucoma management in the absence of triggering factors such as steroid-induced IOP elevation or corneal endothelial dysfunction.

Dawson et al<sup>14</sup> classified IFS into stages ranging from 0 to 3 based on the degree of fluid retention in the flap interface. Using this staging system, the right eye in the current case would be classified as stage 2; the left eye would be categorized as stage 1, which is often referred to as pressure-induced interlamellar stromal keratitis.<sup>15</sup>

A trabeculectomy was performed >5 weeks after IOP increased in the right eye. Owing to this delay, the corneal flap might have been stretched by the interface fluid that had accumulated under the flap. As a result, even after the interface fluid was absorbed and the space under the flap decreased, the stretched flap did not recover, leading to shriveling of the flap and the sustained presence of a fold at 2 years after surgery (Figure 2). Because the central visual field was lost in the right eye, it was impossible to determine how the corneal fold affected the vision of this patient; however, if a corneal fold had developed in the left eye, we would predict a delay in visual recovery.

Unfortunately, the VA of the right eye in this patient became hand motion. We must investigate the reason why the vision in his right eye was nearly lost. One reason could be the fact that he stopped seeing a doctor and terminated his use of antiglaucoma medication because he was informed that the IOP had normalized. Once patients are diagnosed with glaucoma, they must continue to be followed by doctors throughout their lives. It is possible that the explanation provided by the doctor at the first clinic regarding the disease of glaucoma was insufficient. Another reason could be that LASIK was performed on the eye without sufficient information about the probability of glaucoma progression and the difficulty of glaucoma management after LASIK. It is well known that the IOP is often underestimated after LASIK.<sup>12,16,17</sup> In this case, on the first visit to our hospital, IOP measurements of 13 mm Hg in the

right eye and 14 mm Hg in the left eye were obtained via GAT. Given the power of the contact lenses ( $-8$  D) before LASIK surgery, underestimation by approximately 4 mm Hg is thought to occur.<sup>12</sup> This result suggests that the corrected IOP might be approximately 17 to 18 mm Hg. According to the target IOP used in the Advanced Glaucoma Intervention Study,<sup>18</sup> the IOP in this patient first reached the targeted IOP. However, to predict the appropriate IOP to be maintained for the management of glaucoma in this case, IOP and the visual field should be monitored for a prolonged period. Even if there had been no elevation of IOP, reducing the IOP might have been necessary in the current case. The determination of whether or not treatment is required should be based on frequent medical evaluation and examination. However, one must consider the possibility of an increase in IOP because it is not easy to control IOP based on underestimated IOP measurements using GAT. Cases with normal tension glaucoma are unlikely to develop IFS as occurred in this case because the increase in IOP in this case is unusual. Alternatively, in glaucoma cases involving a prior increase in IOP, IOP can continue to increase during the disease course even if temporary control of IOP has been achieved. If LASIK is performed in such cases, the treatment may be insufficient because of underestimation of the typical IOP. In fact, the measurement of IOP can become difficult at high-IOP levels. Furthermore, serious visual disorders can develop. Thus, LASIK should not be performed on eyes with glaucoma because of the high risk of elevated IOP.

## REFERENCES

- Lyle WA, Jin GJ. Interface fluid associated with diffuse lamellar keratitis and epithelial ingrowth after laser in situ keratomileusis. *J Cataract Refract Surg.* 1999;25:1009-1012.
- Shaikh NM, Shaikh S, Singh K, et al. Progression to end-stage glaucoma after laser in situ keratomileusis. *J Cataract Refract Surg.* 2002;28:356-359.
- Hamilton DR, Manche EE, Rich LF, et al. Steroid-induced glaucoma after laser in situ keratomileusis associated with interface fluid. *Ophthalmology.* 2002;109:659-665.
- Galal A, Artola A, Belda J, et al. Interface corneal edema secondary to steroid induced elevation of intraocular pressure simulating diffuse lamellar keratitis. *J Refract Surg.* 2006;22:441-447.
- Ramos JL, Zhou S, Yo C, et al. High-resolution imaging of complicated LASIK flap interface fluid syndrome. *Ophthalmic Surg Lasers Imaging.* 2008;39:S80-S82.
- Moya Calleja T, Iribarne Ferrer Y, Sanz Jorge A, et al. Steroid-induced interface fluid syndrome after LASIK. *J Refract Surg.* 2009;25:235-239.
- Senthil S, Rathi V, Garudadi C. Misleading Goldmann applanation tonometry in a post-LASIK eye with interface fluid syndrome. *Indian J Ophthalmol.* 2010;58:333-335.
- Wirbelauer C, Pham DT. Imaging interface fluid after laser in situ keratomileusis with corneal optical coherence tomography. *J Cataract Refract Surg.* 2005;31:853-856.
- Kang SJ, Dawson DG, Hopp LM, et al. Interface fluid syndrome in laser in situ keratomileusis after complicated trabeculectomy. *J Cataract Refract Surg.* 2006;32:1560-1562.
- Han SB, Woo SJ, Hyon JY. Delayed-onset interface fluid syndrome after laser in situ keratomileusis secondary to combined cataract and vitreoretinal surgery. *J Cataract Refract Surg.* 2012;38:548-550.
- McLeod SD, Mather R, Hwang DG, et al. Uveitis-associated flap edema and lamellar interface fluid collection after LASIK. *Am J Ophthalmol.* 2005;139:1137-1139.

12. Arimoto A, Shimizu K, Shoji N, et al. Underestimation of intraocular pressure in eyes after laser in situ keratomileusis. *Jpn J Ophthalmol*. 2002;46:645–649.
13. Furukawa H, Hiro-Oka H, Satoh H, et al. Full-range imaging of eye accommodation by high-speed long-depth range optical frequency domain imaging. *Biomed Opt Express*. 2010;1:1491–1501.
14. Dawson DG, Schmack I, Holley GP. Interface fluid syndrome in human eye bank corneas after LASIK. *Ophthalmology*. 2007;114:1848–1859.
15. Belin MW, Hannush SB, Yau CW, et al. Elevated intraocular pressure-induced interlamellar stromal keratitis. *Ophthalmology*. 2002;109:1929–1933.
16. Bashford KP, Shafranov G, Tauber S, et al. Considerations of glaucoma in patients undergoing corneal refractive surgery. *Surv Ophthalmol*. 2005;50:245–251.
17. Chihara E, Takahashi H, Okazaki K, et al. The preoperative intraocular pressure level predicts the amount of underestimated intraocular pressure after LASIK for myopia. *Br J Ophthalmol*. 2005;89:160–164.
18. VanVeldhuisen PC, Ederer F, Gaasterland DE. The AGIS Investigators. The Advanced Glaucoma Intervention Study (AGIS): 7. The relationship between control of intraocular pressure and visual field deterioration. *Am J Ophthalmol*. 2000;130:429–440.