

Preferential conduction during focal atrial tachycardia arising from the noncoronary cusp



Peter Kabunga, MBChB, MRCP,^{*} George J. Klein, MD, FHRS,[†] Raymond W. Sy, MBBS, PhD^{*‡}

From the ^{*}Department of Cardiology, Royal Prince Alfred Hospital, Camperdown, Australia, [†]University of Western Ontario, London, Canada, and [‡]Sydney Medical School, University of Sydney, Sydney, Australia.

Introduction

Ventricular arrhythmias arising from a single focus within the left ventricular outflow tract and aortic sinuses of Valsalva may exhibit different QRS morphologies owing to preferential conduction to multiple exits.^{1,2} We describe a case of an atrial tachycardia (AT) arising from the non-coronary aortic cusp (NCC) with different P-wave morphologies, presumably on the basis of preferential conduction.

Case report

A 64-year-old man with drug-refractory supraventricular tachycardia was referred for an electrophysiology study. There was no evidence of structural heart disease. AT (cycle length 380–420 ms) was induced using atrial pacing during isoprenaline infusion (up to 5 mcg/minute). During tachycardia, 2 apparent P-wave morphologies were observed (Figure 1A). When timed premature ventricular contractions were delivered from the right ventricular catheter to minimize fusion between the P wave and the preceding T wave, the P wave in V1 was demonstrated to alternate between a negative-positive (Neg-Pos) and positive-negative (Pos-Neg) morphology (Figure 1B and C). Electroanatomic mapping (Carto-3; Biosense Webster) of the right atrium (RA) during tachycardia revealed early activation in the mid-septal region, adjacent to the His bundle catheter. Interestingly, during beats with a Pos-Neg morphology in V1, there was also early activation in the superior septal region that was on time with the His atrial signal (His A), whereas during beats with a Neg-Pos morphology in V1, activation in the superior septal region was 15 ms later than the His A (Figure 1D). Sequential mapping of the left atrium and aortic sinuses during tachycardia revealed earliest atrial activation (15 ms ahead of the His A) in the NCC that was independent of P-wave morphology in V1 (Figure 2). Radiofrequency ablation

(irrigated SmartTouch DF catheter, 20–30 W) at this site terminated tachycardia at 6 seconds (Figure 3) with no recurrence seen during the rest of the electrophysiology study (including during isoproterenol infusion) and at 10-month follow-up, off medications.

Discussion

Focal ATs may arise from various sites, including the crista terminalis, peritricuspid and mitral annuli, pulmonary veins, coronary sinus ostium, atrial appendages, atrial septum, and, very rarely, the NCC.^{3–5} Anatomically, NCC is intimately related to the epicardial aspect of the right atrial wall lying anterior and superior to the paraseptal region of the RA, within close proximity to the atrioventricular node. As such, and as in our case, AT with apparent early activation at the His may be successfully ablated from the NCC.^{4–6}

P-wave morphology may localize the origin of focal ATs. In particular, a negative or positive-negative P wave in V1 suggests a right atrial origin, whereas a positive or negative-positive P wave suggests a left atrial origin.³ Although a negative-positive P wave in V1 has been described in ATs arising from the NCC,⁵ the P-wave morphology in V1 can be quite variable for such ATs.^{3,6} In septal ATs, a positive-negative P wave in V1 predicts earlier right atrial activation, whereas a negative-positive P wave predicts earlier left atrial activation, correlating with the site of successful ablation.⁷ In the present case, cyclical alternation in P-wave morphology was observed in V1. In the aortic root and left atrium, the earliest activation was consistently observed in the NCC, followed by the left perinodal region, independent of P-wave morphology. In the RA, the earliest activation was also observed in the perinodal region during negative-positive P waves in V1. However, there was an additional site of early activation in the superior RA septum that was only observed during positive-negative P waves. We speculate that preferential conduction to the superior septal RA occurred on alternate beats, resulting in earlier right atrial activation explaining the positive-negative P wave in V1.

KEYWORDS Atrial tachycardia; Aortic sinus of Valsalva; Noncoronary cusp; Catheter ablation (Heart Rhythm Case Reports 2016;2:363–366)

Address reprint requests and correspondence: Dr Raymond Sy, Department of Cardiology, Royal Prince Alfred Hospital, Camperdown, NSW 2050, Australia. E-mail address: raymond.sy01@gmail.com.

KEY TEACHING POINTS

- Preferential conduction during premature ventricular contractions arising from the aortic sinus has been well described.
- Preferential conduction may also occur during atrial tachycardia arising from the aortic sinus, resulting in variable P-wave morphology.
- Recognition of this electrophysiological phenomenon should prompt one to perform mapping within the aortic sinus.

sinuses.^{1,2,8,9} Our case demonstrates that preferential conduction may also occur during AT arising from the aortic sinus. Importantly, recognition of this electrophysiological phenomenon should prompt one to perform mapping within the aortic sinus.

Several reports have suggested the existence of preferential conduction during premature ventricular contractions arising from the aortic mitral continuity and aortic

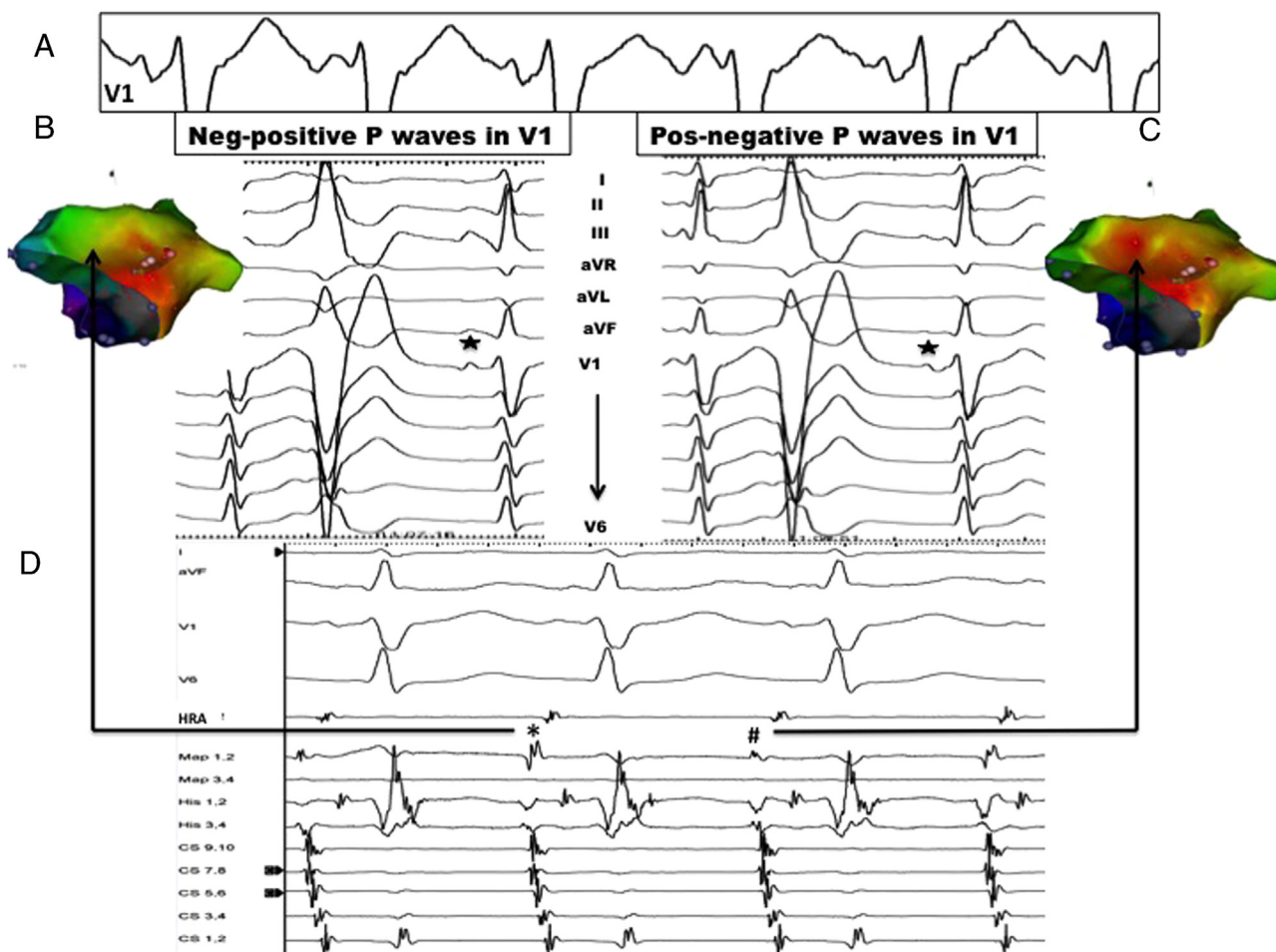


Figure 1 A: Alternating P-wave morphology during tachycardia, demonstrated in lead V1. B, C: Premature ventricular tachycardia delivered from the right ventricle during tachycardia demonstrates 2 distinct P-wave morphologies with corresponding activation maps (left-lateral projection). D: Map 1,2 refers to local electrogram at superior septum (during negative-positive morphology, denoted by *; and during positive-negative P wave, denoted by #). See text for details.

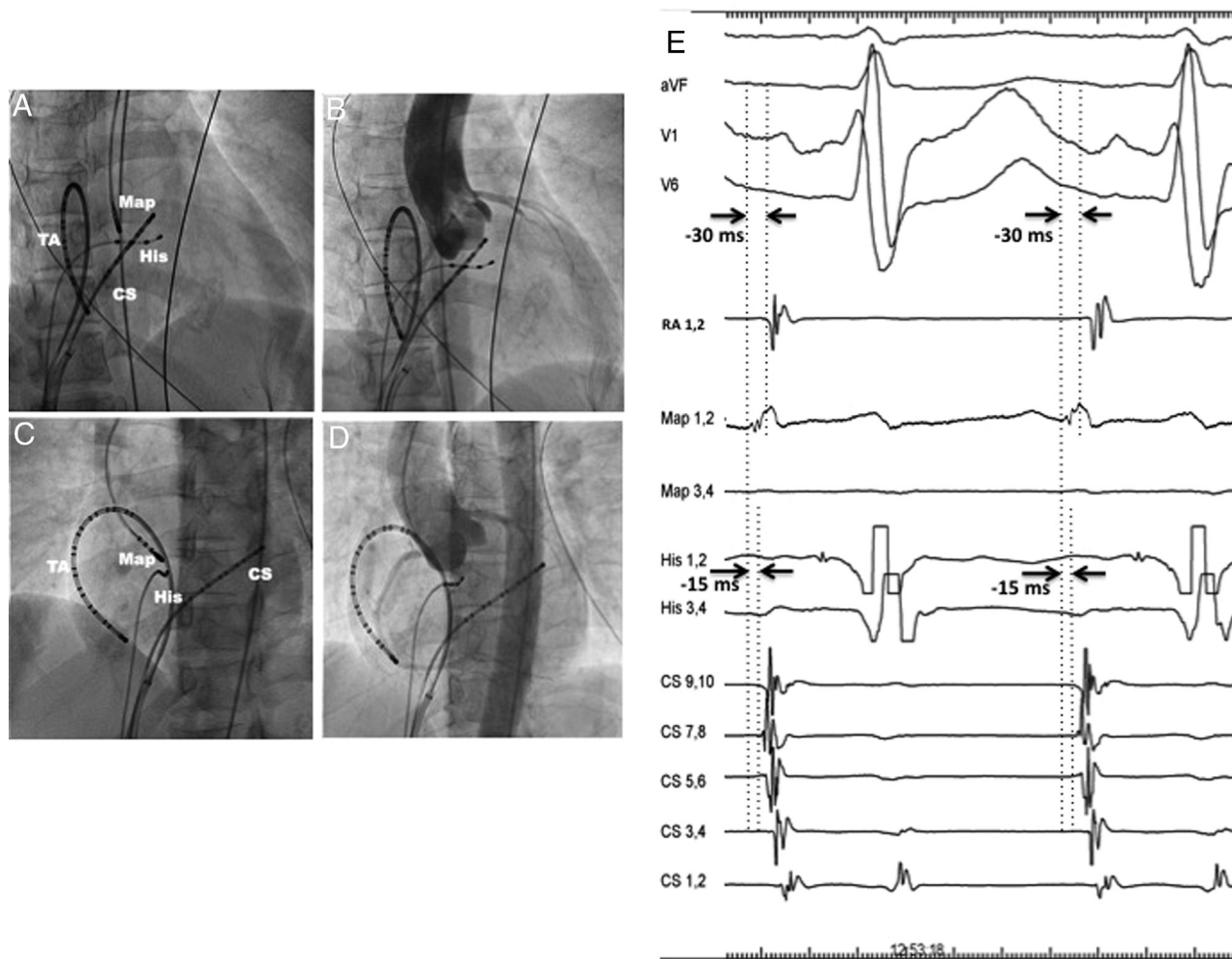


Figure 2 A,B: Fluoroscopic image (right anterior oblique view); C,D: fluoroscopic image (left anterior oblique view): Ablation catheter (Map) is at the successful site in the noncoronary aortic cusp. TA = 20-pole catheter in RA; His = catheter at the His area; CS = 10-pole coronary sinus catheter. E: Ablation catheter (Map 1,2) at the successful ablation site in the noncoronary aortic cusp. Map “A” precedes His “A” (His 3,4) by 15 ms and onset of surface P wave by ~30 ms during both positive-negative and negative-positive morphologies in V1.

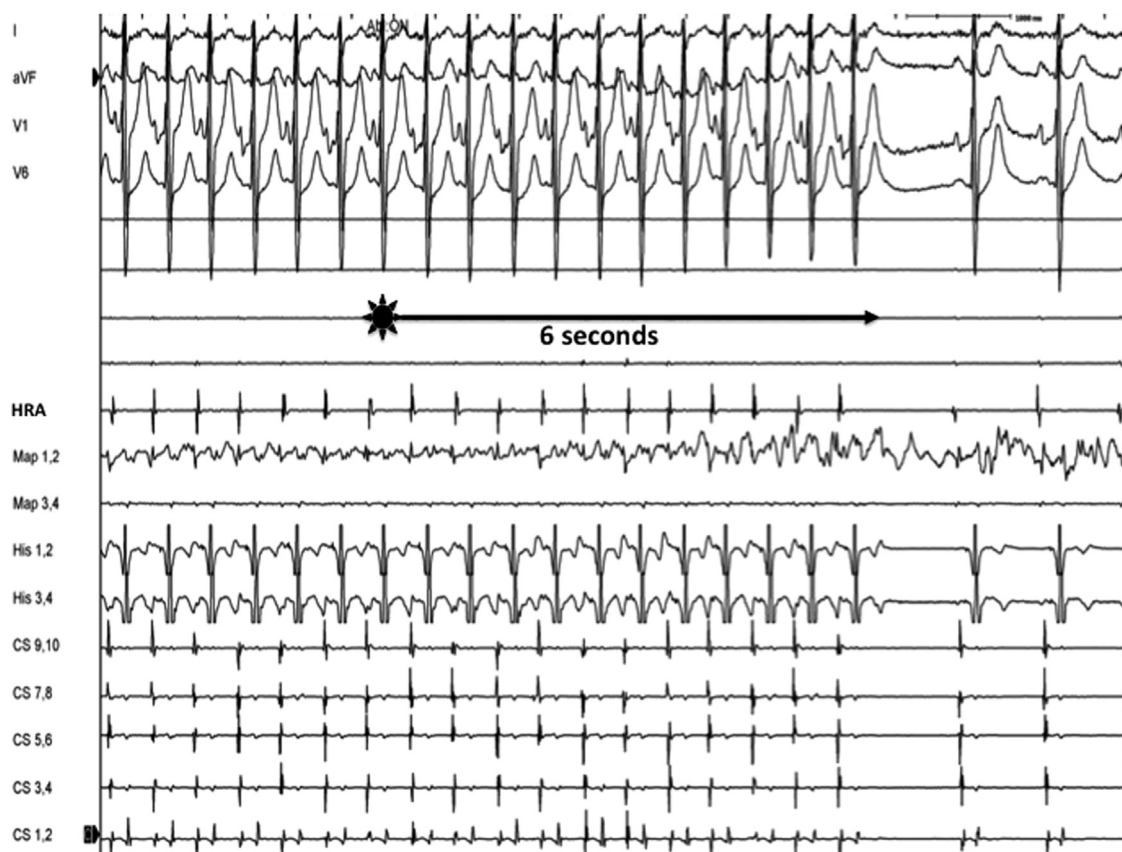


Figure 3 Tachycardia terminates after 6 seconds of radiofrequency application in the noncoronary aortic cusp.

References

1. Yamada T, Yoshida Y, Inden Y, Murohara T, Kay GN. Idiopathic premature ventricular contractions exhibiting preferential conduction within the aortic root. *Pacing Clin Electrophysiol* 2010;33:e10–e13.
2. Gouda S, Wichterle D, Peichl P, Kautzner J. Idiopathic left ventricular outflow tract ectopy: a single focus with extremely divergent breakouts. *BMC Cardiovasc Disord* 2014;14:161.
3. Kistler PM, Roberts-Thomson KC, Haqqani HM, Fynn SP, Singarayar S, Vohra JK, Morton JB, Sparks PB, Kalman JM. P-wave morphology in focal atrial tachycardia. *J Am Coll Cardiol* 2006;48:1010–1017.
4. Chen Y, Xia S, Tao Q, Zheng L. Ablation of atrial tachycardia originating from the noncoronary sinus: case report and literature review. *J Cardiovasc Med (Hagerstown)* 2010;11:389–393.
5. Ouyang F, Ma J, Ho SY, Bänsch D, Schmidt B, Ernst S, Kuck KH, Liu S, Huang H, Chen M, Chun J. Focal atrial tachycardia originating from the non-coronary aortic sinus: electrophysiological characteristics and catheter ablation. *J Am Coll Cardiol* 2006;48:122–131.
6. Das S, Neuzil P, Albert CM, D'Avila AN, Mansour M, Mela T, Ellinor PT, Singh J, Patton K, Ruskin JN, Reddy VY. Catheter ablation of peri-AV nodal atrial tachycardia from the noncoronary cusp of the aortic valve. *J Cardiovasc Electrophysiol* 2008;19:231–237.
7. Kaneko Y, Kato R, Nakahara S, Tobiume T, Morishima I, Tanaka K, Nakajima T, Irie T, Kusano KF, Kamakura S, Nagase T. Characteristics and catheter ablation of focal atrial tachycardia originating from the interatrial septum. *Heart Lung Circ* 2015;24:988–995.
8. Shirai Y, Goya M, Isobe M, Hirao K. Preferential pathway pacing within the aortic sinus of valsalva: strong evidence for the existence of preferential conduction with different exit sites traversing the ventricular septum. *J Cardiovasc Electrophysiol* 2015;26:805–808.
9. Hai JJ, Chahal AA, Friedman PA, Vaidya VR, Syed FF, DeSimone CV, Nanda S, Brady PA, Madhavan M, Cha YM, McLeod CJ. Electrophysiologic characteristics of ventricular arrhythmias arising from the aortic mitral continuity-potential role of the conduction system. *J Cardiovasc Electrophysiol* 2015;26:158–163.