

Research Article

Attenuating Effect of *Ginkgo biloba* Leaves Extract on Liver Fibrosis Induced by Thioacetamide in Mice

Atef M. Al-Attar

Department of Biological Sciences, Faculty of Sciences, King Abdulaziz University, P.O. Box 139109, Jeddah 21323, Saudi Arabia

Correspondence should be addressed to Atef M. Al-Attar, atef.a_2000@yahoo.com

Received 28 May 2012; Accepted 28 July 2012

Academic Editor: Y. James Kang

Copyright © 2012 Atef M. Al-Attar. This is an open access article distributed under the Creative Commons Attribution License, which permits unrestricted use, distribution, and reproduction in any medium, provided the original work is properly cited.

The purpose of this study is to investigate the effect of *Ginkgo biloba* leaves extract on experimental liver fibrosis induced by thioacetamide (TAA) in male albino mice. The experimental mice were divided into four groups. The mice of the first group were served as control. The experimental animals of the second group were given 150 mg/kg body weight of TAA by intraperitoneal injection, twice weekly, for 9 weeks. The mice of the third group were exposed to TAA and supplemented with *G. biloba* leaves extract. The animals of the fourth group were supplemented with *G. biloba* leaves extract. The levels of plasma alanine aminotransferase, aspartate aminotransferase, gamma-glutamyl transferase, alkaline phosphatase, triglycerides, cholesterol, and low-density lipoprotein cholesterol were statistically increased while the levels of plasma total protein, albumin, glucose, and high-density lipoprotein cholesterol were significantly decreased. The levels of liver superoxide dismutase, glutathione, glycogen and total protein were notably declined, whereas the level of total lipid was increased in mice of the second group. Furthermore, microscopic examination of liver sections from mice treated with TAA showed an abnormal morphology characterized by nodular transformations in liver parenchyma which surrounded by fibrous septa. Administration of *G. biloba* leaves extract reduced extent and development of fibrous septa, liver cells change, and biochemical alterations in mice exposed to TAA. This study showed that *G. biloba* leaves extract has a potential activity against TAA-induced liver fibrosis and suggested that the chemical constituents of *G. biloba* are effective in modulation of oxidative stress induced by TAA.

1. Introduction

Liver fibrosis is a common sequel to diverse liver injuries. Without effective treatments, reversible liver fibrosis at an early stage leads to irreversible cirrhosis. Chronic liver injury leads to a progressive wound healing response that eventually results in liver fibrosis characterized by both quantity and quality alteration of hepatic extracellular matrix, ECM [1]. Moreover, liver fibrosis represents the response of the liver to diverse chronic insults such as parasitic disease, chronic viral infection (hepatitis B and C), immunologic attack (autoimmune hepatitis), hereditary metal overload, toxic damage, and so forth. Because of the worldwide prevalence of these insults, liver fibrosis is common and is associated with significant morbidity and mortality [2–4].

Thioacetamide (TAA) was originally used as a fungicide [5]. TAA is a weak carcinogen that mainly affects liver and kidney [6–8]. TAA is one of the several agents that produces

centrilobular necrosis of the liver and has been so employed. Furthermore, TAA has been considered to be an inducer of liver fibrosis and cirrhosis [9–15]. The effects of TAA are not limited to the liver as profound structural and functional changes have been described in thymus [16], kidney [17, 18], the intestine [18, 19], spleen, [20] and lung [21]. These modifications may alter the response seen in the liver and influence the host response in general.

Herbal medicine is increasingly gaining acceptance from the public and medical professionals due to advances in the understanding of the mechanisms by which herbs positively influence health and quality of life [22]. *Ginkgo biloba* (maidenhair tree) is one of the oldest herbal medicines that have been used as a therapeutic agent in modern pharmacology. *Ginkgo biloba* has been a popular remedy in traditional Chinese medicine for over 4000 years, and it has been a common herbal medicine in Europe since the 1730's [23]. Standardized extracts from dried ginkgo leaves (EGb 761)

take also important place in modern medicine [24]. The *Ginkgo* tree, the only existing tree in the family *Ginkgoaceae*, is the world's oldest living tree and is thus sometimes referred to as a "living fossil" [25]. *Ginkgo* trees are now widely planted in China, Japan, Korea, France, Germany, and the United States for both ornamental and medicinal purposes. Various chemical constituents have been isolated from *G. biloba* leaves, including diterpenes (e.g., ginkgolides A, B, C, and J), sesquiterpenes (e.g., bilobalide), ginkgo flavonol glycosides (e.g., the glycosides of kaempferol, quercetin, and isorhamnetin), triterpenes (e.g., sterols), organic acids, and polyphenols [23]. Popularly marketed to the general public, *G. biloba* extract is believed to provide beneficial effects in memory impairment, stroke, edema, inflammation, Alzheimer's dementia, and vasoocclusive disorders [26]. The mechanism of action of *G. biloba* is not known. However, it appears to possess antioxidant activity [27]. Based on these evidences, the present study was aimed to evaluate the beneficial action of *G. biloba* leaves extract on liver fibrosis induced by TAA administration in male mice. This could be fulfilled through the histological analysis of liver and the determination of specific physiological parameters including the levels of blood plasma alanine aminotransferase (ALT), aspartate aminotransferase (AST), gamma-glutamyl transferase (GGT), alkaline phosphatase (ALP), total protein, albumin, triglycerides, cholesterol, high-density lipoprotein cholesterol (HDL-C), and low-density lipoprotein cholesterol (LDL-C), and liver superoxide dismutase (SOD), glutathione (GSH), glycogen, total protein, and total lipid.

2. Materials and Methods

2.1. Animals. Adult MFI male albino mice weighing 38.2–40.4 g were obtained from the Experimental Animal Unit of King Fahd Medical Research Center, King Abdulaziz University, Jeddah, Saudi Arabia. The experimental animals were acclimatized to the laboratory conditions for 10 days prior to the initiation of experimental treatments. They were caged in a quite temperature-controlled room ($23 \pm 1^\circ\text{C}$) and had free access to water and standard diet. The experimental treatments were conducted in accordance with ethical guidelines of the Animal Care and Use Committee of King Abdulaziz University.

2.2. *Ginkgo biloba* Leaves Extraction. Fine quality of *G. biloba* leaves (Erica Kruidrijen, Amsterdam, the Netherlands) were used for preparation of an aqueous extract. Fifteen grams of *G. biloba* leaves were crushed, added to 500 mL cold water and mixed in an electric mixture for 20 minutes. The mixture was centrifuged, and the clear supernatant was carefully removed and kept in a refrigerator at $2-8^\circ\text{C}$ as a final extract for subsequent experimental treatments.

2.3. Experimental Treatments. The experimental mice were divided into four groups of ten animals each. The mice of the first group were served as control and given saline solution (0.9% NaCl) by intraperitoneal injection, twice weekly, for 9 weeks. The experimental animals of the second group were given 150 mg/kg body weight of TAA (Sigma-Aldrich

Co., St. Louis, MO, USA) by intraperitoneal injection, twice weekly, for 9 weeks. The mice of the third group were intraperitoneally injected with TAA at the same dose given to the second group and were orally supplemented with 0.5 mL of *G. biloba* leaves extract, five times weekly for 9 weeks. The animals of the fourth group were given saline solution (0.9% NaCl) by intraperitoneal injection, twice weekly, for 9 weeks and treated with *G. biloba* leaves extract at the same dose given to the third group.

2.4. Biochemical Analyses. At the end of experimental period, mice were fasted for 6 hours and anaesthetized with diethyl ether. Blood specimens were collected from orbital venous plexus in vacuum tubes containing EDTA (k_3) as anticoagulants. Blood specimens were centrifuged at $200 \times g$ for 10 minutes, and the clear samples of blood plasma were separated. Plasma ALT, AST, GGT, ALP, glucose, triglycerides and cholesterol were estimated using an automatic analyzer (Reflotron Plus System, Roche, Germany). Plasma total protein, albumin, HDL-C, and LDL-C were measured using automated clinical chemistry analysis system, Dimension type RXL Max (Dade Behring Delaware, DE, USA). Moreover, liver homogenates were obtained using a tissue homogenizer. The homogenates (1:10 w/v) were prepared using a 100 mM KCl buffer (7:00 pH) containing EDTA 0.3 mM. All homogenates were centrifuged at $200 \times g$ for 20 minutes at 4°C , and the supernatants were used for the biochemical assays of SOD and GSH levels using SOD and GSH assay kits (Sigma-Aldrich Co.) according to the manufacturer's instruction with some modifications. Liver glycogen, total protein, and total lipid were evaluated using the methods of Barnes et al. [28], Gornall et al. [29], and Entenman [30], respectively.

2.5. Histopathological Examination. For histopathological evaluation, the liver tissues were fixed in 10% formaldehyde immediately after removal from the animals. Fixed tissues were routinely processed, then embedded in paraffin, and cut into $4 \mu\text{m}$ thick sections; they were mounted on slides for hematoxylin and eosin (H&E) staining. Qualitative evaluation of prepared tissues and the obtaining of their photos were carried out using Motic digital microscope, DM-B1 series, Motic Company.

2.6. Statistical Analysis. Numerical data were represented as mean \pm standard deviation (SD). Statistical Package for Social Sciences (SPSS) for Windows version 12.0 software was utilized for statistical analysis. Data were analyzed using one-way analysis of variance (ANOVA) followed by Dunnett's test. Statistical probability level of less than 5% ($P < 0.05$) was considered significant.

3. Results

Plasma ALT, AST, GGT, ALP, total protein, albumin, glucose, triglycerides, cholesterol, HDL-C, and LDL-C levels of control and treated mice are shown in Table 1 TAA at the dose of 150 mg/kg body weight induced significant increases ($P < 0.05$) of plasma ALT (+117.8%), AST (+101.8%),

TABLE 1: Plasma ALT, AST, GGT, ALP, total protein, albumin, glucose, triglycerides, cholesterol, HDL-L, and LDL-C levels (mean \pm SD) of control, TAA, TTA plus *G. biloba* leaves extract, and *G. biloba* leaves extract treated mice ($n = 7$). Percentage changes are included in parentheses.

Parameters	Treatments			
	Control	TAA	TAA + leaves extract	Leaves extract
ALT (U/L)	26.63 \pm 2.06	58.00 \pm 12.15 ^{ab} (+117.8)	33.63 \pm 6.35 ^{ac} (+26.9)	24.75 \pm 3.01 (-7.1)
AST (U/L)	41.38 \pm 5.10	83.50 \pm 23.40 ^{ab} (+101.8)	49.87 \pm 11.64 (+20.5)	41.00 \pm 5.93 (-0.9)
GGT (U/L)	4.79 \pm 0.55	11.55 \pm 1.31 ^{ab} (+141.1)	5.83 \pm 1.33 ^c (+21.7)	4.54 \pm 0.48 (-5.2)
ALP (U/L)	118.56 \pm 8.70	182.63 \pm 25.28 ^{ab} (+54.0)	127.38 \pm 17.78 (+7.4)	119.13 \pm 8.86 (+0.5)
Total protein (g/dL)	5.67 \pm 0.29	4.63 \pm 0.30 ^{ab} (-18.3)	5.36 \pm 0.67 (-5.5)	5.63 \pm 0.23 (-0.7)
Albumin (g/dL)	3.69 \pm 0.31	2.87 \pm 0.36 ^{ab} (-22.2)	3.30 \pm 0.55 (-10.6)	3.71 \pm 0.29 (+0.5)
Glucose (mg/dL)	85.43 \pm 6.90	69.57 \pm 8.06 ^{ab} (-18.6)	76.14 \pm 6.87 ^c (-10.9)	86.00 \pm 6.09 (+0.7)
Triglycerides (mg/dL)	70.00 \pm 4.44	136.14 \pm 16.38 ^{ab} (+94.5)	99.14 \pm 17.7 ^{ac} (+41.6)	70.85 \pm 5.34 (+1.2)
Cholesterol (mg/dL)	92.43 \pm 6.16	176.29 \pm 35.68 ^{ab} (+90.7)	139.29 \pm 29.23 ^{ac} (+50.7)	94.00 \pm 9.93 (+1.7)
HDL-C (mg/dL)	40.75 \pm 2.27	32.00 \pm 3.06 ^{ab} (-21.5)	38.14 \pm 2.0 ^a (-6.4)	39.86 \pm 2.80 (-2.2)
LDL-C (mg/dL)	24.86 \pm 2.28	46.14 \pm 7.20 ^{ab} (+85.6)	33.57 \pm 3.82 ^{ac} (+35.0)	22.75 \pm 2.12 (-8.5)

^aIndicates a significant difference between control and treated groups.

^bIndicates a significant difference between the group treated with TAA and groups treated with TAA plus *G. biloba* leaves extract and *G. biloba* leaves extract.

^cIndicates a significant difference between the group treated with TAA plus *G. biloba* leaves extract and group treated with *G. biloba* leaves extract.

GGT (+141.1%), ALP (+54.0%), triglycerides (+94.5%), cholesterol (+90.7%), and LDL-C (+85.6%), while the levels of plasma total protein (-18.3%), albumin (-22.2%), glucose (-18.6%), and HDL-C (-21.5%) were statistically decreased ($P < 0.05$) in mice of group 2 compared with control (group 1), TAA plus *G. biloba* leaves extract (group 3), and *G. biloba* leaves extract (group 4) treated mice. The level of plasma ALT (+26.9%), triglycerides (+41.6%), cholesterol (+50.7%), and LDL-C (+35.0%) were statistically elevated in mice treated with TAA plus *G. biloba* leaves extract compared with control and *G. biloba* leaves extract-treated mice. The level of plasma GGT (+21.7%) was notably increased in mice treated with TAA plus *G. biloba* leaves extract compared with mice supplemented with only *G. biloba* leaves extract. Moreover, the level of plasma glucose (-10.9%) was declined in mice treated with TAA plus *G. biloba* leaves extract compared with mice supplemented with only *G. biloba* leaves extract. The levels of plasma HDL-C (-6.4%) were decreased in mice treated with TAA plus *G. biloba* leaves extract compared with only control mice. The levels of plasma AST, ALP, total protein, and albumin were significantly unchanged in mice treated with TAA plus *G. biloba* leaves extract. The levels of liver SOD (-34.0%), GSH (-28.5%), glycogen (-21.4%), and total protein (-17.6%) were significantly decreased, whereas the level of liver total lipid (+36.7%) was increased in mice of group 2 compared

with groups 1, 2, and 3 (Table 2). In comparison with groups 1 and 4, the levels of liver SOD (-19.6%) and GSH (-20.1%) were statistically decreased ($P < 0.05$) while the level of total lipid (+23.9%) was increased in mice of group 3. The levels of liver glycogen (-13.7%) was notably declined compared with only group 1 and liver total protein was statistically unchanged in mice of group 3 (Table 2). Furthermore, insignificant changes of plasma ALT, AST, GGT, ALP, total protein, albumin, glucose, triglycerides, cholesterol, HDL-C, LDL-C, and liver SOD, GSH, glycogen, total protein, and total lipid were observed in mice treated with only *G. biloba* leaves extract (Tables 1 and 2).

Liver sections from control mice (group 1) showed normal structure (Figure 1(a)). The main normal structural component of the liver is the liver cells or hepatocytes. These cells are cuboidal epithelial cells arranged in anastomosing plates and cords. In classical lobules, the plates radiate from the central vein and cords alternate with sinusoids. Microscopic examination of liver sections from mice treated with TAA (group 2) showed an abnormal morphology characterized by nodular transformations in liver parenchyma which surrounded by fibrous septa (Figures 1(b), 1(c), 1(d), 1(e), and 1(f)). Furthermore, liver cells showed various degenerative alterations like cloudy swelling, hydropic degeneration, and necrosis with loss of nuclei which indicate a complete loss of the liver tissue

TABLE 2: Liver SOD, GSH, glycogen, total protein, and total lipid levels of control, TAA, TTA plus *G. biloba* leaves extract, and *G. biloba* leaves extract treated mice ($n = 7$). Percentage changes are included in parentheses.

Parameters	Treatments			
	Control	TAA	TAA + leaves extract	Leaves extract
SOD (U/mg tissue)	5.26 ± 0.67	3.47 ± 0.42 ^{ab} (−34.0)	4.23 ± 0.49 ^{ac} (−19.6)	5.34 ± 0.52 (+1.5)
GSH (μmol/g tissue)	8.69 ± 0.82	6.21 ± 0.55 ^{ab} (−28.5)	6.94 ± 0.62 ^{ac} (−20.1)	8.90 ± 0.68 (+2.4)
Glycogen (mg/g tissue)	9.34 ± 0.87	7.34 ± 1.19 ^{ab} (−21.4)	8.06 ± 0.81 ^a (−13.7)	9.03 ± 1.25 (−3.3)
Total protein (mg/g tissue)	247.43 ± 12.61	204.00 ± 8.43 ^{ab} (−17.6%)	236.11 ± 17.58 (−4.6%)	254.29 ± 18.63 (+2.8%)
Total lipid (mg/g tissue)	143.00 ± 8.76	195.43 ± 14.97 ^{ab} (+36.7)	177.14 ± 8.09 ^{ac} (+23.9)	140.29 ± 10.26 (−1.9)

^aIndicates a significant difference between control and treated groups.

^bIndicates a significant difference between the group treated with TAA and groups treated with TAA plus *G. biloba* leaves extract and *G. biloba* leaves extract.

^cIndicates a significant difference between the group treated with TAA plus *G. biloba* leaves extract and group treated with *G. biloba* leaves extract.

architecture. In mice treated with TAA plus *G. biloba* leaves extract (group 3), liver sections showed a reduced extent and development of fibrous septa (Figures 1(g), 1(h), and 1(i)). In addition, the liver cells showed slight alterations compared with liver cells structure of mice treated with only TAA. All mice treated with only *G. biloba* leaves extract (group 4) had normal livers microscopically (Figure 1(j)).

4. Discussion

The present study is the first to demonstrate that *G. biloba* leaves extract inhibits liver fibrosis induced by TAA in mice. Liver diseases remain one of the serious health problems. Liver fibrosis is participated by a variety of etiologies leading to sustained cellular injury. Liver fibrosis is one of the most prevalent chronic diseases in the world hence; the investigation for an efficient hepatoprotective drug from natural source is an urgent need. Liver fibrosis is a reaction to chronic liver injury, and it is characterized by an excessive accumulation of extracellular matrix proteins including collagen. It is a common process during the majority of chronic liver diseases [31]. Fibrosis as a scarring response to liver damage may be thought of as beneficial, since it contains the injurious process [32]. Ultimately, however, this progressive scarring can lead to impairment of liver function, development of hepatocellular carcinoma, and portal hypertension with all its associated complications. Recently, there has been a growing understanding of the pathophysiology behind fibrosis, which has contributed to the development of agents that could potentially inhibit and even reverse the fibrotic process in the future [33]. Among various hepatotoxins, TAA is known to be the most potent because of its rapid elimination and cumulative injury. The present study showed that TAA administration for 9 weeks induced liver fibrosis with many histopathological alterations. These observations were in line with many previous studies, which investigated the induction of liver fibrosis and cirrhosis by TAA in experimental animals [12, 14, 34–38]. The obtained results showed an elevation in

the levels of plasma ALT, AST, GGT, and ALP in mice treated with TAA, since necrosis or membrane damage releases these enzymes into circulation, which agrees with the previously reported results [39]. Moreover, many studies showed that these enzymes were statistically increased in experimental animals treated with TAA [12, 35–37, 40, 41]. The present decline levels of blood plasma total protein, albumin, glucose and HDL-C, and liver glycogen, and total protein with the increases of plasma triglycerides, cholesterol, LDL-C, and liver total lipid indicate disturbances in protein, carbohydrate and lipid metabolism induced by TAA intoxication. Several investigators reported that TAA intoxication models registered significantly lower blood total protein levels compared to those of the healthy models [42–44]. This alteration could be related to the induction of ubiquitin-associated protein degradation by TAA toxic stress [45]. Kruszynska and McIntyre [46] reported that the blood sugar level after overnight fasting in cirrhotic patients is believed to decrease only in severe hepatic failure. Several studies showed that carbon tetrachloride (CCl₄) administration depleted liver glycogen in cirrhotic rats [47–50]. Blood glucose concentration is known to depend on the ability of the liver to absorb or produce glucose. The liver performs its glucostatic function owing to its ability to synthesize or degrade glycogen according to the needs of the organism, as well as via gluconeogenesis [51]. Tripathi et al. [52] showed that the levels of serum cholesterol were decreased in adult albino rats intoxicated with TAA, CCl₄ or paracetamol, while Khalaf et al. [53] reported that the levels of serum cholesterol and triglycerides were increased in rats intoxicated with CCl₄. Ismail et al. [54] showed that the levels of serum cholesterol, triglycerides, LDL-C, and very low-density lipoprotein cholesterol (VLDL-C) were increased, while the level of serum HDL-C was declined in rats exposed to CCl₄. Additionally, Al-Attar [14] reported that the chronic administration of TAA for a period of 10 weeks increased the levels of serum ALT, AST, GGT, ALP, total bilirubin, triglycerides, cholesterol, creatine kinase (CK), and lactate dehydrogenase (LDH), while the levels of glucose,

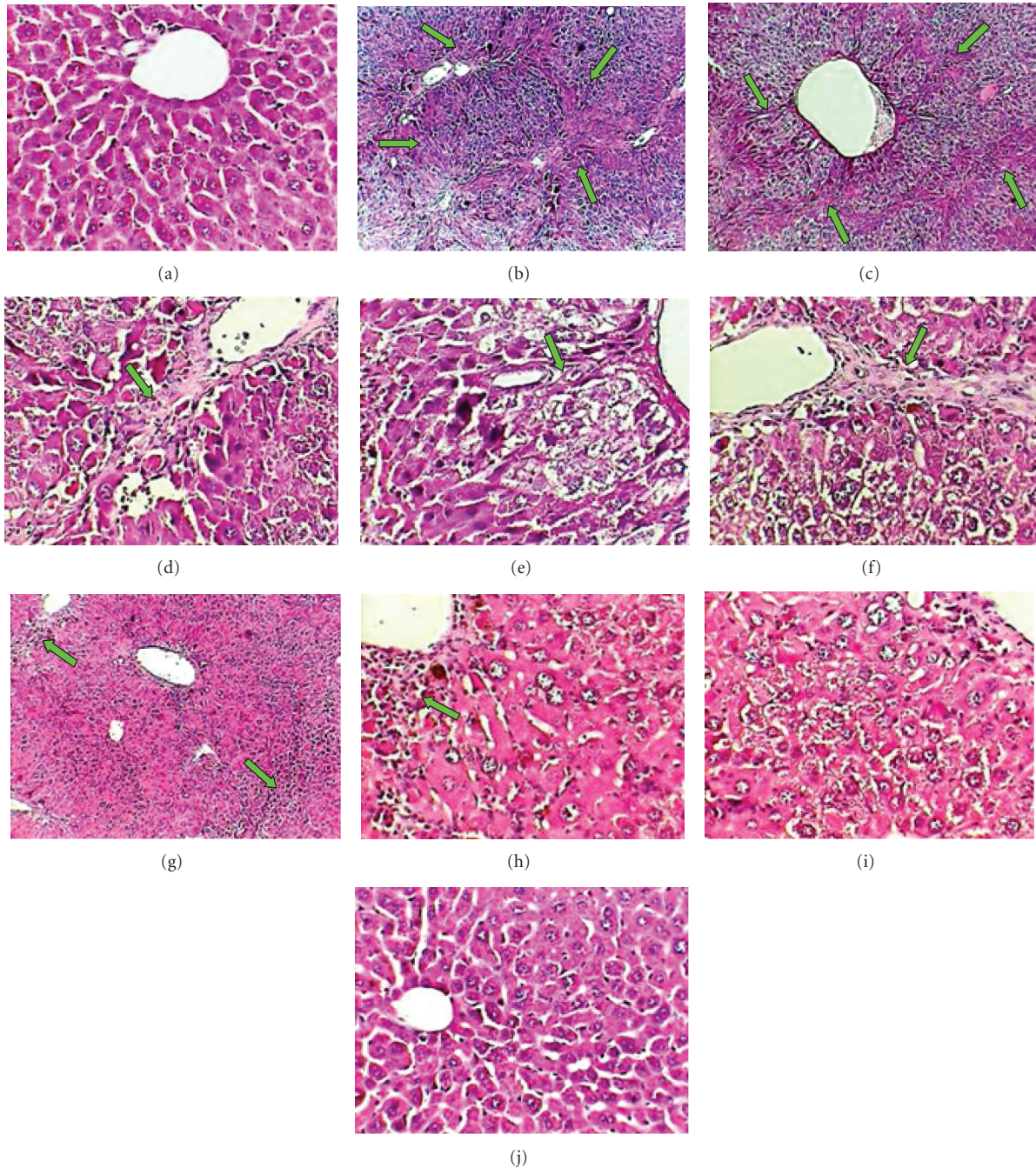


FIGURE 1: Photomicrographs of liver sections of normal control mice ((a), $\times 400$) showing normal histological structure; TAA-treated mice ((b) and (c), $\times 100$; (d), (e), and (f), $\times 400$) showing severe damage of liver structure including the formation of pseudolobules with fibrotic septa (arrows); TAA plus *G. biloba* leaves extract-treated mice ((g), $\times 100$; (h) and (i), $\times 400$) showing disarrangement of hepatic strands and few of fibrotic septa (arrows); *G. biloba* leaves extract-treated mice ((j), $\times 400$) showing normal histological structure.

total protein, and albumin were statistically decreased in experimental male rats.

In mice treated with TAA, there were significant decreases in the levels of liver SOD and GSH. These findings are consistent with previous investigations which indicated that TAA caused a significant decrease in the levels of liver SOD and GSH [12, 55, 56]. TAA is a well-known liver hepatotoxicant, the hepatotoxicity results from its metabolic

conversion to free radical products: thioacetamide sulfoxide and thioacetamide-S, S-dioxide which attacks microsomal lipids leading to their peroxidation and production of reactive oxygen species (ROS), such as the H_2O_2 , super oxide anion O_2^- , and the hydroxyl radical. ROS affects the antioxidant defense mechanisms, decreases the activity of SOD that causes liver injury, cirrhosis development, and hepatocarcinoma [57]. Oxidative stress plays an important

role in the formation of liver fibrosis via increasing the stellate cell activation and collagen synthesis [58]. Superoxide dismutases (SODs) belong to a family of antioxidant enzymes that catalyze the dismutation of superoxide to yield hydrogen peroxide and oxygen [59]. SOD is essentially a protective enzyme which scavenges the superoxide ions produced as cellular byproducts during oxidative stress [60]. Its decreased activity can lead to adverse effects because superoxide anions are extremely toxic and may accumulate in the cells. Glutathione (GSH), a tripeptide present in the majority of cells, is responsible for hydrophilic xenobiotics conjugation. GSH serves many vital physiological functions including protection of cells from ROS, detoxification of exogenous compounds, and amino acid transport [61, 62]. Sulphydryl group of glutathione is essential for its antioxidant activity against some forms of ROS in cells [63]. Much of the pathology is associated with the decrease in intracellular GSH concentration [64]. Therefore, GSH concentration is important for survival of the cells. It is also a substrate for glutathione peroxidase. Probably, the most important protective mechanism for free radical scavenging and inhibition of electrophilic xenobiotics attack on cellular macromolecules involves tripeptide glutathione [63]. Due to nucleophilic thiol group, it can detoxify substances in one of three ways: (I) conjugation catalyzed by glutathione-S-transferases (GST), (II) chemical reaction with a reactive metabolite to form a conjugate, and (III) donation of proton or hydrogen atom to reactive metabolites or free radicals. Reactive intermediates can react with GSH either by a direct chemical reaction or by a GST-mediated reaction preventing possible cell death. Regarding the role of glutathione in the protection against oxidative stress and detoxification of xenobiotics, its availability in the reduced form (GSH) may be a key factor in maintenance of the health. It has been established in several different animal models, as well as in human, that a decrease in GSH concentration may be associated with aging and pathogenesis of many diseases [64–68].

The present results demonstrated that supplementation of mice with *G. biloba* leaves extract reduced the liver fibrosis process and tissues damage induced by TAA administration as verified by the values of liver function markers (ALT, AST, GGT, and ALP), levels of plasma glucose triglycerides, cholesterol, HDL-C, LDL-C, levels of liver SOD, GSH, glycogen and total lipids, unchanged of plasma total protein, albumin and liver total protein, and liver histopathological observations. Shenoy et al. [69] studied the protective effect of *G. biloba* against CCl₄-induced hepatotoxicity in Wistar male rats. They reported that *G. biloba* pretreatment exhibited histopathological and biochemical protections and suggested that the probable mechanism of *G. biloba* action is by protection against oxidative damage produced by CCl₄. Sener et al. [70] assessed the antioxidant and antifibrotic effects of long-term *G. biloba* extract administration on liver fibrosis induced by bile duct ligation (BDL) and scission in Wistar male albino rats. They suggested that *G. biloba* protects the liver from oxidative damage following BDL in rats. This effect possibly involves the inhibition of neutrophil infiltration and lipid peroxidation, thus, restoration of oxidant and antioxidant status in the tissue. Luo et al.

[71] investigated the reversing effect of *G. biloba* extract on CCl₄-induced liver fibrosis in Wistar male rats. They found that the liver fibrosis rats treated with *G. biloba* extract had decreased serum total bilirubin and aminotransferase levels and increased levels of serum albumin compared with saline-treated rats. Microscopic studies revealed that the livers of rats receiving *G. biloba* extract showed alleviation in fibrosis. The liver collagen and reticulum contents were lower in rats treated with *G. biloba* extract. Additionally, Liu et al. [1] evaluated the effects of *G. biloba* extract on experimental liver fibrosis induced by CCl₄ in Wistar male rats. They demonstrated that the histopathological score of fibrosis, liver function and the levels of plasma hyaluronic acid (HA) and laminin (LN) were significantly improved in rats treated with CCl₄ plus *G. biloba* extract, compared with those treated with CCl₄ only. The activities of liver SOD and glutathione peroxidase (GSH-Px) were notably elevated, while malondialdehyde (MDA) content was significantly decreased in the rats treated with CCl₄ plus *G. biloba* extract. Inhibition of hepatic stellate cell (HSC) activation and nuclear factor kappaBP65 (NF-κBP65) expression was demonstrated in the livers of *G. biloba* extract-treated rats. The activation of NF-κB was significantly suppressed in *G. biloba* extract-treated rats. Furthermore, *G. biloba* extract reduced expressions of transforming growth factor-β1 (TGF-β1) and collagen I mRNA. In addition, they concluded that extract of *G. biloba* is able to ameliorate liver injury and prevent rats from CCl₄-induced liver fibrosis by suppressing oxidative stress. This process may be related to inhibiting the induction of NF-κB on HSC activation and the expression of TGF-β1. Harputluoglu et al. [72] investigated the influence of *G. biloba* on TAA-induced fulminant hepatic failure in rats. They showed that *G. biloba* ameliorated hepatic damage in TAA-induced fulminant hepatic failure and suggested that the action of *G. biloba* may be due to its free radical-scavenging effects. Moreover, Zhang et al. [73] studied the effect of *G. biloba* treatment on male patients with chronic hepatitis B, and they concluded that *G. biloba* can improve sinusoidal microcirculation, alleviate inflammation and inhibit liver fibrosis through multiple mechanisms; it is effective in the treatment of chronic liver diseases. The mechanism for action of *G. biloba* remains completely unknown, although several speculations have been advanced. Moreover, while the mechanism underlying the protective benefits of *G. biloba* has remained unclear, the attempts at explanation of its protective activity proposed its antioxidant properties [1, 72]. However, the present study suggests that the chemical constituents of *G. biloba* are effective in modulation of oxidative stress induced by TAA administration. Finally, it can be concluded that *G. biloba* leaves extract has a potential activity against TAA-induced liver fibrosis. Therefore, it may be useful against liver fibrosis, cirrhosis, and dysfunction induced by TAA and different pathogenic factors.

Acknowledgments

This paper was funded by the Deanship of Scientific Research (DSR), King Abdulaziz University, Jeddah, Saudi Arabia, under Grant no. 2-372-D1432. The author, therefore,

acknowledges with thanks DSR technical and financial support.

References

- [1] S. Q. Liu, J. P. Yu, H. L. Chen, H. S. Luo, S. M. Chen, and H. G. Yu, "Therapeutic effects and molecular mechanisms of *Ginkgo biloba* Extract on liver fibrosis in rats," *The American Journal of Chinese Medicine*, vol. 34, no. 1, pp. 99–114, 2006.
- [2] W. X. Chen, Y. M. Li, C. H. Yu, W. M. Cai, M. Zheng, and F. Chen, "Quantitative analysis of transforming growth factor beta 1 mRNA in patients with alcoholic liver disease," *World Journal of Gastroenterology*, vol. 8, no. 2, pp. 379–381, 2002.
- [3] D. W. Han, "Intestinal endotoxemia as a pathogenetic mechanism in liver failure," *World Journal of Gastroenterology*, vol. 8, no. 6, pp. 961–965, 2002.
- [4] L. Shen, J. G. Fan, Y. Shao et al., "Prevalence of nonalcoholic fatty liver among administrative officers in Shanghai: an epidemiological survey," *World Journal of Gastroenterology*, vol. 9, no. 5, pp. 1106–1110, 2003.
- [5] H. V. Vadi and R. A. Neal, "Microsomal activation of thioacetamide-S-oxide to a metabolite(s) that covalently binds to calf thymus DNA and other polynucleotides," *Chemico-Biological Interactions*, vol. 35, no. 1, pp. 25–38, 1981.
- [6] R. Bruck, S. Weiss, A. Traister et al., "Induced hypothyroidism accelerates the regression of liver fibrosis in rats," *Journal of Gastroenterology and Hepatology*, vol. 22, no. 12, pp. 2189–2194, 2007.
- [7] M. Hasegawa, M. Ide, S. Takenaka, J. Yamate, and S. Tsuyama, "Urinary metabolic fingerprinting for thioacetamide-induced rat acute hepatic injury using fourier transform-ion cyclotron resonance mass spectrometry (FT-ICR MS), with reference to detection of potential biomarkers for hepatotoxicity," *Toxicologic pathology*, vol. 35, no. 4, pp. 570–575, 2007.
- [8] R. D. Rekha, A. A. Amali, G. M. Her et al., "Thioacetamide accelerates steatohepatitis, cirrhosis and HCC by expressing HCV core protein in transgenic zebrafish *Danio rerio*," *Toxicology*, vol. 243, no. 1–2, pp. 11–22, 2008.
- [9] A. Eroğlu, S. Demirci, H. Akbulut, N. Sever, S. Demirel, and A. E. Ünal, "Effect of granulocyte-macrophage colony-stimulating factor on hepatic regeneration after 70% hepatectomy in normal and cirrhotic rats," *HPB*, vol. 4, no. 2, pp. 67–73, 2002.
- [10] G. Kumar, G. S. Banu, P. V. Pappa, M. Sundararajan, and M. R. Pandian, "Hepatoprotective activity of *Trianthema portulacastrum* L. against paracetamol and thioacetamide intoxication in albino rats," *Journal of Ethnopharmacology*, vol. 92, no. 1, pp. 37–40, 2004.
- [11] G. Gribilas, A. Zarros, A. Zira et al., "Involvement of hepatic stimulator substance in experimentally induced fibrosis and cirrhosis in the rat," *Digestive Diseases and Sciences*, vol. 54, no. 11, pp. 2367–2376, 2009.
- [12] A. F. Aydin, Z. Küskü-Kiraz, S. Dođru-Abbasođlu, M. Güllüođlu, M. Uysal, and N. Koçak-Toker, "Effect of carnosine against thioacetamide-induced liver cirrhosis in rat," *Peptides*, vol. 31, no. 1, pp. 67–71, 2010.
- [13] M. K. Tsai, Y. L. Lin, and Y. T. Huang, "Effects of salvianolic acids on oxidative stress and hepatic fibrosis in rats," *Toxicology and Applied Pharmacology*, vol. 242, no. 2, pp. 155–164, 2010.
- [14] A. M. Al-Attar, "Hepatoprotective influence of vitamin C on thioacetamide-induced liver cirrhosis in Wistar male rats," *Journal of Pharmacology and Toxicology*, vol. 6, no. 3, pp. 218–233, 2011.
- [15] J. H. Wang, J. W. Shin, M. K. Choi, H. G. Kim, and C. G. Son, "An herbal fruit, *Amomum xanthoides*, ameliorates thioacetamide-induced hepatic fibrosis in rat via antioxidative system," *Journal of Ethnopharmacology*, vol. 135, no. 2, pp. 344–350, 2011.
- [16] E. A. Barker and E. A. Smuckler, "Nonhepatic thioacetamide injury. I. Thymic cortical necrosis," *The American Journal of Pathology*, vol. 71, no. 3, pp. 409–418, 1973.
- [17] E. A. Barker and E. A. Smuckler, "Nonhepatic thioacetamide injury. II. The morphologic features of proximal renal tubular injury," *The American Journal of Pathology*, vol. 74, no. 3, pp. 575–590, 1974.
- [18] M. E. Caballero, J. Berlanga, D. Ramirez et al., "Epidermal growth factor reduces multiorgan failure induced by thioacetamide," *Gut*, vol. 48, no. 1, pp. 34–40, 2001.
- [19] M. A. Ortega, M. I. Torres, M. I. Fernández, A. Rios, A. Sánchez-Pozo, and A. Gil, "Hepatotoxic agent thioacetamide induces biochemical and histological alterations in rat small intestine," *Digestive Diseases and Sciences*, vol. 42, no. 8, pp. 1715–1723, 1997.
- [20] A. Al-Bader, T. C. Mathew, M. Khoursheed, S. Asfar, H. Al-Sayer, and H. M. Dashti, "Thioacetamide toxicity and the spleen: histological and biochemical analysis," *Anatomia, Histologia, Embryologia*, vol. 29, no. 1, pp. 3–8, 2000.
- [21] S. M. Latha, M. R. M. S. Pai, and P. K. Pai, "Thioacetamide toxicity and the lung: histological analysis," *Indian Journal of Physiology and Pharmacology*, vol. 47, no. 4, pp. 476–478, 2003.
- [22] V. S. Panda and S. R. Naik, "Evaluation of cardioprotective activity of *Ginkgo biloba* and *Ocimum sanctum* in rodents," *Alternative Medicine Review*, vol. 14, no. 2, pp. 161–171, 2009.
- [23] T. A. van Beek, E. Bombardelli, P. Morazzoni, and F. Peterlongo, "*Ginkgo biloba* L.," *Fitoterapia*, vol. 69, no. 3, pp. 195–244, 1998.
- [24] S. Jaracz, S. Malik, and K. Nakanishi, "Isolation of ginkgolides A, B, C, J and bilobalide from *G. biloba* extracts," *Phytochemistry*, vol. 65, no. 21, pp. 2897–2902, 2004.
- [25] B. S. Joshi and P. N. Kaul, "Alternative medicine: herbal drugs and their critical appraisal—part I," *Progress in Drug Research*, vol. 56, pp. 1–76, 2001.
- [26] B. J. Diamond, S. C. Shiflett, N. Feiwei et al., "*Ginkgo biloba* extract: mechanisms and clinical indications," *Archives of Physical Medicine and Rehabilitation*, vol. 81, no. 5, pp. 668–678, 2000.
- [27] S. Pietri, E. Maurelli, K. Drieu, and M. Culcasi, "Cardioprotective and anti-oxidant effects of the terpenoid constituents of *Ginkgo biloba* extract (EGb 761)," *Journal of Molecular and Cellular Cardiology*, vol. 29, no. 2, pp. 733–742, 1997.
- [28] H. Barnes, B. Margaret, and D. M. Finlayson, "The seasonal changes in body weight, biochemical composition and oxygen uptake of two common bivalve cirripedes, *Balanus balanoides* and *B. Balanus*," *Journal of the Marine Biological Association of the United Kingdom*, vol. 43, no. 1, pp. 185–211, 1963.
- [29] A. G. Gornall, C. J. Bardawill, and M. M. David, "Determination of serum proteins by means of the Biuret reaction," *The Journal of Biological Chemistry*, vol. 177, no. 2, pp. 751–766, 1949.
- [30] G. Entenman, "General procedures for separating lipid components of tissue," *Methods in Enzymology*, vol. 3, pp. 299–317, 1957.
- [31] R. Bataller and D. A. Brenner, "Liver fibrosis," *The Journal of Clinical Investigation*, vol. 115, no. 2, pp. 209–218, 2005.

- [32] T. Poynard, P. Mathurin, C. L. Lai et al., "A comparison of fibrosis progression in chronic liver diseases," *Journal of Hepatology*, vol. 38, no. 3, pp. 257–265, 2003.
- [33] V. Bhat and M. Bhat, "Hepatic fibrosis: novel strategies in detection and therapy," *McGill Journal of Medicine*, vol. 11, no. 1, pp. 38–40, 2008.
- [34] A. I. Mir, B. Kumar, S. A. Tasduq, D. K. Gupta, S. Bhardwaj, and R. K. Johri, "Reversal of hepatotoxin-induced pre-fibrogenic events by *Emblica officinalis*—a histological study," *Indian Journal of Experimental Biology*, vol. 45, no. 7, pp. 626–629, 2007.
- [35] R. R. Guerra, M. R. Trotta, O. M. Parra et al., "Modulation of extracellular matrix by nutritional hepatotrophic factors in thioacetamide-induced liver cirrhosis in the rat," *Brazilian Journal of Medical and Biological Research*, vol. 42, no. 11, pp. 1027–1034, 2009.
- [36] J. B. Wu, H. R. Chuang, L. C. Yang, and W. C. Lin, "A standardized aqueous extract of *Anoectochilus formosanus* ameliorated thioacetamide-induced liver fibrosis in mice: the role of Kupffer cells," *Bioscience, Biotechnology and Biochemistry*, vol. 74, no. 4, pp. 781–787, 2010.
- [37] F. A. Kadir, F. Othman, M. A. Abdulla, F. Hussan, and P. Hassandarvish, "Effect of *Timospora crista* on thioacetamide-induced liver cirrhosis in rats," *Indian Journal of Pharmacology*, vol. 43, no. 1, pp. 64–68, 2011.
- [38] J. F. Li, B. C. Chen, D. D. Lai et al., "Soy isoflavone delays the progression of thioacetamide-induced liver fibrosis in rats," *Scandinavian Journal of Gastroenterology*, vol. 46, no. 3, pp. 341–349, 2011.
- [39] M. C. Kew, "Serum aminotransferase concentration as evidence of hepatocellular damage," *The Lancet*, vol. 355, no. 9204, pp. 591–592, 2000.
- [40] B. Yagalakshmi, P. Viswanathan, and C. V. Anuradha, "Investigation of antioxidant, anti-inflammatory and DNA-protective properties of eugenol in thioacetamide-induced liver injury in rats," *Toxicology*, vol. 268, no. 3, pp. 204–212, 2010.
- [41] N. P. Foo, S. H. Lin, Y. H. Lee, M. J. Wu, and Y. J. Wang, "α-lipoic acid inhibits liver fibrosis through the attenuation of ROS-triggered signaling in hepatic stellate cells activated by PDGF and TGF-β," *Toxicology*, vol. 282, no. 1-2, pp. 39–46, 2011.
- [42] P. N. Trennery and R. H. Waring, "Early changes in thioacetamide-induced liver damage," *Toxicology Letters*, vol. 19, no. 3, pp. 299–307, 1983.
- [43] M. Galisteo, A. Suárez, M. P. Montilla, M. I. Fernandez, A. Gil, and M. C. Navarro, "Protective effects of *Rosmarinus tomentosus* ethanol extract on thioacetamide-induced liver cirrhosis in rats," *Phytomedicine*, vol. 13, no. 1-2, pp. 101–108, 2006.
- [44] N. K. Jain and A. K. Singhai, "Protective effects of *Phyllanthus acidus* (L.) Skeels leaf extracts on acetaminophen and thioacetamide induced hepatic injuries in Wistar rats," *Asian Pacific Journal of Tropical Medicine*, vol. 4, no. 6, pp. 470–474, 2011.
- [45] M. W. Andersen, N. R. Ballal, I. L. Goldknopf, and H. Busch, "Protein A24 lyase activity in nucleoli of thioacetamide-treated rat liver releases histone 2A and ubiquitin from conjugated protein A24," *Biochemistry*, vol. 20, no. 5, pp. 1100–1104, 1981.
- [46] Y. T. Kruszynska and N. McIntyre, "Oxford textbook of clinical hepatology," in *Carbohydrate Metabolism*, N. McIntyre, P. J. Benhamou, J. Bircher, M. Rizzetto, and J. Rodes, Eds., pp. 129–143, Oxford University Press, New York, NY, USA, 1991.
- [47] L. Favari and V. Perez-Alvarez, "Comparative effects of colchicine and silymarin on CCl₄-chronic liver damage in rats," *Archives of Medical Research*, vol. 28, no. 1, pp. 11–17, 1997.
- [48] P. Muriel and Y. Escobar, "Kupffer cells are responsible for liver cirrhosis induced by carbon tetrachloride," *Journal of Applied Toxicology*, vol. 23, no. 2, pp. 103–108, 2003.
- [49] P. Muriel, E. Fernández-Martínez, V. Pérez-Álvarez et al., "Thalidomide ameliorates carbon tetrachloride induced cirrhosis in the rat," *European Journal of Gastroenterology and Hepatology*, vol. 15, no. 9, pp. 951–957, 2003.
- [50] M. G. Moreno, E. Chávez, L. R. Aldaba-Muruato et al., "Coffee prevents CCl₄-induced liver cirrhosis in the rat," *Hepatology International*, vol. 5, no. 3, pp. 857–863, 2011.
- [51] O. M. Ahmed, H. Abdel Hamid, M. Bastway, and N. A. Hasona, "Antihyperglycemic effects of *Plantago Ispaghula* seeds aqueous extract in diabetic and hypercholesterolemic rats," *Journal of the Egyptian German Society of Zoology*, vol. 51, pp. 371–393, 2006.
- [52] B. K. Tripathi, S. Srivastava, R. Rastogi, D. Raina, V. J. Ram, and A. K. Srivastava, "Hepatoprotection by 3-bromo-6-(4-chlorophenyl)-4-methylthio-2H-pyran-2-one against experimentally induced liver injury in rats," *Acta Pharmaceutica*, vol. 53, no. 2, pp. 91–100, 2003.
- [53] A. A. A. Khalaf, M. E. M. Mekawy, M. S. Moawad, and A. M. Ahmed, "Comparative study on the protective effect of some antioxidants against CCl₄ hepatotoxicity in rats," *Egyptian Journal of Natural Toxins*, vol. 6, no. 1, pp. 59–82, 2009.
- [54] R. S. A. Ismail, A. A. A. El-Megeid, and A. R. Abdel-Moemin, "Carbon tetrachloride-induced liver disease in rats: the potential effect of supplement oils with vitamins E and C on the nutritional status," *GMS German Medical Science*, vol. 7, pp. 1–10, 2009.
- [55] S. Z. Mansour and H. El-Kabany, "Effects of *Fructus Piperis Longi* extract on fibrotic liver of gamma-irradiated rats," *Chinese Medicine*, vol. 4, article 2, 2009.
- [56] M. K. Kantah, R. Kobayashi, J. Sollano et al., "Hepatoprotective activity of a phytotherapeutic formula on thioacetamide-induced liver fibrosis model," *Acta Bio Medica*, vol. 82, no. 1, pp. 82–89, 2011.
- [57] G. Poli, "Pathogenesis of liver fibrosis: role of oxidative stress," *Molecular Aspects of Medicine*, vol. 21, no. 3, pp. 49–98, 2000.
- [58] V. Tahan, R. Ozaras, B. Canbakan et al., "Melatonin reduces dimethylnitrosamine-induced liver fibrosis in rats," *Journal of Pineal Research*, vol. 37, no. 2, pp. 78–84, 2004.
- [59] W. T. Johnson, L. A. K. Johnson, and H. C. Lukaski, "Serum superoxide dismutase 3 (extracellular superoxide dismutase) activity is a sensitive indicator of Cu status in rats," *The Journal of Nutritional Biochemistry*, vol. 16, no. 11, pp. 682–692, 2005.
- [60] G. Pushpakiran, K. Mahalakshmi, and C. V. Anuradha, "Taurine restores ethanol-induced depletion of antioxidants and attenuates oxidative stress in rat tissues," *Amino Acids*, vol. 27, no. 1, pp. 91–96, 2004.
- [61] A. Kojima-Yuasa, K. Umeda, T. Ohkita, D. O. Kennedy, S. Nishiguchi, and I. Matsui-Yuasa, "Role of reactive oxygen species in zinc deficiency-induced hepatic stellate cell activation," *Free Radical Biology and Medicine*, vol. 39, no. 5, pp. 631–640, 2005.
- [62] D. Mendoza-Cózatl, H. Loza-Tavera, A. Hernández-Navarro, and R. Moreno-Sánchez, "Sulfur assimilation and glutathione metabolism under cadmium stress in yeast, protists and plants," *FEMS Microbiology Reviews*, vol. 29, no. 4, pp. 653–671, 2005.
- [63] N. H. P. Cnubben, I. M. C. M. Rietjens, H. Wortelboer, J. van Zanden, and P. J. van Bladeren, "The interplay of glutathione-related processes in antioxidant defense," *Environmental Toxicology and Pharmacology*, vol. 10, no. 4, pp. 141–152, 2001.

- [64] O. I. Aruoma, B. Halliwell, B. M. Hoey, and J. Butler, "The antioxidant action of *N*-acetylcysteine: its reaction with hydrogen peroxide, hydroxyl radical, superoxide, and hypochlorous acid," *Free Radical Biology and Medicine*, vol. 6, no. 6, pp. 593–597, 1989.
- [65] D. S. Boehme, K. R. Maples, and R. F. Henderson, "Glutathione release by pulmonary alveolar macrophages in response to particles in vitro," *Toxicology Letters*, vol. 60, no. 1, pp. 53–60, 1992.
- [66] L. J. Smith, M. Houston, and J. Anderson, "Increased levels of glutathione in bronchoalveolar lavage fluid from patients with asthma," *American Review of Respiratory Disease*, vol. 147, no. 6, part 1, pp. 1461–1464, 1993.
- [67] B. M. Lomaestro and M. Malone, "Glutathione in health and disease: pharmacotherapeutic issues," *Annals of Pharmacotherapy*, vol. 29, no. 12, pp. 1263–1273, 1995.
- [68] W. Dröge, A. Gross, V. Hack et al., "Role of cysteine and glutathione in HIV infection and cancer cachexia: therapeutic intervention with *N*-acetylcysteine," *Advances in Pharmacology*, vol. 38, pp. 581–600, 1997.
- [69] K. A. Shenoy, S. N. Somayaji, and K. L. Bairy, "Hepatoprotective effects of *Ginkgo biloba* against carbon tetrachloride induced hepatic injury in rats," *Indian Journal of Pharmacology*, vol. 33, no. 4, pp. 260–266, 2001.
- [70] G. Sener, L. Kabasakal, M. Yüksel, N. Gedik, and Ý. Alican, "Hepatic fibrosis in biliary-obstructed rats is prevented by *Ginkgo biloba* treatment," *World Journal of Gastroenterology*, vol. 11, no. 35, pp. 5444–5449, 2005.
- [71] Y. J. Luo, J. P. Yu, Z. H. Shi, and L. Wang, "*Ginkgo biloba* extract reverses CCl₄-induced liver fibrosis in rats," *World Journal of Gastroenterology*, vol. 10, no. 7, pp. 1037–1042, 2004.
- [72] M. M. M. Harputluoglu, U. Demirel, H. Ciralik et al., "Protective effects of *Ginkgo biloba* on thioacetamide-induced fulminant hepatic failure in rats," *Human and Experimental Toxicology*, vol. 25, no. 12, pp. 705–713, 2006.
- [73] C. F. Zhang, C. Q. Zhang, Y. H. Zhu, J. Wang, H. W. Xu, and W. H. Ren, "*Ginkgo biloba* extract EGb 761 alleviates hepatic fibrosis and sinusoidal microcirculation disturbance in patients with chronic hepatitis B," *Gastroenterology Research*, vol. 1, pp. 20–28, 2008.