

Contents lists available at [ScienceDirect](http://www.sciencedirect.com)

International Journal of Surgery Case Reports

journal homepage: www.casereports.com

Iatrogenic gastric perforation in a misdiagnosed case of late presenting congenital diaphragmatic hernia: Report of an avoidable complication

Pradeep Kajal^{a,*}, Namita Bhutani^b, Mohit Goyal^c, Poonam Kamboj^c^a Deptt. of Pediatric Surgery, PGIMS, Rohtak, Haryana, India^b Deptt. of Pathology, PGIMS, Rohtak, Haryana, India^c Deptt. of Pediatrics, PGIMS, Rohtak, Haryana, India

ARTICLE INFO

Article history:

Received 18 July 2017

Received in revised form

19 September 2017

Accepted 19 September 2017

Available online 12 October 2017

Keywords:

Case report

Congenital diaphragmatic hernia

Pyothorax

Chest tube

Iatrogenic gastric perforation

ABSTRACT

INTRODUCTION: Congenital diaphragmatic hernia (CDH) is a defect in diaphragm which usually presents with severe respiratory distress in neonatal period.

PRESENTATION OF CASE: We present a case of congenital diaphragmatic hernia presenting at an age of 2.5 years in a male child. It was misdiagnosed as a case of pyothorax for which chest tube was attempted on left side resulting in iatrogenic gastric perforation. The patient was managed by early and prompt surgery.

DISCUSSION: Late presentation is usually rare with vast array of respiratory and gastrointestinal symptoms. It often leads to clinical and radiological misdiagnosis.

CONCLUSION: Surgical intervention in misdiagnosed cases can lead to catastrophic iatrogenic complications.

© 2017 Published by Elsevier Ltd on behalf of IJS Publishing Group Ltd. This is an open access article under the CC BY-NC-ND license (<http://creativecommons.org/licenses/by-nc-nd/4.0/>).

1. Introduction

Congenital diaphragmatic hernia (CDH) is the herniation of contents of abdomen in thoracic cavity through a defect in diaphragm. About 70–95% cases are diagnosed in the neonatal period and 5–45.5% cases are diagnosed later in life either incidentally in asymptomatic patients or clinically from respiratory and gastrointestinal symptoms requiring specific investigations [1–4]. It can mimic and be misdiagnosed as congenital lung cyst and bullae, pyothorax, pneumothorax, gastric volvulus [5]. While treating a misdiagnosed case, there are high chances of injuring the herniating content [6,7]. A high index of clinical suspicion is the key to prevent the catastrophic iatrogenic complications.

2. Case report

A 2.5-years-old male child was brought to paediatric casualty with chief complaints of respiratory distress and pain abdomen for previous 2 days. There was history of similar multiple episodes in

the past as well for which the patient's family pursued treatment by tribal healers. His symptoms used to get relieved to some extent but not completely. There was history of fever off and on. On examination, the child was having gross respiratory distress with all the accessory muscles of respiration at work and respiratory rate above 60 per minute. On auscultation, there was no air entry on left side and much decreased air entry on right side of the chest. The child was investigated after prompt resuscitation. On chest X-Ray, there was an obvious large rounded homogenous opacity along with air filled gut loops in left hemi-thorax compressing the left lung to left apical region. There was very significant mediastinal shift to contralateral side resulting in a compressed right lung (Fig. 1). These findings on chest X-ray were missed completely by the resident on duty and a chest tube was inserted under local anesthesia on left side considering it to be a case of pyothorax. The child got a bit relieved as well. He was shifted to pediatric intensive care unit and was started on oral feeds the next day. The pediatric resident on duty was surprised on seeing milk and fruit juice in the chest tube which was given him orally. So, she called the pediatric surgeon on duty. He examined the patient thoroughly and evaluated the X-Ray. The homogenous opacity and air in the herniated gut loops was in continuity with that in the abdomen. Therefore, a clinical diagnosis of left sided congenital diaphragmatic hernia with iatrogenic gastric perforation was made and the patient was taken up for urgent surgery. Exploratory laparotomy was done with left subcostal Kocher's incision. Per-operatively, there was a defect

* Corresponding author at: 23/8 FM, Medical Campus, Rohtak, Haryana 124001, India.

E-mail addresses: drpradeepkajal@gmail.com, pkajalsurg@gmail.com (P. Kajal), namitabhutani89@gmail.com (N. Bhutani), mohitgoyal1996@gmail.com (M. Goyal), impoonamkamboj@gmail.com (P. Kamboj).

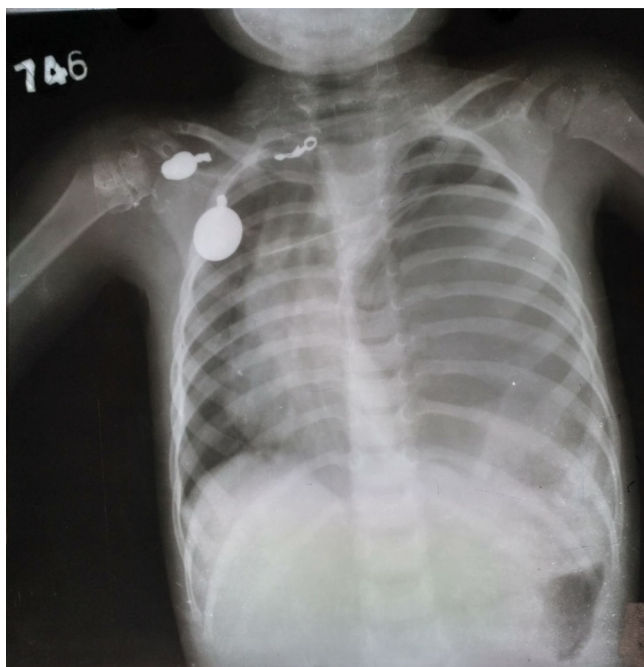


Fig. 1. Chest X-Ray showing large rounded homogenous opacity along with air filled gut loops in left hemi-thorax compressing the left lung to left apical region and mediastinal shift to contralateral side resulting in a compressed right lung.

of around 3.5×2.5 cm in posterior part of left hemi-diaphragm (Bochdalek hernia). The manual reduction of the herniated contents was attempted but was not successful owing to the small size of the defect. So, the defect was extended by 1.5 cm medially with the help of electrocautery. It was evident that stomach, spleen, transverse colon and left lobe of liver were herniating in left hemithorax with massive dilatation of stomach. The stomach was full of brownish black thick fluid coming out from iatrogenic perforation of about 1.5×1.5 cm on the greater curvature. (Fig. 2). It was decompressed completely with suction and all the herniated viscera pulled back in the abdominal cavity. The posterior lip of the diaphragm was deficient. So, a part of renal fascia from anterior surface of the left kidney was mobilized superiorly and utilized for the reconstruction of diaphragm with 3-0 proline continuous suture. The gastric perforation was closed with silk 3-0 interrupted sutures and abdominal wound was closed in layers. Check chest X-ray was done on 5th post-operative day which showed a satisfactory shape and function of diaphragm with left lung expanded significantly. The right lung was fully expanded with the mediastinum shifting back to its normal midline position (Fig. 3). The post-operative period was uneventful with the child receiving chest physiotherapy and made to do respiratory exercises with a mediciser. The child was discharged in fair health on 6th post-operative day.

3. Discussion

Congenital diaphragmatic hernia (CDH) is described as (1) failure of diaphragmatic closure at development, (2) presence of herniated abdominal contents into chest and (3) pulmonary hypoplasia. It occurs in about 1 in 3000 live births and results from the failure of different parts of diaphragm to fuse resulting in patent pleuropertoneal canal in embryonic life [7]. Another conjecture is that if the development of lung bud is disturbed, there is an impaired development of a post hepatic mesenchymal plate (PHMP) that is closely related to the development of lung, resulting in a defective diaphragm [8]. In diaphragm, the defects are usually present in posterolateral part (Bochdalek hernias, 70–75%)

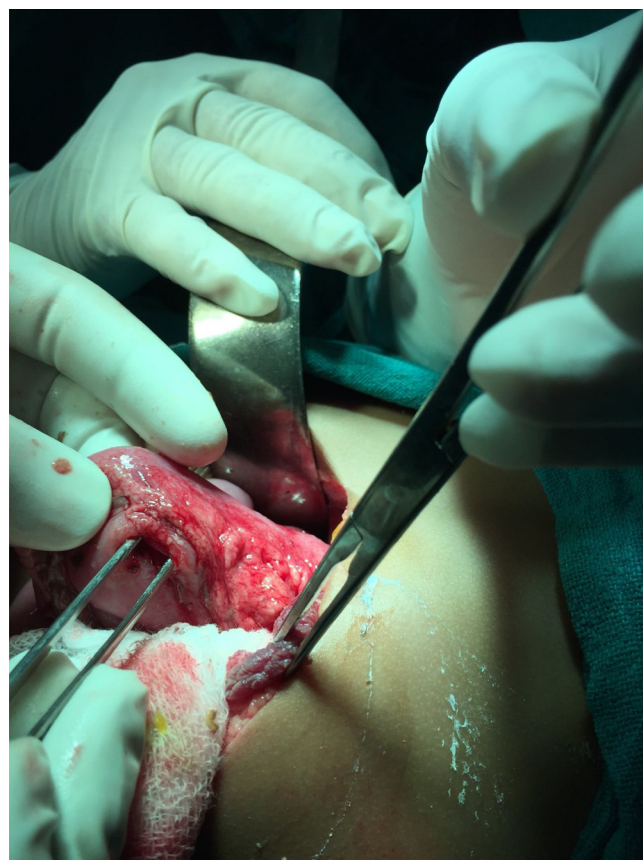

Fig. 2. Per-operative photograph showing an iatrogenic perforation of about 1.5×1.5 cm on the greater curvature of the stomach (the tip of forceps in the perforation).

followed by anterior aspect (Morgagni hernias, 23–28%) and central part (2–7%) [7–9]. So, ours was a case of late presenting Bochdalek hernia. In neonatal period, a patient with CDH presents with severe respiratory distress which was considered a surgical emergency but with recent understanding, the first step is to stabilize the patient haemodynamically followed by surgical intervention [10]. When a patient presents late, symptoms vary according to the organ affected. On a chest X-Ray, there may be large rounded homogenous opacity because of herniated stomach along with air-filled gut loops in left hemi-thorax compressing the left lung to left apical region and even mediastinal shift to contralateral side resulting in a compressed right lung as in our case. It can mimic and be misdiagnosed as congenital lung cyst and bullae, pyothorax, pneumothorax, and gastric volvulus.

In our case, the patient was having respiratory distress due to compression of the left lung to left apical region by the herniating stomach, spleen, transverse colon and left lobe of liver through posterolateral defect. This led to contralateral shift of the mediastinum resulting in significant compression of the right lung as well. The presenting symptoms can be vague and non-specific most of the times as in our case. Also, the chest X-ray findings were misinterpreted by the resident on duty as pyothorax for which chest tube was inserted causing gastric perforation. The inappropriate insertion of a chest drain, although relieves the symptoms temporarily as in our case as well, may result in serious consequences by damaging intrathoracic abdominal viscera. There is also the risk of spillage of the gastric or intestinal contents into the thoracic cavity leading to mediastinitis. Damage to the spleen or blood vessels in cases of left sided CDH could result in life threatening haemorrhage. In cases of right sided CDH, an intrathoracic liver may be damaged

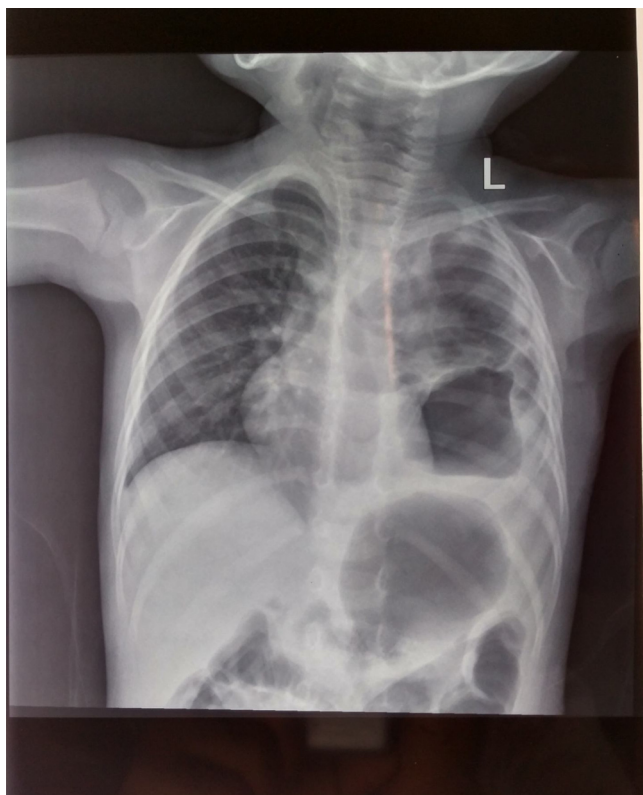


Fig. 3. Post-operative chest X-ray showing the normalized shape of diaphragm with left lung expanded significantly and right lung fully and the mediastinum shifted back to its normal midline position.

by a chest drain. Similar cases have been reported with chest tube insertion leading to iatrogenic perforation in patients with undiagnosed diaphragmatic hernia [6,7]. X-ray abdomen showing gastric and intestinal gas shadow in continuity with that in the ipsilateral hemithorax gives a clue to the possibility of CDH. Ultrasound of the abdomen and chest is an easily available and quite helpful diagnostic modality [11]. A chest radiograph after inserting a nasogastric tube will clinch the diagnosis in case of gastrothorax. The other investigations which can be done are computed tomography of the chest and abdomen, magnetic resonance imaging (MRI), and upper or lower gastrointestinal contrast studies [11]. So, a detailed history, good clinical examination and appropriate radiological investigations hold the key to a correct and early diagnosis and a good eventual prognosis. Once diagnosed, the treatment is early surgery either open or minimally invasive. The approach can be abdominal or thoracic depending on the expertise and personal preference of the surgeon. CDH may be associated with other congenital anomalies in about 40–50% of cases [12]. Gastrointestinal tract congenital anomalies are very common but cardiovascular and neurological anomalies determine the final outcome and prognosis for the child. Fortunately, there were no obvious associated congenital anomalies in our patient. The late presenting CDH poses considerable diagnostic challenges because of its varied presentation often resulting in diagnostic delay, inappropriate treatment and potential fatal outcome.

Extra Corporeal Membrane Oxygenation (ECMO) is used for very sick neonates, but is available at very few centres. In spite of being a tertiary care centre, even our institute does not have ECMO facility but we do have a state of the art neonatal intensive care unit (NICU) with a good number of neonatal ventilators and trained neonatal intensivists. They manage these sick neonates by putting central lines, giving TPN and vasopressors if they are in shock and unstable. There is round the clock availability of senior paediatric surgeons

who operate upon these patients at the earliest with their general condition permitting. This does translate into an improved eventual survival of neonates with life threatening congenital anomalies like CDH. Therefore, in a developing country like India, the need of the hour is to develop state of the art neonatal intensive care units (NICU) with dedicated staff and have trained paediatric anaesthetists and neonatal intensivists for a good overall survival of neonates having this potentially life-threatening condition.

We also want to emphasize the fact in a developing country like India, antenatal supervision by trained specialists is not available to a majority of females especially in remote areas and villages. Even if they go to primary and community health centres, radiologists are not available there. Secondly, ultrasonography being a subjective investigations, some of the congenital anomalies including CDH do get missed on their screening at 18–20 weeks of gestation. But a large majority of them usually present after 20 weeks of gestation. So, even if CDH or any other life threatening congenital anomaly is detected, MTP Act doesn't allow the treating gynaecologist and paediatric surgeon to advise for termination of these pregnancies in India, but the families of these pregnant do have an idea of not so good eventual prognosis in these early presenting CDH. The implication is they never report to a tertiary care centre well equipped with all the facilities to handle these complicated cases because of ignorance and financial constraints. Therefore, so many neonates of CDH either get aborted, are still-born or die soon after birth at homes, primary health centres, community health centres or even general hospitals because of non-availability of advanced health care facilities. This mortality goes unreported in medical literature. Moreover, we, at a government tertiary care centre accept only the savagable neonates having CDH due to a limited number of neonatal ventilators in our set-up, rest of the neonates are referred to some other centres. The likely outcome of these very sick neonates is also not reported. In addition to this, only those neonates are taken up for surgery who are haemodynamically stable and seem to be salvagable. So, there is definitely a hidden mortality in neonates with CDH which never gets reported [13].

4. Conclusion

CDH after neonatal period can present with wide array of clinical symptoms which often lead to delay in diagnosis and even misdiagnosis resulting in significant morbidity and potentially fatal outcomes. Interventions with misdiagnosis may result in iatrogenic complications which further increase morbidity and can even result in unwarranted mortality. When patient presents with recurrent non-specific respiratory or gastrointestinal tract symptoms, CDH should always be considered in differential diagnosis. Chest X-ray with nasogastric tube insertion, contrast enhanced CT scan and barium studies pave the way to correct diagnosis decreasing the morbidity and potential mortality due to CDH.

Conflicts of interest

There is no conflict of interest amongst the authors.

Funding

There was no source of funding for our research.

Ethical approval

Not applicable as it is a case report.

Consent

Written informed consent was obtained from the patient's guardian for publication of this case report and any accompanying images.

We state that the work has been reported in line with the SCARE criteria [14].

We also declare that there are no conflicts of interest amongst the authors.

The consent has been taken from the parents of the child for publication of this case report.

Author contribution

Pradeep Kajal – Diagnosed the condition and operated upon the patient

Namita Bhutani – Wrote the article and did the final editing.

Mohit Goyal – Reviewed the literature and provided the needed articles.

Poonam Kamboj – Managed the patient post-operatively.

Registration of research studies

Not applicable.

Guarantor

Kamal N. Rattan.

References

- [1] P.D. Robinson, D.A. Fitzgerald, Congenital diaphragmatic hernia, *Pediatr. Respir. Rev.* 8 (2007) 323–335.
- [2] E.A. Elhalaby, M.H. Abo Sikeena, Delayed presentation of congenital diaphragmatic hernia, *Pediatr. Surg. Int.* 18 (2002) 480–485.
- [3] M. Bağlaj, Late-presenting congenital diaphragmatic hernia in children: a clinical spectrum, *Pediatr. Surg. Int.* 20 (2004) 658–669.
- [4] M.T. Vega, R.H. Maldonado, G.T. Vega, A.T. Vega, E.A. Liévano, P.M. Velázquez, Late-onset congenital diaphragmatic hernia: a case report, *Int. J. Surg. Case Rep.* 4 (11) (2013) 952–954, <http://dx.doi.org/10.1016/j.ijscr.2013.07.034>.
- [5] B. Lawrence, S. David, H. Sigmund, S. Barry, The late-presenting pediatric bochdalek hernia: a 20-year review, *J. Pediatr. Surg.* 23 (1988) 735–739, [http://dx.doi.org/10.1016/S0022-3468\(88\)80414-7](http://dx.doi.org/10.1016/S0022-3468(88)80414-7).
- [6] R. Wadhwa, Z. Ahmad, M. Kumar, Delayed traumatic diaphragmatic herniamimicking hydro-pneumothorax. [PubMed Central], *Indian J. Anaesth.* 58 (2) (2014) 186–189, <http://dx.doi.org/10.4103/0019-5049.130825>, Available from <http://www.ncbi.nlm.nih.gov/pmc/articles/PMC4050937>.
- [7] J.J. Greer, Current concepts on the pathogenesis and etiology of congenital diaphragmatic hernia, *Respir. Physiol. Neurobiol.* 189 (2) (2013) 232–240.
- [8] I. Iritani, Experimental study on embryogenesis of congenital diaphragmatic hernia, *Anat. Embryol. (Berl.)* 169 (2) (1984) 133–139.
- [9] D.C. Veenma, A. de Klein, D. Tibboel, Developmental and genetic aspects of congenital diaphragmatic hernia, *Pediatr. Pulmonol.* 47 (6) (2012) 534–545.
- [10] J. Rohana, N.Y. Boo, C.R. Thambidorai, Early outcome of congenital diaphragmatic hernia in a Malaysian tertiary centre, *Singapore Med. J.* 49 (2008) 142–144.
- [11] K.S. Oh, B. Newman, T.M. Bender, et al., Radiological evaluation of the diaphragm, *Radiol. Clin. North Am.* 26 (1988) 355–364.
- [12] M. Hosgor, I. Karaca, A. Karkiner, B. Ucan, Fescekoglu O. ErdagG, Associated malformations in delayed presentation of congenital diaphragmatic hernia, *J. Pediatr. Surg.* 39 (July (7)) (2004) e1073–e1076.
- [13] E.M. Brownlee, A.G. Howatson, C.F. Davis, A.J. Sabharwal, The hidden mortality of congenital diaphragmatic hernia: a 20-year review, *J. Pediatr. Surg.* 44 (February (2)) (2009) 317–320.
- [14] R.A. Agha, A.J. Fowler, A. Saetta, I. Barai, S. Rajmohan, D.P. Orgill, for the SCARE group, the SCARE statement: consensus-based surgical case report guidelines, *Int. J. Surg.* 34 (2016) 180–186.

Open Access

This article is published Open Access at sciedirect.com. It is distributed under the [IJSCR Supplemental terms and conditions](#), which permits unrestricted non commercial use, distribution, and reproduction in any medium, provided the original authors and source are credited.