

# Reliability and Reproducibility of a Novel Grading System for Lesions of the Ligamentous-Fossa-Foveolar Complex in Young Patients Undergoing Open Hip Preservation Surgery

Vera Maren Stetzelberger,<sup>\*†</sup> MD, Corinne Andrea Zurmühle,<sup>†</sup> MD, Matthieu Hanauer,<sup>†</sup> MD, Jonathan Laurençon,<sup>†</sup> MD, Darius Marti,<sup>†</sup> MD, Malin Kristin Meier,<sup>‡</sup> MD, Vlad Popa,<sup>†</sup> MD, Joseph Michael Schwab,<sup>§</sup> MD, and Moritz Tannast,<sup>†</sup> MD

*Investigation performed at Department of Orthopaedic Surgery and Traumatology, Cantonal Hospital Fribourg HFR, University of Fribourg, Fribourg, Switzerland*

**Background:** Several classification systems based on arthroscopy have been used to describe lesions of the ligamentum teres (LT) in young active patients undergoing hip-preserving surgery. Inspection of the LT and associated lesions of the adjuvant fovea capitis and acetabular fossa is limited when done arthroscopically but is much more thorough during open surgical hip dislocation. Therefore, we propose a novel grading system based on our findings during surgical dislocation comprising the full spectrum of ligamentous-fossa-foveolar complex (LFFC) lesions.

**Purpose:** To determine (1) intraobserver reliability and (2) interobserver reproducibility of our new grading system.

**Study Design:** Cohort study (diagnosis); Level of evidence, 3.

**Methods:** We performed this validation study on 211 hips (633 images in total) with surgical hip dislocation (2013-2021). We randomly selected 5 images per grade for each LFFC item to achieve an equal representation of all grades (resulting in 75 images). The ligament, fossa, and fovea were subcategorized into normal, inflammation, degeneration, partial, and complete defects. All surgeries were performed in a standardized way by a single surgeon. The femur was disarticulated using a bone hook, the LT was inspected, documented and resected, then the fossa and fovea were documented with the femoral head in full dislocation using a 70° arthroscope. Six observers with different levels of expertise in hip-preserving surgery independently conducted the measurements twice, and intraclass correlation coefficients (ICC) were calculated to determine (1) intraobserver reliability and (2) interobserver reproducibility of the novel grading system.

**Results:** For intraobserver reliability, excellent ICCs were found in both the junior and the experienced raters for grading the ligament, fossa, fovea, and total LFFC (ICCs ranged from 0.91 to 0.99 for the LFFC score). We found excellent interobserver reproducibility between raters for all items of the LFFC (all interobserver ICCs  $\geq$  0.76).

**Conclusion:** Our new grading system for lesions of the LFFC is highly reliable and reproducible. It covers the full spectrum of damage more precisely than arthroscopic classifications do and offers a scientific basis for standardized intraoperative evaluation.

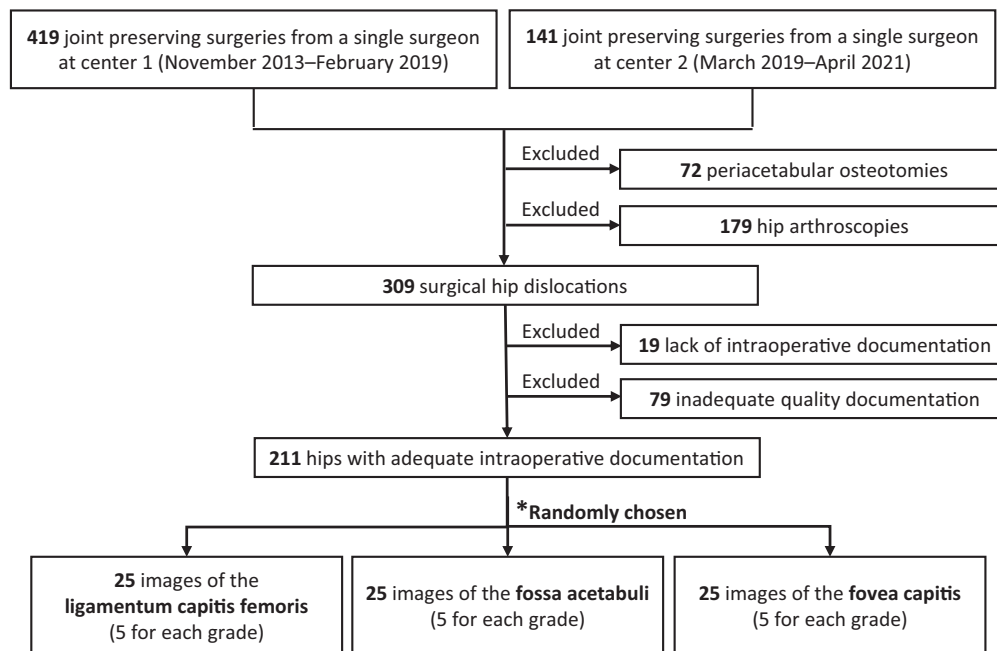
**Keywords:** femoroacetabular impingement; fossa acetabuli; hip arthroscopy; joint preserving surgery; ligamentum capitis femoris; ligamentum teres; perifoveolar area; surgical hip dislocation; validation of grading system

Intra-articular lesions in joint-preserving hip surgery have focused traditionally on peripheral lesions of the chondrolabral complex.<sup>23</sup> While trauma is a well-known cause of central ligamentous-fossa-foveolar complex (LFFC)

lesions,<sup>6</sup> hips with developmental dysplasia,<sup>11,12</sup> femoroacetabular impingement (FAI),<sup>7,17,19</sup> and osteoarthritis also regularly demonstrate LFFC lesions. The ligamentum teres (LT) is an innervated structure and has been recognized as a potential source of hip pain.<sup>1,7,16,19,22</sup> Specifically in athletes, lesions of the ligament are highly prevalent.<sup>6,8,20</sup> Damage to the LT is in fact the third most common injury in athletes who have undergone hip

The Orthopaedic Journal of Sports Medicine, 10(6), 23259671221098750  
DOI: 10.1177/23259671221098750  
© The Author(s) 2022

This open-access article is published and distributed under the Creative Commons Attribution - NonCommercial - No Derivatives License (<https://creativecommons.org/licenses/by-nc-nd/4.0/>), which permits the noncommercial use, distribution, and reproduction of the article in any medium, provided the original author and source are credited. You may not alter, transform, or build upon this article without the permission of the Author(s). For article reuse guidelines, please visit SAGE's website at <http://www.sagepub.com/journals-permissions>.



**Figure 1.** Flowchart of participant selection and randomization into groups. Asterisk indicates randomly chosen.

arthroscopy.<sup>5,6</sup> LT lesions are associated frequently with articular cartilage damage in the inferior middle part of the acetabulum as well as the apex of the femoral head.<sup>15</sup>

An accurate, reliable, and reproducible description of such lesions is crucial to understand their origin, detect associated pathomechanisms, and potentially predict prognosis. To date, no descriptive standard that meets these requirements has emerged. Current arthroscopic descriptions of LFFC lesions have significant drawbacks. These include a lack of consideration of associated cartilage lesions at the foveal insertion and the fossa,<sup>4,14</sup> unreliable or missing intra- and interobserver analyses,<sup>9,18,21</sup> and incomplete visual analysis of the lesions.<sup>4,14,21</sup>

In contrast to hip arthroscopy, surgical hip dislocation allows an unrestricted visualization of the LFFC, including a dynamic assessment of the hip. Based on our long clinical experience, we introduce a novel grading system for lesions of the LFFC with a systematic description of the LT, the acetabular fossa, and perifoveolar region. The aim of this study was to evaluate (1) intraobserver reliability and (2) interobserver reproducibility of this grading system. Our hypotheses were that the new grading system would have superior intraobserver reliability and interobserver

reproducibility when compared with previous grading systems.

## METHODS

In this local institutional review board–approved diagnostic study we assessed 560 patients with informed consent, undergoing joint-preserving surgery by a single surgeon (M.T.) at 2 institutions (2013–2019 and 2019–2021, respectively) (Figure 1).

We excluded 179 hips that underwent arthroscopy and 72 that underwent periacetabular osteotomy. From 309 hips that underwent surgical dislocation, 98 hips with incompletely performed intraoperative documentation were excluded, leaving 211 hips for further evaluation. The mean age at surgery was  $31 \pm 11$  years (range, 17–74), and 44% of patients were male (Table 1).

For each hip, 3 images in total (1 of each of the structures from the LFFC) were available: 1 from the ligament, 1 from the acetabular fossa, and 1 from the perifoveolar area. This resulted in a total of 633 images. The developer of the novel grading system (V.M.S.) preliminarily graded the hips accordingly. Using a computer-generated randomization

\*Address correspondence to Vera Maren Stetzelberger, MD, Department of Orthopaedic Surgery and Traumatology, Cantonal Hospital Fribourg HFR, University of Fribourg, Chemin des Pensionnats 2-6, 1708 Fribourg, Switzerland (email: vera.stetzelberger@unifr.ch).

†Department of Orthopaedic Surgery and Traumatology, Cantonal Hospital Fribourg HFR, University of Fribourg, Fribourg, Switzerland.

‡Department of Orthopaedic Surgery and Traumatology, Inselspital Bern, University of Bern, Bern, Switzerland.

§Department of Orthopaedic Surgery, Medical College of Wisconsin, Milwaukee, Wisconsin, USA.

Final revision submitted February 23, 2022; accepted March 9, 2022.

The authors declared that there are no conflicts of interest in the authorship and publication of this contribution. AOSSM checks author disclosures against the Open Payments Database (OPD). AOSSM has not conducted an independent investigation on the OPD and disclaims any liability or responsibility relating thereto.

Ethical approval for this study was obtained from the regional ethics committee for the Canton of Bern (project ID: 2018-00078).

TABLE 1  
Descriptive, Radiographic, and Surgical Parameters of the Patients (N = 75 Patients; 75 Hips)<sup>a</sup>

Parameter	Value	Parameter	Value
<b>Characteristics</b>		<b>Femoral radiographic features</b>	
Age at surgery, y	31 ± 11 (17 to 74)	Neck-shaft angle, deg	135 ± 6 (114 to 149)
BMI	24 ± 4 (18 to 37)	Alpha angle, deg	57 ± 13 (37 to 97)
Male	32 (44)	Femoral version, deg	29 ± 17 (-5 to 58)
Right	31 (41)	<b>Surgical features</b>	
<b>Diagnosis</b>		Offset correction	68 (91)
FAI	58 (77)	Acetabular rim trimming	30 (40)
Cam	24 (32)	Tuberculum tertium trimming	9 (12)
Pincer	1 (1.3)	Labral refixation	43 (57)
Torsional deformity	6 (8)	Additional periacetabular osteotomy	5 (7)
Combined	22 (29)	Additional subtrochanteric	13 (17)
Associated dysplasia	5 (7)	Derotation osteotomy	7 (9)
Epiphysiolysis capitis femoris	1 (1.3)	Rotation osteotomy	6 (8)
Legg-Calvé-Perthes disease	1 (1.3)	Acetabular microfracturing/drilling	16 (21)
Avascular necrosis	4 (5)	Femoral osteochondroplasty	3 (4)
Traumatic onset	11 (15)		
<b>Acetabular radiographic features</b>			
Lateral center-edge angle, deg	36 ± 12 (0 to 68)		
Acetabular index, deg	0.49 ± 9 (-29 to 29)		
Extrusion index, deg	16 ± 10 (-8 to 52)		
Anterior center-edge angle, deg	44 ± 4 (10 to 74)		
Anterior acetabular coverage, %	28 ± 12 (7 to 68)		
Posterior acetabular coverage, %	48 ± 12 (10 to 77)		
Total acetabular coverage, %	84 ± 10 (43 to 100)		
Crossover sign, % positive	51 (82)		
Posterior wall sign, % positive	38 (61)		
Retroversion index, %	16 ± 16 (0 to 63)		

<sup>a</sup>Continuous values are expressed as mean ± SD (range); other values are presented as No. (%). BMI, body mass index; FAI, femoroacetabular impingement.

list, the first author (V.M.S.) collected consecutive images for each grade of the 3 items of the LFFC until 5 images per grade and structure were present. This resulted in a total of 75 images (25 for each component of the LFFC) in 75 different patients.

Based on our clinical observation, we developed a grading system for the LFFC with specific categorizations for the LT, the acetabular fossa, and the perifoveolar area. All 3 items were subcategorized into normal, inflammation, degeneration, partial, and complete defects. In contrast to previously presented categorical classification systems, the proposed grading system incorporates the entire spectrum of lesions observed during surgical hip dislocation for all surgical indications. The specific definitions with a detailed description of the lesions are summarized in Table 2 and illustrated in Figure 2.

The indications for surgical hip dislocation were symptomatic intra- and extra-articular FAI with or without femoral version abnormalities (not accessible using hip arthroscopy), posttraumatic lesions, and avascular necrosis of the femoral head (Table 1). We used the inventor's original technique for hip dislocation.<sup>13</sup> A step-cut osteotomy of the greater trochanter was usually conducted,<sup>2</sup> except in cases necessitating distalization of the trochanter. Before transection of the ligament and dislocation of the femoral head, the joint was subluxated using a bone hook with the

hip in flexion and external rotation. This allowed a full visualization of the pyramidal fan-shaped structure of the LT (Figure 3).

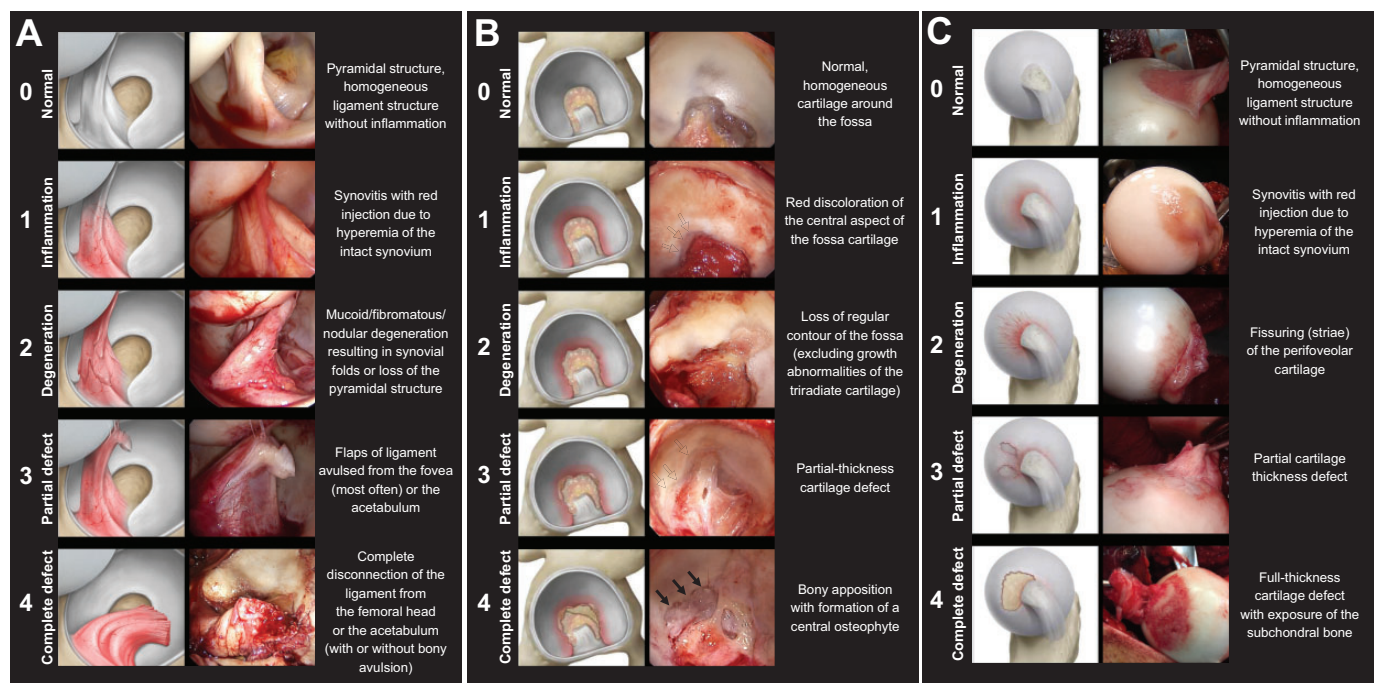
We used a 70° arthroscopic camera (4K Synergy Arthroscopy; Arthrex) for photographic documentation. The fossa and the perifoveolar area were inspected using a probe (Subtilis nerve root retractor cushioning 10 mm; Accuratus) after transection and resection of the LT.

One of the authors (V.M.S.) blinded and randomized the 75 images. Six observers (C.A.Z., M.H., J.L., D.M., M.K.M., V.P.) with different levels of expertise in hip joint-preserving surgery independently conducted the assessments twice, with at least 1 month between assessments. The observers did not participate in the selection of the cases or in the blinding process. Three were board-certified staff hip surgeons with specific training in joint-preserving surgery (M.H., J.L., D.M.), and 3 were orthopaedic surgery residents (C.A.Z., M.K.M., V.P.). All raters were provided with schematic illustrations and intraoperative examples of the classification system (Figure 2) as well as a detailed description of the specific lesions (Table 2). The treating surgeon (M.T.) was not involved in the measurements. Given 6 observers each performed 2 measurements on 75 intraoperative images, this resulted in a total of 900 measurements for the final analysis. For final evaluation, we calculated the LFFC score, defined as the sum of the

TABLE 2

Description of the Novel Classification System for Grading the Different Lesions of the Ligamentous-Fossa-Foveolar Complex

Parameter/ Grading	Grade 0 (Normal)	Grade 1 (Inflammation)	Grade 2 (Degeneration)	Grade 3 (Partial Defect)	Grade 4 (Complete Defect)
Ligament	Homogeneous, pyramidal structure	Synovitis with red injection due to hyperemia of the intact synovium	Mucoid/fibromatous/nodular degeneration resulting in synovial folds or loss of the pyramidal structure	Flaps of ligament avulsed from the fovea (most often) or the acetabulum	Complete disconnection of the ligament from the femoral head or the acetabulum (with or without bony avulsion)
Fossa	Normal	Red discoloration of the central aspect of the fossa cartilage	Loss of regular contour of the fossa (excluding growth abnormalities of the triradiate cartilage)	Partial-thickness cartilage defect	Bony apposition with formation of a central osteophyte
Fovea	Normal	Red discoloration of the perifoveolar cartilage as a sign of hyperemia	Fissuring (striae) of the perifoveolar cartilage	Partial-thickness cartilage defect	Full-thickness cartilage defect with exposure of the subchondral bone



**Figure 2.** Grading system of the ligamentous-fossa-foveolar complex for lesions of the (A) ligament, (B) fossa, and (C) perifoveolar area is demonstrated using a schematic illustration (left column), an intraoperative image (right column), and the corresponding description.

individual degeneration grades for the ligament, the acetabular fossa and the perifoveolar area for the 75 hips (corresponding to 75 patients).

### Statistical Analysis

Using the Bonett method for sample size calculation,<sup>3</sup> given an expected intraclass correlation coefficient (ICC) reliability of 0.85 with a precision of  $\pm 0.09$ ,<sup>23</sup> a confidence level of 95%, 6 raters, and an expected dropout rate of 0%, we calculated a minimum sample size of 21 images per item. We calculated

the ICC (2-way model, absolute agreement) with 95% CI to determine the intraobserver reliability and interobserver reproducibility. All statistical analyses were conducted using MedCalc Statistical Software Version 19.8 (2021).

## RESULTS

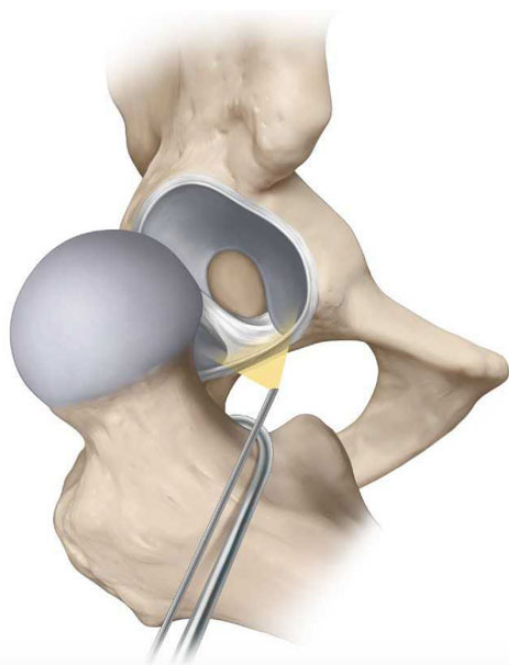
### Intraobserver Reliability

The highest intraobserver ICCs were found for ligament lesions, followed by perifoveolar and acetabular fossa

lesions. Specifically, for ligament lesions, we found a mean ICC of 0.972 (95% CI, 0.926-0.985) (Table 3). For acetabular fossa lesions, we found a mean ICC of 0.883 (95% CI, 0.753-0.947). For perifoveolar lesions, we found a mean ICC of 0.946 (95% CI, 0.856-0.976). For the LFFC sum, we found a mean ICC of 0.949 (95% CI, 0.885-0.977). The mean ICC of the 3 senior raters was 0.942 (95% CI, 0.869-0.974) and that of the resident raters was 0.956 (95% CI, 0.901-0.980). The mean Kappa value was 0.83 (95% CI 0.74-0.93).

### Interobserver Reproducibility

As with intraobserver reliability, ligament lesions had the highest ICC for interobserver reproducibility, followed by perifoveolar and acetabular fossa lesions (Table 3). Specifically, for ligament lesions, the mean ICC was 0.92 (95% CI, 0.88-0.96). For acetabular fossa lesions, the mean ICC was 0.79 (95% CI, 0.67-0.89). For perifoveolar lesions, we found a mean ICC of 0.88 (95% CI, 0.80-0.94). For the LFFC sum, we found a mean ICC of 0.93 (95% CI, 0.81-0.94). The mean ICC of the 3 senior raters was 0.89 (95% CI, 0.80-0.95), and for the resident raters, it was 0.90 (95% CI, 0.81-0.95). The mean interobserver reproducibility Kappa value was 0.60 (0.59-0.60).



**Figure 3.** The femoral head is placed in external rotation and partially dislocated using a bone hook, then the ligamentous-fossa-foveolar complex is assessed and documented using a 70° arthroscope.

### DISCUSSION

Lesions of the LFFC in joint-preserving surgery are reportedly highly prevalent although the underlying pathomechanism is not yet fully understood. Current classification systems are based on arthroscopic inspection only, which are subject to limitations regarding visibility. In addition, some of them focus on the integrity of the LT only and do not involve a description of (very commonly found) associated lesions of the acetabular fossa and the perifoveolar area. We have introduced and validated a novel grading system based on surgical hip dislocation and found it to be highly reliable and reproducible.

The lowest intraobserver values were mainly found for lesions of the acetabular fossa. This might be related to misinterpretation of the nature of the acetabular fossa, which often shows irregularities of its shape due to incomplete fusion of the triradiate cartilage.<sup>10</sup> In contrast to arthroscopic classifications,<sup>4,9,14</sup> our grading system has a very high reliability for lesions of the LT. We relate this to the unrestricted visibility of the pyramidal ligament structure when the femoral head is subluxated (Figure 3) using a bone hook. The direction of traction is parallel to the spatial orientation of the ligament, revealing the pyramidal structure and any lesions very well. During hip arthroscopy, the

**TABLE 3**  
Results of Reliability and Reproducibility Analysis<sup>a</sup>

Parameter	Intraobserver ICC (95% CI)						Interobserver ICC (95% CI)	
	Senior Surgeons			Junior Surgeons			First Measurement	Second Measurement
	Observer 1	Observer 2	Observer 3	Observer 4	Observer 5	Observer 6		
Ligament lesions	0.99 (0.98-0.99)	0.96 (0.91-0.98)	0.96 (0.91-0.98)	0.95 (0.90-0.98)	1	0.97 (0.93-0.99)	0.91 (0.89-0.95)	0.92 (0.87-0.96)
Fossa acetabuli lesions	0.79 (0.53-0.91)	0.95 (0.88-0.96)	0.74 (0.49-0.88)	0.90 (0.79-0.95)	0.97 (0.94-0.99)	0.95 (0.89-0.98)	0.76 (0.63-0.87)	0.82 (0.71-0.90)
Perifoveolar lesions	1	0.92 (0.82-0.96)	0.93 (0.86-0.97)	0.96 (0.92-0.98)	0.99 (0.98-1)	0.87 (0.71-0.94)	0.87 (0.79-0.93)	0.89 (0.81-0.94)
LFFC score	0.95 (0.88-0.98)	0.96 (0.91-0.98)	0.91 (0.81-0.96)	0.93 (0.86-0.97)	0.99 (0.98-0.99)	0.97 (0.93-0.99)	0.87 (0.79-0.93)	0.98 (0.97-0.99)

<sup>a</sup>ICC, intraclass correlation coefficient; LFFC, ligamentous-fossa-foveolar complex.

TABLE 4  
Definition of Different Classification Systems in the Literature<sup>a</sup>

	Gray and Villar <sup>14</sup> (1997)	Botser et al <sup>4</sup> (2011)	Porthos Salas and O'Donnell <sup>21</sup> (2015)	O'Donnell and Arora <sup>18</sup> (2018) <sup>b</sup>	Current study (2022)
Surgery	Arthroscopy	Arthroscopy	Arthroscopy	Arthroscopy	Open surgery
0	—	—	—	Normal	Normal
1	Complete rupture	Low-grade tear (<50%)	Ligament synovitis	Synovitis (± fraying)	Inflammation
2	Partial rupture	High-grade tear (>50%)	Ligament synovitis with impingement	Partial tear (± synovitis)	Degeneration
3	Degenerative rupture (complete or partial)	Full-thickness tear (100%)	Partial ligament tear: low grade	Complete tear (± synovitis)	Partial defect
4	—	—	Partial ligament tear: high grade	—	Complete defect
5	—	—	Partial ligament tear with hip osteoarthritis	—	—
6	—	—	Complete tear of the ligament: (1) acquired, (2) avulsion fracture, (3) congenital/absence	—	—
Intraobserver	Cohen $\kappa$ for 2 observers: 0.66 (0.35-0.92)	Cohen $\kappa$ for 2 observers: 0.42 (0.15-0.65)	NA	NA	$\kappa$ for 6 observers: 0.83 (0.74-0.93)
Interobserver	Fleiss $\kappa$ for 4 observers: 0.39 (0.15-0.598)	Fleiss $\kappa$ for 4 observers: 0.38 (0.21-0.57)	NA	NA	Fleiss $\kappa$ for 6 observers: 0.60 (0.59-0.60)
Associated lesions addressed	No	No	Yes	No	Yes

<sup>a</sup>Dashes indicate not applicable. BTS, Beighton test score; NA, not available.

<sup>b</sup>A or B depending on the laxity. A, no generalized laxity (BTS <3); B, generalized laxity (BTS  $\geq$ 4).

ligament initially relaxes under longitudinal traction and is then assessed using internal and external rotation. This can lead to an accordion effect of the ligament, which can be incorrectly identified as a partial rupture.

The values for interobserver reproducibility were generally lower compared with the intraobserver values. The lowest ICC of 0.76 was found for the acetabular fossa lesions. Interestingly, this evaluation was independent of the level of experience of the raters. We believe this adds to the robustness of our grading system.

In the literature, there is little information available about inter- and intraobserver variability of existing LFFC classification systems (Table 4).

The original articles describing a relatively rough evaluation of the LT by Gray and Villar<sup>14</sup> and Botser et al<sup>4</sup> did not include reliability or reproducibility. Later, Devitt et al<sup>9</sup> specifically assessed the reliability and reproducibility of both classifications and found only a fair agreement even with experienced observers. A main criticism was that the presence of synovitis was not in either classification but was considered an important finding. Based on this, Salas and O'Donnell<sup>21</sup> introduced a novel classification system that included therapeutic recommendations but did not provide inter- and interobserver analyses. Later, O'Donnell and Arora<sup>18</sup> published another classification system, also

including synovitis as a criterion and with special consideration of joint hypermobility, but they did not perform an assessment of the reliability and reproducibility (Table 4).

Our values are substantially higher compared with the reported values for the Gray and Villar<sup>14</sup> classification. In addition, it includes selected features of the Salas classification<sup>21</sup> but on a systematic basis. This might be due to the larger number of items in our grading system and the use of kappa values instead of the ICC for statistical analysis. Even when using kappa analysis for our evaluation for better comparability, we noted considerably higher values (mean intraobserver reliability:  $\kappa = 0.83$  [95% CI, 0.74-0.93]; mean interobserver reproducibility,  $\kappa = 0.60$  [95% CI, 0.59-0.60]).

The current study has some limitations. First, the proposed grading system is descriptive only and does not take into account clinical information. The potential use for future prognostic or therapeutic recommendations has yet to be shown. Specifically, the weighting of the individual items needs to be evaluated. Moreover, most hip surgeons use an arthroscopic approach for the treatment of FAI and may encounter difficulties in fully applying our classification system. However, in contrast to the previously developed classification system, our system covers the entire degenerative cascade of the LFFC and is reliable and

reproducible. Therefore, even with a limited application in hip arthroscopy, our grading system offers a validated tool for future studies on prognosis, treatment guidelines, and causes of lesions. A second limitation is that we used static photographs instead of video clips for validation. Since the features of our grading system are based solely on visual criteria and not tactile information, static images should suffice. In addition, we believe this feature makes our grading system more user-friendly and adds to its reproducibility.

## CONCLUSION

We have introduced a novel grading system for the LFFC complex based on open surgery. The grading system seems to be robust, be independent of the experience level of the raters, and have high reliability and reproducibility. It seems to be superior to previously presented descriptions and offers a scientific basis for standardized intraoperative evaluation. As a first line, future studies will need to focus on the correlation of the grading system using magnetic resonance imaging so that it can be implemented in preoperative evaluation of the patients, which is a decisive factor for open joint-preserving surgery as well as hip arthroscopy. This will convert the descriptive grading system into a more clinically useful classification in open and arthroscopic surgery.

## REFERENCES

- Bardakos NV, Villar RN. The ligamentum teres of the adult hip. *J Bone Joint Surg Br.* 2009;91(1):8-15.
- Bastian JD, Wolf AT, Wyss TF, Nötzli HP. Stepped osteotomy of the trochanter for stable, anatomic refixation. *Clin Orthop Relat Res.* 2009;467(3):732-738.
- Bonett DG. Sample size requirements for estimating intraclass correlations with desired precision. *Stat Med.* 2002;21(9):1331-1335.
- Botser IB, Martin DE, Stout CE, Domb BG. Tears of the ligamentum teres: prevalence in hip arthroscopy using 2 classification systems. *Am J Sports Med.* 2011;39(suppl):117S-125S.
- Byrd JW, Jones KS. Hip arthroscopy in athletes. *Clin Sports Med.* 2001;20(4):749-761.
- Byrd JWT, Jones KS. Traumatic rupture of the ligamentum teres as a source of hip pain. *Arthroscopy.* 2004;20(4):385-391.
- Chahla J, Soares EAM, Devitt BM, et al. Ligamentum teres tears and femoroacetabular impingement: prevalence and preoperative findings. *Arthroscopy.* 2016;32(7):1293-1297.
- Chona DV, Minetos PD, LaPrade CM, et al. Hip dislocation and subluxation in athletes: a systematic review. Published online October 8, 2021. *Am J Sports Med.* doi:10.1177/03635465211036104
- Devitt BM, Smith B, Stapf R, Jo S, O'Donnell JM. The reliability of commonly used arthroscopic classifications of ligamentum teres pathology. *J Hip Preserv Surg.* 2017;4(2):187-193.
- Dietrich TJ, Suter A, Pfirrmann CWA, Dora C, Fucentese SF, Zanetti M. Supraacetabular fossa (pseudodeflect of acetabular cartilage): frequency at MR arthrography and comparison of findings at MR arthrography and arthroscopy. *Radiology.* 2012;263(2):484-491.
- Domb BG, Lareau JM, Baydoun H, Botser I, Millis MB, Yen Y-M. Is intraarticular pathology common in patients with hip dysplasia undergoing periacetabular osteotomy? *Clin Orthop Relat Res.* 2014;472(2):674-680.
- Domb BG, Martin DE, Botser IB. Risk factors for ligamentum teres tears. *Arthroscopy.* 2013;29(1):64-73.
- Ganz R, Gill TJ, Gautier E, Ganz K, Krügel N, Berlemann U. Surgical dislocation of the adult hip a technique with full access to the femoral head and acetabulum without the risk of avascular necrosis. *J Bone Joint Surg Br.* 2001;83(8):1119-1124.
- Gray AJ, Villar RN. The ligamentum teres of the hip: an arthroscopic classification of its pathology. *Arthroscopy.* 1997;13(5):575-578.
- Kaya M, Suzuki T, Minowa T, Yamashita T. Ligamentum teres injury is associated with the articular damage pattern in patients with femoroacetabular impingement. *Arthroscopy.* 2014;30(12):1582-1587.
- Leunig M, Beck M, Stauffer E, Hertel R, Ganz R. Free nerve endings in the ligamentum teres. *Acta Orthop Scand.* 2000;71(5):452-454.
- Manner HM, Mast NH, Ganz R, Leunig M. Potential contribution of femoroacetabular impingement to recurrent traumatic hip dislocation. *J Pediatr Orthop.* 2012;21(6):574-578.
- O'Donnell JM, Arora M. A novel and simple classification for ligamentum teres pathology based on joint hypermobility. *J Hip Preserv Surg.* 2018;5(2):113-118.
- O'Donnell JM, Pritchard M, Salas AP, Singh PJ. The ligamentum teres—its increasing importance. *J Hip Preserv Surg.* 2014;1(1):3-11.
- Philippon M, Schenker M, Briggs K, Kuppersmith D. Femoroacetabular impingement in 45 professional athletes: associated pathologies and return to sport following arthroscopic decompression. *Knee Surg Sports Traumatol Arthrosc.* 2007;15(7):908-914.
- Porthos Salas A, O'Donnell JM. Ligamentum teres injuries—an observational study of a proposed new arthroscopic classification. *J Hip Preserv Surg.* 2015;2(3):258-264.
- Wettstein M, Garofalo R, Borens O, Mouhsine E. Traumatic rupture of the ligamentum teres as a source of hip pain. *Arthroscopy.* 2005;21(3):382.
- Yamamoto T, Zurmühle CA, Stetzelberger VM, Schwab JM, Steppacher SD, Tannast M. The new Bern chondrolabral classification is reliable and reproducible. *Clin Orthop Relat Res.* 2021;479(5):1002-1013.